



ELSEVIER

Contents lists available at [ScienceDirect](https://www.sciencedirect.com)

Respiratory Medicine Case Reports

journal homepage: www.elsevier.com/locate/rmcr

Case report

A wolf in sheep's clothing: Dogs confer an unrecognized risk for their immunocompromised master

Lipisha Agarwal^{b,c}, Harpreet Singh^{a,*}, Chinmay Jani^{b,c}, Peymaan Banankhah^{b,c}, Mohammed Abdalla^a, Jonathan S. Kurman^a, Rose A. Franco^a^a Department of Medicine, Division of Pulmonary and Critical Care, Medical College of Wisconsin, Milwaukee, WI, USA^b Department of Medicine, Mount Auburn Hospital/Beth Israel Lahey Health, Cambridge, MA, USA^c Harvard Medical School, Boston, MA, USA

ARTICLE INFO

Keywords:

Bordetella bronchiseptica
Immunosuppression
Respiratory failure
Pneumonia

ABSTRACT

Bordetella bronchiseptica is a pleomorphic gram-negative coccobacillus that commonly causes respiratory tract infections in canines, felines, and swine. Human infections are rare. We report a case of *Bordetella bronchiseptica* pneumonia in a 67-year-old immunocompromised host. His past medical history included multiple myeloma treated with autologous bone marrow transplant followed by a chimeric antigen receptor cell therapy for relapse. He was admitted with unremitting diarrhea due to HHV-6 pancolitis. During the hospital course he developed high-grade fever (102.3°F), cough and respiratory failure requiring mechanical ventilation. Chest imaging demonstrated bilateral opacities most pronounced at lung bases and worsening mediastinal lymphadenopathy. Bronchoalveolar lavage cultures grew *Bordetella bronchiseptica*. He was treated with piperacillin/tazobactam, but developed progressive multiorgan failure, transitioned to comfort care, and expired in the hospital. *Bordetella bronchiseptica* is an organism that do not cause serious infection in immunocompetent persons but can sometimes cause serious illness in immunocompromised populations. It causes “kennel cough” in dogs and spread by respiratory droplets. Dogs and cats are not uniformly vaccinated against this pathogen. Therefore, transmission through animal contact is becoming increasingly common. Realize that unlike other *Bordetella* spp, this pathogen is not typically responsive to erythromycin and is often resistant to ampicillin and cephalosporins so the typical neutropenic fever coverage with an antipseudomonal cephalosporin and azithromycin might not be effective. Given the increasing recognition of this zoonosis as a threat to the immunocompromised, it is essential to educate immunocompromised patients to minimize zoonotic exposure, as immunization of pets might not confer protection to humans.

1. Introduction

Bordetella bronchiseptica is a pleomorphic gram-negative coccobacillus that commonly causes respiratory tract infections in canines, felines, and swine. Human infections are occasionally reported in immunocompromised patients [1–4]. We report a case of *Bordetella bronchiseptica* pneumonia in a stem cell transplant patient.

* Corresponding author. Medical College of Wisconsin, 8701 W Watertown Plank Road, Milwaukee, WI, 53226, USA.
E-mail address: hasingh@mcw.edu (H. Singh).

<https://doi.org/10.1016/j.rmcr.2022.101672>

Received 22 October 2021; Received in revised form 10 February 2022; Accepted 17 May 2022

Available online 25 May 2022

2213-0071/© 2022 The Authors. Published by Elsevier Ltd. This is an open access article under the CC BY-NC-ND license (<http://creativecommons.org/licenses/by-nc-nd/4.0/>).

2. Case narration

A 67-year-old man with multiple myeloma treated with autologous bone marrow transplant followed by a chimeric antigen receptor cell therapy (CAR-T) for relapse was admitted to the hospital with unremitting diarrhea due to HHV-6 pancolitis. Because of the gravity of the infection, he underwent reversal of CAR-T with rituximab. Two days later, the patient developed a fever up to 102.3°F, a productive cough, and worsening hypoxia. Chest computed tomography demonstrated bilateral patchy infiltrates most pronounced at lung bases, tree-in-bud opacities, bronchial wall thickening, and worsening mediastinal lymphadenopathy (Fig. 1A&B). In the background of severely compromised immune status of the patient, a broad range of differential diagnosis were considered including but not limited to viral, bacterial, fungal, and mycobacterial infections and a bronchoscopy with bronchoalveolar lavage (BAL) was performed. BAL cultures grew beta lactamase positive bordetella bronchiseptica (>100,000 colony forming units/ml) which was sensitive to piperacillin/tazobactam, but resistant to cefepime and ceftazidime. He was treated with piperacillin/tazobactam both empirically as well as upon review of final BAL culture data, but over the next week his respiratory status worsened necessitating invasive mechanical ventilation. He developed progressive multiorgan failure, transitioned to comfort care, and expired in the hospital.

3. Discussion

It is well known that certain organisms that do not cause serious infection in immunocompetent persons, can sometimes cause serious illness in immunocompromised populations. *Bordetella bronchiseptica* is one such agent; an aerobic coccobacillus known best as a commensal microbe of the mammalian upper respiratory tract of cats, dogs, and pigs [1]. It is one of many respiratory pathogens that cause “kennel cough” in dogs and atrophic rhinitis in swine. Spread by respiratory droplets, human disease is rare despite frequent domestic exposure. However, the number of cases is slowly growing in the immunocompromised population and can cause a wide range of symptoms from asymptomatic infection to severe pulmonary disease. Transmission through animal contact is becoming increasingly common. Dogs and cats are not uniformly vaccinated against this pathogen as it is most often encountered in day-care/kennel settings where it can cause an outbreak as it is highly contagious. Exposure to the family pet even if not participating in group activities such as day care can lead to zoonotic transmission highlighting the need to counsel the immunocompromised patients on how to minimize their risk [1,2,5–7].

A literature review reveals that the majority of people infected with *B. bronchiseptica* have either a history of cancer (such as leukemia or lung cancer), structural lung disease (including cystic fibrosis and emphysema), AIDS, or immunosuppressive states such as after hematopoietic stem cell transplantation (HSCT) or solid organ transplantation [1,8]. Our case of fatal infection in a HSCT patient study contributes to the existing literature.

The patient developed high grade fevers and severe hypoxia and bilobar pneumonia. Affected patients can have features ranging from mild sinusitis or bronchitis to severe pneumonias. Paroxysmal “whooping” cough similar to pertussis is also seen in some cases, therefore, *B. bronchiseptica* can be suspected in immunocompromised patients with this cough, especially when there is a history of zoonotic exposure [8]. *B. bronchiseptica* is also known to cause meningitis in immunocompromised patients [9].

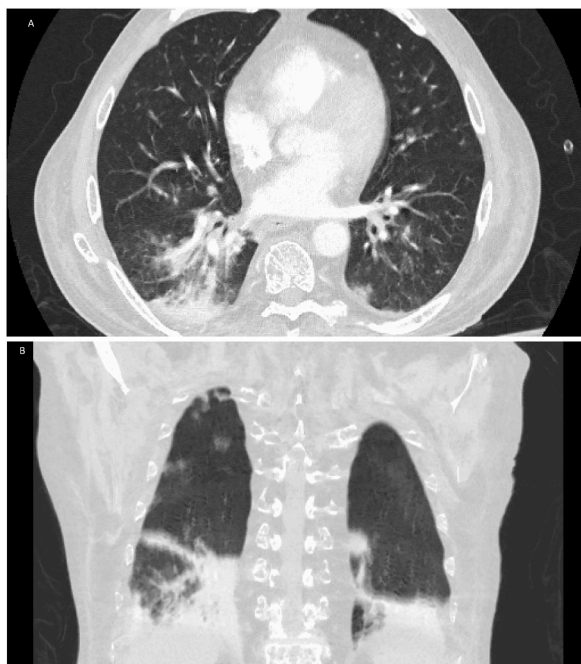


Fig. 1. A&B: Chest computed tomography axial and coronal views with bilateral patchy infiltrates, tree-in-bud opacities, and bronchial wall thickening.

In our patient, radiographic findings included bilateral nodular opacities and bronchial thickening which is not uncommon. His progression to respiratory failure was due in large part to profound mucus plugging. Imaging results can be varied and include multifocal, lower lobe predominant consolidation and atelectasis, interstitial pneumonia, cavitary airspace disease, nodules, and mosaic attenuation [6,8].

In terms of treatment, the lack of established treatment guidelines in humans requires dependence on susceptibility testing. Isolates are generally susceptible to anti-pseudomonal penicillins, carbapenems, fluoroquinolones and aminoglycosides. Realize that unlike other *Bordetella* spp, this pathogen is not typically responsive to erythromycin and is often resistant to ampicillin and cephalosporins so may break through typical neutropenic fever coverage [4] (an antipseudomonal cephalosporin and azithromycin). Duration of therapy can range from two weeks to several months depending on the degree of immunocompromise and is generally guided by the resolution of radiological abnormalities [1,5,8]. Most patients eventually recover appropriately, however there have been few reported deaths from sepsis [3]. In pets, *bordetella bronchiseptica* presentation varies significantly from asymptomatic to mild upper-respiratory signs to severe bronchopneumonia. Educating immunocompromised individuals regarding symptoms in pets such as cough, fever, mucopurulent nasal discharge, lethargy, decreased appetite may provide only limited protection because commonly the pets shed the organisms for a month and occasionally up to 3 months [10]. Minimizing the overall zoonotic exposure might be more effective. Risks are higher if pet is enrolled in daycare/kennel. Immunization of the pets should be discussed to minimize the risk of pneumonia in immunocompromised patients.[11] Vaccination can be given twice a year but is required at-least once a year.

4. Conclusion

Bordetella bronchiseptica is a rare zoonotic infection that should not be overlooked in immunocompromised patients presenting with respiratory symptoms and a history of exposure to animals. While most patients recover with treatment, some require ventilatory support and prolonged antibiotics. As our patient a rare few have died from the infection. The pathogen is easily identifiable on sputum culture as well as BAL. Given the increasing recognition of this zoonosis as a threat to the immunocompromised, it is essential to educate immunocompromised patients to minimize zoonotic exposure, as immunization of pets might not confer protection to humans.

Disclosures statement

The authors report no disclosures.

Conflicts of interest

The authors report no conflicts of interest.

Acknowledgment

Each of the authors significantly contributed to this manuscript.

References

- [1] A.T. Yacoub, M. Katayama, J. Tran, R. Zadikany, M. Kandula, J. Greene, *Bordetella bronchiseptica* in the immunosuppressed population - a case series and review, *Mediterr. J. Hematol. Infect. Dis.* 6 (1) (2014 Apr 7), e2014031, <https://doi.org/10.4084/MJHID.2014.031>. PMID: 24804004; PMCID: PMC4010603.
- [2] E.S. Huebner, B. Christman, S. Dummer, Y.W. Tang, S. Goodman, Hospital-acquired *Bordetella bronchiseptica* infection following hematopoietic stem cell transplantation, *J. Clin. Microbiol.* 44 (7) (2006 Jul) 2581–2583, <https://doi.org/10.1128/JCM.00510-06>. PMID: 16825386; PMCID: PMC1489478.
- [3] R.J.I.R. Baptista, J.M.S.S.D. Costa, R.A. Badura, Severe cavitary pneumonia caused by *Bordetella bronchiseptica* in an HIV-infected patient, English, Spanish, *Enferm. Infecc. Microbiol. Clín.* 38 (8) (2020 Oct) 404–405, <https://doi.org/10.1016/j.eimc.2020.02.014>. Epub 2020 Mar 17. PMID: 32192778.
- [4] M. Ducours, P. Rispal, M.P. Danjean, Y. Imbert, E. Dupont, E.M. Traissac, S. Grosleron, *Bordetella bronchiseptica* infection, *Med. Maladies Infect.* 47 (7) (2017 Nov) 453–458, <https://doi.org/10.1016/j.medmal.2017.05.012>. Epub 2017 Sep 22. PMID: 28943167.
- [5] D. Wernli, S. Emonet, J. Schrenzel, S. Harbarth, Evaluation of eight cases of confirmed *Bordetella bronchiseptica* infection and colonization over a 15-year period, *Clin. Microbiol. Infect.* 17 (2) (2011 Feb) 201–203, <https://doi.org/10.1111/j.1469-0691.2010.03258.x>. PMID: 20459438.
- [6] D.M. Berkowitz, R.I. Bechara, L.L. Wolfenden, An unusual cause of cough and dyspnea in an immunocompromised patient, *Chest* 131 (5) (2007 May) 1599–1602, <https://doi.org/10.1378/chest.06-1541>. PMID: 17494814.
- [7] J.J. Gisel, L.M. Brumble, M.M. Johnson, *Bordetella bronchiseptica* pneumonia in a kidney-pancreas transplant patient after exposure to recently vaccinated dogs, *Transpl. Infect. Dis.* 12 (1) (2010 Feb) 73–76, <https://doi.org/10.1111/j.1399-3062.2009.00451.x>. Epub 2009 Oct 28. PMID: 19874567.
- [8] A.K. Patel, J.A. Prescott-Focht, J.R. Kunin, C.E. Essmyer, M.L. Rosado-de-Christenson, Imaging findings in human *Bordetella bronchiseptica* pneumonia, *J. Thorac. Imag.* 26 (4) (2011 Nov) W146–W149, <https://doi.org/10.1097/RTI.0b013e31820209a1>. PMID: 21263355.
- [9] C. Radcliffe, A. Lier, N. Doilicho, S. Parikh, F. Kaddouh, *Bordetella bronchiseptica*: a rare cause of meningitis, *BMC Infect. Dis.* 20 (1) (2020 Dec 3) 922, <https://doi.org/10.1186/s12879-020-05668-2>. PMID: 33272197; PMCID: PMC7713019.
- [10] K.L. Reagan, J.E. Sykes, Canine infectious respiratory disease, *Vet. Clin. North Am. Small Anim. Pract.* 50 (2) (2020 Mar) 405–418, <https://doi.org/10.1016/j.cvs.2019.10.009>. Epub 2019 Dec 5. PMID: 31813556; PMCID: PMC7132485.
- [11] C.M. Matherne, E.K. Steffen, J.E. Wagner, Efficacy of commercial vaccines for protecting Guinea pigs against *Bordetella bronchiseptica* pneumonia, *Lab. Anim. Sci.* 37 (2) (1987 Apr) 191–194. PMID: 3599889.