

# Endoscopic ultrasound-guided drainage of difficult-to-access liver abscesses

SAGE Open Medicine

Volume 8: 1–6

© The Author(s) 2020

Article reuse guidelines:

[sagepub.com/journals-permissions](https://sagepub.com/journals-permissions)

DOI: 10.1177/2050312120921273

[journals.sagepub.com/home/smo](https://journals.sagepub.com/home/smo)Yung Ka Chin  and Ravishankar Asokkumar

## Abstract

**Objectives:** Antibiotic therapy and percutaneous drainage have been the first-line treatments for liver abscesses. However, percutaneous drainage of abscesses may be challenging in difficult-to-access locations such as the caudate lobe. The aim of this review was to determine the indications, technical feasibility and efficacy of endoscopic ultrasound-guided drainage of difficult-to-access liver abscesses.

**Methods:** A literature review of original articles, abstracts, case series and case reports describing endoscopic ultrasound-guided liver abscess drainage was performed. The indications, techniques and complications associated with endoscopic ultrasound-guided drainage were reviewed.

**Results:** A total of 15 studies were identified. The main indications were failed antibiotic therapy and difficulty in gaining percutaneous access. The technique involved identification and puncturing of an abscess under endoscopic ultrasound guidance followed by placement of a prosthesis via a guide wire. The technique was 97.5% successful with no major complications reported.

**Conclusion:** Endoscopic ultrasound-guided drainage was feasible and safe and allowed complete drainage of liver abscesses not accessible by percutaneous drainage.

## Keywords

Endoscopic ultrasound, liver abscess, drainage, complications

Date received: 3 October 2019; accepted: 2 April 2020

## Introduction

Liver abscesses are associated with significant morbidity and mortality if left untreated.<sup>1</sup> Current conventional treatment involves antibiotic therapy and, in the context of abscesses larger than 5 cm, additional percutaneous drainage (PD). It may be possible to treat smaller abscesses with antibiotic therapy alone, but additional percutaneous aspiration or drainage may frequently still be required. Surgical drainage is associated with significant morbidity and mortality (32%).<sup>2–4</sup> Surgical drainage is usually performed as a second-line treatment option when PD is either not feasible or unsuccessful. The reported success rates with PD range from 85% to 100%.<sup>5,6</sup> Despite high success rates, PD can also be associated with procedure-related complications such as bleeding, perforation, peritonitis, fistula, sepsis and tube-related discomfort. Moreover, PD of abscesses in the caudate and left lobe of the liver can be technically challenging. Endoscopic ultrasound (EUS)-guided drainage of subphrenic, pancreatic and pelvic abscesses has been described as an alternative to surgery and PD.<sup>7–9</sup> The close proximity of

the left lobe and central segments of the liver to the stomach makes EUS-guided drainage an attractive and feasible option. With advancements in EUS techniques and accessories, EUS-guided drainage of inaccessible collections can be a standard of care in the future. In this review, we discussed the indications, techniques, endoprotheses, and complications associated with EUS-guided drainage of liver abscesses.

## Materials and methods

A PubMed search was performed to identify relevant articles on EUS-guided drainage of liver abscesses. The search terms

Department of Gastroenterology and Hepatology, Academia, Singapore General Hospital, Singapore

### Corresponding author:

Yung Ka Chin, Department of Gastroenterology and Hepatology, Academia, Singapore General Hospital, Level 3, 20 College Road, Singapore 169856.

Emails: [yungka@gmail.com](mailto:yungka@gmail.com); [chin.yung.ka@singhealth.com.sg](mailto:chin.yung.ka@singhealth.com.sg)



**Table 1.** Summary of the studies included.

Author	Abscess (n)	Location (n)	Approach	Technical success (%)	Clinical success (%)	Complications
Seewald et al. <sup>11</sup> (2005)	1	Left lobe	TG	100	100	Nil
Ang et al. <sup>12</sup> (2009)	1	Left lobe	TG	100	100	Nil
Noh et al. <sup>13</sup> (2010)	3	Gastro hepatic space (1) Caudate lobe (2)	TG (2) TD (1)	100	100	Nil
Itoi et al. <sup>14</sup> (2011)	2	Caudate lobe (1) Left lobe (1)	TD TG	100	100	Nil
Keohane et al. <sup>15</sup> (2011)	2	Caudate lobe (2)	TG	100	100	Nil
Ivanina et al. <sup>16</sup> (2012)	1	Caudate lobe	TG	100	100	Nil
Medrado et al. <sup>17</sup> (2013)	1	Left lobe	TG	100	100	Stent migration
Alcaide et al. <sup>18</sup> (2013)	1	Left lobe	TG	100	100	Nil
Kawakami et al. <sup>19</sup> (2014)	1	Left lobe	TG	100	100	Nil
Koizumi et al. <sup>20</sup> (2014)	1	Left lobe	TG	100	100	Nil
Kodama et al. <sup>21</sup> (2015)	1	Left lobe	TG	100	100	Dislodgement of naso-cystic catheter. Resolution with FCSEMS
Ogura et al. <sup>22</sup> (2016)	8	Left lobe (6) Right lobe (2)	TG (6) TD (2)	100	100	Nil
Tonozuka et al. <sup>23</sup> (2015)	7	Left lobe (6) Right lobe (1)	TG (6) TD (1)	100	71.4	Spontaneous stent dislodgement
Yamamoto et al. <sup>24</sup> (2017)	1	Right lobe	TD	100	100	Nil
Carbajo Lopez et al. <sup>25</sup> (2019)	9	Left lobe (3) Right lobe (6)	TG (3) TD (6)	88.9	88.9	GI bleeding Perforation

TG: trans-gastric; TD: trans-duodenal; FCSEMS: fully covered self-expanding metal stent; GI: gastrointestinal.

used were “EUS,” “endosonography” or “EUS-guided,” and “liver abscess” or “liver abscesses.” Only English language articles were included. The abstracts of the proceedings of two major international meetings (Digestive Disease Week (DDW) and United European Gastroenterology (UEG) Week) were also reviewed. The timeline of the literature search was from January 2005 (the first case report of this technique was published in 2005) to June 2019. The references of the papers were reviewed for additional relevant articles. The indications, techniques, accessories, prosthesis, success rate and complications were analyzed. The evidence from these articles was graded according to the Grading of Recommendations Assessment Development and Evaluation (GRADE) system.<sup>10</sup>

## Results

We identified 15 relevant articles describing EUS-guided drainage of liver abscesses. These included 12 case reports and 3 retrospective studies (Table 1).<sup>11–25</sup> Only original reports were used for analysis. The full article was accessible for all studies except for one case report that was in abstract form. According to the GRADE recommendations, the quality of the available evidence was low, as the evidence was from uncontrolled studies and case reports (Table 2). However, the results from these studies could have an important impact because patients with abscesses inaccessible to PD have limited treatment options. In total,

**Table 2.** Grading of recommendation.

Category of evidence	Studies
I	0
II-1	0
II-2	3
II-3	12
III	0
Grading of evidence	C (low quality)
Strength of recommendation	Strong recommendation

39 patients with 40 liver abscesses resulting from a variety of causes underwent EUS-guided abscess drainage. The information on patient demographics, indication for drainage, technique, type of accessories used, prosthesis used, success rate and complication rate are summarized in Tables 3 and 4.

## Indication

The most common indication for EUS-guided drainage of liver abscesses was failed medical therapy and the inability to drain the abscess percutaneously (93%). The mean size of the abscess in the reported studies was  $7.7 \pm 2.7$  cm (2.5–11). The most common etiology was pyogenic liver abscess (95%), while two patients had tubercular and amoebic liver abscesses, one of whom required two

**Table 3.** Patient characteristics.

Characteristics	Patients (n = 39)
Age (mean)	64.2 ± 16.3 (range, 31–94)
Location of the abscess	
Left lobe	75% (n = 30)
Right lobe	25% (n = 10)
Etiology	
Pyogenic abscess	95% (n = 37)
Tubercular abscess	2.5% (n = 1)
Amoebic abscess	2.5% (n = 1)
Size of the abscess (mean)	7.7 ± 2.7 cm (range, 2.5–11)
Indication	
Failed antibiotic treatment (or) inaccessible by PD drainage	66.7% (n = 26)
Primary EUS-guided drainage	33.3% (n = 13)

PD: percutaneous drainage; EUS: endoscopic ultrasound.

**Table 4.** Summary of intervention and outcome.

Intervention	Liver abscess (n = 40)
Drainage approach	
Trans-gastric	72.5% (n = 29)
Trans-duodenal	27.5% (n = 11)
Drainage prosthesis	
Naso-cystic catheter	12.5% (n = 5)
Straight stent	2.5% (n = 1)
Double pigtail stent	12.5% (n = 5)
Double pigtail stent + naso-cystic catheter	7.5% (n = 3)
FCSEMS alone	2.5% (n = 1)
FCSEMS + naso-cystic catheter	17.5% (n = 7)
FCSEMS + double pigtail stent	37.5% (n = 15)
LAMS + double pigtail stent	7.5% (n = 3)
Technical success	97.5%
Clinical success	95.0%
Complication	
Stent migration	5% (n = 2)

FCSEMS: fully covered self-expanding metal stent; LAMS: lumen-apposing metal stent.

drainage procedures.<sup>11–25</sup> In most reports, the abscess was located in the left lobe of the liver (75%). Ang reported EUS-guided drainage of a ruptured liver abscess in a patient with high surgical risk.<sup>12</sup> Keohane reported EUS-guided drainage of a liver abscess in a patient with septic shock requiring intensive care treatment.<sup>15</sup> Two discrete tubercular abscesses located in the caudate lobe and between the left lobe of the liver and pancreas were successfully drained by Itoi.<sup>14</sup> Although accessing the right lobe using EUS can be challenging, Ogura, Tonozuka, Yamamoto and Carbajo reported 10 patients in whom a pyogenic abscess located in the right liver lobe was drained successfully.<sup>22–25</sup>

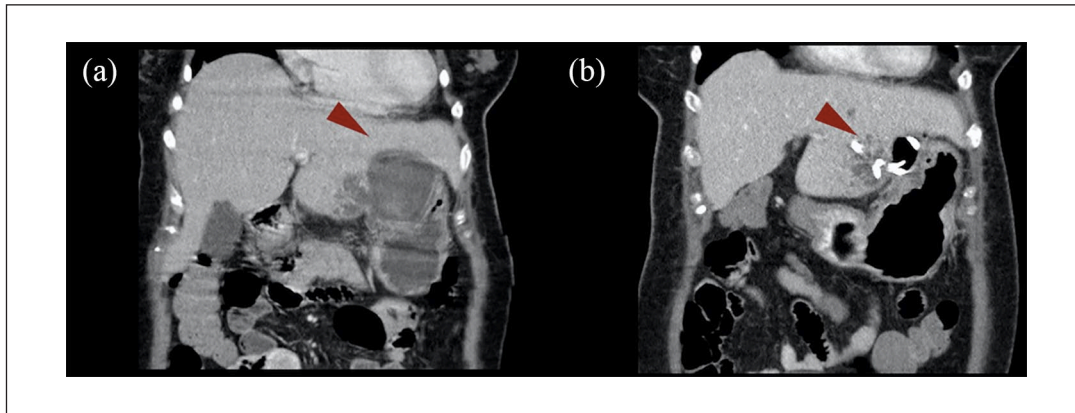
### EUS-guided drainage technique

The abscess collection site was preidentified by cross-sectional imaging, such as computer tomography. The liver abscess was localized using a linear echoendoscope. Both a diagnostic echoendoscope with a 2.8-mm working channel and a therapeutic echoendoscope with a larger working channel of 3.7–3.8 mm were used. The former allows for insertion of only 7-Fr stents, whereas larger 10-Fr stents can be inserted with a therapeutic echoendoscope. The type of approach was decided by the proximity of the abscess to the luminal wall and the presence of intervening vascular structures as determined by color Doppler ultrasonography. The trans-gastric approach was preferred for abscesses located in the left lobe of the liver (72.5%), and the trans-duodenal approach was preferred for right lobe abscesses (27.5%).<sup>11–25</sup> Ten patients with right lobe abscesses were drained via a trans-duodenal approach.<sup>13,14,22,23</sup>

The first reported case by Seewald used a 22-gauge (G) needle with a 6-Fr Teflon outer sheath for the puncture, after which the needle was withdrawn and a guidewire was inserted through the Teflon sheath.<sup>11</sup> In other cases, the abscess cavity was punctured using a 19G EUS-fine needle aspiration (FNA) needle. Upon gaining access to the abscess cavity, the stylet of the FNA needle was removed, and a 0.035- or 0.025-inch guidewire was advanced into and coiled inside the abscess cavity under fluoroscopic guidance (Figure 1). A minimum of two loops inside the abscess cavity was recommended to maintain stability of the guidewire and allow safe deployment of the endoprosthesis. If dilatation of the tract prior to stent insertion was needed, it was achieved by using a coaxial biliary dilator (6–10 Fr) or a balloon dilator (6–8 mm) either alone or in combination. The prosthesis was then placed to drain the abscess into the stomach or duodenum.

### Prosthesis and accessories

Once a tract has been established, either a stent or a naso-cystic drainage catheter can be considered for drainage of the abscess cavity. The pigtail plastic stent and fully covered self-expanding metal stents (FCSEMSs) were the drainage systems used by most endoscopists. Concomitant use of a naso-cystic drainage catheter allowed irrigation of the abscess cavity to improve drainage. The first reported case by Seewald et al. used a 7-Fr naso-cystic catheter.<sup>11</sup> Multiple double pigtail stents were used for drainage of larger abscesses. Ang used 8- and 10-Fr double pigtail stents to drain a large ruptured hepatic abscess (10.7 × 5.7 cm).<sup>12</sup> The location of the abscess and the type of approach can make stent deployment challenging. Itoi et al. used a 7-Fr straight stent because the abscess drainage was approached from the duodenal bulb.<sup>14</sup> Double pigtail stents were preferred over straight stents because of the lower risk of migration. Recent publications have reported the insertion of FCSEMSs under



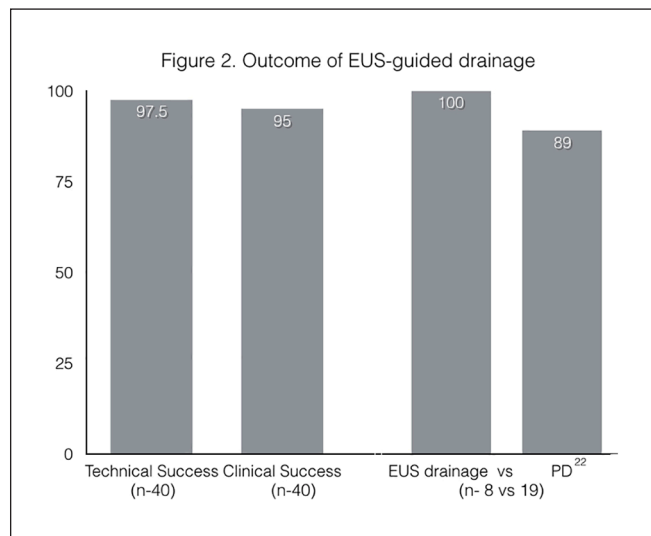
**Figure 1.** Describes the drainage of a left lobe liver abscess. (a) A large abscess is seen in the left lobe of the liver in close proximity to the gastric wall. (b) EUS-guided drainage of the abscess into the stomach as demonstrated by placement of cysto-gastric stent resulted in resolution of the abscess.

EUS guidance for drainage.<sup>17–25</sup> The use of FCSEMSs has several theoretical advantages when compared to plastic stents: (1) the wider diameter of the metal stent allows rapid drainage, (2) the chance of pus leakage is minimized, (3) the ability to remove solid necrotic debris is enhanced, and (4) the need for repeated procedures is decreased. These theoretical advantages over plastic stents remain unvalidated.

Medrado carried out trans-gastric drainage using a 10-mm partially covered self-expandable metal stent (SEMS).<sup>17</sup> Alcaide et al.<sup>18</sup> used 10-mm lumen-apposing metal stents (LAMSs) for drainage of a left lobe abscess. Kumta and Carbajo reported the use of electrocautery-enhanced LAMSs in the drainage of three liver abscesses with clinical success. Ogura et al.,<sup>22</sup> in their retrospective study involving 27 patients, compared PD and EUS drainage using FCSEMSs. They demonstrated a higher clinical success rate and significantly shorter hospital stay in the EUS drainage group. Similarly, Tonzuka et al.,<sup>23</sup> in their retrospective case series, showed successful drainage of seven liver abscesses using FCSEMSs. In one patient, the large diameter of the FCSEMS, compared to pigtail stents, permitted the surgeons to perform direct endoscopic necrosectomy to remove solid necrotic debris. Another retrospective study by Carbajo compared PD and EUS drainage and showed no significant difference in the technical or clinical success of either group. They reported their experience in the use of LAMSs.<sup>25</sup>

### Outcome and follow-up

There were no reports of difficulty with the drainage technique. Large abscesses and the presence of solid components may require additional endoscopic drainage. Tonzuka reported a clinical success rate of 71.4% at the first session. Two patients with large abscesses and solid components showed resolution after the second session. No major procedure complications were reported. All studies showed complete resolution of the abscess (Figure 2). Stents, when



**Figure 2.** The outcome of EUS-guided drainage and comparison with PD.

needed, were removed without any difficulty after abscess resolution. In the report by Medrado, where a 10-mm partially covered biliary SEMS was used for trans-gastric drainage, intra-abscess stent migration was noted at 2 weeks. A 10-Fr double pigtail stent was inserted inside the SEMS to maintain the drainage channel, and there was full clinical resolution by 8 weeks.<sup>17</sup> Tonzuka et al.<sup>23</sup> reported spontaneous dislodgement of FCSEMSs into the digestive tract without any adverse events. The limitation with FCSEMSs is the risk of stent migration. However, the use of the new LAMSs with their anti-migratory systems, as demonstrated by Alcaide et al.,<sup>18</sup> Kawakami et al.<sup>19</sup> and Carbajo et al.,<sup>25</sup> can decrease the risk of stent displacement. Carbajo et al.<sup>25</sup> reported three cases of gastrointestinal bleeding that were managed conservatively and one perforation that was closed during the procedure.



## Discussion

There is no doubt that PD is the standard of care, with its excellent safety profile and high efficacy. However, there are situations where PD may not be technically feasible, and this is where an EUS-guided approach may have a role, as described by Yamamoto et al.<sup>24</sup> The limited published data seem promising.

The technique of EUS-guided liver abscess drainage derives from techniques used for EUS-guided pseudocyst drainage, where there are abundant data ascertaining their efficacy and safety.<sup>26</sup> There is a crucial difference that must be recognized. In the context of pseudocysts, the pseudocyst wall is adherent to the gastric or duodenal wall. In contrast, in the case of caudate or left/right lobe liver abscesses, the wall of the abscess cavity is nonadherent to the luminal wall. Thus, where feasible, there should be a rim of intervening liver parenchyma. It is probably safest to minimize the dilatation to avoid intraperitoneal spillage and to use noncautery-based techniques. Spillage may be reduced if the stent fits snugly or if customized LAMs are used. This concept is somewhat similar to that for EUS-guided transluminal drainage of the bile duct, where the bile duct is just adjacent but not adhered to the gastrointestinal wall.<sup>27</sup>

The advancement in therapeutic EUS has made surgical drainage of liver abscesses a less attractive option in cases that cannot be accessed percutaneously. The complications and morbidity are lower with an endoscopic approach than with a surgical approach. The major advantages of EUS-guided drainage include (1) clear visualization and localization of the abscess, (2) clear demarcation of the intervening structures and avoidance of inadvertent complications, and (3) direct passage of the needle into the cavity and avoidance of cutaneous infection and fistula formation. Although it appears promising, EUS-guided drainage has certain limitations. These include (1) difficulty in accessing the right lobe of the liver, (2) acute angulation in the duodenum limiting its maneuverability, and (3) the need for a high level of technical expertise and lack of routine availability. Despite the above limitations, a high success rate has been reported in the available studies.<sup>11–25</sup> Stent migration is another concern; thus, double pigtail stents are preferred over other stents because of the lower chance of migration. Ongoing advances in EUS and accessories have led to the development of SEMs with anti-migrating systems. Alcaide et al.,<sup>18</sup> Kawakami et al.<sup>19</sup> and Carbajo et al.<sup>25</sup> used a lumen-apposing fully covered self-expanding metal stent for drainage of a left lobe abscess. However, it is uncertain whether SEMs can be cost-effective, and studies are needed to establish the efficacy and superiority of SEMs over plastic stents. Currently, the decision regarding the type of approach and choice of prosthesis should be individualized based on the patient's condition and endoscopist's experience. The response to drainage should be assessed in terms of both clinical and radiological improvement. The decision to remove a stent should be guided by treatment response. The

time of prosthesis removal varied widely in the available reports but should be done after adequate antibiotic therapy and documented radiological resolution of the abscess.

The decision regarding the drainage approach for multiple or multiloculated abscesses should be individualized. Factors to be considered include the number, size and accessibility of the abscesses and the underlying comorbidities of the patient. Surgical drainage has been the conventional approach in these circumstances, but there was a retrospective study that described successful PD in the setting of multiple abscesses (22 of 24 patients) and multiloculated abscesses (51 of 54 patients).<sup>28</sup> In the current literature review, there was no report on EUS-guided drainage of multiple or multiloculated abscesses. However, a hybrid model of drainage, combining both PD and EUS-guided drainage, could be adopted if multiloculated abscesses involved both liver lobes to improve clinical outcome. The drainage approach should be individualized after considering the patient's condition and the availability of technical expertise.

The mainstay of management for an amoebic liver abscess is antibiotic therapy, which is effective in most cases. Drainage of an amoebic liver abscess is only indicated when there is no clinical improvement following antibiotic treatment and a high risk of abscess rupture.<sup>29</sup> Koizumi et al reported their experience in EUS-guided drainage of amoebic liver abscesses. They adopted a transhepatic approach through the stomach to avoid leakage of infected contents into the peritoneal cavity, which may result in catastrophic outcomes. The author concluded that EUS-guided drainage is an effective alternative to PD with some advantages, such as clear visualization, low risk of transcutaneous infection and the possibility of achieving direct access via a transluminal route without an external tube.<sup>20</sup>

## Conclusion

EUS has revolutionized the field of diagnostic and therapeutic endoscopy. EUS allows complete visualization of the left lobe and central segments of the liver. The available preliminary data suggest that EUS-guided drainage is safe and feasible. However, the use of EUS-guided drainage should be limited only to liquefied abscesses involving the left lobe or central segments of the liver not amenable to PD. We strongly believe that EUS-guided drainage, with its excellent safety profile, should be considered for abscesses inaccessible by PD before surgical drainage (*GRADE C, Strong recommendation*). In certain clinical situations, EUS-guided drainage can serve as a complementary technique to the PD approach. The decision regarding the type of approach and choice of prosthesis should be individualized based on the patient's condition and endoscopist's experience. Double pigtail plastic stents are preferred over straight stents. Theoretically, SEMs may hasten the recovery process by allowing faster drainage than other stents but would need to be LAMs to

reduce the risk of migration. The indication for EUS-guided drainage of liver abscess is failure of conservative treatment with antibiotics or the abscess not being amenable to PD. This procedure is contraindicated in patients who are unstable for endoscopy, including sedation, uncorrected coagulopathy and lack of technical expertise or support from other specialties, such as interventional radiologists and surgeons. In addition, the issue of relative cost-effectiveness must be addressed. Given that PD is the current cornerstone of treatment and the relatively low frequency of situations where PD is not possible, it is unlikely that any large randomized studies can be performed, and the decision must therefore be based on expertise and clinical judgment.

### Declaration of conflicting interests

The author(s) declared no potential conflicts of interest with respect to the research, authorship, and/or publication of this article.

### Funding

The author(s) received no financial support for the research, authorship, and/or publication of this article.

### ORCID iD

Yung Ka Chin  <https://orcid.org/0000-0002-0816-9375>

### References

- Malik AA, Bari SU, Rouf KA, et al. Pyogenic liver abscess: changing patterns in approach. *World J Gastrointest Surg* 2010; 272(12): 395–401.
- Bertel CK, Van Heerden JA, Sheedy PF, et al. Treatment of pyogenic hepatic abscesses surgical vs percutaneous drainage. *Arch Surg* 1986; 121: 554–558.
- Bergamini TM, Larson GM, Malangoni MA, et al. Liver abscess: review of a 12-year experience. *Arch Surg* 1986; 121(5): 596–599.
- Vogl TJ and Estifan F. Pyogenic liver abscess: interventional versus surgical therapy: technique, results and indications. *Rofo* 2001; 173(7): 663–667.
- Rajak CL, Gupta S, Jain S, et al. Percutaneous treatment of liver abscesses: needle aspiration versus catheter drainage. *AJR Am J Roentgenol* 1998; 170(4): 1035–1039.
- Zerem E and Hadzic A. Sonographically guided percutaneous catheter drainage versus needle aspiration in the management of pyogenic liver abscess. *AJR Am J Roentgenol* 2007; 189(3): W138–W142.
- Giovannini M, Bories E, Moutardier V, et al. Drainage of deep pelvic abscesses using therapeutic echo endoscopy. *Endoscopy* 2003; 35(6): 511–514.
- Giovannini M, Pesenti C, Roland AL, et al. Endoscopic ultrasound-guided drainage of pancreatic pseudocyst or pancreatic abscesses using a therapeutic echo endoscope. *Endoscopy* 2001; 33(6): 473–477.
- Seewald S, Brand B, Omar S, et al. EUS guided drainage of subphrenic abscess. *Gastrointest Endosc* 2004; 59(4): 578–580.
- Guyatt GH, Oxman AD, Vist GE, et al. GRADE: an emerging consensus on rating quality of evidence and strength of recommendations. *BMJ* 2008; 336(7650): 924–926.
- Seewald S, Imazu H, Omar S, et al. EUS-guided drainage of hepatic abscess. *Gastrointest Endosc* 2005; 61(3): 495–498.
- Ang T, Seewald S, Teo E, et al. EUS-guided drainage of ruptured liver abscess. *Endoscopy* 2009; 41(Suppl. 2): E21–E22.
- Noh S, Park do H, Kim Y, et al. EUS-guided drainage of hepatic abscesses not accessible to percutaneous drainage(with Videos). *Gastrointest Endosc* 2010; 71(7): 1314–1319.
- Itoi T, Ang T, Seewald S, et al. Endoscopic ultrasonography-guided drainage for tuberculous liver abscess drainage. *Dig Endosc* 2011; 23(Suppl. 1): 158–161.
- Keohane J, Dimaio CJ, Schattner MA, et al. EUS guided drainage of caudate lobe liver abscess. *J Interv Gastroenterol* 2011; 1(3): 139–141.
- Ivanina E, Mayer I, Li J, et al. EUS-guided drainage of hepatic abscess. *Gastrointest Endosc* 2012; 75(4): AB114.
- Medrado BF, Carneiro FOAA, Vilaca TG, et al. EUS-guided drainage of giant liver abscess. *Endoscopy* 2013; 45(Suppl. 2): E331–E332.
- Alcaide N, Vargas-Garcia AL, Sancho del Val L, et al. EUS-guided drainage of liver abscess by using a lumen-apposing metal stent. *Gastrointest Endosc* 2013; 78(6): 941–942.
- Kawakami H, Kawakubo K, Kuwatani M, et al. Endoscopic ultrasonography-guided liver abscess drainage using a dedicated, wide, fully covered self-expandable metallic stent with flared-ends. *Endoscopy* 2014; 46(Suppl. 1 UCTN): E982–E993.
- Koizumi K, Masuda S, Uojima H, et al. Endoscopic ultrasound-guided drainage of an amoebic liver abscess extending into the hepatic subcapsular space. *Clin J Gastroenterol* 2015; 8(4): 232–235.
- Kodama R, Saegusa H, Ushimaru H, et al. Endoscopic ultrasonography-guided drainage of infected intracystic papillary adenocarcinoma of the liver. *Clin J Gastroenterol* 2015; 8(5): 335–339.
- Ogura T, Masuda D, Saori O, et al. Clinical outcome of endoscopic ultrasound-guided liver abscess drainage using self-expandable covered metallic stent (with Video). *Dig Dis Sci* 2016; 61(1): 303–308.
- Tonozuka R, Itoi T, Tsuchiya T, et al. EUS-guided drainage of hepatic abscess and infected biloma using short and long metal stents (with videos). *Gastrointest Endosc* 2015; 81(6): 1463–1469.
- Yamamoto K, Itoi T, Tsuchiya T, et al. EUS-guided drainage of hepatic abscess in the right side of the liver of a patient with Chilaiditi syndrome. *VideoGIE* 2017; 2: 299–300.
- Carbajo AY, Brunie Vegas FJ, Garcia-Alonso FJ, et al. Retrospective cohort study comparing endoscopic ultrasound-guided and percutaneous drainage of upper abdominal abscesses. *Dig Endosc* 2019; 31(4): 431–438.
- Kato S, Katanuma A, Maguchi H, et al. Efficacy, safety, and long-term follow-up results of EUS-guided transmural drainage for pancreatic pseudocyst. *Diagn Ther Endosc* 2013; 2013: 924291.
- Ogura T, Sano T, Onda S, et al. Endoscopic ultrasound-guided biliary drainage for right hepatic bile duct obstruction: novel technical tips. *Endoscopy* 2015; 47(1): 72–75.
- Liu CH, Gervais DA, Hahn PF, et al. Percutaneous hepatic abscess drainage: do multiple abscesses or multiloculated abscesses preclude drainage or affect outcome? *J Vasc Interv Radiol* 2009; 208: 1059–1065.
- Petri WA Jr and Singh U. Diagnosis and management of amebiasis. *Clin Infect Dis* 1999; 29: 1117–1125.