

Received: 2018.08.14
Accepted: 2018.11.15
Published: 2019.02.07

Chimney-Patch Arterial Graft in Kidney or Pancreas Transplantation for Recipients with Heavily Calcified Iliac Arteries

Authors' Contribution:
Study Design A
Data Collection B
Statistical Analysis C
Data Interpretation D
Manuscript Preparation E
Literature Search F
Funds Collection G

AE 1 **Nosratollah Nezakatgoo**
BE 2 **Leah E. Hendrick**
DE 3 **Charles L. Mesh**
ACE 4 **Jason M. Vanatta**
ABCDEF 1 **Ryan A. Helmick**

1 Department of Transplant, University of Tennessee Health Science Center, Methodist University Hospital Transplant Institute, Memphis, TN, U.S.A.
2 Department of Surgery, University of Tennessee Health Science Center, Memphis, TN, U.S.A.
3 Department of Surgery, Rush University, Chicago, IL, USA
4 Transplant Center, Cleveland Clinic Florida, Weston, FL, U.S.A.

Corresponding Author:
Source of support:

This work was presented as a rapid-paced oral presentation at the 41st Annual Meeting of the Midwestern Vascular Surgical Society. Presented September 8th, 2017 in Chicago, Illinois

Ryan A. Helmick, e-mail: ryan.helmick.md@gmail.com, rhelmick@uthsc.edu
Departmental sources

Iliac artery calcification is a common phenomenon complicating renal transplantation, particularly in those with diabetes. The potential for vascular clamp injury can threaten the renal allograft, ipsilateral lower extremity, or both.

Utilization of internal balloon occlusion can allow for placement of a "Chimney Patch" graft, fashioned from a deceased donor artery, to the calcified vessel, eliminating the risk of clamp injury and minimizing warm ischemic time.

We present a series of 6 patients transplanted with internal balloon occlusion with successful renal and pancreatic allograft function and no ipsilateral vascular complications.

Internal balloon occlusion is a safe and effective adjunct for renal or pancreas transplant to prevent clamp injury with no adverse effect on allograft function.

MeSH Keywords: **Balloon Occlusion • Kidney Transplantation • Plaque, Atherosclerotic • Vascular System Injuries**

Full-text PDF: <https://www.annalsoftransplantation.com/abstract/index/idArt/912744>



Background

Cardiovascular complications account for up to 50% of mortality in patients with end-stage renal disease (ESRD) who are on dialysis [1]. Patients with concomitant diabetes and ESRD are at particularly high risk, with mortality rates as high as 19.9 per 100 patient-years [2]. Conversely, these patients realize the most benefit from renal transplantation as measured by post-transplant life-years, regardless of age group.

Secondary hyperparathyroidism in renal failure patients further exacerbates vascular dysfunction, and elevations in parathormone (PTH) are linked to increased rates of vascular calcification [3,4]. Moderate to severe iliac artery calcification, determined by plain x-ray screening and CT angiography, is associated with increased rates of limb ischemia, early allograft loss, and death [5].

A significant morbidity concern is the potential for vascular clamp injury to heavily calcified recipient arteries. These injuries are related in most situations to plaque disruption and have been reported in both transplant and non-transplant cases [6,7]. Alternate vascular control techniques such as the use of pneumatic tourniquets for heavily calcified extremity arteries have been described for dialysis access surgery and lower-extremity re-vascularization [8,9]. Unfortunately, these techniques are not applicable to the control of pelvic vessels.

Although pre-operative diagnostic studies can optimize clamp placement [10], underestimation of arterial calcification may require alternate methods of vascular control. In such cases intraluminal balloon inflation may be helpful. Other authors have utilized this technique but utilizing artificial conduit, raising concerns for potential infectious complications [11]. Fashioning a technically perfect transplant arterial anastomosis may be difficult, add warm ischemia time and increase the risk of delayed graft function. We describe a technique to mitigate these issues by placement of double balloon occlusion catheters through a Carrel aortic patch to allow unhurried creation of an arterial conduit and subsequent simplified conduit anastomosis to the transplant inflow artery.

Material and Methods

Creation of the “Chimney Patch”

The aortic patch is trimmed leaving 2–2.5 mm of aortic tissue circumferentially around the renal artery ostium. The Carrel aortic patch is then divided from the renal allograft by cutting the renal artery obliquely 1–1.5 cm from the aorta. For the pancreas allograft and live donor kidney recipient, deceased donor common iliac artery is used as an interposition graft.

Patients

All patients underwent multidisciplinary transplant team evaluation and listing at the University of Tennessee Methodist Transplant Institute, and procedures were performed over a six-year timeframe. CT imaging of pelvic vasculature demonstrating severe degrees of calcification was used to guide clamp placement, and all patients had evidence on CT of atherosclerotic plaque to varying degrees. All patients were hypertensive. Retrospective chart review documented years on dialysis, presence of co-morbid conditions, pre-operative claudication, and post-operative vascular complications.

Case 1

This patient underwent chimney-patch technique for deceased donor kidney transplant using the aortic patch to the right external iliac artery (EIA), with no associated graft stenosis or complication. The patient underwent angiogram and stenting of the left superficial femoral and popliteal arteries 5.5 years after renal transplant.

Case 2

This patient underwent chimney-patch technique for deceased donor kidney transplant using the aortic patch to the right EIA, with no associated graft stenosis or complication. The patient underwent angiogram and atherectomy with angioplasty of the left superficial femoral artery 4.8 years after renal transplant.

Case 3

This patient underwent chimney-patch technique for deceased donor kidney transplant using the aortic patch to the right common iliac artery. There was no post-transplant stenosis or vascular complication.

Case 4

This patient underwent chimney-patch technique for living donor kidney transplant using deceased donor iliac artery graft anastomosed to the right EIA. There was no post-transplant stenosis or vascular complication.

Case 5

This patient underwent chimney-patch technique as part of a simultaneous pancreas-kidney (SPK) transplant. The chimney patch was created using a deceased donor iliac artery graft to the right EIA and used for implantation of the pancreas allograft. The patient was a Jehovah's witness and suffered from late bleeding 5 days after transplant at the drain site. He was observed expectantly without re-operation or

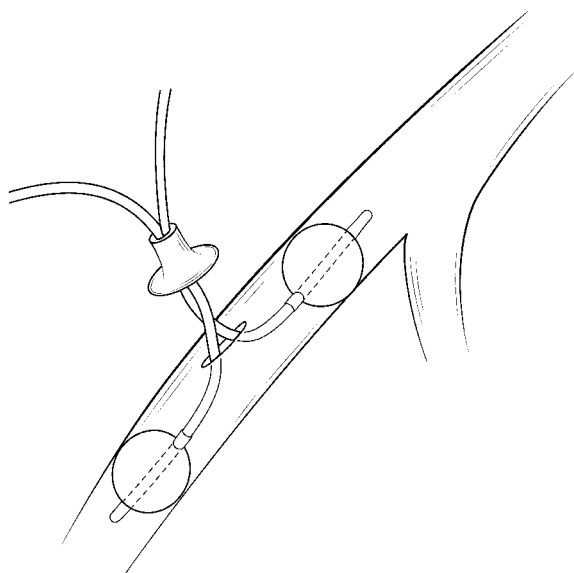


Figure 1. Diagram of “Chimney Patch” technique. The arterial patch is placed over 2 Fogarty catheters, which are inserted in an arteriotomy in the external iliac artery utilizing proximal and distal internal Fogarty balloon occlusion.

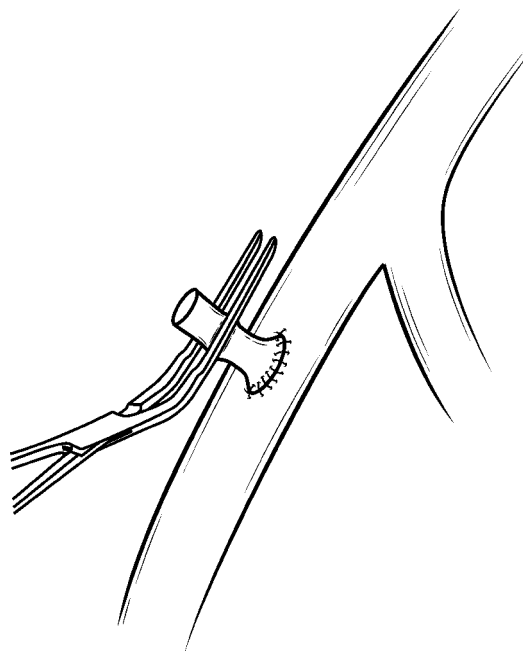


Figure 2. Placement of chimney patch with anastomosis completed and Fogarty catheters removed. The chimney patch is then occluded with a DeBakey clamp.

transfusion. There were no post-transplant stenoses or vascular complications.

Case 6

This patient underwent chimney-patch technique for a deceased donor kidney transplant using the aortic patch to the right EIA. The patient had early bleeding and was taken back to surgery on post-operative day 1 for control of bleeding and washout. There was no bleeding from either of the anastomoses involved in the chimney-patch technique. There were no post-transplant stenoses or vascular complications.

Recipient procedures

A right lower quadrant Gibson type incision was used for kidney transplantation, while the SPK recipient received a midline incision. If calcification prevented safe iliac artery clamp application as determined by vessel palpation, we proceed with the “Chimney-Patch” technique. Two Fogarty catheters are placed through the “Chimney-Patch” graft, and an arteriotomy is created on the softest superficial segment of common or external iliac artery and #6 or #7 Fogarty catheters with 3-way stopcocks are then inserted into the vessel proximally and distally. Balloon inflation achieves internal occlusion, as visualized in Figure 1. A 4.0 mm aortic punch is used to enlarge the arteriotomy and the “Chimney-Patch” is then anastomosed to the calcified recipient vessel using 5-0 Prolene suture. With the

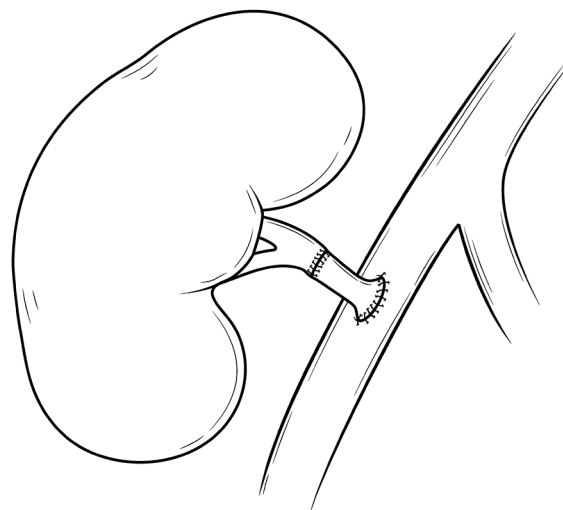


Figure 3. Completion of renal transplant end-to-end anastomosis between the renal artery and the chimney graft.

interposition graft in place, Fogarty catheters are removed and the “Chimney Patch” is clamped with a DeBakey or Satinsky clamp (Figure 2). Unhurried end-to-end anastomosis is then performed between the “Chimney-Patch” graft and the donor renal artery or pancreatic y-graft as appropriate (Figure 3). All procedures were performed by a single surgeon (NN). This study was approved by the University of Tennessee Health Science Center IRB.

Table 1. Characteristics of “Chimney Patch” recipients.

Case	Age	Sex	Race	DM	PTH	Dialysis modality	Years of dialysis	Claudication	Baseline Cr	1 week Cr	1 month Cr	1 year Cr	Last Cr	Years of follow-up
1	51	Female	White	Yes	498	PD	5	Yes	9.5	1.6	1.2	0.9	2.7	7.5
2	60	Male	Black	No	340	HD	15	No	10.6	1.8	2.3	1.7	3.56	8.5
3	57	Male	Black	No	335	HD	10	No	6.4	1.2	1.14	0.93	1.14	3.2
4	59	Male	White	Yes	618	HD	1.5	Yes	7.1	1.3	3.5	3.01	2.7	2.4
5	43	Male	Black	Yes	643	PD	2.2	No	7.9	1.8	1.55	1.7	1.6	2.8
6	63	Male	Black	Yes	233	HD	2.5	No	6.54	5.56	2.1	1.72	1.67	7.7

DM – diabetes, PTH – parathyroid hormone, PD – peritoneal dialysis, HD – hemodialysis, Cr – creatinine.

Results

Recipient pre-transplant characteristics are noted in Table 1. All recipients were hypertensive and on dialysis prior to transplant. Four of 6 had diabetes and one patient with type 1 diabetes mellitus received a simultaneous pancreas-kidney (SPK) transplant. Dialysis time ranged from 1.5 to 15 years, with a median of 3.75 years. Secondary hyperparathyroidism was uniformly present with a median intact (parathyroid hormone) PTH of 419 pg/mL and a range of 233 to 643 pg/mL.

Post-transplant outcomes are outlined in Table 1. All patients had functioning allografts after 1 year, and there were no vascular complications ipsilateral to the “Chimney Patch.” Median creatinine levels at 1 month and 1 year post-transplant were 1.83 mg/dL and 1.7 mg/dL respectively. Median creatinine was 2.19 at a median follow up period of 5.4 years. There were no vascular complications or interventions required on the side of chimney patch utilization. All patients remained off chronic hemodialysis after transplant.

Discussion

Kidney transplantation is a lifesaving operation for patients with ESRD, yet many of the co-morbid conditions that lead to renal failure contribute to progressive peripheral atherosclerosis. While patients with diabetes and peripheral vascular disease arguably derive the greatest survival benefit from transplant, they also pose the greatest technical challenges at operation and are at highest risk for graft loss [5,10]. Clamp injuries to atheromatous plaques can create flow limiting lesions to the ipsilateral lower extremity, the transplanted organ, or both. Pre-operative imaging may guide a surgeon to less calcified target vessels, or allow for either pre-transplant or combined transplant-donor vessel vascular reconstruction [10,12,13].

Many methods have been described to manage severe circumferential calcification at the site of proposed anastomosis [8,14]. Alexis Carrel initially utilized a wide based aortic patch for transplantation of the renal vessels to avoid thrombosis of the smaller renal vessels [15]. We have utilized the Carrel patch for a different purpose - to avoid intimal injury from external clamping. “Chimney-Patch” double-balloon occlusion of the iliac vessels is a safe and simple technical adjunct to avoid injury to circumferentially calcified vessels, and this technique has been utilized in both deceased and living donor kidney transplantation, as well as deceased donor pancreas transplantation. No patient suffered either ipsilateral claudication or required vascular intervention post-transplant. Furthermore, renal and pancreatic allograft outcome was excellent with no rejection and all grafts functioning after one year.

There are limitations to the applicability of the chimney-patch technique. First, suitable conduit must be available for use as a chimney patch; for deceased donor renal or pancreas transplantation there is always graft available whether from the aortic patch or deceased donor iliac vessel. However, in living donor renal transplant the availability of vessels may be limited. Dacron or PTFE could theoretically be used as suitable grafts though this may significantly increase the associated risks. Second, aneurysmal proximal vessels may prohibit adequate internal balloon occlusion.

Conclusions

Chimney-patch double-balloon occlusion remains a useful adjunct and should be considered for technically challenging transplant recipients.

Conflict of interest

None.

References:

1. Amann K, Tyralla K, Gross ML et al: Special characteristics of atherosclerosis in chronic renal failure. *Clin Nephrol*, 2003; 60(Suppl. 1): S13–21
2. Wolfe RA, Ashby VB, Milford EL et al: Comparison of mortality in all patients on dialysis, patients on dialysis awaiting transplantation, and recipients of a first cadaveric transplant. *N Engl J Med*, 1999; 341(23): 1725–30
3. Bortotolotto LA, Costa-Hong V, Jorgetti V et al: Vascular changes in chronic renal disease patients with secondary hyperparathyroidism. *J Nephrol*, 2007; 20(1): 66–72
4. Rocha-Singh KJ, Zeller T, Jaff MR: Peripheral arterial calcification: Prevalence, mechanism, detection, and clinical implications. *Catheter Cardiovasc Interv*, 2014; 83(6): E212–20
5. Brar A, Jindal RM, Elster EA et al: Effect of peripheral vascular disease on kidney allograft outcomes: A study of U.S. Renal data system. *Transplantation*, 2013; 95(6): 810–15
6. McBane RD, Gloviczki P, Wysokinski WE: Images in vascular medicine. Cross-clamp injury: An unusual cause of intermittent claudication. *Vasc Med Lond Engl*, 2006; 11(3): 173–74
7. Humar A, Grubbs B, Zapzalka D et al: Isolated iliac artery stenosis as a cause of kidney graft dysfunction post-transplant. *Clin Transplant*, 1998; 12(5): 406–8
8. Wagner WH, Treiman RL, Cossman DV et al: Tourniquet occlusion technique for tibial artery reconstruction. *J Vasc Surg*, 1993; 18(4): 637–45; discussion 645–47
9. Bourquelot P, Levy BI: Narrow elastic disposable tourniquet (Hemaclear®) vs. traditional wide pneumatic tourniquet for creation or revision of hemodialysis angioaccesses. *J Vasc Access*, 2016; 17(3): 205–9
10. Aitken E, Ramjug S, Buist L, Kingsmore D: The prognostic significance of iliac vessel calcification in renal transplantation. *Transplant Proc*, 2012; 44(10): 2925–31
11. Nanmoku K, Watarai Y, Narumi S et al: Surgical techniques and procedures for kidney transplant recipients with severe atherosclerosis. *Exp Clin Transplant*, 2017; 15(6): 594–601
12. Galazka Z, Grochowicki T, Jakimowicz T et al: Is severe atherosclerosis in the aortoiliac region a contraindication for kidney transplantation? *Transplant Proc*, 2011; 43(8): 2908–10
13. Pampaloni F, Sanchez LJ, Bencini L, Taddei G: Simultaneous aortoiliac reconstruction and renal transplantation: Is it safe? *Chir Ital*, 2002; 54(1): 115–20
14. White JV, Gass J: Preparation of the calcified tibial artery for bypass grafting. *Surg Gynecol Obstet*, 1990; 171(2): 165–66
15. Sade RM: Transplantation at 100 years: Alexis Carrel, pioneer surgeon. *Ann Thorac Surg*, 2005; 80(6): 2415–18