

ORIGINAL ARTICLE

Preoperative portal vein recanalization–transjugular intrahepatic portosystemic shunt for chronic obliterative portal vein thrombosis: Outcomes following liver transplantation

Abhinav Talwar¹ | Jeffrey Varghese¹ | Gabriel M. Knight¹ | Nitin Katariya² | Juan-Carlos Caicedo² | Zach Dietch² | Daniel Borja-Cacho² | Daniella Ladner²  | Derrick Christopher² | Talia Baker³ | Michael Abecassis⁴ | Samdeep Mouli¹ | Kush Desai¹ | Ahsun Riaz¹ | Bart Thornburg¹ | Riad Salem¹ 

¹Department of Radiology, Section of Vascular and Interventional Radiology, Northwestern University, Chicago, Illinois, USA

²Department of Surgery, Division of Transplant Surgery, Northwestern University, Chicago, Illinois, USA

³Department of Surgery, Division of Transplant Surgery, University of Chicago, Chicago, Illinois, USA

⁴Department of Surgery, Division of Transplant Surgery, University of Arizona, Tucson, Arizona, USA

Correspondence

Riad Salem, Department of Radiology, Section of Vascular and Interventional Radiology, Northwestern University, 676 North St. Clair, Suite 800, Chicago, IL 60611, USA.

Email: r-salem@northwestern.edu

Funding information

Supported by the National Institute of Diabetes and Digestive and Kidney Diseases (grant R01DK104876 to J.C.C.) and the National Cancer Institute (grant R01CA233878 to J.C.C.)

Abstract

High-grade portal vein thrombosis (PVT) is often considered to be a technically challenging scenario for liver transplantation (LT) and in some centers a relative contraindication. This study compares patients with chronic obliterative PVT who underwent portal vein recanalization–transjugular intrahepatic portosystemic shunt (PVR-TIPS) and subsequent LT to those with partial non-occlusive PVT who underwent LT without an intervention. This institutional review board-approved study analyzed 49 patients with cirrhosis with PVT from 2000 to 2020 at our institution. Patients were divided into two groups, those that received PVR-TIPS due to anticipated surgical challenges from chronic obliterative PVT and those who did not because of partial PVT. Demographic data and long-term outcomes were compared. A total of 35 patients received PVR-TIPS while 14 did not, with all receiving LT. Patients with PVR-TIPS had a higher Yerdel score and frequency of cavernoma than those that did not. PVR-TIPS was effective in decreasing portosystemic gradient (16 down to 8 mm HG; $p < 0.05$). Both groups allowed for end-to-end anastomoses in >90% of cases. However, veno–veno bypass was used significantly more in patients who did not receive PVR-TIPS. Additionally, patients without PVR-TIPS required significantly more intraoperative red blood cells. Overall survival was not different between groups. PVR-TIPS demonstrated efficacy in resolving PVT and allowed for end-to-end portal vein anastomoses. PVR-TIPS is a viable treatment option for chronic obliterative PVT with or without cavernoma that simplifies the surgical aspects of LT.

This is an open access article under the terms of the [Creative Commons Attribution-NonCommercial-NoDerivs](https://creativecommons.org/licenses/by-nc-nd/4.0/) License, which permits use and distribution in any medium, provided the original work is properly cited, the use is non-commercial and no modifications or adaptations are made.

© 2022 The Authors. *Hepatology Communications* published by Wiley Periodicals LLC on behalf of American Association for the Study of Liver Diseases.

INTRODUCTION

Portal vein thrombosis (PVT) is a well-described serious complication of cirrhosis that ultimately causes cessation of portal blood flow. The prevalence of PVT among patients with cirrhosis ranges from 4.4% to 15%.^[1] Acute symptomatic PVT most often presents as abdominal pain, intestinal ischemia, nausea, fever, and splenomegaly. Chronic PVT, by contrast, typically begins asymptotically due to hepatic arterial vasodilation and so-called venous rescue or the development of venous collaterals around the portal vein thrombus. Chronic PVT can slowly progress to ascites, variceal bleeding, hepatic encephalopathy, hepatopulmonary, and hepatorenal syndrome.

PVT is particularly important to diagnose in patients undergoing workup for liver transplantation (LT). Preoperative PVT documentation precludes the use of certain types of organs at the time of transplant, including marginal grafts and livers with more than 30% macrosteatosis.^[2,3] For patients proceeding with transplant, minimal PVT with luminal expansion can be resolved through standard operative techniques that restore physiologic flow into the liver (i.e., intraoperative mechanical thrombectomy with end-to-end anastomoses, interposition vein, or mesoportal jump grafts).

More severe cases of PVT necessitate using techniques that restore nonphysiologic inflow, including renoportal anastomoses, portal vein arterialization, and portacaval hemitransposition.^[4] Nonphysiologic methods, however, are associated with a higher incidence of adverse events, such as rethrombosis, gastrointestinal bleeding, and poor 5-year survival.^[4] Chronic high-grade PVT also predisposes patients receiving LT to increased operative time, higher transfusion requirements, and higher rates of reintervention.^[5–9] For these reasons, some transplant centers consider diffuse PVT with cavernomatous transformation to be a relative contraindication to LT.^[10]

More recently, portal vein recanalization (PVR)—transjugular intrahepatic portosystemic shunt (TIPS) has been employed in patients with obliterative PVT and cavernoma as a means of restoring portal vein inflow. This permits end-to-end anastomoses at LT, simplifying surgery and improving long-term outcomes. Work published by Salem et al.^[11] demonstrated adequate safety and efficacy of PVR-TIPS in patients with complete/near complete (>95%) portal vein occlusion and cavernoma. There are no data describing posttransplant outcomes of this procedure to potentiate LT in PVT compared to those that do not. This is the subject of our report.

PATIENTS AND METHODS

Patient selection and study design

This analysis was institutional review board approved and compliant with the Health Insurance Portability and Accountability Act. The population includes patients

with evidence of PVT during consideration of LT between 2000 and 2020. Laboratory values (liver function tests, coagulation studies, basic chemistry, complete blood count) and preoperative cross-sectional imaging (computed tomography [CT], magnetic resonance imaging [MRI]) were reviewed at a weekly liver multidisciplinary conference with physicians from interventional radiology, transplant surgery, and hepatology. There, determination for how to proceed was made by consensus. In patients with expansile PVT where a simple thrombectomy intraoperatively was deemed feasible by transplant surgery, those patients were listed and ultimately underwent LT without intervention. In contradistinction, patients in which the portal vein was not visible and occluded, often associated with large cavernomas, were listed but requested by transplant surgery to undergo pre-LT PVR-TIPS by interventional radiology. This analysis compared outcomes of patients with severe PVT that underwent pre-LT PVR-TIPS to those with minor PVT that underwent LT without PVR-TIPS.

Baseline characteristics

Basic demographic and clinical information were collected, including age, sex, and etiology of liver disease. Details from preoperative imaging, such as presence of portosystemic shunts, extension of portal vein thrombus, and presence of cavernoma (collaterals surrounding the portal vein perfusing the liver), were recorded. PVT was classified according to the Yerdel grading system (grade 1, <50% occlusion of main portal vein with no or minimal obstruction of superior mesenteric vein [SMV]; grade 2, >50% obstruction of main portal vein, including total obstruction; grade 3, complete obstruction of main portal vein and proximal SMV; grade 4, complete obstruction of the portal vein and SMV).^[7] Child-Pugh (CP) class was determined for every patient.

PVR-TIPS procedure

All patients underwent cardiac workup by echocardiogram to rule out underlying cardiac pathology and confirm LT clearance in case of post-PVR-TIPS decompensation. All PVR-TIPS cases were performed under general anesthesia. The internal jugular vein access was obtained by standard method, and a 10 French sheath was advanced into the right atrium for pre-TIPS pressure measurement. The sheath was then placed in the hepatic vein for wedged hepatic vein venography to confirm presence and extent of PVT noted on imaging. PVR was subsequently conducted by transjugular, transsplenic, or transhepatic approaches. Early on in our experience with PVR-TIPS, we attempted to catheterize portal radicals through transjugular access.

When this was not possible, the portal radicals were selected percutaneously (transhepatic approach) through a 21-gauge needle. A catheter was then advanced after recanalizing through the chronically occluded main portal vein. Contemporarily, the standard of care at our institution for PVR is by splenic vein access because it is technically easier.^[12] In the transsplenic approach, the splenic vein was selected under ultrasound guidance and a catheter was advanced through the splenic vein and PVT. This technique has been described.^[11,12]

After achieving main portal vein access across the thrombus, a 10-mm gooseneck snare was placed in an intrahepatic portal vein as a puncture target. Following puncture into the snare, a wire was used for body floss access. The sheath was upsized, and splenoportography was performed. Finally, a TIPS stent was placed, permitting a 4–6-cm portion of nonstented portal vein to remain for end-to-end anastomoses at the time of LT. Originally, shunt embolization, if necessary, was conducted 1 month after the procedure at the time of the follow-up TIPS venogram. Since the advent of the trans-splenic approach, however, our group has begun to embolize shunts during the TIPS procedure.

Follow-up and liver transplant

TIPS procedural details, including length of radiation exposure, fluoroscopic dose, and time between TIPS and transplant, were tabulated for the cohort that underwent PVR-TIPS. Preprocedural and postprocedural portosystemic gradients and CP scores were compared. Adverse events following PVR-TIPS and before LT were graded according to guideline standards.^[13]

Important surgical details of LT were recorded, including inferior vena cava reconstruction technique (piggyback vs. cavoplasty), portal vein reconstruction technique, and use of veno–veno portosystemic bypass (VVB). Adverse events from transplant were evaluated in accordance with the Clavien-Dindo classification system, and quantity of blood products transfused was used as a proxy for intraoperative blood loss.^[14]

Statistical analysis

Statistical analysis for all data was conducted with Microsoft Excel and MedCalc. Continuous variables were depicted as medians and interquartile ranges (IQRs). Categorical variables were represented as a percent of the whole. Chi-squared and two-tailed unpaired Student *t* tests were used to compare characteristics and outcomes between the PVR-TIPS and non-PVR-TIPS cohorts. Blood products transfused during transplant were represented as medians with IQRs and evaluated for significance using a nonparametric Mann-Whitney U test. Overall survival between

groups was performed using Kaplan-Meier. $p < 0.05$ was considered significant.

RESULTS

We identified 49 patients in need of LT with radiographic evidence of PVT. Of these, 14 patients with partial PVT underwent immediate LT without intervention; 35 patients with chronic oblitative PVT were listed but underwent PVR-TIPS in order to enhance outcomes and permit portal end-to-end anastomosis. Representative images of a patient with partial PVT undergoing LT without TIPS and a patient with cavernoma undergoing pre-LT PVR-TIPS are shown in [Figures 1](#) and [2A,B](#), respectively. Demographic information for these two groups is shown in [Table 1](#). The average age at transplant was 55 years in the PVR-TIPS group and 50 years in the non-PVR-TIPS group ($p > 0.05$). All patients had evidence of PVT on preoperative imaging (35 patients were diagnosed on abdominal MRI, 14 were diagnosed on abdominal CT). The most common etiology for end-stage liver disease was nonalcoholic steatohepatitis ($n = 14$), followed by alcoholic cirrhosis (ethanol cirrhosis) ($n = 13$) and hepatocellular carcinoma ($n = 13$). Other causes included primary sclerosing cholangitis, autoimmune hepatitis, hepatitis C, hepatitis B, and biliary atresia. The two study groups were comparable in terms of severity of liver disease, as evidenced by similar CP class distribution between the groups.

Both cohorts presented with a similar frequency of portosystemic shunts, including esophageal and gastric varices, as well as splenorenal shunts. However, the cohorts were significantly different in severity of PVT. As expected, the PVR-TIPS group exhibited worse PVT, initially prohibiting them from being listed for LT in our center. The average Yerdel grade for the PVR-TIPS group was 2.2, including two grade 1, 23 grade 2, 10 grade 3, and no grade 4. The average Yerdel grade for the non-PVR-TIPS group, in contrast, was 1.5, including 10 grade 1, two grade 2, one grade 3,

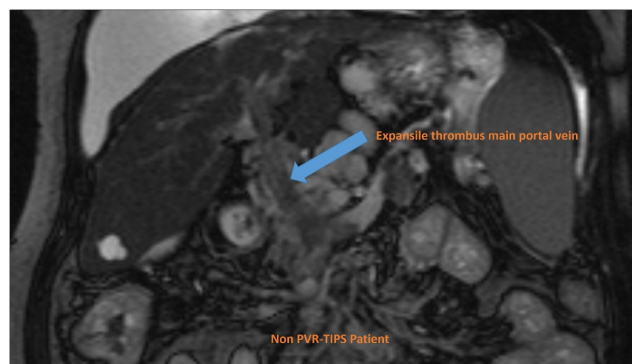


FIGURE 1 Coronal MRI demonstrating expansile bland thrombus in the main portal vein. No pre-LT intervention was performed

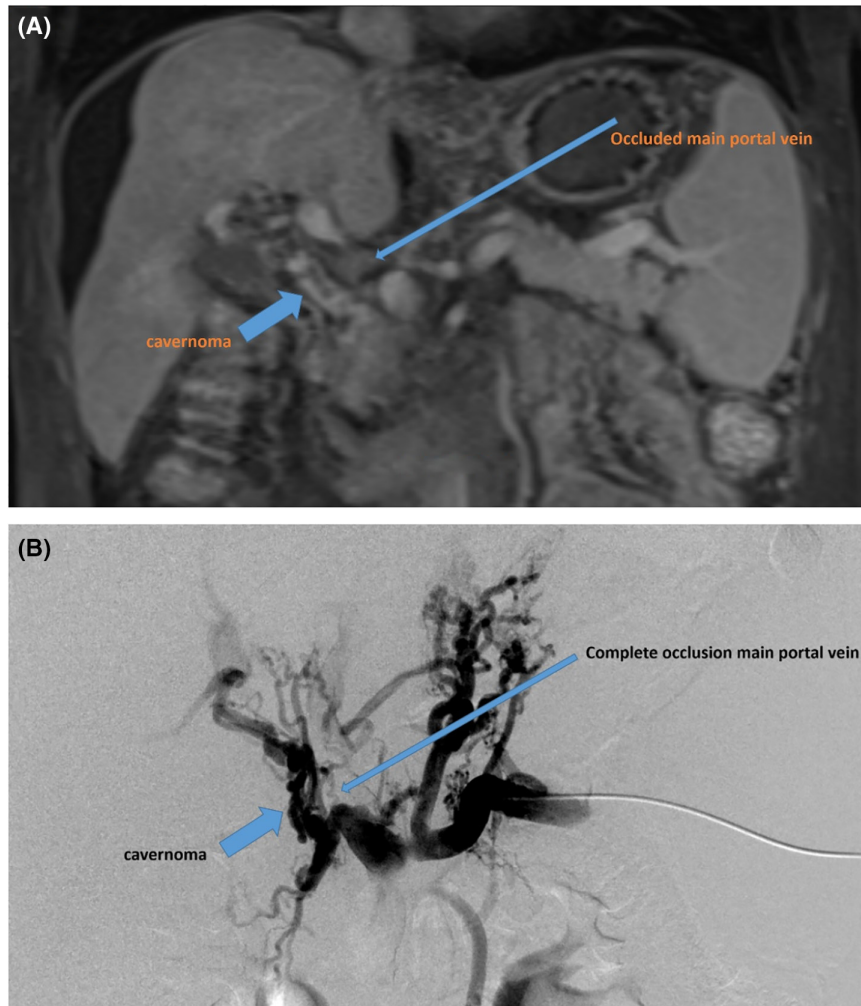


FIGURE 2 Occluded main portal vein and cavernoma. (A) Coronal MRI demonstrating occluded main portal vein and cavernoma. Pre-LT intervention was requested by the transplant team. (B) Same patient as A. Intraprocedural venography confirming MR findings of occluded main portal vein and cavernoma

and one grade 4. The presence of cavernoma, deemed to impart an added surgical risk to LT, was more commonly found in patients who underwent PVR-TIPS than those who did not ($p < 0.05$).

PVR-TIPS was conducted a median of 9 months after diagnosis of PVT. Symptomatology before PVR-TIPS most commonly included ascites, hepatic encephalopathy, and abdominal distention. The median age at TIPS was 57 years (Table 2). The median length of the radiation exposure was 40 minutes, and the median fluoroscopic dose was 1.9 Gray. A total of 12 patients underwent PVR-TIPS by a transsplenic approach, while 5 required a percutaneous transhepatic approach for portal vein access. Shunts were embolized in 18 patients, with 9 patients receiving shunt embolization at the time of TIPS and 9 receiving embolization at 1-month TIPS venography. PVR-TIPS was technically successful in all patients, as demonstrated by patent postprocedural portal vein and patent shunt. Fluoroscopic imaging of the portal vein before and after PVR-TIPS is depicted in Figure 3.

There was a significant drop in portosystemic gradient on average before and after PVR-TIPS (16 vs. 8 mm Hg, respectively; $p < 0.05$). At the end of the procedure, 24 (69%) patients demonstrated complete resolution of thrombus within the main portal vein. One-month TIPS venography demonstrated resolution of thrombus in 12 out of 17 patients (70%). After TIPS, the CP score increased by 1–2 points, reflecting further decompensation, resulting in an increase of patients with CP class C (decompensated disease) ($p < 0.05$). These details are tabulated in Table 3.

Adverse events from PVR-TIPS were graded according to the Society of Interventional Radiology criteria for procedural complications. These are presented in Table 4. There were a total of 13 minor complications, with the most common being hepatic encephalopathy requiring nominal therapy (6 patients); this was followed by abdominal pain, self-limited ascites, and pleural effusion. The most common major complication from TIPS was shunt stenosis requiring revision (17%); this was followed by persistent

TABLE 1 Baseline characteristics

Parameter	PVR-TIPS	Non-PVR-TIPS	p value
Number of patients	35	14	
Average age (years) at transplant, mean \pm SD	55 \pm 12	50 \pm 10	0.22
Sex			
Male	23 (65.7%)	10 (71.4%)	0.83
Female	12 (34.3%)	4 (28.6%)	0.75
Etiology			
ETOH cirrhosis	8 (22.9%)	5 (35.7%)	0.43
Autoimmune hepatitis	4 (11.4%)	0 (0%)	0.21
NASH	11 (31.4%)	3 (21.4%)	0.55
Hepatitis C	6 (17.1%)	5 (35.7%)	0.22
Hepatitis B	3 (8.6%)	0 (0%)	0.27
Hepatocellular carcinoma	11 (31.4%)	2 (14.3%)	0.29
Biliary atresia	1 (2.9%)	0 (0%)	0.53
Primary sclerosing cholangitis	2 (5.7%)	2 (15.4%)	0.34
Clinical presentation			
Patients with portosystemic shunts	34 (97.1%)	7 (87.5%)	0.10
PVT imaging			
Yerdel classification, mean \pm SD	2.2 \pm 0.5	1.5 \pm 0.9	0.0015
Number of vessels thrombosed, mean \pm SD	1.8 \pm 0.9	2 \pm 0.9	0.46
Patients with cavernoma	17 (48.6%)	1 (7.1%)	0.031
CP class			
A	4 (11.4%)	0 (0%)	0.21
B	18 (51.4%)	10 (71.4%)	0.40
C	13 (37.1%)	4 (28.6%)	0.65

Abbreviations: ETOH, ethanol; NASH, nonalcoholic steatohepatitis.

TABLE 2 PVR-TIPS characteristics

Parameter	Number
Number of patients	35
Average age at TIPS, median years (IQR)	57 (13)
Time between PVT diagnosis and TIPS, median months (IQR)	9 (22)
Time between TIPS and transplant, median months (IQR)	5 (19)
Length of radiation exposure, median minutes (IQR)	40 (34)
Fluoroscopic dose, median mGy (IQR)	1948 (3508)

thrombus (14%) and minor bleeding at puncture sites (8.5%) that did not require intervention/embolization. All other major complications shown in [Table 4](#) (biliary fistula, pneumonia, spontaneous bacterial peritonitis, ascites) required an increase in level of care but did not cause permanent adverse sequelae or mortality. The average time between TIPS and transplant was 7.3 months.

Regarding LT, 32 (91%) patients who received PVR-TIPS underwent an end-to-end portal vein anastomosis. Three patients required the use of a graft (one side-to-end SMV interposition graft and two deceased donor end-to-end iliac vein extension grafts). However,

all received physiologic portal inflow anastomoses. Similarly, 13 (93%) patients who did not undergo PVR-TIPS achieved end-to-end portal vein anastomosis at the time of transplant. One patient in this cohort received a donor iliac venous jump graft. None of the grafts in either cohort failed or rethrombosed. The frequency of different types of caval reconstruction was statistically equivalent in both groups as well. Three (8%) patients with TIPS and 3 (21%) patients without TIPS had inferior vena cava reconstruction through the piggyback technique. All other patients underwent cavoplasty (32 patients in the TIPS group vs. 11 patients in the non-TIPS group). No patient in either group required

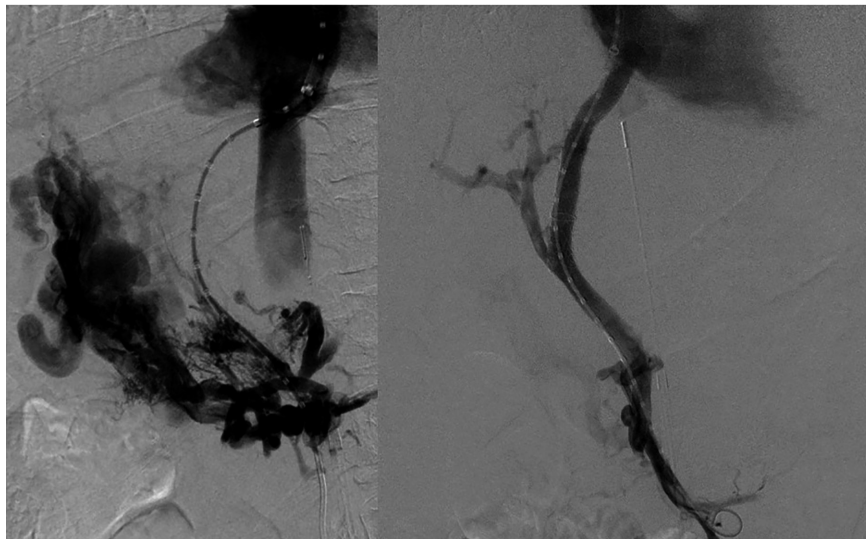


FIGURE 3 Thrombosed main portal vein and large cavernoma. (Left) Mesenteric venography after recanalization demonstrating a thrombosed main portal vein and large cavernoma. (Right) TIPS stent in place, patent main portal vein with 5-cm unstented segment and decompression of the cavernoma

TABLE 3 TIPS procedure results

	Pre-TIPS	Post-TIPS	<i>p</i> value
Child-Pugh class			
A	4 (11.4%)	1 (2.9%)	0.67
B	18 (51.4%)	8 (22.9%)	0.80
C	13 (37.1%)	26 (74.3%)	<0.0001
Portosystemic gradient, mm Hg	16	8	0.0002

TABLE 4 TIPS adverse events

Complications	Number
Minor complications	
Hepatic encephalopathy	6 (17%)
Abdominal pain and distension	3 (8.5%)
Ascites	3 (8.5%)
Pleural effusion	1 (3%)
Major complications	
Shunt stenosis	6 (17%)
Persistent thrombus	5 (14%)
Bleeding (hematoma/hemorrhage), no intervention required	3 (8.5%)
Biliary fistula	1 (3%)
Pneumonia	1 (3%)
Spontaneous bacterial peritonitis	1 (3%)
Ascites	1 (3%)

complete caval replacement. Finally, 4 patients (11%) in the PVR-TIPS group underwent multiorgan liver/kidney transplants. Four patients (29%) in the non-PVR-TIPS group underwent multiorgan transplant with three liver/kidney transplants and one stomach/pancreas/small

bowel/liver transplant. The aforementioned surgical details are presented in [Table 5](#).

Significantly more red blood cells (RBCs; median, 15 units; IQR, 23 units) were transfused during transplant in patients who did not have PVR-TIPS than those who had preoperative PVR-TIPS (median, 12 units; IQR, 15 units). There was no significant difference between the amount of fresh-frozen plasma (FFP), platelets, cryoglobulin, and cell saver used between the two groups. VVB was used significantly more in the non-PVR-TIPS group. VVB was never used in the PVR-TIPS group.

Adverse events following LT are depicted in [Table 6](#). Overall, both groups displayed similar low- and high-grade complication profiles. However, patients without preoperative TIPS experienced hematochezia significantly more frequently ($p < 0.05$). Overall survival of the two groups is depicted by the Kaplan-Meier curve in [Figure 4](#). Median overall survival for the groups was not significantly different (log-rank $p > 0.05$).

DISCUSSION

Some centers consider the presence of chronic obliterative PVT with or without cavernoma a relative

TABLE 5 Surgical details

Parameter	Pre-OLT TIPS	OLT without TIPS	p value
Portal vein reconstruction			
End-to-end anastomosis	32 (91.4%)	13 (92.9%)	0.9624
Graft/conduit	3 (8.6%)	1 (7.1%)	0.8744
Caval reconstruction technique			
Piggyback	3 (8.3%)	3 (21.4%)	0.2453
Cavoplasty	32 (88.9%)	11 (78.6%)	0.6643
Blood transfusion			
RBC, median units (IQR)	12 (15)	15 (23)	0.0293
FFP, median units (IQR)	11 (15)	14 (23)	0.2187
Platelets, median units (IQR)	4 (5)	3 (2)	0.7795
Cryo, median units (IQR)	2 (4)	2 (4)	0.9920
Cell saver, median units (IQR)	0 (3100)	0 (2252)	0.5093
VVB	0 (0%)	2 (14.3%)	0.0253

Abbreviation: OLT, orthotopic liver transplant.

contraindication for LT. The 35 patients in our study who had high-grade PVT/cavernoma were initially deemed, by transplant surgery, to be surgically challenging and high risk for LT without a portal intervention; they were recommended for PVR-TIPS. The 14 patients who were deemed to be able to receive a transplant, on the other hand, had low Yerdel grades (71% had Yerdel grade 1) and rarely exhibited cavernoma on preoperative imaging. It is our understanding that other institutions operate similarly when recommending LT to patients with PVT. This is likely because chronic PVT necessitates nonphysiologic flow reconstruction of the portal vein at the time of transplant, which is associated with sub-optimal outcomes. Portocaval hemitransposition, for example, can predispose patients to variceal bleeding requiring reintervention, azotemia, and persistent portal hypertension.^[15] Arterialization of the portal vein can cause pulmonary hypertension, right heart failure, and renal failure.^[16] Multiorgan transplantation is known to have a high morbidity and mortality.^[17] Finally, renoportal anastomoses, largely used for patients with spleno-renal shunts, predispose patients to rethrombosis, renal failure, and recurrent ascites.^[18]

The limitations of surgical management of high-grade PVT in patients receiving LT necessitates alternative interventions, such as PVR-TIPS. TIPS in the setting of PVT was first described by several authors in the mid 1990s.^[19–21] The procedure has since evolved to incorporate technical improvements using transsplenic access for highly complex cases, as is now routinely performed at our institution for chronic obliterative PVT.^[11,12,22] The goal of PVR-TIPS is to create an open unstented PV and allow for end-to-end physiologic flow anastomosis of the portal vein at the time of LT. The data presented here show that PVR-TIPS (irrespective of transjugular, transhepatic, or transsplenic approach) is effective at resolving portal venous obstruction.

Rates of thrombus resolution at the conclusion of TIPS and 1-month venography were high and consistent with previous findings.^[11,23] Recently, the transmesenteric route has also been described.^[24]

PVR-TIPS was a safe procedure. Frequency of minor complications, such as hepatic encephalopathy (17%), pleural effusions (3%), and ascites (11.5%), are consistent with a previous report of adverse events related to PVR-TIPS.^[22] Other complications, such as shunt stenosis (17%) and persistent thrombus (14%), were found in similar extents as earlier reports.^[22] Of note, shunt embolization, either at the time of TIPS or during follow-up, may have helped decrease the risk of adverse events. Patients who had shunts embolized experienced minor complications, such as hepatic encephalopathy, abdominal pain, and ascites. The only major complications experienced by the 18 patients who had shunts embolized were two cases of shunt stenosis (11%) and one case of persistent PVT (5%). This low adverse event rate is presumably due to increased forward flow through the TIPS stent.^[25] Further investigation into this association is needed in order to draw definitive therapeutic conclusions.

The CP score for patients who received PVR-TIPS increased by 1–2 points, reflecting an element of further hepatic decompensation. These decompensations in classification were largely due to small 1-point changes in international normalized ratio and bilirubin, as would be expected in patients with high-grade PVT. Nonetheless, PVR-TIPS improved liver transplant candidacy in our cohort. The patients in our study who were initially not able to undergo transplantation because of high-grade PVT all went on to receive transplants. Moreover, 91% of these patients were able to undergo end-to-end portal vein anastomosis. Additionally, veno–veno bypass was not used in any patient who underwent PVR-TIPS. It was, however, used in 2 patients

TABLE 6 Posttransplant adverse events^a

Parameter	PVR-TIPS n = 35	Non-PVR-TIPS n = 14	p value
Grade 1 total			
Abdominal pain	5 (14%)	2 (14%)	1.00
Acute kidney injury	4 (11%)	4 (29%)	0.18
Ascites	7 (20%)	1 (7%)	0.31
Hematoma	4 (11%)	0	0.21
Hepatic encephalopathy	3 (9%)	0	0.27
Pleural effusion	11 (31%)	5 (38%)	0.81
Grade 2 total			
Bacteremia	2 (6%)	2 (14%)	0.34
Cholangitis	1 (3%)	0	0.53
Endocarditis	1 (3%)	1 (7%)	0.50
Pancytopenia	2 (6%)	0	0.37
Pneumonia	1 (3%)	1 (7%)	0.50
Spontaneous bacterial peritonitis	2 (6%)	1 (7%)	0.86
Hematochezia	0	2 (14%)	0.026
Grade 3 total			
Ascites	1 (3%)	1 (7%)	0.50
Abscess	1 (3%)	1 (7%)	0.50
Biliary leak	1 (3%)	0	0.53
Biliary stricture	9 (26%)	4 (31%)	0.86
Enterocutaneous fistula	0	1 (7%)	0.11
Hepatic artery stenosis	2 (6%)	1 (7%)	0.86
Hematoma	2 (6%)	2 (14%)	0.34
Pleural effusion	2 (6%)	1 (7%)	0.86
Portal vein rethrombosis	3 (9%)	2 (14%)	0.57
Grade 4 total			
Chronic kidney disease requiring dialysis	5 (14%)	2 (14%)	1.00
Liver failure	1 (3%)	1 (7%)	0.50
Multiple organ failure	2 (6%)	3 (21%)	0.12

^aClavien-Dindo grading system.

(14%) with low-grade PVT who did not have PVR-TIPS. Avoiding VVB in LT is an important clinical goal as it results in shorter surgical times, shorter anhepatic phases, shorter warm ischemia times, and a lower total cost of the operation.^[26] There are also some reports that VVB can cause pulmonary thromboembolism or postreperfusion syndrome in up to 30% of patients.^[27] Patients who had PVR-TIPS also required significantly less intraoperative RBC transfusions than patients who did not. This is of vital importance as increased transfusion of blood products is highly correlated with liver transplant morbidity and mortality.^[28] Of note, FFP and cryoglobulin were also transfused more on average in the non-PVR-TIPS group. These differences may have been significant if our study had a higher sample size of patients to analyze.

In terms of surgical complications, both groups experienced similar side-effect profiles. In fact, there were no

significant differences in adverse events except for hematochezia (a low-grade complication found more frequently in the non-PVR-TIPS group). Notably, there was an increased incidence of acute kidney injury in the non-PVR-TIPS group that may be explained by the high levels of blood loss experienced by these patients as measured by high quantities of intraoperative RBC transfusions. Finally, overall survival was similar between groups.

It is possible that the 35 patients in our study who received PVR-TIPS before LT would not have received a transplant at other institutions. Historically, lack of portal vein visualization and cavernomatous portal vein transformation have been considered contraindications to LT. Complex nonphysiologic vascular reconstructions for high-grade PVT are occasionally taken on by high-volume centers. Meanwhile, multivisceral transplantation for obliterative PVT is only offered in select centers.^[29] Even so, these operations have high

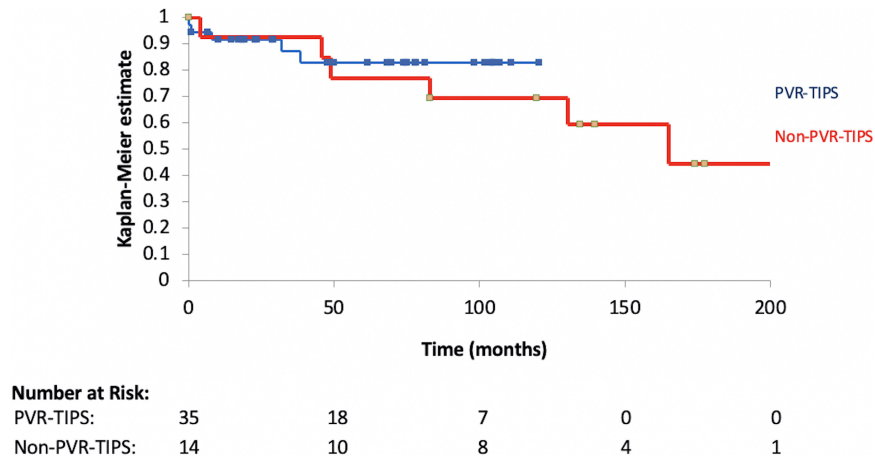


FIGURE 4 Overall survival comparison between groups ($p > 0.05$)

rates of adverse events. After PVR-TIPS, our patients with high-grade PVT became excellent surgical candidates and went on to have few posttransplant complications. PVR-TIPS, therefore, represents an option to bridge patients to liver transplantation.

Our group first used PVR-TIPS several years ago. Throughout our experience, we have simplified the procedure to simple steps that can be adopted by other interventional radiologists. Technical considerations, preoperative workup, and expected outcomes of the procedure have been detailed extensively by Thornburg et al.^[12] Thus far, a few PVR-TIPS cases conducted in other centers have been showcased on social media and described in peer-reviewed journals.^[30] We anticipate more data to be published in the coming years as operators become increasingly familiar with the technique.

The primary strength of this study was that it is the first study to compare LT in patients who received preoperative PVR-TIPS for chronic PVT to those who did not. In effect, it compares a high-risk group (complete PVT with cavernoma requiring intervention) to a less risky group (partial PVT not requiring intervention). The data spans 20 years and encompasses procedures performed by experienced interventional radiologists and transplant surgeons. Conversely, this study was limited by its small sample size as receiving PVR-TIPS before LT occurs only in select cases. There were also several confounding variables. For example, this study was also unable to account for advancements in LT techniques and immunosuppression since 2000. It is therefore possible that some of the benefits of PVR-TIPS cases, which were predominantly performed after 2010, are attributable to a better standard of care. Similarly, transsplenic and mesenteric approaches to PVR-TIPS have been pioneered recently, and the outcomes may have varied had all cases been conducted with these new approaches.^[23,24] Another possible confounding variable

was a higher prevalence of multiorgan transplants in the non-PVR-TIPS group (29% vs. 11%). As the present analysis focuses on LT, multiorgan transplants may have inappropriately skewed overall survival by contributing to morbidity and mortality. Finally, while the rate of mild PVT in our patient with LT population may seem low, it should be noted that the presence of PVT is often documented from operative findings while this analysis focuses on gross PVT and cavernoma documented at imaging.

PVR-TIPS is an effective option for patients in need of LT afflicted with chronic obliterative PVT with cavernoma. Through this technique, normal portal physiologic inflow can be achieved at the time of transplant. Postoperative adverse events and survival of patients with high-grade high-risk PVT who receive PVR-TIPS are comparable to those patients with low-grade low-risk PVT who undergo transplantation directly. Thus, PVR-TIPS is an important neoadjuvant option and represents an added tool to other surgical techniques for patients with extensive PVT awaiting liver transplantation.

ACKNOWLEDGMENT

None.

CONFLICT OF INTEREST

Dr. Mouli consults for and received grants from Boston Scientific Corporation. Dr. Desai consults for W.L. Gore and Associates.

ORCID

Daniella Ladner  <https://orcid.org/0000-0001-5526-8272>

Riad Salem  <https://orcid.org/0000-0001-9745-1825>

REFERENCES

1. Amitrano L, Guardascione MA, Brancaccio V, Margaglione M, Manguso F, Iannaccone L, et al. Risk factors and clinical presentation of portal vein thrombosis in patients with liver cirrhosis. *J Hepatol.* 2004;40:736–41.

2. Mihaylov P, Mangus R, Ekser B, Cabrales A, Timsina L, Fridell J, et al. Expanding the donor pool with the use of extended criteria donation after circulatory death livers. *Liver Transpl.* 2019;25:1198–208.
3. Croome KP, Lee DD, Taner CB. The “Skinny” on assessment and utilization of steatotic liver grafts: a systematic review. *Liver Transpl.* 2019;25:488–99.
4. Hibi T, Nishida S, Levi DM, Selvaggi G, Tekin A, Fan JI, et al. When and why portal vein thrombosis matters in liver transplantation: a critical audit of 174 cases. *Ann Surg.* 2014;259:760–6.
5. Lendoire J, Raffin G, Cejas N, Duek F, Barros Schelotto P, Trigo P, et al. Liver transplantation in adult patients with portal vein thrombosis: risk factors, management and outcome. *HPB (Oxford).* 2007;9:352–6.
6. Lladó L, Fabregat J, Castellote J, Ramos E, Torras J, Jorba R, et al. Management of portal vein thrombosis in liver transplantation: influence on morbidity and mortality. *Clin Transplant.* 2007;21:716–21.
7. Yerdel MA, Gunson B, Mirza D, Karayalçin K, Olliff S, Buckels J, et al. Portal vein thrombosis in adults undergoing liver transplantation: risk factors, screening, management, and outcome. *Transplantation.* 2000;69:1873–81.
8. Chen H, Turon F, Hernández-Gea V, Fuster J, Garcia-Criado A, Barrufet M, et al. Nontumoral portal vein thrombosis in patients awaiting liver transplantation. *Liver Transpl.* 2016;22:352–65.
9. Bhangui P, Lim C, Levesque E, Salloum C, Lahat E, Feray C, et al. Novel classification of non-malignant portal vein thrombosis: a guide to surgical decision-making during liver transplantation. *J Hepatol.* 2019;71:1038–50.
10. Manzia TM, Fazzolari L, Manuelli M, Pellicciaro M, Baiocchi L, Tisone G. Liver transplantation in a patient with complete portal vein thrombosis, is there a surgical way out? A case report. *Ann Med Surg (Lond).* 2016;11:5–8.
11. Salem R, Vouche M, Baker T, Herrero JI, Caicedo JC, Fryer J, et al. Pretransplant portal vein recanalization-transjugular intrahepatic portosystemic shunt in patients with complete obliterative portal vein thrombosis. *Transplantation.* 2015;99:2347–55.
12. Thornburg B, Desai K, Hickey R, Kulik L, Ganger D, Baker T, et al. Portal vein recanalization and transjugular intrahepatic portosystemic shunt creation for chronic portal vein thrombosis: technical considerations. *Tech Vasc Interv Radiol.* 2016;19:52–60.
13. Sacks D, McClenny TE, Cardella JF, Lewis CA. Society of Interventional Radiology clinical practice guidelines. *J Vasc Interv Radiol.* 2003;14:S199–202.
14. Dindo D, Demartines N, Clavien PA. Classification of surgical complications: a new proposal with evaluation in a cohort of 6336 patients and results of a survey. *Ann Surg.* 2004;240:205–13.
15. Tzakis AG, Kirkegaard P, Pinna AD, Jovine E, Misiakos EP, Maziotti A, et al. Liver transplantation with cavoportal hemitransposition in the presence of diffuse portal vein thrombosis. *Transplantation.* 1998;65:619–24.
16. Zhang K, Jiang Y, Lv LZ, Cai Q-C, Yang F, Hu H-Z, et al. Portal vein arterialization technique for liver transplantation patients. *World J Gastroenterol.* 2014;20:12359–62.
17. Tekin A, Beduschi T, Vianna R, Mangus RS. Multivisceral transplant as an option to transplant cirrhotic patients with severe portal vein thrombosis. *Int J Surg.* 2020;82S:115–21.
18. D’Amico G, Hassan A, Diago Uso T, Hashmimoto K, Aucejo FN, Fujiki M, et al. Renportal anastomosis in liver transplantation and its impact on patient outcomes: a systematic literature review. *Transpl Int.* 2019;32:117–27.
19. Bilbao JI, Quiroga J, Herrero JI, Benito A. Transjugular intrahepatic portosystemic shunt (TIPS): current status and future possibilities. *Cardiovasc Intervent Radiol.* 2002;25:251–69.
20. Blum U, Haag K, Rössle M, Ochs A, Gabelmann A, Boos S, et al. Noncavernomatous portal vein thrombosis in hepatic cirrhosis: treatment with transjugular intrahepatic portosystemic shunt and local thrombolysis. *Radiology.* 1995;195:153–7.
21. Radosevich PM, Ring EJ, LaBerge JM, Peltzer MY, Haskal ZJ, Doherty MM, et al. Transjugular intrahepatic portosystemic shunts in patients with portal vein occlusion. *Radiology.* 1993;186:523–7.
22. Thornburg B, Desai K, Hickey R, Hohlastos E, Kulik L, Ganger D, et al. Pretransplantation portal vein recanalization and transjugular intrahepatic portosystemic shunt creation for chronic portal vein thrombosis: final analysis of a 61-patient cohort. *J Vasc Interv Radiol.* 2017;28:1714–21.e2.
23. Habib A, Desai K, Hickey R, Thornburg B, Vouche M, Vogelzang RL, et al. Portal vein recanalization-transjugularintrahepatic portosystemic shunt using the transsplenic approach to achieve transplant candidacy in patients with chronic portal vein thrombosis. *J Vasc Interv Radiol.* 2015;26:499–506.
24. Entezari P, Riaz A, Thornburg B, Salem R. Percutaneous ultrasound-guided superior and inferior mesenteric vein access for portal vein recanalization-transjugular intrahepatic portosystemic shunt: a case series. *Cardiovasc Intervent Radiol.* 2021;44:496–9.
25. Schultheiß M, Giesler M, Maruschke L, Schmidt A, Sturm L, Thimme R, et al. Adjuvant transjugular variceal occlusion at creation of a transjugular intrahepatic portosystemic shunt (TIPS): efficacy and risks of bucrylate embolization. *Cardiovasc Intervent Radiol.* 2019;42:729–36.
26. Sakai T, Matsusaki T, Marsh JW, Hilmi IA, Planinsic RM. Comparison of surgical methods in liver transplantation: retrohepatic caval resection with venovenous bypass (VVB) versus piggyback (PB) with VVB versus PB without VVB. *Transpl Int.* 2010;23:1247–58.
27. Hoffmann K, Weigand MA, Hillebrand N, Büchler MW, Schmidt J, Schemmer P. Is veno-venous bypass still needed during liver transplantation? A review of the literature. *Clin Transplant.* 2009;23:1–8.
28. Yokoyama A, Kutner J, Sakashita A, Nakazawa C, de Paula T, Zamper R, et al. Risk factors for transfusion after orthotopic liver transplantation. *Transfus Med Hemother.* 2019;46:431–9.
29. Harding DJ, Perera MTPR, Chen F, Olliff S, Tripathi D. Portal vein thrombosis in cirrhosis: controversies and latest developments. *World J Gastroenterol.* 2015;21:6769–84.
30. Salsamendi JT, Gortes FJ, Shnayder M, Doshi MH, Fan JI, Narayanan G. Transsplenic portal vein reconstruction-transjugular intrahepatic portosystemic shunt in a patient with portal and splenic vein thrombosis. *Radiol Case Rep.* 2016;11:186–9.

How to cite this article: Talwar A, Varghese J, Knight GM, Katariya N, Caicedo J-C, Dietch Z, et al. Preoperative portal vein recanalization–transjugular intrahepatic portosystemic shunt for chronic obliterative portal vein thrombosis: outcomes following liver transplantation. *Hepatol Commun.* 2022;6:1803–1812. <https://doi.org/10.1002/hep4.1914>