

Staphylococcus lugdunensis from gluteal abscess to destructive native triple valve endocarditis

Fahad M. Al Majid, ABIM, FRCP

ABSTRACT

في هذا البحث، نستعرض حالة مريض مصاب بداء السكري يبلغ من العمر ٤٣ عامًا وقد تعرض بشكل عدوانيًا لإلتهاب بطانة القلب والصمامات الثلاثية: الأبهري والميتري والثلثي الشرف بعد اصابته بخراج جلدي ناتج عن عدوى بكتيريا *Staphylococcus lugdunensis*. لقد ظهر هذا الكائن العضوي السلبي التخثر والذي يعتبر بشكل عام مكونًا للنبات الطبيعي للبشرة، كمرض سُمي على نحو غير معتاد ومسؤول عن كل من العدوى المكتسبة بالمستشفى والمجتمع. إن هذه الحالة توضح أهمية إعطاء أقصى قدر من الإهتمام وضمان تحديد نوعية الكائن السلبي التخثر عند زراعته المستمرة في الدم. بالإضافة إلى ذلك فإنه يدل أيضا على أهمية التحديد المبكر لهذا الكائن الحي وإعطاء المضادات الحيوية لتجنب التهاب الشغاف بسبب الأمراض الغير العادية لهذا الكائن. وإذا تم عزل ميكروب *Staphylococcus lugdunensis* فإنه يتطلب المزيد من التحقق وإعطاء العلاج لأنه من النادر أن يكون ملوثا سريريا للعينة.

We herein present the case of a 43-year-old male diabetic patient who presented with an aggressive form of infective endocarditis involving the tricuspid, mitral and aortic valves following a gluteal abscess due to infection with *Staphylococcus lugdunensis*. This coagulase-negative organism which is generally considered a component of the normal flora of the skin has however recently emerged as an unusually virulent pathogen responsible for both nosocomial and community-acquired infections. The case demonstrates the importance of paying utmost attention and ensuring a logical conclusion to the identification of persistent coagulase-negative blood cultures. In addition, it also shows the importance of early identification of this organism and aggressive antibiotic administration to avert endocarditis because of the unusual virulence of the organism. *Staphylococcus lugdunensis* is rarely a clinical specimen contaminant, and its isolation warrants further investigation and concerted treatment.

Saudi Med J 2018; Vol. 39 (10): 1050-1053
doi: 10.15537/smj.2018.10.22905

From the Division of Infectious Diseases, King Khalid University Hospital, King Saud University, Riyadh, Kingdom of Saudi Arabia.

Received 8th May 2018. Accepted 1st September 2018.

Address correspondence and reprint request to: Dr. Fahad M. Al Majid, Chief of Infectious Disease's Division, King Khalid University Hospital, King Saud University, Riyadh, Kingdom of Saudi Arabia.
E-mail: falmajid@gmail.com
ORCID ID: orcid.org/0000-0003-2719-5103

Staphylococcus lugdunensis (*S. lugdunensis*) is a coagulase-negative bacterium (CoNS) that is considered a component of the normal skin colonizers. Recently, varieties of clinical infection ranging from skin and soft tissue infection to life-threatening infective endocarditis (IE) have been attributed to *S. lugdunensis*.^{1,2} This coagulase-negative staphylococcus has emerged as an unusually virulent pathogen responsible for nosocomial as well as community-acquired infections. *Staphylococcus lugdunensis* tends to colonize 19-23% of healthy subjects with preferential locations in areas with high surface humidity such as the inguinal fold, perineum, breast, and axilla.³ According to a study of 229 patients with *S. lugdunensis* isolates, the most commonly associated clinical diagnoses were skin infections (55.4% of cases) followed by the blood and vascular infections (17.4%).⁴ Surgical or invasive procedures precede *S. lugdunensis* infection in 80% of patients,³ and overall, most (73%) of the infections involve sites below rather than above the waist.⁵ In addition, bloodstream infections have been documented to follow femoral artery catheterization⁴ and scrotal wounds.

Native valve endocarditis due to *S. lugdunensis* is typically community-acquired and associated with a high rate of complications and death. While other coagulase-negative staphylococci (*S. epidermidis*) can be

Disclosure. Authors have no conflict of interests, and the work was not supported or funded by any drug company.

associated with a high rate of heart failure and valvular complications in the setting of endocarditis, the mortality rate of *S. lugdunensis* endocarditis rivals that of *Staphylococcus aureus*.⁵ The ability of *S. lugdunensis* to cause endocarditis and prosthetic device-associated infections alludes to the fact that the organism has the ability to interact with host tissues and proteins to improve its virulence. *Staphylococcus lugdunensis* pathogenesis is related to production of an enzyme called atL by *S. lugdunensis* gene, which appears to be implicated in cell autolysis and separation.⁶ We present a patient who developed gluteal abscess due to *S. lugdunensis* complicated by bloodstream infection and destructive endocarditis requiring open heart surgery and valve replacement to save his life.

Case Report. Patient information. A 43-year-old Asian male was transferred to our hospital after undergoing a drainage procedure for a gluteal abscess at another hospital. He was known to have poorly controlled diabetes, and hyperlipidemia on treatment; he was also a heavy smoker for more than 20 years. The complaints started 3 weeks prior to presentation with fever and gluteal abscess which was drained surgically (Table 1). The fever persisted despite receiving a combination of gentamycin and penicillin. Two days later, the patient's condition deteriorated with the onset of shortness of breath and orthopnea. Two sets of blood culture performed on 6 August 2017 grew CoNS, which was considered a contaminant. Further evaluation via transthoracic echocardiography revealed the presence of large vegetation on the aortic valve with severe regurgitation and moderate size vegetation on mitral and tricuspid valve with moderate regurgitation plus aortic root abscess. He was subsequently transferred to our hospital for cardiac surgery.

Clinical findings. On arrival, his condition had worsened as evidenced by fever with a temperature of 38.9°C, tachycardia (142 beats/minute), hypotension (96/54 mm Hg), and blood oxygen saturation level of 91%. Laboratory tests revealed a white blood cell count of 14,000/mm³ with 81% neutrophils while kidney profile showed acute renal failure with urea 19.5 mmol/L and creatinine 533 µmol/L. His C-reactive protein level was 200 mg/L.

Hospital course and treatment. He was admitted to the intensive care unit and parenteral vancomycin was initiated based on the knowledge of a previous culture of CoNS from the referring hospital. The condition of the patient deteriorated further the next day with refractory heart failure and pulmonary edema due to the extensive valvular lesions and insufficiency with worse

blood gas values and desaturation (SpO₂, 84%). He was intubated and continuous renal replacement therapy was initiated with a good response as demonstrated by the normalization of his blood pressure and blood gases.

Diagnostic assessment. The microbiologist in our hospital issued the result of the positive blood culture of CoNS, which was identified as *S. lugdunensis* by using MicroScan Walkaway 96 Plus commercial system. The decision to add cefazolin was based on the antibiogram which showed the isolate to be sensitive to almost all antibiotics tested including oxacillin. A transesophageal echocardiogram confirmed the presence of a large vegetation on the aortic valve with regurgitation and moderate vegetations on the mitral and tricuspid valves with regurgitation and aortic root abscess (Figures 1 & 2).

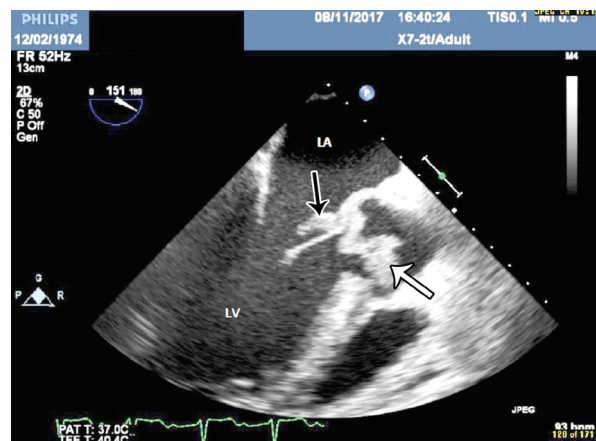


Figure 1 - Transesophageal echocardiogram showing a large vegetation on a native aortic valve (thick arrow). A moderate vegetation (thin arrow) can be seen on the mitral valve. LA - left atrium, LV - left ventricle.

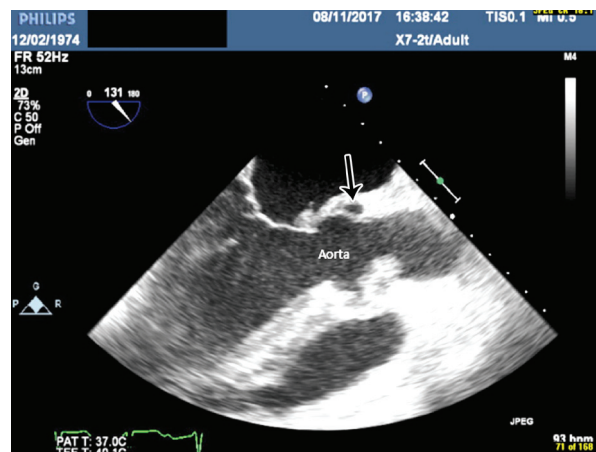


Figure 2 - Transesophageal echocardiogram showing annular aortic abscess with aortic root involvement (white arrow).

Table 1 - Timetable picture for the case of *Staphylococcus lugdunensis*; from gluteal abscess to destructive endocarditis

Date	Relevant past medical history and interventions		
	A 43-year-old Saudi male diagnosed with diabetes mellitus, hypertension, and hyperlipidemia and medical treatment (on insulin, lisinopril and atorvastatin) for 10 years. He was a heavy smoker.		
Date	Summaries from initial visit and admission follow up	Diagnostic testing	Interventions
22 July 2017	Presented to another hospital	USS confirmed gluteal abscess	Drainage with and swab for culture antibiotics initiated
24 July 2017	Fever persisted and patient, developed dyspnea		Antibiotics change to genta and penicillin
07 August 2017	Patient continued to be sick	Blood grew coagulase-negative staphylococci. Echo: multiple vegetation, on mitral, aortic and tricuspid valves	
09 August 2017	Patient was transferred to our hospital for heart surgery		
10 August 2017	Patient was sick with: Temperature: 39°, blood pressure 96/54 mm Hg, pulse rate: 142/m, Saturation: 91%	Laboratory: white blood cells: 14000, Polymorph: 81% Urea: 19.5mmol/l, creatinine: 533 µmol/L	Adjusted dose of vancomycin given
11 August 2017	Patient was diagnosed to have blood grew. Pulmonary edema and infective endocarditis	Lugdunensis	Patient was intubated and CCRT was started
14 August 2017	Patients' condition did not improve and blood pressure	Chest x-ray: pulmonary edema.	Open-heart surgery: Three valve replacement and drainage of the aortic root abscess
	Patient condition has improved significantly and antibiotics were given for 6 weeks.		
	Patient continued to be stable and subsequently discharged in a stable condition		

The general condition worsened with refractory heart failure and pulmonary edema due to the extensive valvular lesions and insufficiency.

Therapeutic intervention. An emergency open heart surgery was then performed to replace all valves and drain the aortic root abscess. His postoperative clinical course was uneventful with vancomycin and cefazolin as a combination of antibiotics administered over a period of 6 weeks. He was subsequently discharged in a stable condition (Table 1).

Discussion. *Staphylococcus lugdunensis* had been confirmed over the last 20 years as an etiological pathogen of many soft-tissue abscesses and IE.⁷ *Staphylococcus lugdunensis* has previously been considered as a component of the normal skin flora and a nonpathogenic organism. The most common sites of colonization are the perineum, the female breast area and the inguinal area, which explains the location of abscess in several reported cases as well as in this patient.³ Bocher et al found that 13% of 159 abscesses were due to *S. lugdunensis*.¹ This index patient was managed at the referring hospital with surgical drainage of the gluteal abscess with CoNS isolated from both the drained pus and blood. Further important steps in management were inadvertently relegated

as the laboratory considered it as a contaminant and in addition the use of inappropriate combination of gentamycin and ceftriaxone led to this catastrophic outcome. Therefore, with proper communication and decision, the patient would have been commenced at least on vancomycin before final identification. Furthermore, patient management has demonstrated the lack of routine identification of CoNS to the species level at the referring hospital which was similar to many clinical microbiology laboratories elsewhere.⁸ Typically, cultures positive for staphylococci are tested to identify *S. aureus*, which in many cases can simply be determined with a slide or latex agglutination test for clumping factor. If the isolates cultured from wounds or blood turn out to be CoNS then many physicians assume it to be a contaminant. In fact, *S. lugdunensis* is easily identifiable with relatively few biochemical tests, namely, a positive p-dimethylamino-cinnamaldehyde reaction, positive ornithine decarboxylase activity, and a negative tube coagulase test. *Staphylococcus lugdunensis* is the only *Staphylococcus species* for which more than 90% of isolates are positive for ornithine decarboxylase. A positive result can be obtained as early as 8 hours. Knowledge of the species early on in the management and commencement of proper antibiotics could have prevented endocarditis in this patient. This case further

highlights the pathogenic potential of coagulase-negative staphylococci as in 2 reported series that examined clinical isolates of *S. lugdunensis*, only a minority of isolates were considered contaminants or colonizing organisms.^{5,9} The importance of *S. lugdunensis* was described in 1989 when it was implicated as an etiological pathogen in infective endocarditis. Since then, more than 100 cases of IE due to *S. lugdunensis* has been reported. So, it seems that this organism is seldom to cause endocarditis but when it occurs it behaves aggressively and often fatal. The incidence of IE due to *S. lugdunensis* bacteremia is reported to be as high as 50 % and tends to be aggressive with valve destruction and periannular abscess formation. Anguera et al has carried out a combined analysis of 69 reported cases of IE due to *S. lugdunensis* and has shown that native valve endocarditis is typically community acquired (n=53 patients, 77%) and characterized by mitral valve involvement with complications such as heart failure (45%), abscess formation (19%), and death (29%) in patients who had open heart surgery.¹⁰ Consequently, many experts recommend not considering *S. lugdunensis* as a contaminant or colonizer unless careful patient review and investigation is performed even with only one positive blood culture.⁴ Effective antibiotics and early surgical intervention with valve replacement are necessary as they were found to reduce mortality from 70% to 18%.⁹ Therefore, every patient with community-acquired *S. lugdunensis* bacteremia should be initiated on antibiotics early and carefully tested for endocarditis by at least transthoracic echocardiography.

In conclusion, IE is a serious complication of *S. lugdunensis* bloodstream infection with significant mortality. Early identification of this species and appropriate antibiotic therapy during the therapeutic window is very crucial in the management to avert endocarditis because of its peculiar virulence. In the event of endocarditis, early surgical intervention with valve replacement in addition to antibiotics is needed in most cases to ensure the survival of patients. Furthermore, *S. lugdunensis* bacteremia is rarely a contaminant of clinical specimens or colonizing organism, and

its isolation necessitates further investigation and aggressive management.

Acknowledgment. I would like to thank the Researchers Support Services Unit at King Saud University, Riyadh, Saudi Arabia for English language editing.

References

1. Lucas A, Heldt Manica, Philip R. Cohen. *Staphylococcus lugdunensis* infections of the skin and soft tissue: A case series and review. *Dermatol Ther (Heidelb)* 2017; 7: 555-562.
2. Sabe MA, Shrestha NK, Gordon S, Menon V. *Staphylococcus lugdunensis*: a rare but destructive cause of coagulase-negative staphylococcus infective endocarditis. *European Heart Journal Acute Cardiovascular Care* 2014; 3: 275-280.
3. Bieber L, Kahlmeter G. *Staphylococcus lugdunensis* in several niches of the normal skin flora. *Clin Microbiol Infect* 2010; 16: 385-388.
4. Byrnes TJ, Rose BT, Myers NM, Myers JP. *Staphylococcus lugdunensis* bacteremia in adults in a large community teaching hospital. Report of 29 Episodes and Review of its Epidemiology, Microbiology, Clinical Manifestations, and Treatment. *J Medical Microbiol Diagnosis* 2014, S.
5. Celestine I, Monica G, Margaret K, Edward C, Yu Shia Lin. *Staphylococcus lugdunensis* endocarditis with destruction of the ventricular septum and multiple native valves. *IDCases* 2017; 7: 14-15.
6. Gibert L, Didi J, Marlinghaus L, Lesouhaitier O, Legris S, Szabados F, et al. The major autolysin of *Staphylococcus lugdunensis*, AtlL, is involved in cell separation, stress-induced autolysis and contributes to bacterial pathogenesis. *FEMS Microbiol Lett* 2014; 352: 78-86.
7. Patel R, Piper K, Rouse M, Uhl JR, Cockerill FR 3rd, Steckelberg JM. Frequency of isolation of *Staphylococcus lugdunensis* among staphylococcal isolates causing endocarditis: a 20-year experience. *J Clin Microbiol* 2000; 38: 4262-4263.
8. Seenivasan MH, Yu VL. *Staphylococcus lugdunensis* endocarditis—the hidden peril of coagulase-negative staphylococcus in blood cultures. *Eur J Clin Microbiol Infect Dis* 2003; 22: 489-491.
9. German GJ, Wang B, Bernard K, Stewart N, Chan F, Pacheco AL, et al. *Staphylococcus lugdunensis*: low prevalence and clinical significance in a pediatric microbiology laboratory. *Pediatr Infect Dis J* 2013; 32: 87-89.
10. Anguera I, Del Río A, Miró JM, Martínez-Lacasa X, Marco F, Gumá JR, et al. *Staphylococcus lugdunensis* infective endocarditis: description of 10 cases and analysis of native valve, prosthetic valve, and pacemaker lead endocarditis clinical profiles. *Heart* 2005; 91 (2): e10.