

Probable haloperidol decanoate-induced fever in an African American with benign ethnic neutropenia: A case report

Lara Youniss, BS, BA¹

Michele Thomas, PharmD, BCPP²

Erica A. K. Davis, PharmD, BCPS, BCPP³

How to cite: Youniss L, Thomas M, Davis EAK. Probable haloperidol decanoate-induced fever in an African-American with benign ethnic neutropenia: A case report. *Ment Health Clin* [Internet]. 2021;11(5):301-4. DOI: 10.9740/mhc.2021.09.301.

Submitted for Publication: May 6, 2021; **Accepted for Publication:** July 30, 2021

Abstract

We present a case in which a patient developed fever and leukocytosis subsequent to each monthly haloperidol decanoate injection, an adverse reaction that does not meet the diagnostic criteria of neuroleptic malignant syndrome (NMS) or any previously reported adverse reaction for this medication. A patient being treated with haloperidol decanoate for psychosis experienced a fever within 3 days of injection and leukocytosis along with swelling, pain, and a “knot” feeling at the injection site. This recurred after each injection for several months. Muscle rigidity or changes in vital signs other than temperature were not noted. Temperature and injection site reactions resolved with administration of acetaminophen and ibuprofen. The elevation in temperature was discovered as a result of universal twice daily temperature monitoring implemented due to the COVID-19 pandemic. Reports of fever with antipsychotics are typically associated with NMS or heat stroke; the details of this case do not meet the clinical criteria for either. Similar reactions are reported for other antipsychotics, such as clozapine and olanzapine, but not for haloperidol. The recommendation was to discontinue use of the medication due to an unclear mechanism of the reaction.

Keywords: haloperidol decanoate, fever, leukocytosis, neuroleptic malignant syndrome

¹ Student, University of Maryland, College Park, Maryland, ORCID: <https://orcid.org/0000-0001-7238-2325>; ² (Corresponding author) Director of Pharmacy, University of Maryland, Baltimore School of Pharmacy, Baltimore, Maryland; Springfield Hospital Center, Sykesville, Maryland, michele.thomas@maryland.gov, ORCID: <https://orcid.org/0000-0002-8632-0974>; ³ Clinical Psychiatric Pharmacist, University of Maryland, Baltimore School of Pharmacy, Baltimore, Maryland; Springfield Hospital Center, Sykesville, Maryland, ORCID: <https://orcid.org/0000-0003-2167-1121>

characterized by muscular rigidity, altered mental status, and autonomic dysfunction.¹ The onset of NMS generally occurs within weeks of medication initiation although it may occur at any time. It is believed that the dopamine D₂ receptor blockade causes a decrease in central dopaminergic activity, leading to these symptoms. This case presents a unique reaction to an antipsychotic with fever that is dissimilar to previously reported reactions to haloperidol decanoate.

Background

Generally, when individuals taking antipsychotics or other dopamine antagonists present with hyperthermia, neuroleptic malignant syndrome (NMS) is suspected. Early recognition of NMS is important due to its potentially life-threatening effects.¹ In addition to hyperthermia, NMS is

Case Report

The individual was a 24-year-old African American male inpatient at a state psychiatric facility. His psychiatric diagnoses included unspecified schizophrenia and psychosis as well as alcohol, cannabis, and nicotine use disorders.



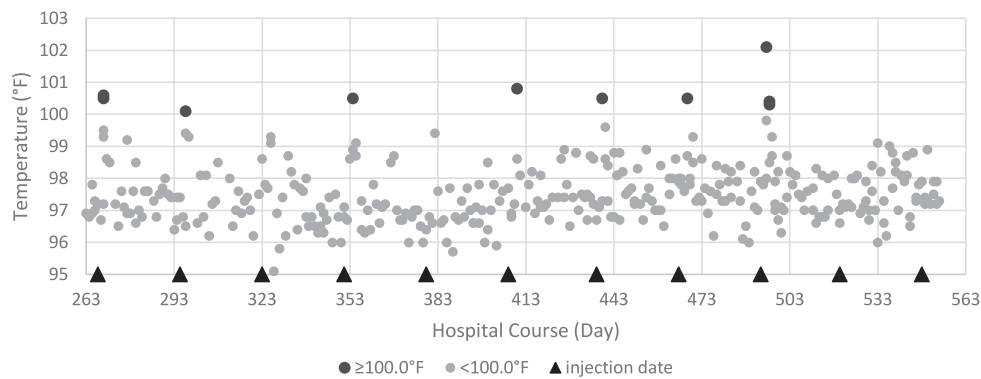


FIGURE 1: Temperatures and haloperidol decanoate injections

His somatic diagnoses included benign ethnic neutropenia and constipation. During the time of this report, his psychiatric medications included haloperidol decanoate 300 mg IM every 28 days in the deltoid and quetiapine 800 mg PO at 9 PM for the past 1.5 years. His somatic medications included polyethylene glycol, docusate, and benztropine. During a previous admission, the patient received daily PO haloperidol (maximum 40 mg/d) but did not receive decanoate. He had no known food or drug allergies. Both haloperidol decanoate and quetiapine were continued at these doses throughout the duration of this case report.

As part of the hospital’s routine vital sign monitoring, monthly temperatures were recorded for the patient from hospital day (HD) 1-263. With the local onset of the COVID-19 pandemic, daily temperatures were recorded starting on HD 263. Because of the increased frequency in temperature monitoring, a pattern began to emerge in which the patient’s temperature was noted to be elevated shortly after receiving his haloperidol decanoate injections (Figure 1). Upon questioning, the patient reported feeling feverish after injections since the beginning of haloperidol decanoate therapy, but no fevers were recorded due to the infrequency of temperature monitoring prior to the COVID-19 pandemic. He also reported that there was usual injection site pain, swelling, and a “knot” feeling that resolved within a few days. During the time of the

fever, muscle rigidity or mental status changes were not observed. Out of the 11 haloperidol injections after initiation of daily temperature monitoring, a temperature of greater than or equal to 100.0°F occurred after 7 injections, each within 2 or 3 days. After each of these occurrences, he received 1 to 2 doses of acetaminophen, and the temperature returned to baseline until the next injection. No other doses of acetaminophen were utilized until the administration of the last 2 recorded haloperidol decanoate doses (HD 520 and 548). At this point, ibuprofen and acetaminophen were given prior to the injection and for the 3 days following as a preventative measure. This was effective against fever and the other adverse reactions he previously experienced, including the knot and swelling at the injection site. Unfortunately, no haloperidol levels were drawn, preventing further evaluation of why this may have occurred.

Additionally, the patient was started on clozapine on HD 387, reaching a maximum dose of 200 mg/d and discontinued on HD 503 due to no significant improvement in behaviors or delusions since initiation. During this time, weekly CBC counts were drawn to monitor absolute neutrophil count as a routine part of clozapine therapy at initiation. Thus, WBC counts are available during this time period, allowing analysis during haloperidol decanoate therapy (Figure 2). By tracking WBC levels, another pattern emerged of elevated counts within 5 days of medication

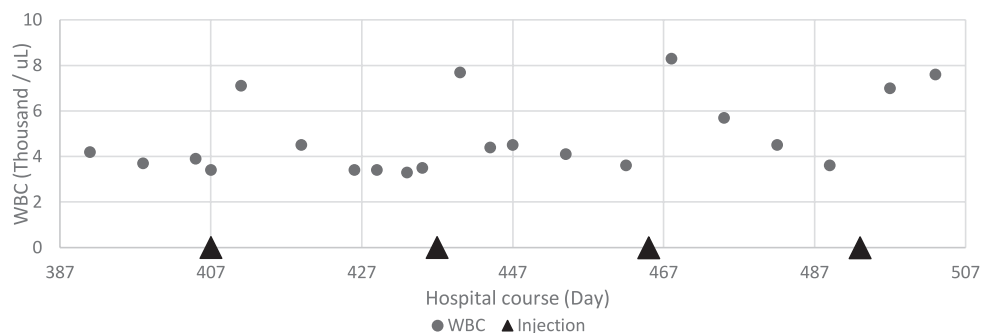


FIGURE 2: WBC level and haloperidol decanoate injections

administration with a subsequent decrease that trends slightly higher than the previous month's baseline. It is important to note that this patient had benign ethnic neutropenia, which accounts for his baseline low WBC.

Aside from fever and injection site reactions, there were generally no other somatic complaints besides 1 headache on HD 354. The patient tested negative for COVID-19 multiple times as well as negative for a COVID-19 serology test on HD 551. He tested negative for influenza A/B on HD 497. Additionally, C-reactive protein levels were found to be elevated twice (HD 355 and 363), but no additional levels are available after a normal level obtained on HD 378. Creatine phosphokinase levels were not obtained due to an absence of muscle rigidity.

One consideration was that this adverse reaction could be occurring with any intramuscular injection because this trend was not observed when he was receiving only oral haloperidol. However, the patient received his first COVID-19 vaccination on HD 565, denied any adverse reactions, did not develop a fever postvaccination, and no acetaminophen or ibuprofen was given.

Discussion

Usually, the first diagnostic thought upon presentation of fever after antipsychotic administration would be NMS, but this case presents a different manifestation of adverse drug effects than those previously known. Although there are many reports of fever and NMS due to antipsychotics, there are very few reports on antipsychotic-associated fevers in the absence of NMS. Clozapine- and, less frequently, olanzapine-related fevers are reported, thought to be due to the effects on temperature-sensitive neurons in the hypothalamus, due to either increased inflammatory cytokines or dopaminergic antagonism although the exact mechanism is unknown.²⁻⁵ Despite the potential for haloperidol to have these same effects on the body's thermoregulatory center, there are very few reports of haloperidol-associated fevers without NMS. Bach and Ryback⁶ describe a case of hyperthermia and elevated creatine phosphokinase levels in a patient receiving oral haloperidol but note that this was during a heat wave. Other cases describe patients on psychiatric medications who experienced heat stroke after exposure to excessively warm ambient temperatures.^{7,8}

After injection, the plasma concentration of haloperidol peaks in 3 to 9 days, and the half-life is about 3 weeks although it may be longer in African Americans.^{9,10} With NMS, one would expect to see symptoms such as hyperthermia, leukocytosis, and autonomic dysfunction, such as tachycardia and hypertension, on or after that peak. For this patient, these symptoms happen at 2 or 3

days after injection and promptly resolve, providing some evidence against NMS, with which the symptoms would be expected to last longer. Furthermore, the few recorded instances of hypertension and tachycardia do not meet the established diagnostic criteria for NMS in the absence of muscle rigidity, autonomic instability, and altered mental status.¹¹ Additionally, the return of symptoms with each dose and subsequent resolution with time do not indicate NMS or heat stroke.

Sahan¹² describes a case of a patient with haloperidol lactate-related neutropenia, which resolved with filgrastim and changing to quetiapine. In comparison, the patient reported here showed leukocytosis and slight neutrophilia with administration of the decanoate formulation. Although the fever was alleviated with acetaminophen and ibuprofen pretreatment, it is unknown if the white blood cell levels were affected due to lack of follow-up labs after clozapine discontinuation. It is also unclear whether clozapine treatment could have affected the trend seen.

Using Naranjo's algorithm,¹³ haloperidol decanoate's causative effects of these adverse reactions are probable. However, no fever was seen when the patient was taking PO haloperidol during a previous admission. There is the potential that the reaction was caused by something in the decanoate preparation that is not present in the oral formulations. Ottervanger et al¹⁴ describe a patient who developed fever with a neuroleptic, likely as a reaction to the solvent in the sustained-action formulation of the medication. Unfortunately, further details on the specific medication or preparation cannot be discovered because the article is not available in English. As the patient described in the above case report has never trialed another long-acting formulation of a different antipsychotic, there is not enough information to draw a conclusion.

Due to this adverse reaction and the lack of clarity on its cause, we recommended the discontinuation of haloperidol decanoate in favor of another medication that has proved effective in previous admissions. The reaction was also reported to the FDA MedWatch reporting system.

Conclusion

Overall, this case report demonstrates a unique adverse drug reaction to an antipsychotic that presents as a fever after each monthly administration of haloperidol decanoate, accompanied by leukocytosis. The pattern for drug-induced fever was not discovered until mandatory hospital-wide daily temperature and symptom monitoring began with the rise of the COVID-19 pandemic. Due to the well-characterized presentation of this reaction and lack

of clarity about the mechanism by which it acts, discontinuation of haloperidol decanoate therapy was recommended.

References

1. Berman BD. Neuroleptic malignant syndrome: a review for neurohospitalists. *Neurohospitalist*. 2011;1(1):41-7. DOI: [10.1177/1941875210386491](https://doi.org/10.1177/1941875210386491). PubMed PMID: [23983836](https://pubmed.ncbi.nlm.nih.gov/23983836/); PubMed Central PMCID: [PMC3726098](https://pubmed.ncbi.nlm.nih.gov/PMC3726098/).
2. Ferreira TF, Godinho FDG, Dehanov SD, Trancas B, Maia T. Olanzapine-induced fever. *Prim Care Companion CNS Disord*. 2019;21(1):18lo2332. DOI: [10.4088/pcc.18lo2332](https://doi.org/10.4088/pcc.18lo2332). PubMed PMID: [30817864](https://pubmed.ncbi.nlm.nih.gov/30817864/).
3. Yang C-H, Chen Y-Y. A case of olanzapine-induced fever. *Psychopharmacol Bull*. 2017;47(1):45-7. PubMed PMID: [28138204](https://pubmed.ncbi.nlm.nih.gov/28138204/).
4. Kluge M, Schuld A, Schacht A, Himmerich H, Dalal MA, Wehmeier PM, et al. Effects of clozapine and olanzapine on cytokine systems are closely linked to weight gain and drug-induced fever. *Psychoneuroendocrinology*. 2009;34(1):118-28. DOI: [10.1016/j.psyneuen.2008.08.016](https://doi.org/10.1016/j.psyneuen.2008.08.016). PubMed PMID: [18835660](https://pubmed.ncbi.nlm.nih.gov/18835660/).
5. Szota A, Ogotdek E, Araszkiwicz A. Fever development in neuroleptic malignant syndrome during treatment with olanzapine and clozapine. *Pharmacol Rep*. 2013;65(2):279-87. DOI: [10.1016/S1734-1140\(13\)71004-1](https://doi.org/10.1016/S1734-1140(13)71004-1). PubMed PMID: [23744413](https://pubmed.ncbi.nlm.nih.gov/23744413/).
6. Bach DS, Rybak MJ. Haloperidol-associated hyperthermia. *Drug Intell Clin Pharm*. 1985;19(3):211. DOI: [10.1177/106002808501900313](https://doi.org/10.1177/106002808501900313). PubMed PMID: [3979264](https://pubmed.ncbi.nlm.nih.gov/3979264/).
7. Sarnquist F, Larson CP. Drug-induced heat stroke. *Anesthesiology*. 1973;39(3):348-50. DOI: [10.1097/0000542-197309000-00023](https://doi.org/10.1097/0000542-197309000-00023). PubMed PMID: [4728582](https://pubmed.ncbi.nlm.nih.gov/4728582/).
8. Bark NM. Heatstroke in psychiatric patients: two cases and a review. *J Clin Psychiatry*. 1982;43(9):377-80. PubMed PMID: [6126476](https://pubmed.ncbi.nlm.nih.gov/6126476/).
9. Correll CU, Kim E, Sliwa JK, Hamm W, Gopal S, Mathews M, et al. Pharmacokinetic characteristics of long-acting injectable antipsychotics for schizophrenia: an overview. *CNS Drugs*. 2021;35(1):39-59. DOI: [10.1007/s40263-020-00779-5](https://doi.org/10.1007/s40263-020-00779-5). PubMed PMID: [33507525](https://pubmed.ncbi.nlm.nih.gov/33507525/).
10. de Leon J, Diaz FJ, Wedlund P, Josiassen RC, Cooper TB, Simpson GM. Haloperidol half-life after chronic dosing. *J Clin Psychopharmacol*. 2004;24(6):656-60. DOI: [10.1097/01.jcp.0000145340.53417.ca](https://doi.org/10.1097/01.jcp.0000145340.53417.ca). PubMed PMID: [15538130](https://pubmed.ncbi.nlm.nih.gov/15538130/).
11. Pope HG Jr, Keck PE Jr, McElroy SL. Frequency and presentation of neuroleptic malignant syndrome in a large psychiatric hospital. *Am J Psychiatry*. 1986;143(10):1227-33. DOI: [10.1176/ajp.143.10.1227](https://doi.org/10.1176/ajp.143.10.1227). PubMed PMID: [2876647](https://pubmed.ncbi.nlm.nih.gov/2876647/).
12. Sahan E. Haloperidol-related neutropenia. *Indian J Psychiatry*. 2019;61(3):307-10. DOI: [10.4103/psychiatry.IndianJPsychiatry_152_18](https://doi.org/10.4103/psychiatry.IndianJPsychiatry_152_18). PubMed PMID: [31142911](https://pubmed.ncbi.nlm.nih.gov/31142911/); PubMed Central PMCID: [PMC6532458](https://pubmed.ncbi.nlm.nih.gov/PMC6532458/).
13. Naranjo CA, Busto U, Sellers EM, Sandor P, Ruiz I, Roberts EA, et al. A method for estimating the probability of adverse drug reactions. *Clin Pharmacol Ther*. 1981;30(2):239-45. DOI: [10.1038/clpt.1981.154](https://doi.org/10.1038/clpt.1981.154). PubMed PMID: [7249508](https://pubmed.ncbi.nlm.nih.gov/7249508/).
14. Ottervanger JP, Gerbrandy-Colijn A, Stricker BH. Fever caused by neuroleptics. *Ned Tijdschr Geneesk*. 1992;136(46):2285-7. PubMed PMID: [1461294](https://pubmed.ncbi.nlm.nih.gov/1461294/).