

Case report

Bilateral interstitial keratitis, erythema nodosum and atrial fibrillation as presenting signs of polyarteritis nodosa

Filippos Vingopoulos^a, Theodoros Karagiotis^b, Sotiria Palioura^{c,*}^a National and Kapodistrian University of Athens School of Medicine, Athens, Greece^b St. Elisabeth-Krankenhaus Köln-Hohenlind General Hospital, Cologne, Germany^c Athens Vision Eye Institute, Athens, Greece

A B S T R A C T

Purpose: To report a case of Polyarteritis Nodosa (PAN) presenting as bilateral episcleritis and interstitial keratitis along with erythema nodosum and atrial fibrillation and to review the ophthalmic literature on PAN with anterior segment findings

Observations: A 35-year old man presented with a two-month history of bilateral episcleritis, skin lesions consistent with erythema nodosum, joint effusions and episodes of prolonged diarrhea and atrial fibrillation. Ophthalmic examination was significant for bilateral diffuse episcleral injection and nummular corneal stromal infiltrates. The patient underwent an extensive infectious and inflammatory work-up that was negative except for a very elevated erythrocyte sedimentation rate (123 mm/h, normal < 20 mm/h) and C-reactive protein (51 mg/L, normal < 5 mg/L). In order to rule out inflammatory bowel disease upper endoscopy and colonoscopy were performed. Biopsies of the gastrointestinal mucosa were positive for a small- and medium-vessel necrotizing vasculitis consistent with polyarteritis nodosa. Disease control was achieved with systemic prednisone and azathioprine. Upon self-tapering both medications the patient developed hearing loss and interstitial keratitis recurred, hence the diagnosis of Cogan's syndrome/PAN was made. Intravenous pulse steroids were administered with resolution of his symptoms. The patient continues to be on azathioprine without disease recurrence for 1.5 years. A review of the ophthalmic literature on PAN with anterior segment findings revealed only 10 cases; of these, 6 had originally presented with ocular manifestations alone (scleritis, peripheral ulcerative keratitis, episcleritis, dacryoadenitis) and 4 of these 6 were lethal due to delay in diagnosis.

Conclusion and importance: Early diagnosis of PAN is crucial, as the five-year mortality rate is close to 90%; upon initiation of systemic immunosuppression the mortality rate drops to 20%. Though PAN manifestations in the anterior segment are rare, a high index of suspicion is warranted in cases of bilateral episcleritis and interstitial keratitis.

1. Introduction

The term interstitial keratitis refers to non-ulcerating inflammation of the corneal stroma without prior involvement of either the epithelium or the endothelium.¹ It is an immune-mediated process thought to be caused by a cellular and humoral response against antigens in the corneal stroma, residual infectious antigens or both.¹ This intralamellar infiltration of lymphocytes is clinically seen as nummular stromal infiltrates.¹ When longstanding, interstitial keratitis leads to corneal stromal neovascularization.

The differential diagnosis of interstitial keratitis includes both infectious and inflammatory etiologies. Congenital syphilis, Lyme disease, tuberculosis, herpes simplex and varicella zoster virus are the major infectious causes, while sarcoidosis, rheumatoid arthritis, Sjogren's syndrome, inflammatory bowel disease, polyangiitis with granulomatosis, Behçet's disease and Cogan's syndrome/polyarteritis nodosa constitute the inflammatory ones.¹

Given the life-threatening nature of several of the above conditions,

appropriate and timely work-up is of utmost importance. Herein we describe a case of polyarteritis nodosa (PAN) that presented as bilateral episcleritis and interstitial keratitis along with systemic symptoms.

2. Case report

A 35-year old Greek man living in Germany presented with a two-month history of bilateral injection, photophobia and foreign body sensation. Over the last year and prior to initiation of his ocular symptoms he had an episode of prolonged diarrhea, followed by atrial fibrillation, skin lesions consistent with erythema nodosum (Fig. 1A) and occasional knee and ankle edema (Fig. 1B). He also reported recurrent oral ulcers since childhood and a recent genital ulcer.

Prior treatment regimens with topical antibiotics (polymyxin B, chloramphenicol) and oral acyclovir had failed to improve his symptoms. The patient reported some response to topical corticosteroids with immediate relapse upon their discontinuation. He brought recent records of negative serology for hepatitis B, C and HIV and of a negative

* Corresponding author. CEBT Athens Vision Eye Institute, 328-330 Syngrou Ave, Athens, 17673, Greece.

E-mail addresses: sotiria.palioura@gmail.com, sotiria.palioura@gmail.com, xsp3131@med.miami.edu (S. Palioura).

<https://doi.org/10.1016/j.ajoc.2020.100619>

Received 13 September 2018; Received in revised form 27 August 2019; Accepted 12 February 2020

Available online 21 February 2020

2451-9936/© 2020 The Authors. Published by Elsevier Inc. This is an open access article under the CC BY-NC-ND license

(<http://creativecommons.org/licenses/by-nc-nd/4.0/>).

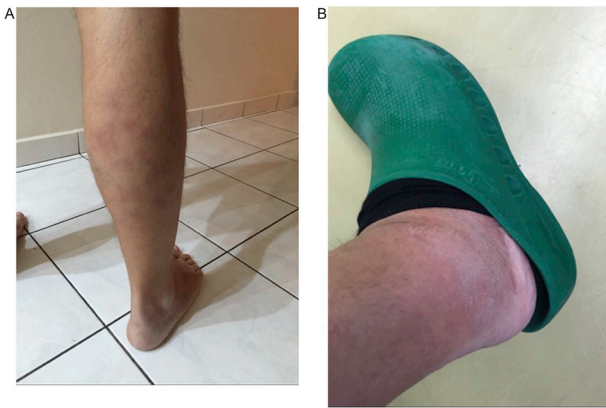

Fig. 1. External photograph of the patient's right calf reveals (A) multiple non-ulcerated erythematous nodules consistent with erythema nodosum two months prior to presentation, and (B) significant ankle edema two weeks prior to presentation.

rheumatologic work-up that included testing for anti-nuclear antibodies, rheumatoid factor, anti-dsDNA, anti-Smith, anti-Scl-70, anti-centromere, anti-SSA/Ro, anti-SSB/La, anti-Jo-1, anti-U1-RNP and anti-phospholipid antibodies. ACE and lysozyme levels were normal and chest CT was clear.

On presentation, visual acuity was 20/20 in both eyes and intraocular pressures were within normal limits. Slit lamp examination revealed bilateral diffuse episcleral injection (Fig. 2A) that blanched with topical phenylephrine, small nummular corneal stromal infiltrates and a few fine stellate keratic precipitates (Fig. 2B). No cells were

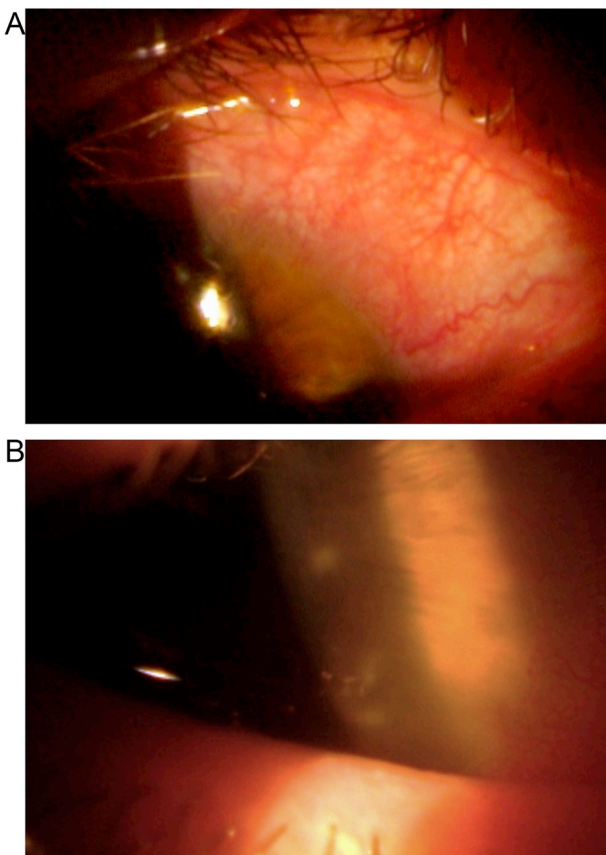


Fig. 2. Slit lamp photograph of the patient's right eye reveals (A) diffuse episcleral injection, and (B) small nummular corneal stromal infiltrates at higher magnification.

detected in the anterior chamber. Dilated fundoscopic examination was normal.

The diagnosis of bilateral interstitial keratitis and episcleritis was made and a systemic infectious and inflammatory work-up was undertaken. Our patient had an elevated C-reactive protein (CRP) level of 51 mg/L (normal < 8.0) and an elevated erythrocyte sedimentation rate (ESR) of 123 mm/h (normal < 22). Serology for syphilis, Lyme disease and testing for tuberculosis with interferon-gamma release assay (IGRA) were all negative. Rheumatoid factor, pANCA, cANCA, HLA-B51, HLA-B27, and pathergy test were also negative. Knee and ankle ultrasounds revealed joint effusions.

Upper endoscopy and colonoscopy were subsequently performed to rule out inflammatory bowel disease. Although the gastrointestinal mucosal lining appeared healthy, random biopsies were taken and revealed segmental non-granulomatous necrotizing transmural inflammation of medium- and small-sized vessels consistent with polyarteritis nodosa (PAN).

The patient received systemic prednisone and was also placed on azathioprine after the histopathologic diagnosis of PAN. Upon self-tapering his steroids and stopping azathioprine, he developed hearing loss and recurrent interstitial keratitis. He was immediately treated with intravenous pulse steroids, which led to symptom resolution within a few days. The diagnosis of Cogan's syndrome/PAN was made and the patient has been on azathioprine and a tapering dose of systemic corticosteroids for the past 1.5 years without recurrence.

3. Discussion

Polyarteritis nodosa is an uncommon systemic vasculitis characterized by subacute, chronic, episodic and segmental necrotizing inflammation of medium- and small-sized arteries. Early diagnosis of PAN is crucial as the five-year mortality rate for untreated PAN is close to 90%.² Ocular involvement is present in 10–20% of patients with PAN and it usually manifests as retinal or choroidal vasculitis.^{2–9} In the rheumatology literature, a recent retrospective study of 1286 patients with systemic necrotizing vasculitides that were entered into the French Vasculitis Study Group database over a span of 53 years (1955–2008) identified 393 patients diagnosed with PAN as per the 1990 American College of Rheumatology criteria.^{3,10} Forty-two patients (42/393 or 10.7%) had ophthalmologic manifestations at diagnosis with the most common being blurred vision (13/42), retinal exudates (8/42) and conjunctivitis (8/42).³ “Keratitis” was seen in three patients though the type of keratitis is not specified nor is the co-occurrence of episcleritis, conjunctivitis, uveitis or retinal vasculitis in these patients.

In the ophthalmic literature, we were able to identify only 10 cases of PAN with well-documented anterior segment findings (Table 1).^{6,11–18} Only cases with either a definitive histopathologic diagnosis of PAN or fulfilling the 1990 American College of Rheumatology criteria for PAN were included in Table 1. Cases not confirmed by the aforementioned diagnostic means were excluded.^{19–21} Seven were women and three were men. Median age at diagnosis was 60 years (range, 23 to 84). Ocular manifestations included conjunctival nodules (n = 1)¹² episcleritis (n = 1)¹¹, episcleritis and dacryoadenitis (n = 1),¹⁴ scleritis (n = 2)^{6,13}, peripheral ulcerative keratitis (n = 3)^{6,17–18}, and scleritis and peripheral ulcerative keratitis (n = 2).^{15,16} Five of the seven patients with scleritis and/or peripheral ulcerative keratitis had bilateral involvement.^{6,16–18} Nine of the ten patients had inflammation solely in the anterior segment,^{6,11,12,14–18} while one patient had severe scleritis that extended from the limbus up to 8 mm posteriorly and secondary exudative retinal detachment.¹³ Six patients had presented with ocular manifestations prior to any other systemic signs of the disease.^{6,11,14,16–18} Delay in diagnosis led to the death of four of these six patients due to systemic vasculitic complications several months after ophthalmologic care was originally sought.^{11,14–18} In three patients diagnosis was made at autopsy^{16–18}, in five by biopsy (skin, n = 2; leg muscle, n = 1; skin and conjunctiva, n = 1; lacrimal gland,

Table 1
Review of polyarteritis nodosa cases with anterior segment findings in the ophthalmic literature.

Author	Age (yrs) Gender	Presenting Sign of Systemic Disease	Ophthalmic Manifestation	pANCA	Lethal	Diagnosis	Ocular Outcome
Yamamoto et al. (2000) ¹¹	71 M	Unilateral episcleritis	Unilateral episcleritis	Positive	Yes	1990 American College of Rheumatology Criteria ¹⁰	20/20
Akova et al. (1993) ⁶	56 F 23 F	Bilateral scleritis, weight loss Bilateral peripheral ulcerative keratitis	Bilateral scleritis Bilateral peripheral ulcerative keratitis	N/A Positive	No No	Skin Nodule Biopsy Skin Nodule Biopsy	20/40 in both eyes 20/40 and 20/60 Penetrating keratoplasties
Purcell et al. (1984) ¹² Kieler RA (1976) ¹³	72 F 84 M	Hemoptysis, weight loss, weakness Weight loss, leg pain	Unilateral conjunctival nodules and iritis Unilateral scleritis and exudative retinal detachment	N/A N/A	Yes No	Skin and Conjunctiva Biopsy Leg Muscle Biopsy	20/40 Enucleation of blind painful eye
Maclure et al. (1968) ¹⁴	60 M	Unilateral dacryoadenitis, nodular episcleritis	Unilateral dacryoadenitis, nodular episcleritis	N/A	Yes	Lacrimal Gland Biopsy	20/30
Moore et al. (1966) ¹⁵	75 F	Weight loss, malaise	Unilateral scleritis and peripheral ulcerative keratitis	Positive	Yes	Histopathology of Enucleated Eye	Enucleation after scleral perforation
Cogan DG (1955) ¹⁶	50 F	Bilateral scleritis and peripheral ulcerative keratitis	Bilateral scleritis and peripheral ulcerative keratitis	N/A	Yes	Autopsy	N/A
Wise et al. (1952) ¹⁸	65 F	Bilateral peripheral ulcerative keratitis	Bilateral peripheral ulcerative keratitis	N/A	Yes	Autopsy	Enucleation of blind right eye, Chronic retinal detachment left eye
Goar et al. (1952) ¹⁷	31 F	Fever, weight loss	Bilateral peripheral ulcerative keratitis	N/A	Yes	Autopsy	N/A

M, male; F, female; pANCA, perinuclear anti-neutrophil cytoplasmic antibodies; N/A, test result is unknown (not done or not reported).

n = 1)^{6,12-14} in one by histopathology after enucleation of the involved eye¹⁵, and in one by use of the 1990 American College of Rheumatology criteria for the classification of vasculitides.¹¹ The ocular disease resulted in loss of vision and eventual enucleation in three patients^{13,15,18} and bilateral tectonic lamellar keratoplasties followed by optical penetrating keratoplasties in one patient⁶, while four patients maintained good vision after systemic treatment (range, 20/20 to 20/40).^{6,11-12 14} pANCA was tested in three patients and found positive in all three of them.^{6,11,15}

To our knowledge, this is the first case of PAN presenting as bilateral episcleritis and interstitial keratitis. Since our patient did not have active skin disease at the time ophthalmologic consultation was sought, diagnosis ended up being established through biopsies of healthy-appearing colonic mucosa during colonoscopy that aimed to rule out inflammatory bowel disease as the cause of the patient's ocular signs and symptoms. Notably, though prior cases of PAN with anterior segment findings were pANCA positive (see Table 1), pANCA was negative in our patient.

Finally, upon self-tapering his steroids and stopping his immunomodulatory therapy, our patient developed recurrent interstitial keratitis and new onset hearing loss as is commonly seen in Cogan's syndrome.²² The inner ear manifestations of Cogan's syndrome are Ménière-like attacks consisting of vertigo, tinnitus, and hearing loss. Approximately 70% of the patients diagnosed with Cogan's syndrome have an underlying vasculitic disorder with the histopathological findings of Cogan's syndrome being very similar to PAN.²³ Thus, it is thought that Cogan's syndrome and PAN might constitute the same entity with Cogan's syndrome/PAN being a variation of PAN affecting the inner ear and the eye.²²⁻²⁴ Treatment of Cogan's syndrome/PAN includes systemic corticosteroids coupled with chronic immunomodulatory therapy to suppress the potentially life-, sight- and hearing-threatening effects of the systemic vasculitis.^{23,25}

4. Conclusion

Though PAN manifestations in the anterior segment are rare, bilateral episcleritis and interstitial keratitis especially when coupled with systemic signs and symptoms should raise suspicion for this autoimmune systemic vasculitis. Early diagnosis of PAN and subsequent initiation of systemic immunosuppression is crucial in preventing the sight-threatening complications of the vasculitis and, more importantly, in substantially improving survival as the five-year mortality rate of untreated PAN is close to 90%.

Patient consent

Written consent to publish potentially identifying information, such as details of the case and photographs, was obtained from the patient.

Funding

None.

Authorship

All authors attest that they meet the current ICJME criteria for Authorship.

Declaration of competing interest

All authors have no financial disclosures.

Appendix A. Supplementary data

Supplementary data to this article can be found online at <https://doi.org/10.1016/j.ajoc.2020.100619>.

References

1. Schwartz GS, Harrison AR, Holland EJ. Etiology of immune stromal (interstitial) keratitis. *Cornea*. 1998;17(3):278–281.
2. De Virgilio A, Greco A, Magliulo G, et al. Polyarteritis nodosa: a contemporary overview. *Autoimmun Rev*. 2016;15(6):564–570.
3. Rothschild PR, Pagnoux C, Seror R, et al. Ophthalmologic manifestations of systemic necrotizing vasculitides at diagnosis: a retrospective study of 1286 patients and review of the literature. *Semin Arthritis Rheum*. 2013;42(5):507–514.
4. Sampson R. Periarteritis nodosa affecting the eye. *Br J Ophthalmol*. 1945;29(6):282–288.
5. Boeck J. Ocular changes in periarteritis nodosa. *Am J Ophthalmol*. 1956;42:567–577.
6. Akova YA, Jabbur NS, Foster CS. Ocular presentation of polyarteritis nodosa. Clinical course and management with steroid and cytotoxic therapy. *Ophthalmology*. 1993;100(12):1775–1781.
7. Hsu CT, Kerrison JB, Miller NR, et al. Choroidal infarction, anterior ischemic optic neuropathy, and central retinal artery occlusion from polyarteritis nodosa. *Retina*. 2001;21(4):348–351.
8. Emad Y, Basaffar S, Ragab Y, et al. A case of polyarteritis nodosa complicated by left central retinal artery occlusion, ischemic optic neuropathy, and retinal vasculitis. *Clin Rheumatol*. 2007;26(5):814–816.
9. Leung AC, McLay A, Boulton-Jones JM. Polyarteritis presenting with thrombocytosis and central retinal vein thrombosis. *Scot Med J*. 1987;32(1):24–26.
10. Fries JF, Hunder GG, Bloch DA, et al. The American College of Rheumatology 1990 criteria for the classification of vasculitis. summary. *Arthritis Rheum*. 1990;33(8):1135–1136.
11. Yamamoto S, Takeuchi S. Episcleritis as the primary clinical manifestation in a patient with polyarteritis nodosa. *Jpn J Ophthalmol*. 2000;44(2):151–153.
12. Purcell Jr JJ, Birkenkamp R, Tsai CC. Conjunctival lesions in periarteritis nodosa. A clinical and immunopathologic study. *Arch Ophthalmol*. 1984;102(5):736–738.
13. Kielar RA. Exudative retinal detachment and scleritis in polyarteritis. *Am J Ophthalmol*. 1976;82(5):694–698.
14. Maclure GM. Polyarteritis nodosa, with an unusual ocular presentation. *Br J Ophthalmol*. 1968;52(2):141–148.
15. Moore JG, Sevel D. Corneo-scleral ulceration in periarteritis nodosa. *Br J Ophthalmol*. 1966;50(11):651–655.
16. Cogan DG. Corneoscleral lesions in periarteritis nodosa and Wegener's granulomatosis. *Trans Am Ophthalmol Soc*. 1955;53:321–344.
17. Goar EL, Smith LS. Polyarteritis nodosa of the eye. *Am J Ophthalmol*. 1952;35(11):1619–1625.
18. Wise GN. Ocular periarteritis nodosa; report of two cases. *AMA Arch Ophthalmol*. 1952;48(1):1–11.
19. Oliner L, Taubenhaus M, Shapira TM, et al. Nonsyphilitic interstitial keratitis and bilateral deafness (Cogan's syndrome) associated with essential polyangitis (periarteritis nodosa); a review of the syndrome with consideration of a possible pathogenic mechanism. *N Engl J Med*. 1953;248(24):1001–1008.
20. Boyd GG. Cogan's syndrome; report of two cases with signs and symptoms suggesting periarteritis nodosa. *AMA Arch Otolaryngol*. 1957;65(1):24–25.
21. Crawford WJ. Cogan's syndrome associated with polyarteritis nodosa; a report of three cases. *Pa Med J*. 1957;60(7):835–838.
22. Cogan DG. Syndrome of nonsyphilitic interstitial keratitis and vestibuloauditory symptoms; a long-term follow-up. *Arch Ophthalmol*. 1945;33:144–149.
23. St Clair EW, McCallum RM. Cogan's syndrome. *Curr Opin Rheumatol*. 1999;11(1):47–52.
24. Cogan DG, Sullivan Jr WR. Immunologic study of nonsyphilitic interstitial keratitis with vestibuloauditory symptoms. *Am J Ophthalmol*. 1975;80:491–494.
25. D'Aguzzo V, Ralli M, de Vincentis M, et al. Optimal management of Cogan's syndrome: a multidisciplinary approach. *J Multidiscip Healthc*. 2018;11:1–11.