


## CLINICAL ARTICLE

# Retrospective Comparative Study of Pedicle Screw Fixation *via* Quadrant Retractor and Buck's Technique in the Treatment of Adolescent Spondylolysis

Yueyang Li, MD, Haiyin Li, MD, Xian Chang, MD, Zhilei Hu, MD, Xuesong Mu, MD, Chenhao Liu, MD, Xiaoxin Gao, MD, Yuyao Zhang, MD, Yue Zhou, MD, Changqing Li, MD 

*Department of Orthopedics, Army Medical University, Chongqing, China*

**Objective:** To compare the effectiveness and practicality of pedicle screw fixation *via* the Quadrant retractor and Buck's technique in the treatment of adolescent spondylolysis.

**Methods:** A total of 31 patients who underwent pedicle screw fixation or Buck's technique at our hospital from 2012 to 2017 were selected for this retrospective study. The patients were divided into a pedicle screw group (16 patients) and a Buck's technique group (15 patients) according to surgical procedure. Age, sex, disease duration, involved segments, preoperative Oswestry disability index (ODI) scores, visual analogue scale (VAS) scores for low back pain (LBP), intraoperative blood loss, incision length, operative time and length of hospital stay were documented. ODI scores, VAS scores for LBP and fusion rates at 1 month, 6 months, 1 year and 3 years postoperatively were used to evaluate surgical outcomes.

**Results:** The average follow-up period was  $32.75 \pm 11.99$  months in the pedicle screw group and  $31.02 \pm 9.64$  months in the Buck's technique group. No significant differences in demographic data and perioperative data were found between the two groups ( $P > 0.05$ ). The ODI scores and VAS scores for LBP in both groups were significantly improved at 3 years postoperatively compared with the values before surgery (ODI%:  $45.74 \pm 2.47$  vs  $10.99 \pm 3.00$ ;  $45.29 \pm 6.94$  vs  $15.73 \pm 6.89$ . VAS:  $5.94 \pm 0.68$  vs  $1.50 \pm 0.52$ ;  $6.13 \pm 0.74$  vs  $2.13 \pm 0.92$ ,  $P < 0.05$ ). The ODI scores of the patients in the pedicle screw group at 1 month to 3 years postoperatively were lower than those of the patients in the Buck's technique group ( $P < 0.05$ ). Moreover, the VAS scores for LBP of the patients in the pedicle screw group at 6 months and 3 years postoperatively were lower than those of the patients in the Buck's technique group ( $P < 0.05$ ). No significant difference in the VAS scores for LBP was found between the two groups at 1 month postoperatively ( $3.88 \pm 0.50$  vs  $4.20 \pm 0.56$ ,  $P = 0.10$ ). Three years postoperatively, good fusion of the pars interarticularis was achieved in all patients in the pedicle screw group, but four patients in the Buck's technique group did not achieve good fusion ( $P = 0.02$ ).

**Conclusion:** Both pedicle screw fixation and Buck's technique can achieve good outcomes in the treatment of adolescent spondylolysis. Pedicle screw fixation *via* the Quadrant retractor for the treatment of spondylolysis is associated with more satisfactory effects in terms of LBP relief and fusion results.

**Key words:** Adolescent; Buck's technique; Pedicle screw system; Spondylolysis

**Address for correspondence** Changqing Li, MD, Department of Orthopedics, Army Medical University, Chongqing, 40000, China Tel: 86-23-68774328; Email: changqli1970@126.com

**Disclosure:** The authors declare that the article content was composed in the absence of any commercial or financial relationships that could be construed as a potential conflict of interest.

Received 28 August 2020; accepted 16 September 2021

Orthopaedic Surgery 2022;14:111-118 • DOI: 10.1111/os.13165

This is an open access article under the terms of the Creative Commons Attribution-NonCommercial-NoDerivs License, which permits use and distribution in any medium, provided the original work is properly cited, the use is non-commercial and no modifications or adaptations are made.

## Introduction

Lumbar spondylolysis, which can be unilateral or bilateral, is a fracture between the upper and lower articular processes of the vertebral pedicle<sup>1</sup>. In the early stages, spondylolysis is assumed to be a fracture caused by repeated minor trauma or a single traumatic accident. The high prevalence in some populations and the high familial predisposition may indicate that spondylolysis has a genetic predisposition. Lumbar spondylolysis is common in adolescents, with an incidence of approximately 6% in this population. More than 4% of the population was diagnosed before 7 years old and few were diagnosed after 18 years old. Spondylolysis occurs in the L<sub>5</sub> segment in approximately 85%–95% of cases<sup>2</sup>. Lumbosacral pain is the most common symptom of lumbar spondylolysis<sup>3</sup>, and approximately 25% of patients have at least one significant episode of lumbar pain throughout the course of the disease<sup>4</sup>. However, most patients do not have radiating pain in the lower limbs. Therefore, most patients are incidentally diagnosed with spondylolysis during the treatment of low back pain (LBP)<sup>5</sup>. Computed tomography (CT) is the most accurate method for diagnosing spondylolysis<sup>6</sup>. Radiography is used as a supplement to CT scans. Magnetic resonance imaging (MRI) can be used to detect disc degeneration in the involved segments and adjacent segments. Spondylolysis is primarily treated with open surgery, which includes Buck's technique, fixation with a pedicle screw and V-rod system, fixation with a pedicle screw hook system, etc.<sup>7–11</sup>.

Among these approaches, pars screw fixation (Buck's technique) was first described by Buck in 1970 and this technique has been used for 50 years<sup>12</sup>. Its effectiveness and safety have been confirmed by extensive studies. In addition, Buck's technique has advantages including preservation of segment motion, a quick recovery after surgery and minimal blood loss. However, current studies have generally found that poor fusion is associated with Buck's technique. Accurate placement of the pars screws and assurance of pars fusion are the most difficult aspects of the surgery and the assurance of pars fusion. Displacement of the pars screws results in poor fusion and intractable low back pain<sup>10</sup>. Therefore, the learning curve of Buck's technique can be lengthy.

The pedicle screw system improved the disadvantage of the postoperative low fusion rate. The strong grasping of the pedicle screw itself and the squeezing effect of the screw system on the isthmus bone graft ensures the fusion of the isthmus. At present, there are some reports on the pedicle screw V-rod system and the hook system. Follow-up results of these two systems have indicated good postoperative recovery. However, due to the open nature of the operation, excessive paraspinal muscle injury can cause the slow relief of postoperative low back pain. Therefore, This study intended to repair spondylolysis with the pedicle screw system *via* a minimal approach. There have been few reports on pedicle screw fixation *via* the Quadrant retractor for the treatment of adolescent spondylolysis.

The aim of this study was: (i) to compare LBP relief in patients treated with Buck's technique and the pedicle screw

system according to clinical data including the Oswestry disability index (ODI) and visual analogue scale (VAS) scores; (ii) to compare the fusion rates of patients who underwent the two types of surgery *via* CT scans at 3 years postoperative; and (iii) to demonstrate the safety and efficiency of the use of the pedicle screw system with a minimal approach by comparing the clinical and radiological data of patients.

## Material and Methods

### General Data

Patients were consecutively enrolled. The Inclusion criteria were as follows: (i) an initial diagnosis of spondylolysis; (ii) patients who had undergone minimally invasive pedicle screw surgery or Buck's technique; (iii) the Oswestry disability index (ODI), the visual analogue scale (VAS) scores and the fusion of the pars interarticularis were considered as the comparison; and (iv) patients with complete follow-up outcomes and a follow-up time of a minimum of 3 years. The exclusion criteria were as follows: (i) patients who were responded to the conservative treatment; (ii) patients who were not between 11–18 years old; (iii) patients with symptoms of nerve compression; (iv) patients who had factors indicative of spinal instability, such as spina bifida or spondylolisthesis; (v) patients with preoperative degeneration of the intervertebral disc; (vi) patients who had undergone other spinal surgery; (vii) patients with spinal infections; and (viii) patients with spinal tumors.

All patients underwent diagnostic blockade, radiography, CT and MRI before surgery. According to the inclusion and exclusion criteria, a total of 31 patients who were diagnosed with adolescent spondylolysis at our hospital from 2012 to 2017 were selected for this retrospective study. The patients were divided into a pedicle screw group and a Buck's technique group. Sixteen patients were included in the pedicle screw group and 15 patients were included in the Buck's technique group.

### Surgical Procedure

#### *Pedicle Screw Fixation via the Quadrant Retractor*

**Anesthesia and position.** The patient was placed in the prone position under general anesthesia, C-arm fluoroscopy was performed to locate the involved segments, and the projection of the segments was marked on the body surface.

**Approach and exposure.** The surgical field was disinfected and draped. A 3- to 5-cm incision was made at a site 2–3 cm lateral to the spine. The skin, subcutaneous tissue and thoracolumbar fascia were incised in layers. A guide rod was placed. Sequential dilation of the incision was performed using dilating trocars. The Quadrant retractor was placed with installation of the free arm and the light source to expose the target pars interarticularis. The scar tissue, callus and hardened tissue were scraped until bleeding was observed on the surface of the pars interarticularis.

**Bone grafting.** A 2- to 3-cm incision was made in the anterior superior iliac spine, and a 2 × 2 × 3-cm bone block was harvested from the anterior superior iliac spine and

implanted in the defect site. The retractor system was removed. The same method described above was used to expose the other side of the pars interarticularis and to remove scar tissue, hardened tissue and callus. The bone graft was implanted in the defect site using the same method ( Fig. 1).

**Pedicle screws implantation.** Though the incision, a puncture needle was used to puncture through the vertebral pedicle. Under fluoroscopy, puncture needle position was confirmed. A guided wire was installed and the puncture needle was withdrawn. Through the guide wire, four pedicle screws were implanted with the installation of a titanium rod. C-arm fluoroscopy was performed to confirm the desired position of the pedicle screw, and then a drainage tube was placed. The incision was closed in layers.

### **Buck's Technique**

**Anesthesia and position.** The patient was placed in the prone position under general anesthesia, C-arm fluoroscopy was performed to locate the involved segments, and the projection of the segments was marked on the body surface. The surgical field was disinfected and draped.

**Approach and exposure.** A 5-cm incision was made through the posterior median approach. The skin, subcutaneous tissue and thoracolumbar fascia were incised in layers. The supraspinous ligament was incised, and the paravertebral muscles were stripped from the spinous process and lamina to expose the pars interarticularis. The scar tissue, callus and hardened tissue were scraped till bleeding appeared on the surface of the pars interarticularis.

**Bone grafting.** A 2- to 3-cm incision was made in the anterior superior iliac spine, and a  $2 \times 2 \times 3$ -cm bone block was harvested from the anterior superior iliac spine and implanted in the defect site.

**Pars screws implantation.** Pars screws were placed in both sides of the fractured pars interarticularis. After C-arm fluoroscopy was performed to confirm the desired position of the pars screw, a drainage tube was placed. The incision was closed in layers (Fig. 1).

### **Observation Indicators**

#### *Follow-up*

The patients were followed up for at least 3 years. The data for the follow-ups performed preoperatively and at 1 months, 6 months and 1 year postoperatively and the data for the 3 years postoperatively follow-up were assessed. The patients who could not be contacted by telephone or mail or had not been evaluated again after the operation were considered to have missed a visit.

#### *Demographic Data*

The demographic data of the two groups of patients, including age, sex, disease duration and the involved segments, were recorded. Demographic information was retrieved from the follow-up database in our hospital. The demographic data were compared between the two groups to exclude the influence of demographic factors on the results, and the comparability between the two groups was increased.

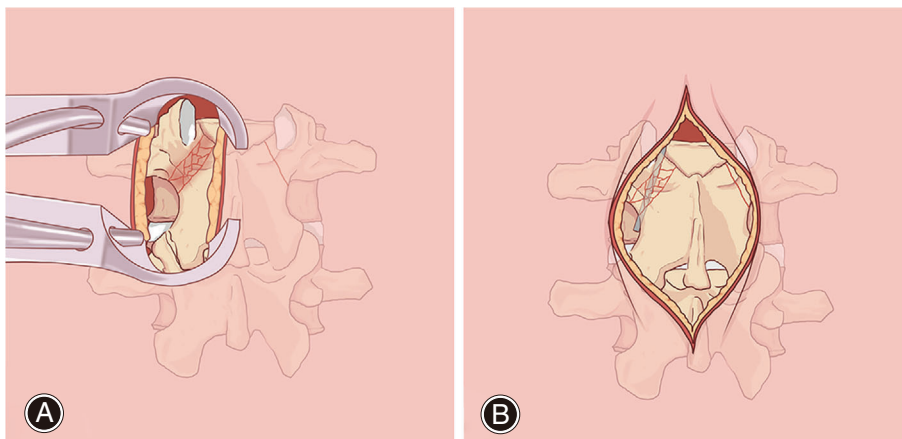
#### *Perioperative Data*

Perioperative data included intraoperative blood loss, the length of hospital stay, incision length and the operative time. All the perioperative data were obtained from the records in the operating room of our hospital or through case data query. To compare the efficiency and safety of the two surgery techniques, the two operations were compared using the perioperative data. Meanwhile, using the perioperative data, this study also evaluated the effect of minimal invasive surgery and open surgery on postoperative rehabilitation of patients.

### **Clinical Data**

#### *Oswestry Disability Index Scores*

The ODI scores were used to evaluate the preoperative and postoperative quality of life of patients. The ODI scores are based on 10 questions, each with a possible score of five points, resulting in a total of 50 points. Because all of the



**Fig 1** The surgical procedure for pedicle screw fixation via the Quadrant retractor and Buck's technique. (A) A  $2 \times 2 \times 3$ -cm bone block was harvested from the anterior superior iliac spine and implanted at the defect site via the Quadrant retractor. (B) Pars screws were placed in the fractured pars interarticularis and a  $2 \times 2 \times 3$ -cm bone block implanted at the defect site.

included patients were teenagers, data on sexual activity were not available. Therefore, the total score was 45 points<sup>13</sup>. ODI scores were collected through questionnaires. Data were collected preoperatively and at 1 month, 6 months, 1 year and 3 years postoperatively. The effectiveness of the two types of surgeries for relieving LBP was examined by comparing the changes in ODI scores between the two groups.

#### Visual analogue Scale Scores

The VAS scores were evaluated based on the patients' own perception of pain. The VAS scores ranged from 0 to 10, with 0 indicating no pain and 10 indicating severe pain. The VAS scores were acquired at similar time points to the ODI scores. Differences in LBP relief were assessed by comparing the changes in the VAS scores between two groups.

#### Radiological Data

The patients underwent follow-up CT at 6 months, 1 year and 2 years postoperatively. The imaging data were collected and measured in the imaging department of our hospital. All imaging data were measured by experienced surgeons and imaging physicians. The results were discussed and revised to obtain the final uniform results. The radiological data were set as the criteria for evaluating isthmus fusion. The criteria for pars interarticularis fusion were as follows: (i) the hypodense area in the pars interarticularis disappeared, and trabecular bone formation was noted; and (ii) good continuity without an osteolytic zone was noted in the pars interarticularis and the bone graft.

#### Statistical Analysis

Statistical data are expressed as the mean  $\pm$  standard deviation. SPSS (version 23.0, IBM Chicago, IL, USA) was used for the statistical analysis. The *t* test was used to compare the data with a normal distribution and the homogeneity of variance between the two groups. Repeated analysis of variance (ANOVA) was used to compare the ODI and VAS scores for LBP at different time points (the least significant difference (LSD) method was used for the intragroup comparisons). The  $\chi^2$  test was used to compare count data. Nonparametric tests were used to compare data without a normal distribution but with homogeneity of variance.

## Results

#### Follow-up

The average follow-up period was  $32.75 \pm 11.99$  months in the pedicle screw group and  $31.02 \pm 9.64$  months in the Buck's technique group. All patients were followed up.

#### General Result

The demographic data of the 31 patients with spondylolysis who were treated from 2012 to 2017 were collected retrospectively. The patients were randomly divided into a pedicle screw group (16 patients, including 10 boys and six girls) and a Buck's technique group (15 patients, including 12 boys

**TABLE 1** Demographic data of the pedicle screw group and the Buck's technique group

Variable	Pedicle Screw Group	Buck's Technique Group	P value
Age (years), SD	15.06 $\pm$ 0.62	14.20 $\pm$ 0.68	0.68
Sex			0.50
Male	10	12	-
Female	6	3	-
Duration of pain (days), SD	166.25 $\pm$ 105.38	145.33 $\pm$ 127.89	0.25
Level			0.94
L <sub>4</sub>	2	3	-
L <sub>5</sub>	14	12	-
Perioperative data			
ODI (%)	45.74 $\pm$ 2.47	45.29 $\pm$ 6.94	0.81
VAS of the lower back	5.94 $\pm$ 0.68	6.13 $\pm$ 0.74	0.45

Scores are the mean  $\pm$  standard deviation. The values are given as the mean and standard deviation.; ODI, Oswestry disability index; VAS, visual analogue scale.

and three girls). The demographic data of the two groups are shown in Table 1. No significant difference in demographic data was found between the two groups ( $P > 0.05$ ).

#### Perioperative Result

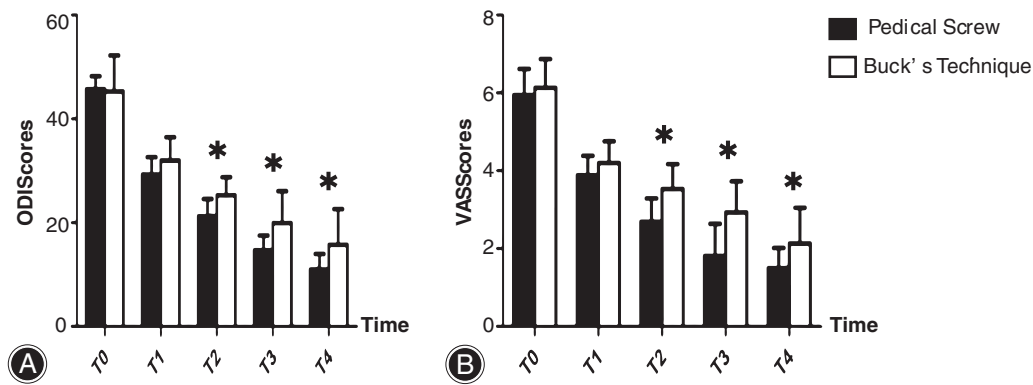
Regarding the perioperative data of the pedicle screw group and the Buck's technique group, blood loss was  $159.16 \pm 132.01$  mL and  $125.33 \pm 70.18$  mL, respectively; the length of hospital stay were  $12.69 \pm 7.65$  days and  $12.07 \pm 2.66$  days, respectively; the incision length were  $4.16 \pm 1.48$  cm and  $5.10 \pm 2.38$  cm, respectively; and the operative times were  $165.56 \pm 35.66$  min and  $216.67 \pm 62.60$  min, respectively. No significant difference in the perioperative data was found between the two groups ( $P > 0.05$ ).

#### Clinical Results

##### Oswestry Disability Index scores

The changes over time in the ODI scores in the pedicle screw system and Buck's technique groups are shown in Fig. 2. In both groups, the postoperative ODI and VAS scores for LBP decreased over time. The ODI scores at preoperatively, 1 month postoperatively, 6 months postoperatively, 1 year postoperatively, 3 years postoperatively were  $45.74 \pm 2.47$ ,  $29.30 \pm 3.31$ ,  $21.23 \pm 3.35$ ,  $14.66 \pm 2.88$  and  $10.99 \pm 3.00$  in the pedicle screw group, and  $45.29 \pm 6.94$ ,  $31.98 \pm 4.47$ ,  $25.29 \pm 3.48$ ,  $19.93 \pm 6.15$  and  $15.73 \pm 6.89$  in Buck's technique group. The ODI scores changed over time were significant for each follow-up interval in the two groups ( $P < 0.05$ ).

As to a comparison of ODI scores between the two groups. No significant difference in preoperative and



**Fig 2** The changes in the ODI and VAS scores for LBP in the pedicle screw group and Buck's technique group. \* represents that the comparison between the two groups indicated statistical difference. (A) The ODI changes in the pedicle screw group and the Buck's technique group. (B) Changes in the VAS scores for LBP in the pedicle screw group and the Buck's technique group. T0-T4 represent the time periods: preoperative, 1 month postoperatively, 6 months postoperatively, 1 year postoperatively and 3 years postoperatively, respectively.

1 month postoperative ODI scores for LBP was found between the two groups ( $45.74 \pm 2.47$  vs  $45.29 \pm 6.94$ ,  $P = 0.81$ ;  $29.30 \pm 3.31$  vs  $31.98 \pm 4.47$ ,  $P = 0.07$ ). Comparisons of the ODI scores between the two groups at 6 months postoperatively ( $P = 0.00$ ), 1 year postoperatively ( $P = 0.00$ ) and 3 years postoperatively ( $P = 0.02$ ) indicated significant differences ( $P < 0.05$ ).

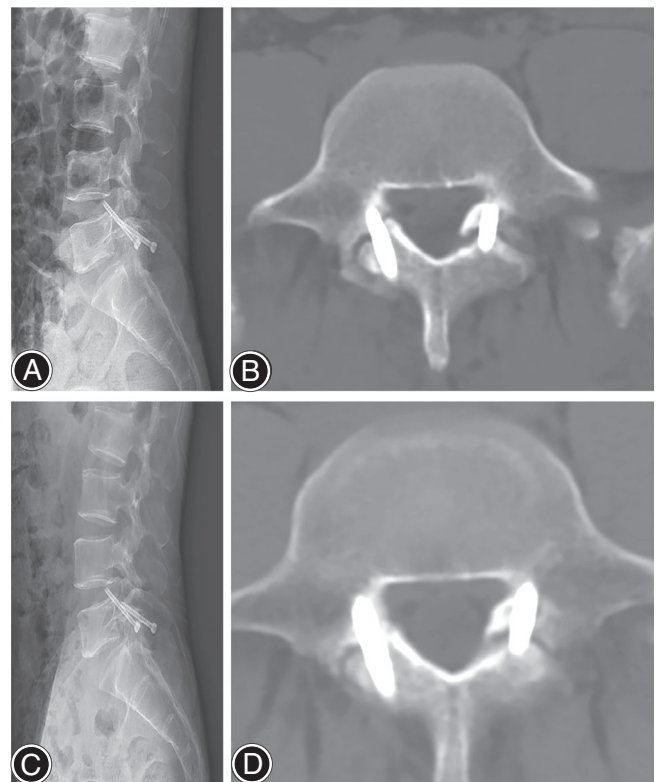
#### Visual analogue Scale Scores

The changes in VAS scores for LBP over time in the two groups are shown in Fig. 2. The trend of changes was similar to that of the ODI scores. However, in the pedicle screw group, there was no significant difference in VAS scores for LBP between 1 and 3 years postoperatively ( $1.81 \pm 0.83$  vs  $1.50 \pm 0.52$ ,  $P = 0.10$ ). For the other follow-up intervals in the two groups, the VAS scores for LBP changes over time were significant ( $P < 0.05$ ).

As to a comparison of VAS scores for LBP. No significant difference in the VAS scores for LBP was observed between the two groups preoperatively and at 1 month postoperatively ( $5.94 \pm 0.68$  vs  $6.13 \pm 0.74$ ,  $P = 0.45$ ;  $3.88 \pm 0.50$  vs  $4.20 \pm 0.56$ ,  $P = 0.10$ ). However, comparisons of the VAS scores for LBP between the two groups at 6 months postoperatively ( $P = 0.00$ ), 1 year postoperatively ( $P = 0.00$ ) and 3 years postoperatively ( $P = 0.02$ ) indicated significant differences ( $P < 0.05$ ).

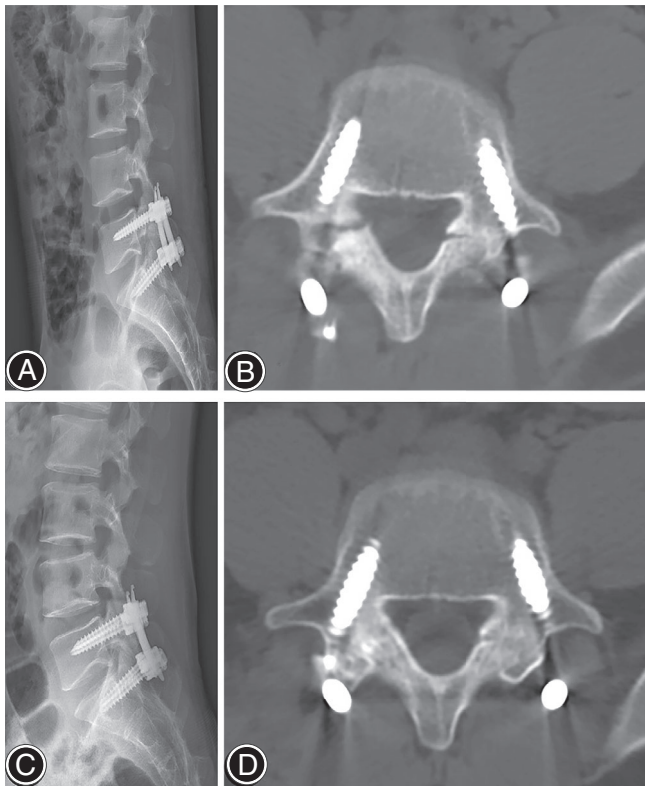
#### Radiological Results

The follow-up CT scans at 6 months, 1 year and 3 years postoperatively showed good fusion of the pars interarticularis in all patients in the pedicle screw group and poor fusion in four patients in the Buck's technique group (Figs 3 and 4). A significant difference in the fusion rate was observed between the two groups ( $P = 0.02$ ). This study separately compared the patients with and without poor fusion. The mean ODI at 3 years postoperatively was  $24.00 \pm 1.41$  and the VAS scores for the low



**Fig 3** The X-ray and CT images of the patient undergoing Buck's technique. The patient showed nonfusion of the pars interarticularis at the 3 years postoperatively follow-up after the Buck's technique. (A, B) were the preoperative X-ray and CT scans of the patient undergoing the Buck's technique. (C, D) were the X-ray and CT images of the patient undergoing the Buck's technique at the 3 years postoperatively follow-up.

back was  $3.20 \pm 0.45$ , which was significantly higher than that for patients who with good fusion ( $P < 0.05$ ) (the ODI% was  $11.23 \pm 3.36$ , and the VAS score was  $5.92 \pm 0.69$ ).



**Fig 4** The X-ray and CT images of the patient undergoing the pedicle screw surgery. The patient showed well fusion of the pars interarticularis at the 3 years postoperatively follow-up after the pedicle screw surgery. (A, B) were the preoperative X-ray and CT scans of the pedicle screw surgery. (C, D) were the X-ray and CT images of the pedicle screw surgery at the 3 years postoperatively follow-up.

### Complications

During the follow-up period, no displacement or rupture of the internal fixation was reported in either group of patients.

### Discussion

Spondylolysis is a form of nonunion caused by a stress fracture between the upper and lower articular processes. A vertebral body with a fracture of the pars interarticularis may exert excessive stress on the intervertebral disc, which may be one of the reasons for LBP in spondylolysis. Conservative treatment (rest, physical therapy, wearing an orthosis, etc.) can usually effectively relieve LBP<sup>14</sup>. Frennered *et al.* has reported that the LBP relief rate in adolescents with spondylolysis is as high as 95% after wearing an orthosis for 3 months<sup>15</sup>. Nevertheless, surgery should be selected for patients who do not respond to conservative treatment after 6 months or experience progressive worsening of LBP. Moreover, because LBP may be a result of mild spondylolisthesis or a degenerated intervertebral disc caused by spondylolysis, it is necessary to perform a blockade of the pars

interarticularis before surgery to confirm that the pain is originating from the fractured pars interarticularis.

One early surgical method is posterolateral fusion surgery<sup>16, 17</sup>. This type of surgery sacrifices segment motion and increases the risk of degeneration of the adjacent vertebral body<sup>18</sup>. In 1968, Kimura proposed repairing the pars defect by bone grafting alone with postoperative cast immobilization of the low back. This idea laid the foundation for the repair of a fractured the pars interarticularis<sup>19</sup>. In 1970, Buck first proposed the use of pars screw fixation (Buck's technique) in addition to bone grafting and reported that the procedure failed in only one out of 16 patients who underwent it<sup>12</sup>. Rajasekaran *et al.* reported that Buck's technique is an effective and feasible surgical method with reduced blood loss that preserves segment motion, but it is not suitable for patients with intervertebral disc degeneration and spondylolisthesis<sup>7</sup>, which is consistent with the results reported by Davidson and Betts, who pointed out that this procedure is only suitable for patients who are younger than 30 years, with a pars defect smaller than 3 or 4 mm and have no spondylolisthesis or spondylolisthesis less than grade 1<sup>20</sup>. The greatest concern with Buck's technique is the low fusion rate. A retrospective study showed that 57% of patients who received reoperation due to nonunion of the pars interarticularis had undergone surgery using Buck's technique<sup>8</sup>. The lower fusion rate in pars screw surgery is associated with the narrow field of view during the procedure, and accurate placement of the pars screws is key in this procedure<sup>21</sup>. Failure to accurately place the pars screws will result in insufficient strength to hold the bone graft within the pars defect, resulting in a decrease in postoperative fusion. Moreover, the implanted pars screw passes through the implant bed and occupies part of the implant bed space, resulting in a reduction in the amount of grafted bone and an insufficient bone graft area<sup>22</sup>. Regarding the long-term follow-up results, patients with poor fusion had significantly higher in ODI and VAS scores than those with good fusion. Kreiner *et al.* reviewed four article of follow-up at least 4 years and suggested that fusion was the key to symptomatic relief in the long-term follow-up<sup>23</sup>. In terms of LBP relief, Buck's technique is an open surgical procedure requiring extensive stripping of the paravertebral muscles, which prolongs the recovery time for the back muscles. Thus, this procedure cannot effectively relieve LBP.

To overcome the shortcomings of the conventional Buck's technique, this study used the Quadrant retractor for pedicle screw fixation. The reported methods for using pedicle screws to repair fractures of the pars interarticularis include segmental fixation with a screw hook system and segmental fixation with a pedicle screw and V-rod system. Chen *et al.* reported that pedicle screw fixation using the pedicle screw and V-rod system successfully fused the fracture sites of the pars interarticularis in all 21 patients in their study and that the average VAS scores for LBP decreased from 7.5 (5–9) preoperatively to 3.04 (2–5) postoperatively and 1.43 (0–3) 6 months postoperatively<sup>9</sup>. A retrospective

study of the screw hook system for pedicle fixation by Debusscher and Troussel showed that approximately 91% of patients achieved good fusion results and that the VAS scores for LBP decreased from an average of 7.75 preoperatively to 1.7 at the 4-year follow-up<sup>10</sup>. However, unstable fixation is a drawback of segmental fixation<sup>11</sup>. The Quadrant retractor is widely used in the surgical treatment of lumbar degenerative disease. Its minimal invasiveness allows patients to recover more quickly postoperatively with fewer complications<sup>24</sup>. Therefore, this study performed pars interarticularis repair with pedicle screw fixation using the Quadrant retractor and achieved satisfactory outcomes. The ODI and VAS scores for LBP showed satisfactory improvement in both groups of patients. Pedicle screw fixation was associated with better relief of LBP than Buck's technique. All patients who underwent pedicle screw fixation achieved satisfactory fusion at the end of the 3-year follow-up, while four patients who underwent Buck's technique had poor fusion. The fusion rate with pedicle screw fixation was higher than that with Buck's technique.

The reason for this difference may be that spondylolysis is pseudarthrosis of the isthmus with failed fracture consolidation. The isthmus fusion requires rigid osteosynthesis with a compression device and sufficient bone graft material. During the surgery, after pedicle screws were implanted, a compressor was installed and the bone graft was compressed. During compression, the lumbar lordosis angle was also restored. Meanwhile, during pedicle screw fixation, the screws did not occupy the bone implant bed. Sufficient space for bone grafting ensured a sufficient bone graft and good healing of the pars interarticularis. After pedicle screw fixation, the affected level still had minimally movement. After 1 year postoperatively, patients were advised to have the pedicle screw removed if the bone union was achieved. There was a hypothesis from this study that the pedicle screw fixation did not harm to the index disc and the adjacent disc. This hypothesis was similar to the reporting of Chen et al. The pedicle screw-V rod system directly repairs the isthmus of the vertebra and the procedure does not impact on adjacent vertebral segments and causes no injury to the diseased intervertebral disc<sup>9</sup>. Furthermore, the Quadrant retractor can provide good illumination, a good visual field and minimal damage to the surrounding tissues, resulting in a faster recovery and pain relief postoperatively. Injury to surrounding tissue and extensive dissection of the paraspinal muscles are among the causes of intractable postoperative LBP. Reducing muscle traction and damage to the posterior branches of spinal nerves plays an important role

in relieving LBP. Wang *et al.* reported a prospective randomized clinical trial which comparing the minimally invasive lumbar interbody fusion through Quadrant retractor *versus* open surgery. They measured the multifidus on MRI, which showed that the T<sub>2</sub> relaxation time in the multifidus muscle was significantly shorter in the minimally invasive surgery (MIS) group than in the open surgery group at 3 months after surgery ( $P < 0.01$ ), and concluded that MIS can effectively reduce sacrospinalis muscle injury compared with open surgery, which is conducive to early functional recovery<sup>24</sup>. The biomechanical changes in the lumbar spine after pedicle screw fixation play a role in relieving LBP. In patients with L<sub>5</sub> spondylolysis, the vertical stress on the lumbar spine is transmitted to the L<sub>5</sub>/S<sub>1</sub> intervertebral disc and then to the sacrum *via* the pedicle screw, which substantially reduces the stress on the intervertebral disc and avoids degeneration of the intervertebral disc postoperatively<sup>9</sup>.

This study had the following limitations: due to the low incidence of adolescent spondylolysis, the sample size was small, which might have caused data bias. Multicenter studies with a large sample size need to be carried out as the next step.

### Conclusion

Pedicle screw fixation *via* the Quadrant retractor to repair spondylolysis is associated with better relief of LBP and better fusion results compared with Buck's technique. Pedicle screw fixation has advantages including less dissection of the paravertebral muscles, a larger bone graft area and better biomechanical effects and is useful for the future development of surgical repair of the pars interarticularis.

### Acknowledgment

This study was supported by the Nature Science Foundation of China (grant number 81572208). All authors contributed to this work. Yueyang Li performed this project and wrote the manuscript. Xuesong Mu and Yuxuan Chen helped with data collection. Wenkai Wang, Zhilei Hu, and Xian Chang helped with calculations and table design. Changqing Li, Yue Zhou and Haiyin Li contributed to project design.

### Authorship Declaration

All authors listed meet the authorship criteria according to the latest guidelines of the International Committee of Medical Journal Editors, and all authors are in agreement with the manuscript.

### References

1. Winter M, Jani L. Results of screw osteosynthesis in spondylolysis and low-grade spondylolisthesis. *Arch Orthop Trauma Surg*, 1989, 108: 96–99.
2. Syrmou E, Tsitsopoulos PP, Marinopoulos D, Tsonidis C, Anagnostopoulos I, Tsitsopoulos PD. Spondylolysis: a review and reappraisal. *Hippokratia*, 2010, 14: 17–21.
3. Patel DR, Kinsella E. Evaluation and management of low back pain in young athletes. *Transl Pediatr*, 2017, 6: 225–235.
4. Ko SB, Lee SW. Prevalence of spondylolysis and its relationship with low back pain in selected population. *Clin Orthop Surg*, 2011, 3: 34–38.
5. Kim MW, Lee KY, Lee S. Factors associated with the symptoms of young adults with L5 spondylolysis. *Asian Spine J*, 2018, 12: 476–483.
6. Bellaache L, Petrover D. Imaging in chronic low back pain: which one and when? *Rev Prat*, 2008, 58: 273–278.

7. Rajasekaran S, Subbiah M, Shetty AP. Direct repair of lumbar spondylolysis by Buck's technique. *Indian J Orthop*, 2011, 45: 136–140.
8. Giudici F, Minoia L, Archetti M, Corriero AS, Zagra A. Long-term results of the direct repair of spondylolisthesis. *Eur Spine J*, 2011, 20: S115–S120.
9. Chen XS, Zhou SY, Jia LS, Gu XM, Fang L, Zhu W. A universal pedicle screw and V-rod system for lumbar isthmic spondylolysis: a retrospective analysis of 21 cases. *PLoS One*, 2013, 8: e63713.
10. Debusscher F, Troussel S. Direct repair of defects in lumbar spondylolysis with a new pedicle screw hook fixation: clinical, functional and Ct-assessed study. *Eur Spine J*, 2007, 16: 1650–1658.
11. Gala RJ, Bovonratwet P, Webb ML, et al. Different fusion approaches for single-level lumbar Spondylolysis have similar perioperative outcomes. *Spine (Phila Pa 1976)*, 2018, 43: E111–E117.
12. Buck JE. Direct repair of the defect in spondylolisthesis. Preliminary report. *J Bone Joint Surg Br*, 1970, 52: 432–437.
13. Tonosu J, Takeshita K, Hara N, et al. The normative score and the cut-off value of the Oswestry disability index (ODI). *Eur Spine J*, 2012, 21: 1596–1602.
14. Bradford DS. Management of spondylolysis and spondylolisthesis. *Instr Course Lect*, 1983, 32: 151–162.
15. Frennered AK, Danielson BI, Nachemson AL. Natural history of symptomatic isthmic low-grade spondylolisthesis in children and adolescents: a seven-year follow-up study. *J Pediatr Orthop*, 1991, 11: 209–213.
16. Hensinger RN. Spondylolysis and spondylolisthesis. *Instr Course Lect*, 1983, 32: 132–151.
17. Pedersen AK, Hagen R. Spondylolysis and spondylolisthesis: treatment by internal fixation and bone-grafting of the defect. *J Bone Joint Surg Am*, 1988, 70A: 15–24.
18. Mihara H, Onari K, Cheng BC, David SM, Zdeblick TA. The biomechanical effects of spondylolysis and its treatment. *Spine (Phila Pa 1976)*, 2003, 28: 235–238.
19. Kimura M. My method of filling the lesion with spongy bone in spondylolysis and spondylolisthesis. *Orthop Surg*, 1968, 19: 285–295.
20. Davidson DC, Betts WJ. Buck's fusion for spondylolisthesis. *J Bone Joint Surg*, 1982, 64-B: 122–123.
21. Lu J1, Ebraheim NA, Biyani A, et al. Screw placement in the lumbar vertebral isthmus. *Clin Orthop Relat Res*, 1997, 338: 227–230.
22. Buck JE. Further thoughts on direct repair of the defect in spondylolysis. *J Bone Joint Surg Br*, 1987, 61: 123.
23. Scott Kreiner D, Jamie Baisden FACS, Mazanec DJ, et al. Guideline summary review: an evidence-based clinical guideline for the diagnosis and treatment of adult isthmic spondylolisthesis. *Spine J*, 2016, 16: 1478–1485.
24. Wang HL, Lü FZ, Jiang JY, et al. Minimally invasive lumbar interbody fusion via MAST quadrant retractor versus open surgery: a prospective randomized clinical trial. *Chin Med J (Engl)*, 2011, 124: 3868–3874.