



Tehran University of Medical
Sciences Publication
<http://tums.ac.ir>

Iran J Parasitol

Open access Journal at
<http://ijpa.tums.ac.ir>



Iranian Society of Parasitology
<http://isp.tums.ac.ir>

Case Report

Trypanosoma evansi and “*Candidatus Mycoplasma haemolamae*” Co-Infection in One-Humped Camel (*Camelus dromedarius*) from the Northwest of Iran: A Case Report

*Bijan ESMAEILNEJAD¹, Aram SAADI², Bahram DALIR-NAGHADEH², Awat SAMIEI¹,
Vahid MOHAMMADI², Ali PIRNEJAD-TALATAPEH³, Shahin EHTESHAMFAR²

1. Department of Pathobiology, Faculty of Veterinary Medicine, Urmia University, Urmia, Iran
2. Department of Internal Medicine and Clinical Pathology, Faculty of Veterinary Medicine, Urmia University, Urmia, Iran
3. Central Laboratory, Faculty of Veterinary Medicine, Urmia University, Urmia, Iran

Received 10 Jan 2018 Accepted 12 Apr 2018	Abstract A 4-year-old male one-humped camel (<i>Camelus dromedarius</i>) was referred to Veterinary Teaching Hospital of Urmia University, Iran in 2017 with anorexia, weakness, depression and pale mucosa. Decreased red blood cell count, packed cell volume and hemoglobin concentration were detected by complete blood cell count. In Giemsa-stained peripheral blood smears <i>Trypanosoma</i> spp. trypomastigotes scattered between erythrocytic spaces and <i>Mycoplasma</i> -like organisms were observed attached to the surface of erythrocytes. Species-specific PCR assay confirmed <i>T. evansi</i> and <i>Candidatus Mycoplasma haemolamae</i> (CMhl) co-infection. Administration of diminazene aceturate, oxytetracycline 20%, flunixin meglumine and phosphorus-vitamin B ₁₂ were not effective in treatment. Hemoplasmosis should be considered as an important differential diagnosis of conditions associated with hemolytic anemia in camel.
Keywords: Dromedary camel; <i>Trypanosoma</i> ; <i>Mycoplasma</i> ; PCR; Iran	
*Correspondence Email: b.esmaeilnejad@urmia.ac.ir	

Introduction

Trypanosoma evansi is a widely-distributed haemoflagellate of veterinary importance that infects a variety of larger mammals including horses, mules, camels, buffalo, cattle and deer and mainly transmitted

by hematophagous flies including, *Tabanus* sp., *Stomoxys* sp., *Lyperosia* sp. and *Haematobia* sp. (1, 2). *T. evansi* infection incurs enormous economic losses including mortality, production losses costs of veterinary diagnosis/treatment

and growth retardation in camel-raising flocks, throughout the tropical and subtropical regions; including Iran, with prevalence rates between 0% and 19.47% (3-5). It also is implicated as a zoonotic agent, causes of public health problem (2, 6).

Hemotropic mycoplasmas (generally less than 1.0 μm in diameter), formerly known as *Eperythrozoon* or *Haemobartonella*, are small epierthrocytic bacterial agents lacking a cell wall. They are found attached to erythrocytes and may be observed free in the plasma of different species of vertebrates, including rodents, ruminants, pigs, alpaca (*Lama pacos*) and llamas. They are regarded as the most pathogenic species in livestock with clinical signs, especially in those with hemolytic anemia (7). *Candidatus Mycoplasma haemolamae* (CMhl) was first described in 1990 in the USA in llamas and reported that CMhl infection alone, contributes to severe hemolytic anemia, fever, jaundice, hemoglobinuria, and weight loss in camelids (8). The present report describes the first case of a hemolytic disorder in an Iranian one-humped camel (*Camelus dromedarius*) co-infected with *T. evansi* and CMhl from north-west of Iran.

Case Presentation

In Jul 2017, a 4-year-old male one-humped camel (*Camelus dromedarius*) from Salmas county, Urmia, Iran belonging to a flock composed of 70 animals was referred to the Veterinary Teaching Hospital of Urmia University, Iran with poor body condition and signs of anorexia, weakness, depression and pale mucosa. According to the farmer, the symptoms started 5 d ago. The camels were reared in the pasture and only brought into the paddock during the night. The flock had no history of vaccination, anti-parasitic treatment, insecticides application or any other medication was recorded. Rectal temperature of the camel was 39.6 °C, heart rate was 50 beats per min and respiratory rate was 15 breaths per min. The body of

camel was inspected carefully for the presence of ectoparasites. Jugular blood samples were taken into vacutainers (Kendall Company, Covidien, USA) containing EDTA-K2 as anticoagulant for determination of hematological and molecular analyses. During examination, the whole body of camel was examined for the presence of ticks by palpation, mainly on their ears, along their nape of neck, perineum, and udder/orchid, between thigh, shoulder region and tail base. The ticks were manually removed and transferred to the parasitology laboratory in tubes containing 70% ethanol solution.

Light microscopic examination of Giemsa stained peripheral blood films revealed the presence *Trypanosoma* spp. trypomastigotes (20×2.2 μm) and *Mycoplasma*-like organisms (up to 0.5 μm) (Fig. 1A). *Mycoplasma* spp. appeared as small, coccoid, basophilic epicellular bodies freely available in plasma or epicellular attached to the surface and periphery of erythrocytes.

Reduced number of RBCs ($3.25 \times 10^6/\mu\text{l}$, reference interval: $6.38 \pm 0.38 \times 10^6/\mu\text{l}$), elevated total leukocyte count ($37 \times 10^3/\mu\text{l}$, reference interval: $12.38 \pm 0.97 \times 10^3/\mu\text{l}$) and decreased hemoglobin concentration (7.4 g/dl, reference interval: 12.00 ± 0.63 g/dl) and low packed cell volume (PCV) (21%, reference interval: $37.21 \pm 2.48\%$) were found in hematological examination (9). Genomic DNA was extracted from 25 μL whole camel blood using a commercially available kit (Thermo Fisher Scientific, Dreieich, Germany) according to the manufacturer's instructions and stored at -80 °C until further use. A pair of primers, CMhl -F 5'- TAG ATT TGA AAT AGT CTA AAT TAA -3' and CMhl -R 5'- AAT TAG TAC AAT CAC GAC AGA ATC -3' were used to amplify a 318 bp fragment of the ssu rRNA gene of CMhl. The primer's specificity and sensitivity were assessed (10). PCR was carried out in 50 μl total reaction volume containing 5 μl of 10 x PCR buffer, 2 mM MgCl_2 , 250 μM of each of the four deoxynucleotide triphosphate, 1.25 U Taq DNA polymerase

(Fermentas, Germany), 50 pmol of each primer and 50 ng of extracted DNA. Amplification of parasite DNA was done in thermocycler CP2-003 (Corbett Research, CP2-003, Australia). Cycling condition for *Candidatus Mycoplasma haemolamae* was 94 °C for 10 min, followed by 32 cycles at 94 °C for 60 sec, 50 °C for 60 sec and 72 °C for 2 min with a final extension step of 72 °C for 70 min. “*Candidatus Mycoplasma haemolamae*” positive control confirmed by GenBank under accession number MF356308. According to the method (11), using a commercially prepared specific primer set (TBr1& TBr 2) that yields a 164 bp product for the specific detection of *T. evansi*. Primer sequences were as follows: TBr1- 5'-GAA TAT TAA ACA ATG CGC AG-3', TBr2- 5'-CCA TTT ATT AGC TTT GTT GC-3'. PCR amplification reaction was carried out in 1x buffer containing 50 mM

KCl, 10 mM Tris- HCl pH 8.3, and 0.1% Triton X-100, enriched with 1.5 mM MgCl 0.2 mM of each dATP, dCTP, dGTP and dTTP (Promega, USA), 25 pmol each primer, 50 ng of genomic DNA and 1.0 U of *Taq* DNA polymerase (Promega, USA). All components were mixed and sterile distilled water was added to a final volume of 50µl. PCR reactions were conducted in thermocycler CP2-003 (Corbett Research, CP2-003, Australia) programmed for an initial denaturation and activation step at 94 °C for 10 min. This step followed by 40 cycles of 94 °C for 30 sec (denaturation), annealing step at 50 °C for 45 sec and extension step at 72 °C for 60 sec. Post-extension was by one cycle at 72 °C for 10 min followed by holding at 4 °C. *T. evansi* positive control (kindly provided by parasitology division of the Bu-Ali Sina University under accession number KR184820 (Fig. 1B).

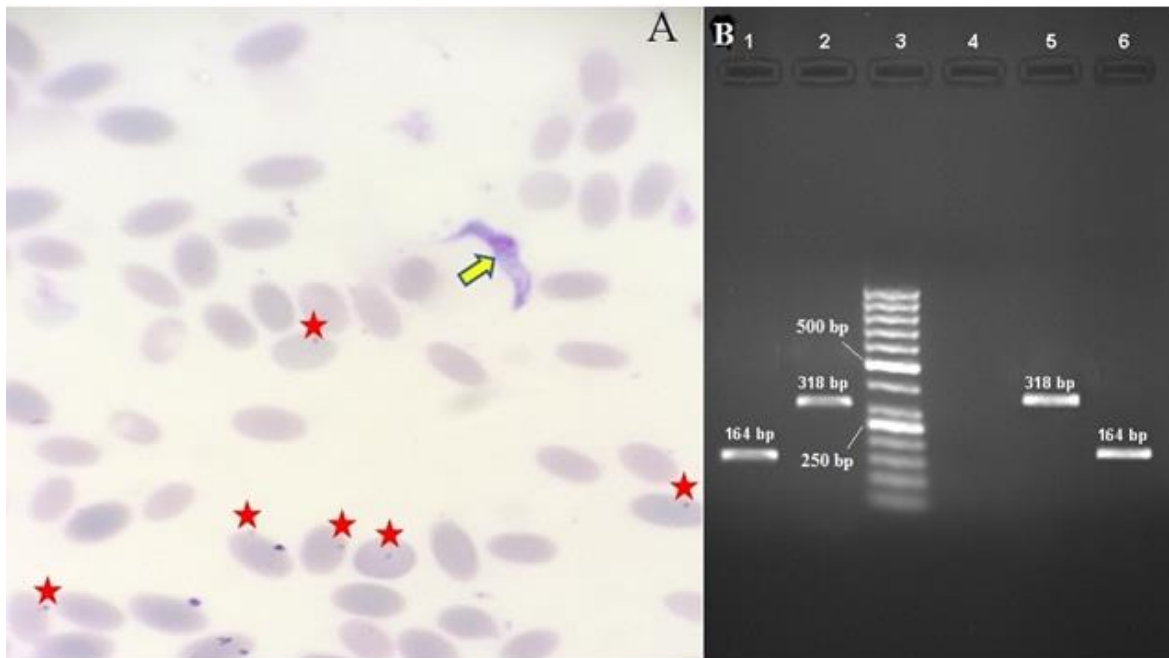


Fig. 1: A) *Trypanosoma evansi* (arrow) and epierythrocytic “*Candidatus Mycoplasma haemolamae*” attached on the surface of camel red blood cells (stars) (Giemsa, 100×). B) Amplified products using *T. evansi* and epierythrocytic “*Candidatus Mycoplasma haemolamae*” specific primers. Lane 1: *T. evansi* infection; Lane 2: “*Candidatus Mycoplasma haemolamae*” infection; Lane 3: 50 bp DNA ladder; Lane 4: Negative control; Lane 5: *Candidatus Mycoplasma haemolamae* positive control; Lane 6: *T. evansi* positive control

Treatment included subcutaneous injection of diminazene aceturate (Aburaihan Co., Tehran, Iran; 7.5 mg kg⁻¹), intramuscular injections of oxytetracycline 20% (Aburaihan Co., Tehran, Iran; 0.2 ml kg⁻¹) and flunixin meglumine (20 ml, Aburaihan Co., Tehran, Iran). Furthermore, phosphorus-vitamin B₁₂ (Aburaihan Co., Tehran, Iran; 0.5 ml kg⁻¹) were prescribed as supportive care subcutaneously. The treatment was relatively efficient in remission of clinical signs for only three days and the animal died 10 d after initiation of treatment.

Twelve adult ticks were collected that the most frequent and abundant tick species found on camel were *Rhipicephalus sanguineus* and *Hyalomma anatolicum anatolicum*.

Discussion

Previous studies from various southern regions of Iran employing PCR reported positive cases of *T. evansi* camels varying from 1.6% to 25.75% (2, 12-15). However; this study is the first molecular identification of causative agent of surra in north-west of Iran. The disease is usually chronic and characterized by fever, anorexia, listlessness, pale mucous membranes, dullness, a very thin hump and drop to one side, abortions in pregnant females, and death in untreated camels (16-18).

Although, infection of camelids by hemomycoplasma has been described previously in camels (*Camelus dromedarius*) from central and south regions of Iran (Yazd and Kerman Provinces) using cytologic and molecular examination (19, 20); however, to the best of the authors' knowledge the present report is the first documented and confirmed case of CMhl infection in Iranian one-humped camels from northern half of Iran. Anemia is a pathognomonic finding of surra and CMhl infections in the camelids. Decreased number of RBCs, hemoglobin concentration and PCV confirmed the occurrences of anemia in this case. These results are in agreement with earlier findings (19, 21). This report was remarkable

in several aspects I) molecular identification of *T. evansi* and *CMhl* co-infection in camel from Iran, II) association of hemoplasma infection with pyrexia and intravascular hemolysis in an in one-humped camel. Since ticks and hematophagous insects are important sources of *Trypanosomes* and CMhl infections in this area, it appears that such infections may be common in camels. The common clinical signs of both infections are fever, pale mucosa, and extremities edema. Since the hemomycoplasmosis is a secondary infection, any kind of stressful, immune suppressing and retarding condition could aggravate the disease.

Rational treatment would appear to consist of correcting the anemia and eliminating of the infection. However, recovery was not achieved by administration of diminazene aceturate, oxytetracycline, and phosphorus-vitamin B12.

Conclusion

Hemoplasmosis should be considered in the differential diagnosis of diseases characterized by hemolytic anemia and pyrexia. The PCR evaluation for hemoplasma DNA should be included in the investigation of such cases to enable the rapid definitive detection of this infection, which may be more common than previously estimated. Conducting further case studies are necessary to recommend successful treatment.

Acknowledgements

The authors would like to thank the Office of the Vice Chancellor for Research of Urmia University for financial support of this study.

Conflict of interest

The authors declare that there is no conflict of interests.

References

1. Desquesnes Marc, Géraldine B, Delphine P et al. First outbreak of *Trypanosoma evansi* in camels in metropolitan France. Vet Rec. 2008; 162(23): 750-752.
2. Sazmand A, Joachim A. Parasitic diseases of camels in Iran (1931–2017)—a literature review. Parasite. 2017; 24:21.
3. Brun R, Hecker H, Lun ZR. *Trypanosoma evansi* and *T. equiperdum*: distribution, biology, treatment and phylogenetic relationship (a review). Vet Parasitol. 1988; 79(2): 95-107.
4. Zakian A, Nouri M, Safaei P et al. An acute outbreak of natural *Trypanosoma evansi* infection in camel (*Camelus dromedarius*) herds in the southwestern Iran. Comp Clin Path. 2017; 26(1):51-9.
5. Khosravi A, Hakimi Parizi M, Bamorovat M et al. Prevalence of *Trypanosoma evansi* in camels using molecular and parasitological methods in the southeast of Iran, 2011. J Parasit Dis. 2015; 39(3): 422–425.
6. OIE Terrestrial manual. *Trypanosoma evansi* infections. Technical Disease Cards, 2008. pp.1–4 (Chapter 8).
7. Reagan W, Garry F, Thrall M et al. The clinicopathologic, light, and scanning electron microscopic features of eperythrozoonosis in four naturally infected llamas. Vet Pathol. 1990; 27(6):426-31.
8. McLaughlin BG, Evans CN, McLaughlin PS et al. An Eperythrozoon-like parasite in llamas. J Am Vet Med Assoc. 1990; 197(9):1170-5.
9. Farooq U, Samad H, Khurshid A, Sajjad S. Normal reference Haematological values of one-humped camels (*Camelus Dromedarius*) kept in Cholistan desert. J Anim Plant Sci. 2011; 21(2):157-60.
10. Tornquist SJ, Boeder LJ, Cebra CK, Messick J. Use of a polymerase chain reaction assay to study response to oxytetracycline treatment in experimental Candidatus *Mycoplasma haemolamae* infection in alpacas. Am J Vet Res. 2009; 70(9):1102-7.
11. Ashour AA, El-Naga TRA, Barghash SM, Salama MS. *Trypanosoma evansi*: Detection of *Trypanosoma evansi* DNA in naturally and experimentally infected animals using TBR 1 & TBR 2 primers. Exp parasitol. 2013; 134(1):109-14.
12. Moghaddar N, Diantpour V. Distribution pattern of *Trypanosoma evansi* in camels (*Camelus dromedarius*) in Iran. J Camel Pract Res. 2009;16(1):73-5.
13. Sazmand A, Rasooli A, Nouri M et al. Serobiochemical alterations in subclinically affected dromedary camels with *Trypanosoma evansi* in Iran. Pak Vet J. 2011; 31(3):223-6.
14. Sazmand A, Eigner B, Mirzaei M et al. Molecular identification of hemoprotozoan parasites in camels (*Camelus dromedarius*) of Iran. Iran J Parasitol. 2016; 11(4), 568–573.
15. Mehrabiyan S, Mahzounieh M, Rabbani-Khorasgani MTH et al. Molecular detection of *Trypanosoma* from one-humped camels slaughtered in Najafabad slaughterhouse. Biol J Micro. 2014; 3(10): 45–50
16. Desquesnes M, Holzmuller P, Lai DH et al. *Trypanosoma evansi* and surra: a review and perspectives on origin, history, distribution, taxonomy, morphology, hosts, and pathogenic effects. Biomed Res Int. 2013; 2013:194176.
17. Lascola K, Vandis M, Bain P, Bedenice D. Concurrent Infection with *Anaplasma phagocytophilum* and *Mycoplasma haemolamae* in a young alpaca. J Vet Intern Med. 2009; 23(2):379-82.
18. Pourjafar M, Badiei K, Sharifiyazdi H et al. Genetic characterization and phylogenetic analysis of *Trypanosoma evansi* in Iranian dromedary camels. Parasitol Res. 2013; 112(2):899-903.
19. Nazifi S, Oryan A, Bahrani S, Razavi S. Evaluation of haematological and serum biochemical parameters in Iranian camels (*Camelus dromedarius*) infected with haemotrophic Mycoplasma (*Eperythrozoon*) spp. Comp Clin Path. 2009; 18(3):329-32.
20. Sharifiyazdi H, Jafari S, Ghane M et al. Genetic characterization and phylogenetic analysis of hemotrophic mycoplasmas in camel (*Camelus dromedarius*). Comp Clin Path. 2018:1-6.
21. Saleh MA, Al-Salahy MB, Sanousi SA. Oxidative stress in blood of camels (*Camelus dromedarius*) naturally infected with *Trypanosoma evansi*. Vet Parasitol. 2009; 162(3):192-9.