

# Extracorporeal Membrane Oxygenation in Severe Acute Respiratory Distress Syndrome Caused by *Chlamydia abortus*: A Case Report

Jiequn Huang<sup>1</sup>, Changzhi Liu<sup>1</sup>, Zhujiang Zhou<sup>1</sup>, Han Xia<sup>2</sup>, Zhensheng Zhu<sup>2</sup>, Jianhai Lu<sup>1</sup>, Jingcheng Lin<sup>1</sup>, Zhen Chen<sup>1</sup>, Qimei Ye<sup>1</sup>, Liuer Zuo<sup>1</sup>

<sup>1</sup>Department of Intensive Care Unit, Shunde Hospital, Southern Medical University (The First People's Hospital of Shunde Foshan), Foshan, Guangdong, People's Republic of China; <sup>2</sup>Department of Scientific Affairs, Hugobiotech Co, Ltd, Beijing, People's Republic of China

Correspondence: Liuer Zuo, Department of Intensive Care Unit, Shunde Hospital, Southern Medical University (The First People's Hospital of Shunde, Foshan), Foshan, Guangdong, People's Republic of China, Email 13500276597@163.com

**Background:** Pneumonia infected by *Chlamydia abortus* (*C. abortus*) is rare, especially complicated with severe acute respiratory distress syndrome (ARDS) and multiple organ dysfunction syndrome (MODS).

**Case Presentation:** We presented the clinical details of a 44-year-old male who was diagnosed with *C. abortus* pneumonia, which rapidly progressed and ultimately led to ARDS, sepsis and MODS. Although he was initially diagnosed with pneumonia upon admission, no pathogenic bacteria were detected in sputum by conventional tests. Empirical intravenous infusion of meropenem and moxifloxacin was administered, but unfortunately, his condition deteriorated rapidly, especially respiratory status. On Day 2 after extracorporeal membrane oxygenation (ECMO) initiation, metagenomic next-generation sequencing (mNGS) was performed on the patient's bronchoalveolar lavage fluid, which indicated an infection with *C. abortus*. The patient's antimicrobial therapy was adjusted to oral doxycycline (0.1g every 12h), intravenous azithromycin (0.5g every day), and imipenem and cilastatin sodium (1g every 6h). The patient's condition improved clinically and biologically. However, the patient was discharged due to financial reasons and unfortunately passed away eight hours later.

**Conclusion:** Infections with *C. abortus* can result in severe ARDS and serious visceral complications which necessitate prompt diagnosis and active intervention by clinicians. The case highlights the significance of mNGS as an essential diagnostic tool for uncommon pathogens. Tetracyclines, macrolides or their combinations are effective choices for treatment of *C. abortus* pneumonia. Further study is needed to explore the transmission routes of *C. abortus* pneumonia and establish precise guidelines for antibiotic treatment.

**Keywords:** *Chlamydia abortus*, ECMO, pneumonia, acute respiratory distress syndrome, metagenomic next-generation sequencing

## Introduction

*Chlamydia abortus* is a non-motile, obligate intracellular Gram-negative bacteria that belongs to the *Chlamydiales* family. It primarily colonizes the placenta of ruminants such as sheep, goats, cattle, pigs, horses, among others, and can cause abortion.<sup>1</sup> Human infections with *C. abortus* are infrequent, but they can result in severe symptoms, especially in pregnant women and immunocompromised individuals, such as abortion, stillbirth, and gestational sepsis.<sup>2</sup> Studies reported that the primary mode of transmission is through direct contact with infected animals or secondary contaminated environments and the oronasal mucosa, and there is little risk of contracting the infection through indirect contact from visiting or living near a farm affected by *C. abortus*.<sup>3,4</sup> Until now, the exact route of infection and the infectious dose for humans remain unclear.

As far as we know, pneumonia is rarely caused by *C. abortus* and there are only five cases have been reported worldwide.<sup>5-9</sup> However, it should be noted that none of these patients received venovenous extracorporeal membrane oxygenation (VV-ECMO), a life-saving rescue therapy for acute respiratory distress syndrome (ARDS) patients when conventional ventilator strategies have proven to be ineffective. Here, we described the first case of severe pneumonia

caused by *C. abortus*, who developed refractory ARDS and was treated with ECMO. The patient received a combination of medical therapy with doxycycline and azithromycin, along with imipenem and cilastatin sodium in China.

## Case Presentation

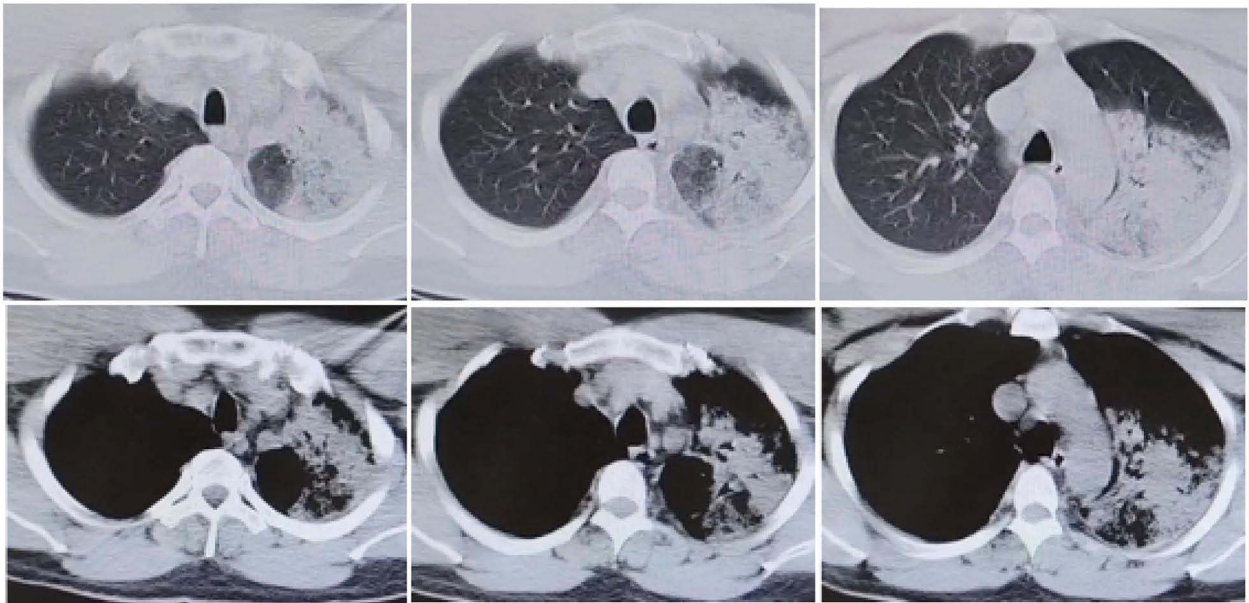
A 44-year-old male, who was a chronic hepatitis B virus carrier with normal liver function, was admitted to the local hospital with a seven-day history of dry cough, shortness of breath and hypodynamia. Three days prior to admission, he experienced frequent coughing with yellow-white sputum and high fever (38.9°C). The patient had a 20-year history of smoking approximately twenty cigarettes daily. Upon querying the patient's wife, we learned that he worked as a handyman but denied recent exposure to sick animals or visiting to farms.

On admission, physical examination showed a temperature of 38.7°C, heart rate of 134/min, respiratory rate of 24/min, blood pressure of 124/70 mmHg, and fine crackles in the left lung. A chest computed tomography (CT) scan demonstrated patchy high-density shadows with blurred margins present in both the posterior segment of the left upper lung and the dorsal segment of the lower lung, which is indicative of pan-lobar pneumonia (Figure 1). Laboratory tests showed slightly elevated leucocyte count ( $10.77 \times 10^9/L$ ), D-dimer and glucose levels (31.21 mg/L and 9.93 mmol/L, respectively), while other indicators such as blood urea nitrogen (27.57 mmol/L), creatinine (576  $\mu\text{mol/L}$ ), C reactive protein ( $>200$  mg/L), procalcitonin (PCT) (36.33  $\mu\text{g/L}$ ), alanine aminotransferase (107 IU/L), aspartate aminotransferase (401 IU/L), lactic dehydrogenase (2119 IU/L), creatine kinase (4620 IU/L), and serum total bilirubin (67.1  $\mu\text{mol/L}$ ) were significantly elevated. In contrast, the serum albumin and serum sodium levels were found to be predominantly decreased to 25.8 g/L (normal: 40–55 g/L) and 128 mmol/L (normal: 137–147 mmol/L), respectively. Arterial blood gas analysis (nasal cannula at 3 L/minute inhalation) showed normal pH (7.45), PaO<sub>2</sub> (71.3mmHg) and blood lactate (1.5mmol/L), decreased PaCO<sub>2</sub> (25.5mmHg) and PO<sub>2</sub>/FiO<sub>2</sub> (216.1mmHg). Samples of sputum, urine and blood were collected for culture, while no pathogenic bacteria, fungi or viruses were found. Acid-fast staining of sputum was negative on three separate occasions. Considering the clinical assessment and the possibility of infection from rare pathogens, the patient was diagnosed with pneumonia, and empiric treatment was initiated with intravenous infusion of meropenem (1g every 8h) and moxifloxacin (0.4 g every day). The clinical course of the patient is depicted in Figure 2.

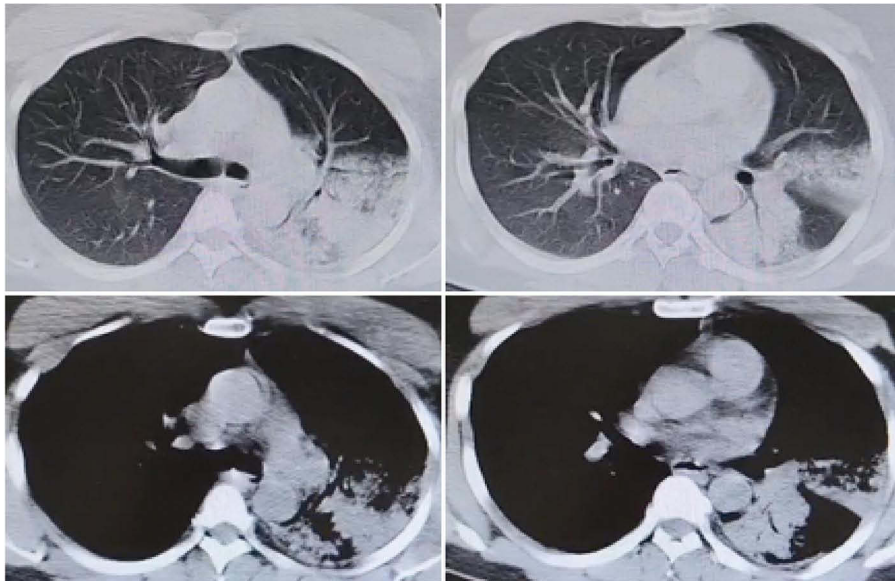
After 6 hours of hospitalization, the patient's respiratory status deteriorated and delirium was observed. As a result, the patient required intubation and ventilator (A/C, FiO<sub>2</sub> 80%, f 15 breaths/min, Vt 480 mL, PEEP 3.0 cmH<sub>2</sub>O). He was then immediately transferred to the intensive care unit (ICU) of local hospital. Repeated blood-gas analysis showed that the pH level was at 7.23, PaCO<sub>2</sub> at 34mmHg, PaO<sub>2</sub> at 193.5mmHg, PO<sub>2</sub>/FiO<sub>2</sub> at 193.5mmHg, and blood lactate at 1.3mmol/L. After the family requested to transfer him to our hospital for further treatment, the patient was taken to the ambulance. However, during transportation, he experienced episodes of significant hypoxemia with oxygen saturation (SpO<sub>2</sub>) ranging from 60% to 70%. Additionally, a large amount of hemorrhagic fluid gushed out from the tracheal tube, and wet and dry rales could be heard clearly in both lungs. Arterial blood-gas analysis showed that the pH level was at 7.29, PaCO<sub>2</sub> at 30.4mmHg, PaO<sub>2</sub> at 73.7mmHg, PO<sub>2</sub>/FiO<sub>2</sub> at 73.7mmHg, and blood lactate at 2.3mmol/L. Obviously, the patient developed ARDS and due to this, the transfer was terminated. To treat this condition, lung-protective ventilation, deep sedation, analgesia, paralysis using neuromuscular blocker and continuous renal replacement therapy were administered. Additionally, prone-position ventilation was given to ameliorate hypoxia.

On the second day after intubation, the patient's condition worsened with an increase in bilateral pulmonary infiltrates, leucocyte count and PCT levels ( $19.54 \times 10^9/L$  and 83.26  $\mu\text{g/L}$ , respectively). The ventilatory parameters were also high (A/C, FiO<sub>2</sub> 100%, f 15 breaths/min, Vt 450mL, PEEP 18 cmH<sub>2</sub>O). A decision was made to establish VV-ECMO with the initial settings: flow 4.5L/min, 3475 RPM and sweep gas flow 4 L/min. The patient underwent cannulation using a left femoral–right internal jugular vein approach. To maintain a plateau pressure  $<25$  cmH<sub>2</sub>O, ventilatory parameters were set to a tidal volume of 6 mL/kg, PEEP 10 cmH<sub>2</sub>O, and a respiratory rate of 15 bpm. Subsequently, the patient was transferred to the ICU of our hospital for further care, which is the nearest tertiary care facility. The patient's Acute Physiology and Chronic Health Evaluation II score upon admission was 17. To get more information on pathogen, bronchoalveolar lavage fluid (BALF) sample was obtained to perform metagenomic next-generation sequencing (mNGS) detection (Hugobiotech Co., Ltd., Beijing, China). Follow-up laboratory testing results showed IL-6 level was at 447.9 pg/mL (normal range  $< 7.0$  pg/mL), IL-8 at 178.6 pg/mL (normal range  $< 62.0$  pg/mL), and IL-10 at 17.8 pg/mL (normal range  $< 9.1$  pg/mL). Given the increased

A

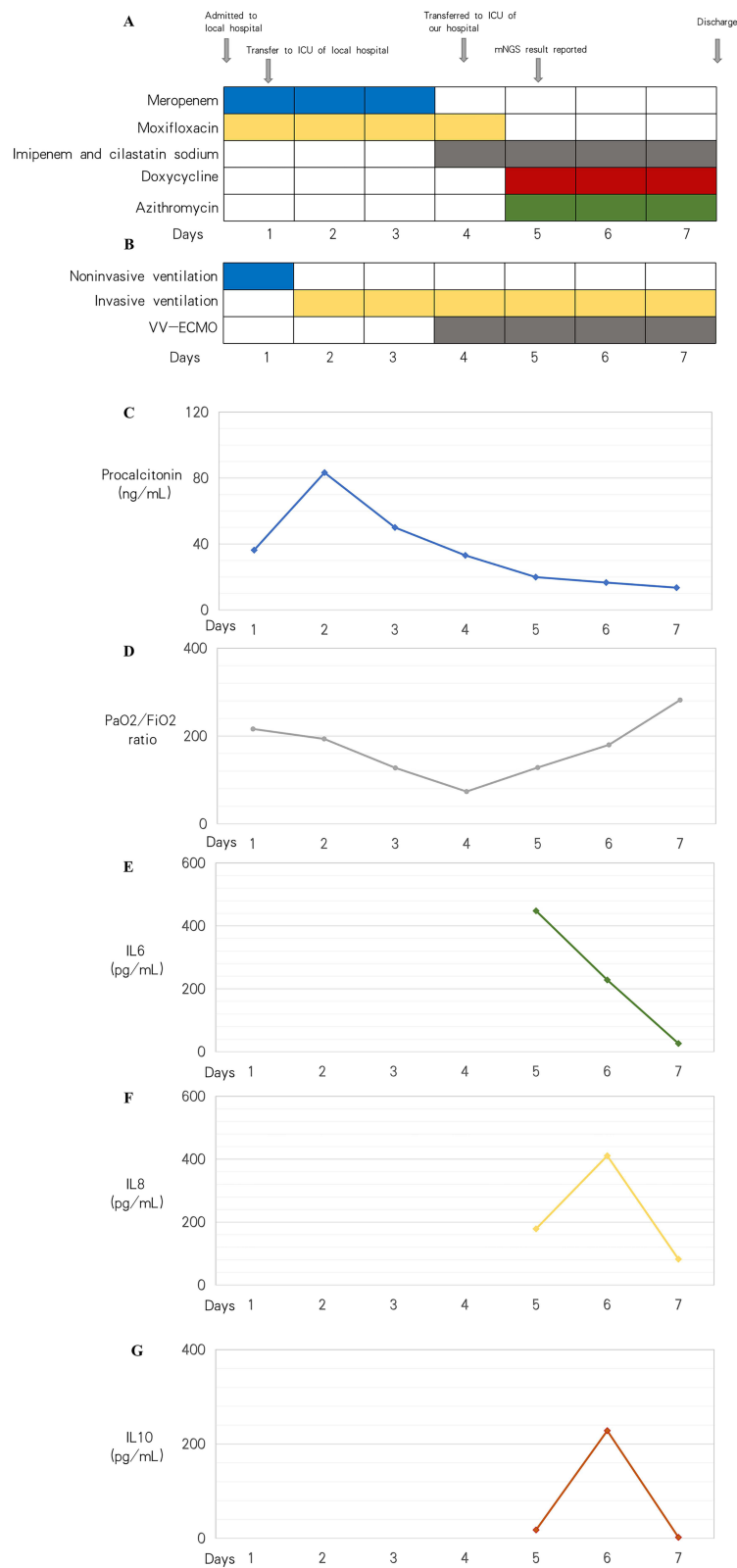


B

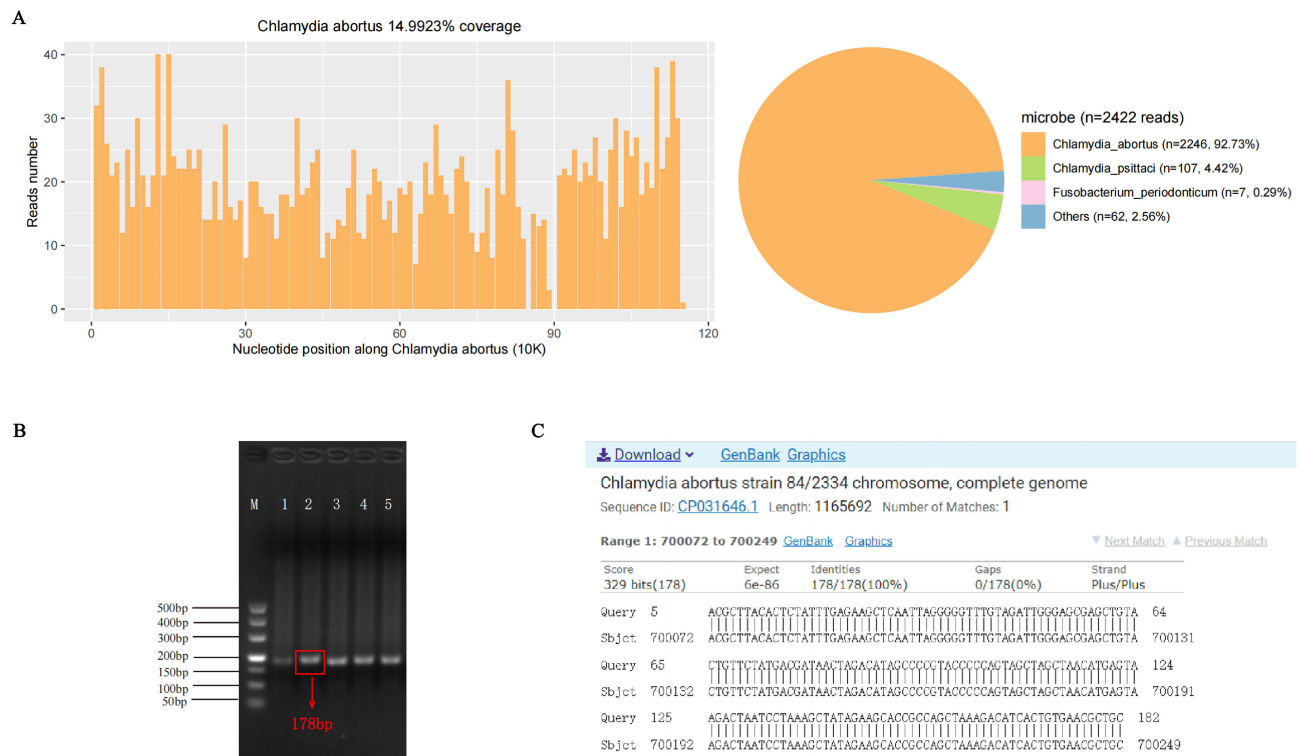


**Figure 1** Chest computed tomography scans on the 0th day of hospitalization in the local hospital (A and B). CT scans showed patchy high-density shadows with blurred margins in both the posterior segment of the left upper lung and the dorsal segment of the lower lung.

pulmonary infiltrates and the progressively elevated levels of inflammatory markers, intravenous antibiotic therapy was continued with moxifloxacin (0.4 g every day), but meropenem (1g every 8h) was switched to imipenem and cilastatin sodium (1g every 6h). On Day 2 of ICU hospitalization, *C. abortus* was detected with 2246 specific reads by mNGS tests of BALF (Figure 3A). Because human infection with *C. abortus* is rare, it was double-checked by PCR assay with a 178bp validation sequence (Figure 3B). Delightedly, the PCR products were confirmed as *C. abortus* by sanger sequencing (Figure 3C), which eventually confirmed the diagnosis of *C. abortus* pneumonia. Based on the results of mNGS and PCR, oral doxycycline (0.1g every 12h) in combination with intravenous azithromycin (0.5g every day) was administered. As *chlamydia* infection is typically a mixed infection, intravenous administration of imipenem and cilastatin sodium (1g every 6h) was continued. Over the next few days, there was a significant improvement in the patient's symptoms and inflammation indicators (PCT [13.55 ug/L], IL-6 [26.3 pg/mL], IL-8 [82.2 pg/mL], and IL-10 [2.1 pg/mL]). The neuromuscular blocker was discontinued, and the

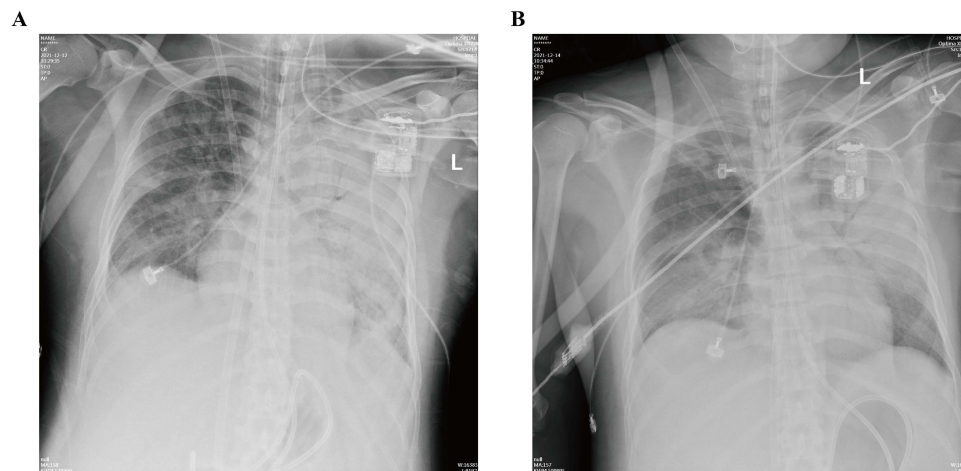


**Figure 2** The clinical course of the patient with *Chlamydia abortus* infection. **(A)** Antibiotic application during hospitalization. **(B)** The types of ventilation in the clinical course. **(C–G)** The changes of procalcitonin, PO<sub>2</sub>/FiO<sub>2</sub>, IL-6, IL-8 and IL-10 on each day.



**Figure 3** Diagnosis of *Chlamydia abortus* infection using mNGS test and following verification using PCR and sanger sequencing. **(A)** The unique mapping reads of *C. abortus* was 2246 with 14.99% genome coverage. **(B)** PCR detected 178 base-pair products in BALF sample with specific primers (for example, Primer 2, forward primer: ACGCTTACTCTATTTGAGAAGCT, reverse primer: GCAGCGTTCACAGTGATGTCTT). **(C)** NCBI sequence alignment result. The “Query” lines indicate the sanger sequencing result of the PCR product, and the “Sbjct” lines show the reference sequence from NCBI database. The identity between the sequence obtained from Sanger sequencing and a reference *C. abortus* sequence (GenBank accession no. CP031646.1) was 100%.

dosage of norepinephrine was gradually down-regulated. There was also a significant improvement in pulmonary infiltrates as observed through chest X-ray (Figure 4), as well as a significant improvement in lung compliance. However, the patient’s liver function continued to deteriorate despite treatment, with serum total bilirubin of 506.36 μmol/L. On Day 4 of ICU hospitalization, the patient’s relatives made the difficult decision to forgo further treatment due to financial reasons. On



**Figure 4** Chest X-ray scans on the abnormality in lungs during the VV-ECMO support hospitalization. **(A)** Chest X-ray on the first day of VV-ECMO showed exudation, consolidation, and bilateral pleural effusion in both lungs, especially in the left lung. **(B)** Chest X-ray on the third day of VV-ECMO showed the exudation, consolidation, and bilateral pleural effusion were relieving than before.

**Table 1** Summary of Case Reports on *Chlamydia abortus* Pneumonia

Author	Reported Time	Reported Area	Methods	ARDS and MODS	Anti-Infective Drugs	ECMO	Clinical Outcome	History of Exposure to Infected Animals or Their Products
Ortega et al <sup>5</sup>	2016	Spain	Serological test by ELISA kit	NO	Levofloxacin + Clarithromycin	NO	Improved	Yes, the patient worked as a veterinary researcher in a laboratory where experimental intranasal infections with <i>C. abortus</i> were developed in sheep.
Pichon et al <sup>6</sup>	2020	France	PCR	ARDS	Doxycycline	NO	Improved	Yes, the patient's husband was a goat farmer, and there is an increased number of abortions among his herd during the previous two years.
Zhu et al <sup>7</sup>	2022	China	mNGS	NO	Piperacillin sodium/ tazobactam + Moxifloxacin	NO	Improved	Not stated, but the patient has a medical history of hepatic malignancy and has undergone three interventional surgeries.
Imkamp et al <sup>8</sup>	2022	Switzerland	PCR	NO	Clarithromycin	NO	Improved	Yes, the patient was living on a farm and help to handle and remove two goats both aborted twins. The two goats did not vaccinated against <i>C. abortus</i> .
Liu et al <sup>9</sup>	2022	China	NGS	NO	Azithromycin+ Levofloxacin	NO	Improved	The patient did not directly contact with infected animals.

December 15, 2021, the patient was weaned off ECMO and discharged with the result of arterial blood gases as follows: pH 7.44, PO<sub>2</sub> 112.8 mmHg, PCO<sub>2</sub> 34 mmHg, PO<sub>2</sub>/FiO<sub>2</sub> 282 mmHg, blood lactate 2.1 mmol/L. Unfortunately, just eight hours after being discharged, the patient passed away.

## Discussion

To the best of our knowledge, this is the first reported case of a patient receiving ECMO treatment for *C. abortus* pneumonia. While *C. abortus* is a well-documented zoonotic pathogen that has been primarily associated with manifestation of abortion, stillbirth, or gestational septicaemia in pregnant women,<sup>10–13</sup> it was no previously known to infect the human respiratory tract until Ortega et al<sup>5</sup> reported the first atypical pneumonia related to *C. abortus* in Spain in 2016. Subsequent studies by Pichon et al<sup>6</sup> in France in 2020, and more recently by Liu et al,<sup>9</sup> Zhu et al,<sup>7</sup> and Imkamp et al<sup>8</sup> in China and Switzerland in 2022 revealed four additional cases of atypical pneumonia caused by *C. abortus* (Table 1). Fortunately, these cases were not life-threatening and patients finally recovered well because of timely diagnosis and correct antibiotic treatment, whereas our patient's case of *C. abortus* infection was particularly severe resulting in rapid progression to severe ARDS and serious visceral complications. The timely administration of VV-ECMO treatment allowed for temporary rest of the patient's lungs, which in turn provided the necessary time to clarify the diagnosis and ensure the effectiveness of antibiotic treatment. As a result, there was a significant improvement in the patient's clinical symptoms and inflammation indicators. Our case demonstrates that *C. abortus* infection can be life-threatening, and ECMO plays an important role in the management of severe ARDS caused by rare pathogens. Until now, the source of human infection with *C. abortus* is unclear. According to studies of previously reported cases,<sup>3,5–8,14</sup> it appears that most patients with *C. abortus* infection had a history of direct or indirect exposure to infected animals. Direct contact (infected

animals or their products, contaminated aerosols or dust) and indirect contact (visiting or living on or near farms affected by endemic abortion) can all be the risk factors for infection.<sup>3</sup> In the present case, the patient's wife reported no typical direct exposure to infected animals or their products. Therefore, we suspect that the patient may have contracted the infection through an indirect mode of transmission.

At present, there are no serological tests approved for the specific diagnosis of *C. abortus* infection in humans. Hence, PCR remains the primary method for diagnosing *C. abortus* infection.<sup>1</sup> However, the molecular technique is a highly targeted test and requires several a priori assumptions. It is typically performed only in cases where clinicians suspect *C. abortus* infection.<sup>15</sup> No pathogenic bacteria were found in sputum by traditional methods in our article, which made precision diagnosis and treatment challenging. mNGS is an unbiased method that can theoretically detect all pathogens of clinical samples and is especially suitable for novel, rare and atypical etiologies of complicated infectious diseases.<sup>16</sup> Additionally, it is characterized by fast detection speed and its results are less affected by prior antibiotic exposure.<sup>17</sup> Therefore, we performed mNGS and finally clarified that the pathogen was *C. abortus* in our patient. PCR was used to further verify the result. Interestingly, the first case of *C. abortus* pneumonia reported in China was also diagnosed via mNGS technology at an earlier time.<sup>7</sup> Comparing with traditional methods, mNGS could be the most promising comprehensive diagnostic tool that is broadly applicable to rarely infectious disease diagnostics.

*C. abortus* infection can be a rare but severe and life-threatening disease as seen in our patient who developed MODS and deteriorated quickly. Therefore, correct and timely treatment is essential. *Chlamydiae* are generally susceptible to antibiotics that inhibit DNA and protein synthesis, including tetracyclines, macrolides and quinolones.<sup>18</sup> There are no established treatment guidelines for *C. abortus* infections in humans so far. Since *C. abortus* was previously classified as a subspecies of *C. psittaci*, current treatment recommendations for *C. psittaci* have been used as a guide for treating *C. abortus* infections. Tetracycline antibiotics are the drug of perfect choice for *C. psittaci* infection in humans, with the oral dosage form for mild cases and intravenous injection recommended for severe cases.<sup>19</sup> Among them, doxycycline is often considered the most effective treatment for various tropical diseases, zoonotic infections, and empiric treatment of undifferentiated febrile illnesses.<sup>14</sup> Recent in vitro test suggested a possible therapeutic advantages of doxycycline on clearing *C. abortus* infection in epithelial cells.<sup>20</sup> In addition, macrolide antibiotics are considered the best alternative agents in patients for whom tetracyclines are contraindicated. Macrolide drugs such as azithromycin have also been confirmed to be effective against *C. psittaci* in vitro.<sup>19,21</sup> According to a report by Fang et al, omadacycline, a novel tetracycline, will be a new option for the treatment of severe *C. psittaci* infection due to its good safety profile and no requirement for dose adjustment in special populations.<sup>22</sup> In some cases, quinolones are effective but are less effective compared to tetracyclines and macrolides.<sup>23</sup> The patient presented in this study had initially been treated with meropenem and moxifloxacin, but his pulmonary function continued to deteriorate, indicating poor efficacy or insufficient treatment. Given the therapeutic options described in the literature, patient's condition, and to prevent the possibility of mixed infection caused by *chlamydia*, we opted for a combination therapy of doxycycline and azithromycin along with imipenem and cilastatin sodium. Although this patient's condition improved clinically and biologically, it was unfortunate that he had to be discharged for financial reasons and eventually passed away.

It is worth noting that this case has its limitations. Our review of a case series involving patients with *C. abortus* revealed that exposure to infected animals had played a significant role in the transmission of the disease. However, given the severity of our patient's illness, we were unable to gather trustworthy epidemiological information through personal interaction. This raised the concern that his exposure history could have been overlooked. Furthermore, timely and accurate diagnosis, coupled with prompt treatment, resulted in a noticeable improvement in the patient's clinical and biological condition. If his relatives decided to continue with the suggested treatment plan, there was a good chance he would be discharged from the hospital with a favorable prognosis.

## Conclusion

Infections with *C. abortus* can result in severe ARDS and serious visceral complications which necessitate prompt diagnosis and active intervention by clinicians. The case highlights the significance of mNGS as an essential diagnostic tool for uncommon pathogens. Tetracyclines, macrolides or their combinations are effective choices for treatment of *C. abortus* pneumonia. Further study is needed to explore the transmission routes of *C. abortus* pneumonia and establish precise guidelines for antibiotic treatment.

## Abbreviations

*C. abortus*, *Chlamydia abortus*; VV-ECMO, Venovenous extracorporeal membrane oxygenation; ARDS, Acute respiratory distress syndrome; CT, Computed tomography; PCT, Procalcitonin; BALF, Bronchoalveolar lavage fluid; mNGS, Metagenomic next-generation sequencing; PCR, Polymerase chain reaction; MODS, Multiple organ dysfunction syndrome; DNA, Deoxyribonucleic acid.

## Data Sharing Statement

The dataset supporting the conclusions of this article is included in the article. Specific laboratory or imaging data are available from the corresponding author on reasonable request.

## Ethics Approval and Consent to Participate

This case had obtained the consent of the Ethics Committee of Shunde Hospital, Southern Medical University (The First People's Hospital of Shunde Foshan) (Approval Number: KYLS20220606). Written informed consent was obtained from the patient's relatives for publication of this case report.

## Consent for Publication

Written informed consent for publication of case-related details and clinical images was obtained from the patient's relatives.

## Funding

This study was funded by the Scientific Research Start Plan of Shunde Hospital, Southern Medical University (The First People's Hospital of Shunde Foshan) (CRSP2022006).

## Disclosure

The authors declare that they have no competing interests.

## References

1. Turin L, Surini S, Wheelhouse N, Rocchi MS. Recent advances and public health implications for environmental exposure to *Chlamydia abortus*: from enzootic to zoonotic disease. *Vet Res*. 2022;53(1):37. doi:10.1186/s13567-022-01052-x
2. Pospischil A, Thoma R, Hilbe M, Grest P, Zimmermann D, Gebbers JO. Abort beim Menschen durch *Chlamydia abortus* (*Chlamydia psittaci* serovar 1) [Abortion in humans by *Chlamydia abortus* (*Chlamydia psittaci* serovar 1)]. *Schweiz Arch Tierheilkd*. 2002;144(9):463–466. German.
3. Meijer A, Brandenburg A, de Vries J, Beentjes J, Roholl P, Dercksen D. *Chlamydia abortus* infection in a pregnant woman associated with indirect contact with infected goats. *Eur J Clin Microbiol Infect Dis*. 2004;23(6):487–490.
4. Cheong HC, Lee CYQ, Cheok YY, Tan GMY, Looi CY, Wong WF. Chlamydiae: diseases in primary hosts and zoonosis. *Microorganisms*. 2019;7(5):64.
5. Ortega N, Caro MR, Gallego MC, et al. Isolation of *Chlamydia abortus* from a laboratory worker diagnosed with atypical pneumonia. *Ir Vet J*. 2015;69:8.
6. Pichon N, Guindre L, Laroucau K, Cantaloube M, Nallatamby A, Parreau S. *Chlamydia abortus* in Pregnant Woman with Acute Respiratory Distress Syndrome. *Emerg Infect Dis*. 2020;26(3):628–629.
7. Zhu C, Lv M, Huang J, et al. Bloodstream infection and pneumonia caused by *Chlamydia abortus* infection in China: a case report. *BMC Infect Dis*. 2022;22(1):181.
8. Imkamp F, Albini S, Karbach M, et al. Zoonotic Chlamydiae as rare causes of severe pneumonia. *Swiss Med Wkly*. 2022;152:w30102.
9. Liu M, Wen Y, Ding H, Zeng H. Septic shock with *Chlamydia abortus* infection. *Lancet Infect Dis*. 2022;22(6):912.
10. Walder G, Hotzel H, Brezinka C, et al. An unusual cause of sepsis during pregnancy: recognizing infection with *chlamydia abortus*. *Obstet Gynecol*. 2005;106(5):1215–1217. doi:10.1097/01.AOG.0000161060.69470.9c
11. Pospischil A, Thoma R, Hilbe M, Grest P, Gebbers JO. Abortion in woman caused by caprine *Chlamydia abortus* (*Chlamydia psittaci* serovar 1). *Swiss Med Wkly*. 2002;132(5–6):64–66.
12. Roberts W, Grist NR, Giroud P. Human abortion associated with infection by ovine abortion agent. *Br Med J*. 1967;4(5570):37.
13. Essig A, Longbottom D. *Chlamydia abortus*: new aspects of infectious abortion in sheep and potential risk for pregnant women. *Curr Clin Microbiol Rep*. 2015;2(1):22–34.
14. Burgener AV, Seth-Smith HMB, Kern-Baumann S, et al. A case study of zoonotic *chlamydia abortus* infection: diagnostic challenges from clinical and microbiological perspectives. *Open Forum Infect Dis*. 2022;9(10):ofac524.
15. Li N, Li S, Tan W, Wang H, Xu H, Wang D. Metagenomic next-generation sequencing in the family outbreak of psittacosis: the first reported family outbreak of psittacosis in China under COVID-19. *Em microbes infect*. 2021;10(1):1418–1428.



16. Goldberg B, Sichtig H, Geyer C, Ledebner N, Weinstock GM. Making the leap from research laboratory to clinic: challenges and opportunities for next-generation sequencing in infectious disease diagnostics. *mBio*. 2015;6(6):e01888–15.
17. Miao Q, Ma Y, Wang Q, et al. Microbiological diagnostic performance of metagenomic next-generation sequencing when applied to clinical practice. *Clin Infect Dis*. 2018;67(suppl\_2):S231–S240.
18. Kohlhoff SA, Hammerschlag MR. Treatment of Chlamydial infections: 2014 update. *Expert Opin Pharmacother*. 2015;16(2):205–212.
19. Balsamo G, Maxted AM, Midla JW, et al. Compendium of Measures to Control Chlamydia psittaci Infection Among Humans (Psittacosis) and Pet Birds (Avian Chlamydiosis), 2017. *J Avian Med Surg*. 2017;31(3):262–282.
20. Diensthuber D, Simnacher U, Peters S, Walther P, Essig A, Hagemann JB. Clearing Chlamydia abortus infection in epithelial cells and primary human macrophages by use of antibiotics and the MDM2-p53-inhibitor nutlin-3. *Diagn Microbiol Infect Dis*. 2022;103(3):115715.
21. Teng XQ, Gong WC, Qi TT, et al. Clinical analysis of metagenomic next-generation sequencing confirmed chlamydia psittaci pneumonia: a case series and literature review. *Infect Drug Resist*. 2021;14:1481–1492.
22. Fang C, Xu L, Tan J, Tan H, Lin J, Zhao Z. Omadacycline for the Treatment of Severe Chlamydia psittaci Pneumonia Complicated with Multiple Organ Failure: a Case Report. *Infect Drug Resist*. 2022;15:5831–5838.
23. Wang L, Shi Z, Chen W, Du X, Zhan L. Extracorporeal Membrane Oxygenation in Severe Acute Respiratory Distress Syndrome Caused by Chlamydia psittaci: a Case Report and Review of the Literature. *Front Med*. 2021;8:731047.

## Infection and Drug Resistance

Dovepress

### Publish your work in this journal

Infection and Drug Resistance is an international, peer-reviewed open-access journal that focuses on the optimal treatment of infection (bacterial, fungal and viral) and the development and institution of preventive strategies to minimize the development and spread of resistance. The journal is specifically concerned with the epidemiology of antibiotic resistance and the mechanisms of resistance development and diffusion in both hospitals and the community. The manuscript management system is completely online and includes a very quick and fair peer-review system, which is all easy to use. Visit <http://www.dovepress.com/testimonials.php> to read real quotes from published authors.

Submit your manuscript here: <https://www.dovepress.com/infection-and-drug-resistance-journal>