

# Minimally Invasive Lower Leg Fasciotomy for Chronic Exertional Compartment Syndrome—How Safe Is It?

## A Cadaveric Study

Peter Grechenig,<sup>\*†</sup> Epaminondas Markos Valsamis,<sup>‡</sup> MB BChir, MA(Cantab), MRCS, PGCertMedEd, Tom Müller,<sup>†</sup> Axel Gänsslen,<sup>§</sup> MD, and Gloria Hohenberger,<sup>||</sup> MD, PhD

*Investigation performed at the Division of Macroscopic and Clinical Anatomy, Medical University of Graz, Graz, Austria*

**Background:** Chronic exertional compartment syndrome (CECS) is a recognized clinical diagnosis in running athletes and military recruits. Minimally invasive fasciotomy techniques have become increasingly popular, but with varied results and small case numbers. Although decompression of the anterior and peroneal compartments has demonstrated a low rate of iatrogenic injury, little is known about the safety of decompressing the deep posterior compartment.

**Purpose:** To evaluate the risk of iatrogenic injury when using minimally invasive techniques to decompress the anterior, peroneal, and deep posterior compartments of the lower leg.

**Study Design:** Descriptive laboratory study.

**Methods:** A total of 60 lower extremities from 30 adult cadavers were subject to fasciotomy of the anterior, peroneal, and deep posterior compartments using a minimally invasive technique. Two common variations in surgical technique were employed to decompress each compartment. Anatomical dissection was subsequently carried out to identify incomplete division of the fascia, muscle injury, neurovascular injury, and the anatomical relationship of key neurovascular structures to the incisions.

**Results:** Release of the anterior and peroneal compartments was successful in all but 2 specimens. There was no injury to the superficial peroneal nerve or any vessel in any specimen. A transverse incision crossing the anterior intermuscular septum resulted in muscle injury in 20% of the cases. Release of the deep posterior compartment was successful in all but 1 specimen when a longitudinal skin incision was used, without injury to neurovascular structures. Compared with a longitudinal incision, a transverse skin incision resulted in fewer complete releases of the deep posterior compartment and a significantly higher rate of injury to the saphenous nerve (16.7%;  $P = .052$ ) and long saphenous vein (23.3%;  $P = .011$ ).

**Conclusion:** Minimally invasive fasciotomy of the anterior, peroneal, and deep posterior compartments using longitudinal incisions had a low rate of iatrogenic injury in a cadaveric model. Complete compartment release was achieved in 97% to 100% of specimens when employing this technique.

**Clinical Relevance:** Minimally invasive fasciotomy techniques for CECS have become increasingly popular with purported low recurrence rates, improved cosmesis, and faster return to sport. It is important to determine whether this technique is safe, particularly given the variable rates of neurovascular injury reported in the literature.

**Keywords:** compartment syndrome; anatomy; peripheral nerve injuries; lower extremity; military training

Chronic exertional compartment syndrome (CECS) of the lower leg is a rare but recognized clinical diagnosis in running athletes and military recruits.<sup>21</sup> After failed nonoperative management, surgical fasciotomy is the treatment of choice.<sup>6</sup>

Clinical outcomes after surgical fasciotomy for CECS have been generally satisfactory but varied, with success rates ranging from 52% to 100%.<sup>7,9,15</sup> Minimally invasive techniques have become increasingly popular and demonstrate low recurrence rates, improved cosmesis, and faster return to sport.<sup>5,13</sup> The anterior compartment of the leg has been thought to be most commonly affected, and the literature has been heavily focused on techniques to decompress this compartment.<sup>2,4</sup> Recent studies have

The Orthopaedic Journal of Sports Medicine, 8(10), 2325967120956924  
DOI: 10.1177/2325967120956924  
© The Author(s) 2020

This open-access article is published and distributed under the Creative Commons Attribution - NonCommercial - No Derivatives License (<https://creativecommons.org/licenses/by-nc-nd/4.0/>), which permits the noncommercial use, distribution, and reproduction of the article in any medium, provided the original author and source are credited. You may not alter, transform, or build upon this article without the permission of the Author(s). For article reuse guidelines, please visit SAGE's website at <http://www.sagepub.com/journals-permissions>.

suggested that deep posterior compartment CECS (dp-CECS) is often overlooked, and its incidence may be higher than anticipated.<sup>22,23</sup>

Traditionally, skin and fascial incisions for lower limb fasciotomy have been longitudinal, although some recent studies have demonstrated that transverse incisions may be a suitable alternative.<sup>3,19</sup> There has been debate over single- versus dual-incision fasciotomies to decompress the lower leg,<sup>13,18</sup> with the single-incision technique potentially offering reduced operative time, but at the theoretical expense of less effective decompression. Bible et al<sup>1</sup> found no difference in patient outcomes after comparing single- and dual-incision techniques.

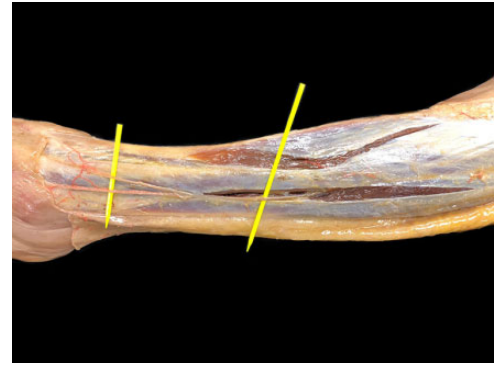
A key surgical concern when employing minimally invasive fasciotomy is the risk of neurovascular injury. The superficial peroneal nerve (SPN) is closely anatomically related to the anterior and peroneal compartments, with a variable rate (0%-8%) of iatrogenic SPN injury reported.<sup>4,5</sup> This variation reflects both the differences in surgical techniques and the small sizes, particularly in cadaveric studies.<sup>4</sup> Fasciotomy for dp-CECS is considered technically challenging, and studies have reported a high risk of injury to neurovascular structures with both open and endoscopic techniques.<sup>11,12,14</sup> The authors of 1 cadaveric study found a concerning high risk (67%) of iatrogenic neurovascular damage with minimally invasive fasciotomy without the use of an endoscope, although they used a small number of specimens (n = 6).<sup>11</sup>

The aim of this study was to evaluate the safety of minimally invasive fasciotomy techniques without the use of endoscopy for lower leg CECS by investigating the risk of iatrogenic injury when decompressing the anterior, peroneal, and deep posterior compartments on cadaveric specimens.

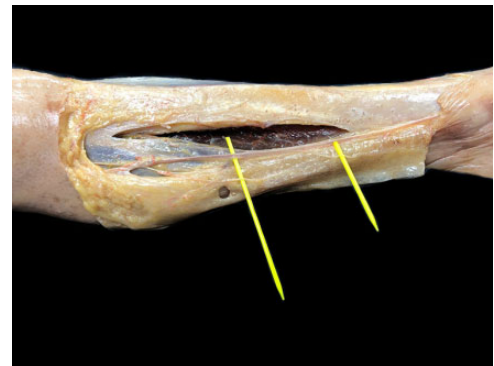
## METHODS

A total of 60 lower extremities from 30 adult human cadavers embalmed with the Thiel method were used for this study.<sup>20</sup> Cadavers with macroscopically visible pathology of the lower limb were excluded. The cadavers were donated to the Medical University of Graz.

Each cadaver was positioned supine on a dissection table with bilateral knee supports. Fasciotomy of the anterior, peroneal, and deep posterior compartments was undertaken in all cadaveric specimens. An experienced trauma surgeon demonstrated the procedure on 2 lower



**Figure 1.** Dissected cadaveric specimen with fasciotomy of the anterior and peroneal compartments. The superficial peroneal nerve is identified over the yellow markers.



**Figure 2.** Dissected cadaveric specimen with fasciotomy of the deep posterior compartment. The neurovascular bundle comprising the long saphenous vein and saphenous nerve is identified over the yellow markers.

extremities, after which the fasciotomies and subsequent anatomical dissection were carried out by 2 supervised medical students.

After the releases were completed, careful anatomical dissection was carried out to identify incomplete division of the fascia, muscle injury (division of any muscle fibers), neurovascular injury, and the anatomical relationship of key neurovascular structures to the incisions. Figures 1 and 2 demonstrate the appearance of the dissected specimens and the relevant neurovascular structures after decompression of the anterior and peroneal compartments and the deep posterior compartment, respectively.

\*Address correspondence to Peter Grechenig, Division of Macroscopic and Clinical Anatomy, Medical University of Graz, Harrachgasse 21, 8010 Graz, Austria (email: peter.grechenig@gmx.net).

<sup>†</sup>Division of Macroscopic and Clinical Anatomy, Medical University of Graz, Graz, Austria.

<sup>‡</sup>Nuffield Orthopaedic Centre, Oxford University Hospitals NHS Trust, Oxford, UK.

<sup>§</sup>Trauma Department, Klinikum Wolfsburg, Wolfsburg, Germany.

<sup>||</sup>Department of Orthopaedics and Trauma Surgery, Medical University of Graz, Graz, Austria.

Final revision submitted April 14, 2020; accepted April 27, 2020.

The authors declared that there are no conflicts of interest in the authorship and publication of this contribution. AOSSM checks author disclosures against the Open Payments Database (OPD). AOSSM has not conducted an independent investigation on the OPD and disclaims any liability or responsibility relating thereto.

Ethical approval for this study was waived by the Medical University of Graz.

## Fasciotomy of the Anterior and Peroneal Compartments

The midpoint of the fibula (halfway between the fibular head and the lateral malleolus) was identified and marked. A 3-cm transverse skin incision was made over this, followed by blunt subcutaneous dissection down to the fascia using dissecting scissors.

On right-sided specimens, a 3-cm transverse incision was made in the fascia, centered over the anterior intermuscular septum. Direct visualization and palpation were used to confirm that the incision crossed the anterior intermuscular septum. The anterior and peroneal compartments were opened separately through percutaneous, longitudinal fascial incisions using long surgical scissors. The incision over the anterior compartment was placed 1 cm lateral to the anterior margin of the tibia and was aimed toward the tibial tuberosity proximally and the anterolateral margin of the tibia distally. The incision over the peroneal compartment was placed in the middle of the peroneal compartment and was aimed toward the fibular head proximally and the lateral malleolus distally.

On left-sided specimens, instead of a transverse fascial incision crossing the anterior intermuscular septum, only separate longitudinal incisions were made over the respective compartments as described above. This was to determine whether there was any difference between these 2 commonly used techniques for decompressing the anterior and peroneal compartments.

## Fasciotomy of the Deep Posterior Compartment

The midpoint between the tip of the medial malleolus and the tibial tuberosity was identified and marked. On right-sided specimens, a 3-cm transverse skin incision was made with the most lateral point of the incision over the medial border of the tibia. The subcutaneous tissue was bluntly dissected with surgical scissors down to the fascia. The medial head of the gastrocnemius was retracted laterally to expose the deep posterior compartment. The deep posterior compartment was opened through a percutaneous, longitudinal fascial incision using long surgical scissors. This incision was placed immediately adjacent to the medial border of the tibia.

On left-sided specimens, instead of a 3-cm transverse skin incision, a 3-cm longitudinal skin incision over the medial border of the tibia was made. The rest of the procedure was the same as that for right-sided specimens.

## Statistical Analysis

The Fisher exact test was used for categorical variables, and the *t* test was used for continuous, normally distributed variables (length of fasciotomy incision). Statistical significance was set at  $P < .05$ . All statistical analysis was undertaken with MedCalc.<sup>17</sup>

## RESULTS

### Fasciotomy of the Anterior and Peroneal Compartments

A total of 30 right-sided lower extremities were used for fasciotomy of the anterior and peroneal compartments using an additional transverse fascial incision over the anterior intermuscular septum. Complete release of the anterior compartment occurred in all but 1 specimen. Superficial (1- to 2-mm depth) muscular injury was identified in 6 specimens. Complete release of the peroneal compartment occurred in all specimens. There was no injury to the SPN or any major vessel. In 10 specimens, the SPN was found to be crossing the fasciotomy incision. In the remaining 20 cases, specimens the SPN pierced the fascia an average of 2.8 cm from the fasciotomy incision.

A total of 30 left-sided lower extremities were used for fasciotomy of the anterior and peroneal compartments using separate longitudinal incisions over each compartment only (without a transverse incision over the anterior intermuscular septum). Complete release of the anterior compartment occurred in all specimens, with muscular injury being identified in 2 specimens. Complete release of the peroneal compartment occurred in all but 1 specimen, with muscular injury being identified in 1 specimen. There was no injury to the SPN or any major vessel. In 6 specimens, the SPN was found to be crossing the fasciotomy incision. In the remaining 24 specimens, the SPN pierced the fascia an average of 3.0 cm from the fasciotomy incision.

### Fasciotomy of the Deep Posterior Compartment

A total of 30 right-sided lower extremities were used for fasciotomy of the deep posterior compartment with a transverse skin incision. Complete release of the deep posterior compartment occurred in all but 5 specimens, with muscular injury being identified in all specimens. The saphenous nerve was injured in 5 specimens and the long saphenous vein was injured in 7 specimens. This injury was a direct consequence of the transverse skin incision that extended posterior to the level of the subsequent fascial incision.

A total of 30 lower extremities were used for fasciotomy of the deep posterior compartment with a longitudinal skin incision. Complete release of the deep posterior compartment occurred in all but 1 specimen, with muscular injury being identified in all specimens. There was no injury to the saphenous nerve or long saphenous vein. In all specimens, the saphenous nerve and long saphenous vein were not found to be crossing the fasciotomy incision. A summary of the results is shown in Table 1.

## DISCUSSION

This cadaveric study demonstrated that a minimally invasive approach to decompress the anterior, peroneal, and deep posterior compartments of the lower leg is safe, with low rates of iatrogenic injury when using 2 separate longitudinal incisions.

TABLE 1  
Details of Fasciotomy Outcomes<sup>a</sup>

Outcome	Anterior (n = 30)			Peroneal (n = 30)			Deep Posterior (n = 30)		
	Right (Transverse)	Left (Longitudinal)	<i>P</i>	Right (Transverse)	Left (Longitudinal)	<i>P</i>	Right (Transverse)	Left (Longitudinal)	<i>P</i>
Complete division of fascia	29 (96.7)	30 (100)	>.999	30 (100)	29 (96.7)	>.999	25 (83.3)	29 (96.7)	.195
Length of fascial incision, cm, mean ± SD	14.8 ± 2.9	13.3 ± 2.8	<b>.046</b>	15.4 ± 2.4	14.9 ± 3.3	.505	11.8 ± 2.9	12.2 ± 2.4	.563
Muscle damage	6 (20)	2 (6.7)	.254	0 (0)	1 (3.3)	>.999	30 (100)	30 (100)	>.999
Nerve injury	0 (0)	0 (0)	>.999	0 (0)	0 (0)	>.999	5 (16.7)	0 (0)	.052
Vessel injury	0 (0)	0 (0)	>.999	0 (0)	0 (0)	>.999	7 (23.3)	0 (0)	<b>.011</b>

<sup>a</sup>Data are presented as number (%) unless otherwise specified. For statistical testing, the Fisher exact test was used for categorical variables and the *t* test for continuous, normally distributed variables (length of fasciotomy incision). Bolded *P* values indicate statistically significant differences between groups (*P* < .05).

There was a high rate (97%-100%) of successful complete decompression of the anterior and peroneal compartments, with no neurovascular injury regardless of whether the anterior intermuscular septum was transversely incised. However, specimens with this transverse incision had a higher rate of muscular injury to the anterior compartment.

Regarding decompression of the deep posterior compartment, there was a comparatively lower rate (83%) of successful complete decompression of the compartment when using a transverse versus a longitudinal skin incision, although this did not reach statistical significance (*P* = .195). All specimens demonstrated muscle injury because the soleus is tightly adherent to the posteromedial aspect of the tibia, forming the soleal bridge over the proximal tibia. However, releasing the soleal bridge is a necessary and important step for successful decompression of the deep posterior compartment.<sup>18</sup> We found an unacceptably higher rate of damage to the saphenous nerve (16.7%; *P* = .052) and long saphenous vein (23.3%; *P* = .011) when using a transverse versus longitudinal skin incision during the approach, but no neurovascular injury occurred when using a longitudinal skin incision. This suggests that neurovascular injury when decompressing the deep posterior compartment is more likely to occur at a superficial level during the skin incision and subcutaneous dissection as opposed to during the fascial release; particular care must therefore be used when executing the approach to this procedure.

To our knowledge, this is the first study in the literature demonstrating that minimally invasive fasciotomy can be used to safely decompress the deep posterior compartment. It is also the study with the largest number of cadaveric specimens to date for investigating fasciotomy for compartment syndrome.

De Bruijn and colleagues<sup>4</sup> investigated the safety of a modified percutaneous fasciotomy technique to decompress the anterior compartment using 9 cadaveric legs and 64 patients. Despite the small numbers, they found no iatrogenic neurovascular injuries. A larger study on 118

patients also demonstrated a low rate (2%) of iatrogenic neurovascular injury. Our results concur with both studies, confirming the safety of a minimally invasive approach to the anterior compartment.

There is considerably less research on minimally invasive fasciotomy for dp-CECS. A cadaveric study by Hutchinson et al<sup>11</sup> concluded that endoscopically assisted fasciotomy has a lower risk of neurovascular injury when compared with a percutaneous technique. However, their study detected a surprisingly large number of nerve injuries: complete transection of the SPN and of the saphenous nerve in 4 out of 6 specimens. Certain differences in surgical technique may explain this disparity. Hutchinson et al made considerably longer average fasciotomy incisions compared with those in our study (30.1 vs 14.1 cm for the anterior and 28.8 vs 15.2 cm for the peroneal compartments). However, studies have demonstrated good clinical results using fasciotomy incisions as small as 4 cm in the anterior compartment.<sup>7,8</sup>

When making a fascial incision to release the deep and superficial posterior compartments, Hutchinson et al<sup>11</sup> describe “creating a transverse incision from the medial border of the tibia about 1 to 2 cm laterally.” This may also have contributed to their high rate of neurovascular injury. We also observed a higher rate of injury of the saphenous nerve and long saphenous vein when using a transverse skin incision (16.7% and 23.3%, respectively). Other authors have described a separate “fifth” compartment of the lower leg consisting of the tibialis posterior muscle that may need addressing in dp-CECS.<sup>10,16</sup> The importance of this fifth compartment is unclear, and its decompression may not be amenable to a minimally invasive approach.

Our study had some limitations. Being a cadaveric study, we were unable to evaluate postoperative patient outcomes. Cadaveric specimens have structural differences compared with living tissue, and it is difficult to ascertain whether outcomes may differ in a clinical setting. Although we could report macroscopic nerve and vessel damage, we were unable to detect neurapraxia or the risk of hematoma, both of which would be important adverse events in patients.

Although all muscle injury we identified was minor (1- to 2-mm depth into muscle), it is unknown whether any bleeding that may have resulted from this injury would have significant adverse effects. The primary operators were supervised medical students who had no formal surgical training. Although this was expected to result in an increased amount of iatrogenic damage, the very low rates of iatrogenic injury despite the relative inexperience of the students further support the safety of this technique. It is possible that careful dissection by an experienced surgeon may further reduce the rate of iatrogenic injury using this technique. Finally, although formal statistical analysis was undertaken, results not demonstrating significance should be interpreted with caution—the relatively small sample size (albeit the largest in the cadaveric fasciotomy literature) means a type 2 statistical error cannot be excluded, and the descriptive statistics should form an important part of the interpretation of this study's results.

Minimally invasive fasciotomy to decompress the anterior, peroneal, and deep posterior compartments of the lower leg appears to be safe, with a low risk of iatrogenic injury. It is important to avoid a transverse medial incision when decompressing the superficial and deep posterior compartments. Future work is required to evaluate postoperative patient outcomes after minimally invasive fasciotomy without the use of endoscopy, especially for dp-CECS.

## ACKNOWLEDGMENT

The authors express their posthumous thanks to the body donors who made this study possible.

## REFERENCES

- Bible JE, McClure DJ, Mir HR. Analysis of single-incision versus dual-incision fasciotomy for tibial fractures with acute compartment syndrome. *J Orthop Trauma*. 2013;27(11):607-611.
- Buerba RA, Fretes NF, Devana SK, Beck JJ. Chronic exertional compartment syndrome: current management strategies. *Open Access J Sports Med*. 2019;10:71-79.
- Crist BD, Della Rocca GJ, Stannard JP. Compartment syndrome surgical management techniques associated with tibial plateau fractures. *J Knee Surg*. 2010;23(1):3-7.
- De Bruijn JA, van Zantvoort APM, Hundscheid HPH, Hoogeveen AR, Teijink JAW, Scheltinga MR. Superficial peroneal nerve injury risk during a semiblind fasciotomy for anterior chronic exertional compartment syndrome of the leg: an anatomical and clinical study. *Foot Ankle Int*. 2019;40(3):343-351.
- De Fijter WM, Scheltinga MR, Luiting MG. Minimally invasive fasciotomy in chronic exertional compartment syndrome and fascial hernias of the anterior lower leg: short- and long-term results. *Mil Med*. 2006;171(5):399-403.
- Detmer DE, Sharpe K, Sufit RL, Girdley FM. Chronic compartment syndrome: diagnosis, management, and outcomes. *Am J Sports Med*. 1985;13(3):162-170.
- Drexler M, Rutenberg TF, Rozen N, et al. Single minimal incision fasciotomy for the treatment of chronic exertional compartment syndrome: outcomes and complications. *Arch Orthop Trauma Surg*. 2017;137(1):73-79.
- Finestone AS, Noff M, Nassar Y, Moshe S, Agar G, Tamir E. Management of chronic exertional compartment syndrome and fascial hernias in the anterior lower leg with the forefoot rise test and limited fasciotomy. *Foot Ankle Int*. 2014;35(3):285-292.
- García-Mata S. Chronic exertional compartment syndrome of the forearm in adolescents. *J Pediatr Orthop*. 2013;33(8):832-837.
- Hislop M, Tierney P, Murray P, O'Brien M, Mahony N. Chronic exertional compartment syndrome: the controversial "fifth" compartment of the leg. *Am J Sports Med*. 2003;31(5):770-776.
- Hutchinson MR, Bederka B, Kopplin M. Anatomic structures at risk during minimal-incision endoscopically assisted fascial compartment releases in the leg. *Am J Sports Med*. 2003;31(5):764-769.
- Lohrer H, Nauck T. Endoscopically assisted release for exertional compartment syndromes of the lower leg. *Arch Orthop Trauma Surg*. 2007;127(9):827-834.
- Maffulli N, Loppini M, Spiezia F, D'Addona A, Maffulli GD. Single minimal incision fasciotomy for chronic exertional compartment syndrome of the lower leg. *J Orthop Surg Res*. 2016;11(1):61.
- Pyne D, Jawad ASM, Padhiar N. Saphenous nerve injury after fasciotomy for compartment syndrome. *Br J Sports Med*. 2003;37(6):541-542.
- Roberts AJ, Krishnasamy P, Quayle JM, Houghton JM. Outcomes of surgery for chronic exertional compartment syndrome in a military population. *J R Army Med Corps*. 2015;161(1):42-45.
- Rorabeck CH. Exertional tibialis posterior compartment syndrome. *Clin Orthop Relat Res*. 1986;208:61-64.
- Schoonjans F, Zalata A, Depuydt CE, Comhaire FH. MedCalc: a new computer program for medical statistics. *Comput Methods Programs Biomed*. 1995;48(3):257-262.
- Singh K, Bible JE, Mir HR. Single and dual-incision fasciotomy of the lower leg. *JBJS Essent Surg Tech*. 2015;5(4):e25.
- Teng AL, Huang JI, Wilber RG, Wilber JH. Treatment of compartment syndrome: transverse fasciotomy as an adjunct to longitudinal dermatofasciotomy: an in vitro study. *J Orthop Trauma*. 2005;19(7):442-447.
- Thiel W. The preservation of the whole corpse with natural color [in German]. *Ann Anat*. 1992;174(3):185-195.
- Tucker AK. Chronic exertional compartment syndrome of the leg. *Curr Rev Musculoskelet Med*. 2010;3(1-4):32-37.
- Winkes M, van Eerten P, Scheltinga M. Deep posterior chronic exertional compartment syndrome as a cause of leg pain. *Unfallchirurg*. 2019;122(11):834-839.
- Winkes MB, Van Zantvoort APM, De Bruijn JA, et al. Fasciotomy for deep posterior compartment syndrome in the lower leg: a prospective study. *Am J Sports Med*. 2016;44(5):1309-1316.