


Contents lists available at [ScienceDirect](https://www.sciencedirect.com)

# Trauma Case Reports

journal homepage: [www.elsevier.com/locate/tcr](http://www.elsevier.com/locate/tcr)

## Case Report

# Traumatic complications of inpatient massage therapy: Case report and literature review

Ishna Sharma<sup>a,\*</sup>, D'Andrea Joseph<sup>b</sup>, Orlando Kirton<sup>c</sup><sup>a</sup> *University of Connecticut, United States of America*<sup>b</sup> *NYU-Winthrop University Hospital, United States of America*<sup>c</sup> *Abington-Jefferson Health, United States of America*

## ARTICLE INFO

### Keywords:

Massage  
Therapy  
Complication  
Trauma  
Thigh  
Hematoma

## Introduction

Recently, massage therapy has gained popularity as an alternative approach to patient care and is a commonly accepted adjunct to patient health care [1]. Between 1990 and 1997, the 1-year prevalence of the use of massage by the United States (US) general population increased from six to 12% [1]. Massage therapy now belongs to the three most popular complementary therapies for traditional medicine in both the US [2] and the United Kingdom (UK) [3]. In some studies, the majority of physicians queried felt that massage provided a useful adjunct to their own practice and refer patients to massage therapists [4–6]. However, as shown in our experience, massage therapy can have adverse effects.

## Case

The patient is a 69-year-old female who admitted to the hospital for pneumonia. She had a history of chronic renal insufficiency grade II and required routine Epoetin injections. Towards the resolution of her pneumonia, she complained of some generalized weakness and soreness, and requested massage therapy. The therapist focused on her right medial thigh as the patient complained of extra soreness in that area. Immediately after therapy, the patient began having significant pain in the medial thigh, which continued over the next day. Two days after the massage the patient complained of weakness and dizziness and was noted to almost collapse on standing. There was ecchymosis in the right medial thigh area with significant swelling compared to the left thigh. Dorsalis pedis pulse and posterior tibialis pulse on the right foot were intact with intact right foot sensation. The range of motion was limited on the right due to pain. Hemoglobin and hematocrit were checked and were 5.1 and 14.9 respectively. She was transfused packed red blood cells with good response.

The patient had a history of chronic kidney disease with a creatinine of 3.8. A non-contrast CT of the abdomen, pelvis, and right

\* Corresponding author.

E-mail addresses: [isharma@uchc.edu](mailto:isharma@uchc.edu) (I. Sharma), [d'andrea.joseph@nyulangone.org](mailto:d'andrea.joseph@nyulangone.org) (D. Joseph), [orlando.kirton@jefferson.edu](mailto:orlando.kirton@jefferson.edu) (O. Kirton).

<https://doi.org/10.1016/j.tcr.2018.11.003>

Accepted 12 November 2018

Available online 16 November 2018

2352-6440/ © 2018 Published by Elsevier Ltd. This is an open access article under the CC BY-NC-ND license

(<http://creativecommons.org/licenses/by-nc-nd/4.0/>).

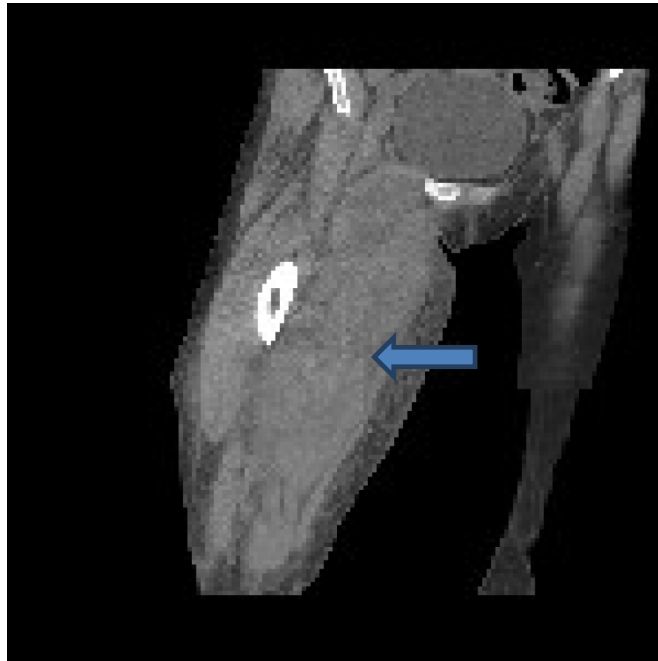


Fig. 1. CT scan of right thigh, arrow indicating hematoma.

lower extremity, was performed which showed a significant hematoma in the medial right thigh, extending 33 cm deep and laterally into the thigh (Fig. 1). The CT also showed multiple heavily calcified vessels in the area of the hematoma (Fig. 2). The patient continued to require transfusion with a total of 4 units of packed red blood cells. The trauma surgery service was consulted and a TEG study was performed. No underlying coagulopathies were noted. The patient was managed with an external compression wrap of the right thigh, and after 4 units of packed red blood cells, the patient's hemoglobin and hematocrit had improved to 10 and 27.9 respectively and remained stable over the next few days. The patient's range of motion returned over the next week with gradual resolution of the pain.

## Discussion

Massage therapy is a commonly used adjunct to conventional medicine and has been perceived as a safe therapeutic modality without any significant risks or side effects [7]. It is defined as a manipulation using the hands or a mechanical device and where

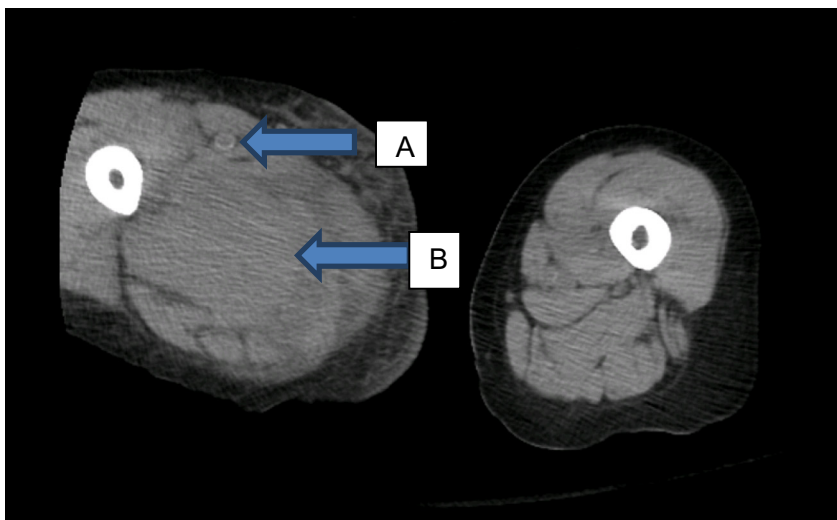


Fig. 2. CT scan of right thigh, arrow A indicating calcified vessel, arrow B indicating hematoma.

numerous specific and general techniques are used in sequence; such as effleurage (circular stroking motion), petrissage (kneading motion), and percussion [7]. The proposed mechanisms behind massage therapy includes local vasodilation and increase in blood and lymph circulation to improve the nutritional status of local organs: deep tissue blood flow to the surface or reduced blood flow locally to reduce congestion [8,9]. Benefits described also include regulation of muscle function, increased muscle flexibility, relief of muscle tension, and promotion of metabolite excretion [8,9]. It is theorized that there is regulation of nerve function: stimulating, inhibiting, or fatiguing of the nerves [8,9]. However, little exists on the potential risks of this therapy. Overall, very few case reports are identified with a mere 3 from this decade. Further, no broad randomized control studies have looked at the potential adverse effects of massage therapy.

The most recent case report in the literature refers to a 59-year-old male patient who developed a significant left buttock hematoma after 2 h of deep tissue massage, and which caused extreme pain and numbness of the entire left lower extremity. An MRI and a subsequent angiographic study demonstrated a damaged arteriole from the superficial branch of the superior gluteal artery. This was embolized with good response [7]. Arterioles are normally elastic, but with increasing age, the vessel wall stiffens from blood vessel wall thickening, intimal calcification, and lipid deposition [10]. Thus, arterial compliance decreases with age [10]. These arterioles are prone to rupture with external forces such as aggressive massage therapy as occurs in deep tissue massage therapy [7]. The authors of the case report suggest considering the status of the vascular system (and the potential blood vessel brittleness) when selecting therapeutic massage techniques for patients [7]. On radiographic evaluation, our patient had several heavily calcified vessels in the area of the hematoma, and could have benefited from screening prior to using massage therapy. A modified approach to massage therapy may have decreased the likelihood of the outcome.

Another recent case report is of a 41 year old male patient who developed an acute spinal subdural hematoma after a vigorous Thai massage [11]. After a back massage, which involved bending at, twisting of, and stepping on the back and waist by a local therapist in Thailand, the patient immediately developed severe back pain radiating down to bilateral lower extremities with inability to walk [11]. The patient presented to the ED 3 days later and with significantly decreased power in his lower extremities, bilateral positive Babinski response, and an inability to void despite sensation of bladder fullness [11]. An MRI showed an acute hematoma in the dura, and the patient was placed on strict bed rest and started on 25 mg of IV dexamethasone with tapering of dose by 5 mg daily [11]. After 2 weeks, the patient's symptoms grossly resolved, and follow-up MRI showed marked decrease in the hematoma [11]. The authors of this report noted that the patient had no other past medical history or recent events to suggest any other etiology for the acute spinal subdural hematoma [11].

The final case report from this past decade looked at a 68 year old male patient who was on warfarin for atrial fibrillation and cerebrovascular disease, who presented to emergency department with 2-day history of persistent abdominal pain, vomiting, and constipation [12]. He had undergone an abdominal massage 3 days prior to presenting to the emergency department, as a part of physiotherapeutic intervention for chronic constipation [12]. His admission INR was 4.25 [12]. Abdominal X-ray showed air fluid levels suggesting a small bowel obstruction, and a CT of the abdomen showed a partial small bowel obstruction secondary to an intramural distal jejunum hematoma [12]. He was subsequently treated with bowel rest, nasogastric decompression, hydration, and vitamin K. He also received fresh frozen plasma, packed red blood cell transfusion, total parenteral nutrition, and discontinuing of the warfarin. He recovered uneventfully in 3 days [12]. Constipation is a common problem in the elderly, and laxative therapy and physiotherapy are not uncommon. Physiotherapy may consist of abdominal massage and exercise [13]. Patients with suspected abdominal obstruction, recent abdominal radiotherapy and surgery, intestine inflammation disease, irritable bowel syndrome, and pregnancy are contraindications for abdominal massage [14]. One case report from 1994 looked at a 62 year old male patient on warfarin after an aortic valve replacement with INR between 2.5 and 3.5, who developed a large back hematoma after his wife digitally massaged the area with 'Oil of Wintergreen'; a known topical salicylate [15]. Topical salicylates can affect the prothrombin time in patients on warfarin, resulting in bleeding complications [16].

Only two review papers looking at overall injuries from massage therapy have been published, and neither is very recent. One study looked at injuries reported in Medline related to the practice of therapeutic massage from 1965 to 2003, which found only 10 applicable case reports, and which ranged from dislodgement of a ureteral stent from deep massage to nerve injuries to hepatic hematoma [15,17]. The authors make five recommendations for safe practice of massage therapy: 1) practitioners should inquire if clients are being treated with anticoagulants; 2) practitioners should inquire if clients have medical appliances such as stents; 3) work done over a contusion or hematoma should be limited to lymphatic drainage, 4) caution should be used to not impinge superficial nerves against underlying bone, and 5) training programs should ensure that training in anatomical knowledge and technique is interspersed with practical experience sufficient to develop good kinesthetic/palpatory skills, awareness of client response, and clinical humility [17]. Although our patient was not on any anticoagulation, the history of chronic kidney disease may have contributed to the event. In addition, she had a history of lymphoma and was on the appropriate post-transplant medication regimen including acyclovir, sirolimus, and prednisone. It is unclear what role if any that these co-morbid issues played in the complication.

The most comprehensive systematic review to date of the safety of massage therapy is by E. Ernst et al., via literature searches of Medline, Embase, Cochrane, and AMED from 1995 to 2001, with a review of 31 relevant articles. This review concluded that adverse events from massage therapy are likely underreported. The authors further recommended a differentiation between various massage approaches [2]. Ernst suggests that massage by nonprofessionals and forceful techniques such as shiatsu, Urut, and Rolwing are more often associated with adverse outcomes as compared to other techniques [2]. However, the reports often do not include the background of the therapist or the type of massage therapy, making broad conclusions difficult [2]. Ultimately, too few clinical trials of massage therapy exist rendering adequate risk-benefit evaluations impossible [2,18,19]. Our patient underwent deep tissue massage by an experienced therapist but the actual methodology was unknown.

Two reviews looked at adverse effects from massage therapy in very specific patient populations. One review looked at whether

back massages are contraindicated after an acute myocardial infarction, and found that back massage can cause elevated blood pressure and decreased heart rate in normal patients, thus recommending that heart rate and blood pressure be monitored before and after a back massage to identify patients at risk for sympathetic stimulation [20]. Interestingly, a Cochrane review of massage therapy for preterm infants stated that no adverse effects of touch or massage were reported in any study [21].

## Conclusion

A paucity of literature exists with respect to massage therapy and the benefits or adverse outcomes. It is possible that these adverse effects are underreported, maybe due to lack of recognition or the belief that the event is isolated. Therefore, it is difficult to provide any clear recommendations on the ideal practices and to assess an individual patient's risk/benefits ratio for massage therapy. Our patient's experience and the reports identified however, would suggest that as a general principle, massage therapy, like all therapies, has risks and benefits, and should be used cautiously and judiciously.

## Contributors

CF, DJ, and OK are the sole contributors to this article.

## Competing interests

None declared.

## Patient consent

Detail has been removed from this case description to ensure anonymity.

## Funding

There were no external or internal funds provided.

## References

- [1] D. Eisenberg, R.B. David, S.L. Ettner, S. Appel, S. Wilkey, M. Van Rompay, R.C. Kessler, Trends in alternative medicine use in the United States, 1990–1997, *J. Am. Med. Assoc.* 280 (1998) 1569–1575.
- [2] E. Ernst, The safety of massage therapy, *Rheumatology (Oxford)* 42 (9) (2003) 1101–1106 (PMID: 12777645).
- [3] R.W. Rees, I. Feigel, A. Vickers, C. Zollman, R. McGurk, C. Smith, Prevalence of complementary therapy use by women with breast cancer: a population-based survey, *Eur. J. Cancer* 36 (2000) 1359–1364.
- [4] M.J. Verhoef, Physicians perspectives on massage therapy, *Can. Fam. Physician* 44 (1998) 1018.
- [5] P.D. Boutin, D. Buchwald, L. Robinson, A.C. Collier, Use of and attitudes about alternative and complementary therapies among outpatients and physicians at a municipal hospital, *J. Altern. Complement. Med.* 6 (2000) 335–343.
- [6] G.F. Wiesinger, M. Quittan, G. Ebenbichler, V. Fialka, Benefit and costs of passive modalities in back pain outpatients: a descriptive study, *Eur. J. Phys. Med. Rehabil.* 7 (1997) 182–186.
- [7] S. Fu, Y. Qi-Ling, Y.G. Zhang, Large buttocks hematoma caused by deep tissue massage therapy, *Pain Med.* 16 (2015) 1445–1451 (PMID: 26176792).
- [8] C. Waters-Banker, E.E. Dupont-Versteegden, P.H. Kitzman, T.A. Butterfield, Investigating the mechanisms of massage efficacy: the role of mechanical immunomodulation, *J. Atl. Train.* 29 (2) (2014) 266–273.
- [9] P. Weerapong, P.A. Hume, G.S. Kolt, The mechanisms of massage and effects on performance, muscle recovery, and injury prevention, *Sports Med.* 35 (3) (2005) 235–256.
- [10] A.D. Gepner, C.E. Korcarz, L.A. Colangelo, E.K. Hom, M.C. Tattersall, B.C. Astor, J.D. Kaufman, K. Liu, J.H. Stein, Longitudinal effects of a decade of aging on carotid artery stiffness: the multiethnic study of atherosclerosis, *Stroke* 45 (1) (2014) 48–53.
- [11] M.M.D. Praful, M.D. Sang-Hoon Paik, J.K. Oh, Y.C. Kim, M.S. Park, T.H. Kim, Y.H. Kwak, J.K. Jung, H.W. Lee, S.W. Kim, Acute spinal subdural hematoma after vigorous back massage, *Spine* 39 (25) (2014) E1545–E1548 (25271505).
- [12] H.M.D. Chen, C.M.D. Wu, A.C. Lin, Small bowel intramural hematoma secondary to abdominal massage, *Am. J. Emerg. Med.* 31 (2013) 758 (e3-758.e4. 23380131).
- [13] R. Addison, C. Davies, D. Haslam, M. Powell, L. Stowers, National audit of chronic constipation in the community, *Nurs. Times* 99 (11) (2003) 34–35.
- [14] A. Pyszora, M. Krajnik, The role of physiotherapy in palliative care for the relief of constipation - a case report, *Adv. Palliat. Med.* 9 (2010) 45–48.
- [15] T.C. Yeo, M.H.H. Choo, M.B. Tay, Massive haematoma from digital massage in an anticoagulated patient: a case report, *Singap. Med. J.* 35 (3) (1994) 319–320 (PMID: 7997915).
- [16] F. Littleton, Warfarin and topical salicylates, *JAMA* 263 (1990) 2888.
- [17] K.E. Grant, Massage safety: injuries reported in Medline as related to the practice of therapeutic massage-1965 to 2003, *J. Bodyw. Mov. Ther.* 7 (40) (2003) 207–212.
- [18] E. Ernst, V. Fialka, The clinical effectiveness of massage therapy - a critical review, *Forsch. Komplementmed.* 1 (1994) 226–232.
- [19] A. Vickers, Yes, but how do we know it's true? Knowledge claims in massage and aromatherapy, *Complement. Ther. Nurs. Midwifery* 3 (1997) 63–65.
- [20] S. Dunbar, E. Redick, Should patients with acute myocardial infarctions receive back massage? *Focus Crit. Care* 13 (1986) 42–46.
- [21] A. Vickers, A. Ohlsson, J.B. Lacy, A. Horsley, Massage therapy for preterm and/or low birth-weight infants, *Cochrane Libr* 1 (2000) 1–23.