



# Comparison of Canine Overlap in Pediatric Patients Requiring Stainless Steel Crown Placement under General Anesthesia before and after the Procedure

Sara Ghadimi<sup>1,2</sup>, Bahman Seraj<sup>2,3</sup>, Abbas Ostadalipour<sup>4</sup>, Elnaz Askari<sup>2\*</sup>

1. Laser Research Center of Dentistry, Dentistry Research Institute, Tehran University of Medical Sciences, Tehran, Iran
2. Department of Pediatric Dentistry, School of Dentistry, Tehran University of Medical Sciences, Tehran, Iran
3. Dental Research Center, Dentistry Research Institute, Tehran University of Medical Sciences, Tehran, Iran
4. Department of Anesthesiology and Critical Care, Farabi Hospital, Tehran University of Medical Sciences, Tehran, Iran

## Article Info

**Article type:**  
Original Article

## Article History:

Received: 29 June 2018  
Accepted: 7 August 2018  
Published: 20 January 2019

## \* Corresponding author:

Department of Pediatric Dentistry,  
School of Dentistry, Tehran University of  
Medical Sciences, Tehran, Iran

Email: lnz.askari@gmail.com

## ABSTRACT

**Objectives:** Despite the increasing popularity of pediatric dental treatments under general anesthesia, information is scarce regarding occlusal changes in patients receiving stainless steel crowns (SSCs) under general anesthesia. This study sought to compare canine overlap before and after general anesthesia in children receiving SSCs. In case of a change, the possibility of returning to the preoperative state and the time required for this process were also evaluated.

**Materials and Methods:** This interventional, before-and-after study was performed on 60 children between 2 to 7 years of age requiring dental treatment under general anesthesia. The contact point of the most prominent area of the maxillary primary canine and mandibular primary canine was marked before and immediately after general anesthesia and at one and two weeks postoperatively. The change in canine overlap was analyzed using repeated measures analysis of variance (ANOVA) and linear regression test.

**Results:** Canine overlap significantly decreased immediately after general anesthesia ( $P < 0.05$ ). The mean bite opening was  $0.51 \pm 0.22$  mm at the site of the right canine and  $0.50 \pm 0.185$  mm at the site of the left canine. These values returned to their normal preoperative state after one week ( $P < 0.05$ ). Repeated measures ANOVA showed significant differences in this respect between the time points ( $P = 0.002$ ).

**Conclusion:** The occlusion and vertical dimension of pediatric patients may change following dental treatment under general anesthesia; the magnitude of change in canine overlap may vary depending on the class of occlusion and number of SSCs placed. These changes are temporary and often resolve within a week.

**Keywords:** Canine; Overbite; Occlusion; General Anesthesia; Stainless Steel; Crowns

- **Cite this article as:** Ghadimi S, Seraj B, Ostadalipour A, Askari E. Comparison of Canine Overlap in Pediatric Patients Requiring Stainless Steel Crown Placement under General Anesthesia before and after the Procedure. *Front Dent.* 2019;16(1):78-87. doi: 10.18502/ffd.v16i1.1113

## INTRODUCTION

Dental caries is a common chronic disease of the childhood [1,2]. Despite the recent reduction in the prevalence of caries in permanent teeth, the prevalence of caries in primary teeth is still high and even growing in some parts of the world [3,4]. Primary teeth serve as space maintainers in the dental arch [1]. They also play important

roles in efficient mastication and maturity of the masticatory system as well as facial esthetics. Psychologically, they play a critical role in the self-confidence of children as well [1,3,5]. The attitude of the parents towards dental treatment of their children has greatly changed in recent years [6], and restoration and preservation of primary teeth have become a

priority for many parents [7, 8]. On the other hand, increased frequency of dental treatments in younger children, who are often uncooperative, has increased the tendency of dentists towards the provision of dental procedures under general anesthesia [9]. The popularity of dental treatments under general anesthesia has also increased among parents [1,10].

Stainless steel crowns (SSCs) are among the most commonly used modalities for restoration of severely decayed primary teeth due to their easy use and optimal durability [11,12]. This modality is often preferred to amalgam and composite restorations for multi-surface restoration of posterior teeth in children under general anesthesia [9,13-15]. SSCs are indicated for restoration of primary molars with more than two decayed surfaces or extensive caries in one or two surfaces, pulpotomized and pulpectomized teeth, broken primary molars, teeth subjected to severe attrition, abrasion or erosion, patients at high risk of caries, those with poor oral hygiene, and patients requiring dental restorative treatments under general anesthesia [11].

Selection of an SSC with an adequate occlusogingival height and well-fitted margins is among the common concerns of pediatric dentists since premature contacts and occlusal interference can have serious consequences such as root resorption, endodontic treatment failure, pain, and abscess formation [16]. Occlusal interference can also lead to parafunctional habits such as bruxism and clenching [17,18] and eventually result in wear, deformation or perforation of the crown. General anesthesia is a reversible drug-induced condition characterized by unconsciousness, immobility, and analgesia with continuous stabilization of the autonomous, cardiovascular, and respiratory systems and body temperature [19,20]. Some studies have recommended frequent closure of the mouth in pediatric patients receiving dental treatment under general anesthesia to check their occlusion [13,14]. However, the function of the autonomous nervous system and skeletal muscles responsible for mouth closure is impaired during general anesthesia. Thus, closure of the patient's mouth under general anesthesia by the clinician does not provide accurate information about the patient's occlusion [20,21].

Moreover, time limitation, oral intubation of some patients, an inappropriate position of the tongue due to pharyngeal pack placement, and relaxation of the tongue muscle can all interfere with accurate assessment of the patient's occlusion under general anesthesia [22].

Several methods can be used for checking the occlusal contacts in pediatric patients receiving SSCs without general anesthesia, which include comparison of the distance between two certain intraoral points such as upper and lower canine overlap before and after the placement of SSC [23] or use of digital devices such as T-Scan for assessment of occlusal forces [24].

Children requiring dental treatment under general anesthesia often need several posterior restorations. However, the occlusion of these patients and its alteration after placement of SSCs under general anesthesia have not been extensively studied. Moreover, the time required for the return of the altered occlusion to its baseline state is a matter of question. Thus, this study aimed to assess and compare canine overlap in children requiring SSC placement under general anesthesia before and after the procedure. In case of a change, the possibility of returning to the preoperative state and the time required for this process were also evaluated.

## MATERIALS AND METHODS

This interventional, before-and-after study evaluated 60 children between the ages of 2 to 7 years presenting to the School of Dentistry, Tehran University of Medical Sciences, Tehran, Iran, who required dental treatment under general anesthesia due to the following reasons [1,3]:

(I) uncooperative patients (emotional or psychological immaturity or disability), (II) uncooperative, fearful, anxious or inflexible children with communication difficulties and in need of major dental treatments (their behavior was not expected to improve in the near future), (III) patients requiring immediate, extensive, and comprehensive dental treatment, and (IV) patients whose dental treatment was necessary for their psychological development or would reduce the risk of medical problems.

The present study has been approved by the ethics committee of the School of Dentistry, Tehran University of Medical Sciences (IR.TUMS.DENTISTRY.REC.1396.3670).

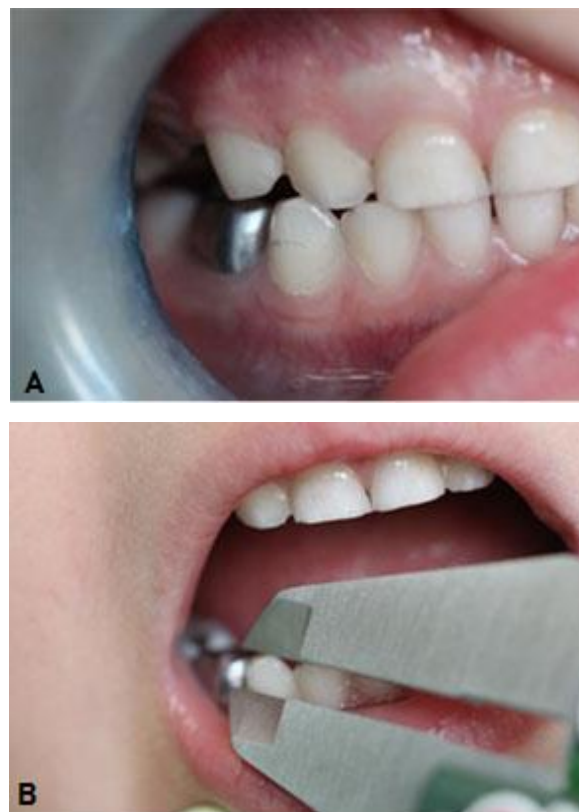
The minimum sample size was calculated to be 51 patients by performing a pilot study on 9

patients, which yielded a standard deviation (SD) of 1.07 mm for the change in the overlap. Considering 0.5mm difference as critical difference in overlap,  $\alpha=0.05$ , and  $\beta=0.1$ , the sample size was calculated using the paired mean power analysis feature of PASS 11 software (NCSS, LLC, Kaysville, Utah, USA). Thus, 60 patients were enrolled considering the possibility of dropouts and loss to follow-up.

The need for dental treatment under general anesthesia in all patients was confirmed by a pediatric dentist who was also a faculty member of the School of Dentistry, Tehran University of Medical Sciences. Prior to general anesthesia, the children were examined by an anesthesiologist and an internal medicine specialist, and the necessary paraclinical tests were requested. Patients who met all the eligibility criteria were enrolled. Written informed consent was obtained from the parents or legal guardians of all children. The patients were also clinically and radiographically examined, and those who required SSC placement (from 1 to 8 SSCs) and had primary canines without Class IV caries, built-up crowns, extensive caries involving two-thirds of the incisal and palatal surfaces or any incisal edge involvement were chosen. On the day of the procedure, a questionnaire asking for previous dental treatments of the child and his/her medical history was filled out by the parents. Those who were not willing to participate were not included. The suggested treatment plan, the position of canines, and the presence/absence of primary second molars in functional occlusion were also recorded. The vertical overlap of upper and lower primary canines was determined by marking the contact point of the most prominent part of the upper primary canines over the lower primary canines on the right and left sides using a sharp pencil (Fig. 1A).

The distance from this point to the tip of the lower primary canine was measured using a digital caliper (INSIZE Co., Ltd., Germany) with the accuracy of  $\pm 0.02$  mm (Fig. 1B). The measured values were recorded. This measurement was made while the child was held by the parent, and his/her head was supported by the non-working arm of the parent. The highest part of the drawn line was considered as the reference line. For further accuracy, this was repeated twice and in case of

the presence of a difference, the measurement was repeated for the third time, and the mean of the values was calculated.



**Fig. 1.** (A) Measuring canine overlap by marking the contact point of the most prominent part of the upper primary canine with the lower primary canine. (B) Measurement of the distance by a digital caliper

All the measurements were made by a single examiner. The measurements were made in the maximum intercuspation position (MIP) in the centric occlusion (CO) guided by appropriate methods according to the child's age (guiding with hand, swallowing his/her saliva, and sticking the tongue to the palate).

The treatment was performed under general anesthesia.

Tooth preparation was done according to the principles of Spedding [25] to have 1-mm clearance between the respective tooth and the opposing tooth [1,3,13,26], and SSCs (3M ESPE, St. Paul, MN, USA) were seated.

After discharging the patient from the recovery room and reestablishment of the function of the facial muscles, some simple questions were asked of the patient to ensure his/her consciousness. Next, the occlusion was checked,

and the canine overlap was recorded again as explained earlier. In case of a change in canine overlap by more than 0.1 mm, the patient was followed up for one or two weeks until the baseline occlusion was reinstated. A free-of-charge fluoride therapy was performed for all patients showing up for follow-up sessions, and they were provided with gifts such as toothbrush and toothpaste packs. The tell-show-do behavioral technique was employed for measurement in uncooperative children. Oral hygiene instructions were also provided. Data were analyzed using repeated measures analysis of variance (ANOVA) and linear regression test via SPSS software (version 22; SPSS Inc., Chicago, IL, USA). The level of significance was set at  $P < 0.05$ .

## RESULTS

A total of 60 children with a mean age of 44.33 months (ranging from 22 to 109 months) participated in this study. 50% of the patients were males and 50% were females. In 91.7% of the children, primary second molars were in functional occlusion, while primary second molars had not erupted in 8.3% of the patients or were not in occlusion. Of all, 76.7% had Class I canine relationship, 18.3% had Class II canine relationship, and 5% had Class III canine relationship.

Table 1 shows the number of SSCs placed under general anesthesia and their frequency percentage. As shown in Table 1, 48.3% of the children had received 4 or fewer SSCs. More than 50% of the children had received 4 or a higher number of SSCs. Primary anterior teeth were not extracted in 75% of the cases, while all four primary anterior teeth were extracted in 20% of the children. Table 2 shows dental treatments performed on primary molars.

**Table 1.** Number, frequency and percentage of stainless steel crowns placed under general anesthesia

No.	Frequency	Percentage	Accumulative percentage
1	2	3.3	3.3
2	3	5	8.3
3	6	10	18.3
4	18	30	48.3
5	8	13.3	61.7
6	8	13.3	75.0
7	6	10	85.0
8	9	15	100.0

Table 3 shows the amount of canine overlap before anesthesia, immediately after anesthesia, and at one and two weeks postoperatively on the right and left sides. Also, the difference in canine overlap after anesthesia and at one and two weeks postoperatively was calculated by subtracting the pre- and postoperative values (Table 4).

As shown in Table 4, canine overlap significantly decreased immediately after general anesthesia, and the mean bite opening was  $0.51 \pm 0.22$  mm at the site of the right canine ( $\geq 0.1$  mm in 45% of the children) and  $0.50 \pm 0.18$  mm at the site of the left canine ( $> 0.1$  mm in 41.7% of the children;  $P < 0.05$ ); this difference became smaller after one and two weeks and approximated zero after one week.

The reduction in the difference was significant after one week, and the value approximated the baseline overlap value. In 15% of the cases, the change in canine overlap was  $\pm 0.02$  mm (equal to the accuracy of the caliper). Repeated measures ANOVA was applied to analyze the difference in canine overlap at different time points, which showed a significant difference between different time points ( $P = 0.002$ ; Table 5).

**Table 2.** Frequency percentage of treatments performed on primary molars

Treatment	Tooth							
	Upper right D	Upper left D	Lower right D	Lower left D	Upper right E	Upper left E	Lower right E	Lower left E
Amalgam, composite, preventive resin restoration, fissure sealant or no treatment	10	6.7	13.3	8.3	58.3	53.3	48.3	40
SSC	80	78.3	68.3	81.7	40	45.0	48.3	58.3
Tooth extraction	10	15	18.3	10.0	1.7	1.7	3.3	1.7

**Table 3.** Canine overlap (mm) at different time points on the right and left sides

Tooth/Time point	Minimum	Maximum	Mean	SD
Right canine preoperatively	1.50	6.58	3.70	1.04
Left canine preoperatively	1.96	6.25	3.62	0.95
Right canine immediately after anesthesia	0.00	6.51	3.47	1.13
Left canine immediately after anesthesia	0.00	6.16	3.44	1.11
Right canine one week after anesthesia	1.50	6.51	3.66	1.02
Left canine one week after anesthesia	1.34	6.16	3.62	0.99
Right canine two weeks after anesthesia	1.50	6.51	3.70	1.01
Left canine two weeks after anesthesia	1.85	6.16	3.64	0.96

SD: Standard Deviation

**Table 4.** Difference in canine overlap (mm) at different time points

Tooth/Time point	Maximum*	Minimum*	Mean	SD
Right canine immediately after anesthesia	-1.59	0.51	-0.22	0.51
Left canine immediately after anesthesia	-2.50	0.98	-0.18	0.50
Right canine one week after anesthesia	-1.38	0.46	-0.03	0.29
Left canine one week after anesthesia	-0.67	0.98	0	0.24
Right canine two weeks after anesthesia	-1.38	0.46	0	0.24
Left canine two weeks after anesthesia	-0.67	0.98	0.02	0.22

\*Difference in overlap was calculated by subtracting the baseline value from the value at the respective time point (immediately after anesthesia and one and two weeks later); SD: Standard Deviation

**Table 5.** Difference in overlap (mm) at different time points according to repeated measures analysis of variance

Time point*	Difference of means**	Standard Error	P-value	95% CI for the difference		
				Lower bound	Upper bound	
1	2	0.223*	0.066	0.001	0.092	0.354
	3	0.035	0.038	0.348	-0.040	0.111
	4	-0.004	0.031	0.884	-0.066	0.057
2	1	-0.223*	0.066	0.001	-0.354	-0.092
	3	-0.188*	0.050	0.000	-0.288	-0.087
	4	-0.227*	0.055	0.000	-0.338	-0.117
3	1	-0.035	0.038	0.348	-0.111	0.040
	2	0.188*	0.050	0.000	0.087	0.288
	4	-0.040	0.021	0.060	-0.082	0.002
4	1	0.004	0.031	0.884	-0.057	0.066
	2	0.227*	0.055	0.000	0.117	0.338
	3	0.040	0.021	0.060	-0.002	0.082

\*Time point (1): baseline, (2): immediately after anesthesia, (3): one week after anesthesia, (4): two weeks after anesthesia, \*\*Difference in canine overlap at the baseline (before surgery) and overlap at the respective time point, \*Time points at which P<0.05; CI=Confidence Interval

As shown in Table 5, the difference in canine overlap before and at one and two weeks after the procedure and immediately after general anesthesia was statistically significant (P<0.05). Linear regression was applied to assess the effect of age, gender, the number of extracted

anterior and posterior teeth, total number of SSCs placed, the number of SSCs placed in the same quadrant, SSCs placed in the opposing quadrant, the class of occlusion, and the eruption status of primary second molars on the magnitude of change in canine overlap (Table 6).



**Table 6.** Results of regression model regarding the effect of different variables on canine overlap

Variants	Unstandardized Coefficients		Significance
	B	Standard Error	
OCC	-0.27	0.11	0.015
RUD	0.25	0.14	0.074
RUE	0.28	0.15	0.074
LUE	-0.40	0.16	0.015
LLE	0.30	0.16	0.071

OCC: Occlusion, RUD: Right Upper D, RUE: Right Upper E, LUE: Left Upper E, LLE: Left Lower E, B: unstandardized beta (the slope of the line between the predictor and dependent variables)

This analysis showed a significant difference in the results with regard to the class of occlusion ( $P=0.015$ ) such that Class III canine relationship resulted in a greater bite opening (a more negative value was obtained). Moreover, the reduction in canine overlap according to the type of treatment was different for posterior teeth. In other words, SSC placement resulted in a greater bite opening and reduction of canine overlap compared to other treatments such as amalgam and composite restorations, fissure sealant therapy, and no treatment ( $P<0.05$ ). Linear regression analysis found no significant association between the number of extracted teeth, the presence of primary second molars in functional occlusion, and gender with canine overlap ( $P>0.05$ ).

## DISCUSSION

Complete oral rehabilitation by several dental restorations improves the mastication in children [27,28]. Also, evidence shows the significant effect of restoration of caries on the growth and development of children and their psychological well-being [27,29-31]. SSCs are extensively used for restoration of primary molars [9,32,33]. Selection of a crown that efficiently covers all dental surfaces and provides adequate occlusion is important for the reconstruction of severely carious primary teeth. However, some premature contacts may be encountered following placement of SSCs due to inadequate tooth preparation, incorrect/incomplete seating of SSCs during cementation or placing an SSC larger than the tooth. Premature contacts and occlusal interference can have serious consequences such as root resorption or endodontic

treatment failure in case of traumatic occlusion [16]. Despite the significance of this topic, occlusal changes after placement of SSCs have not been extensively studied [24,34].

Conventionally, the occlusion should be clinically checked by dental clinicians after placement of SSCs, and occlusal adjustment should be performed if necessary. However, this would be difficult to achieve under general anesthesia because it would be time-consuming and inaccurate [16].

This study compared canine overlap before and after general anesthesia in children receiving SSCs under general anesthesia. In case of a change, the possibility of the return of the overlap to the preoperative state and the time required for this process were also evaluated. The results showed that canine overlap significantly decreased immediately after general anesthesia. The mean bite opening was  $0.51\pm 0.22$  mm at the site of the right canine ( $\geq 0.1$  mm in 45% of the cases) and  $0.50\pm 0.185$  mm at the site of the left canine ( $>0.1$  mm in 41.7% of the cases). These values returned to their normal preoperative state after one week ( $P<0.05$ ). Repeated measures ANOVA showed significant differences between the time points in this respect ( $P=0.002$ ). A search of the literature by the authors yielded only one relatively similar previous study on this topic. Alshareef et al [34] evaluated the bite pattern of children with severe early childhood caries before and after the complete restoration of all teeth under general anesthesia and concluded that placement of SSCs significantly improved their mastication. The number of force outliers and occlusal interference increased by 100% during the first week but a reduction in their overall number occurred at the end of one month, and this value decreased to 40% [34]. In our study, the difference in canine overlap, which was observed immediately after general anesthesia, approximated zero at the end of the first week, which was in contrast to the results reported by Alshareef et al [34] who reported 100% increase after one week. However, their methodology was different from ours since they did not assess the interference immediately after anesthesia. Moreover, they used a digital device for their assessment. Nevertheless, both studies showed that this difference eventually decreased, and the occlusion returned to its baseline state after a while.

Gallagher et al [24] evaluated the occlusion after placement of SSCs in children using T-Scan III. In contrast to our study, they performed this assessment on individual teeth. They reported that general anesthesia did not have any effect on the child reaching the maximum intercuspation. In addition, the maximum intercuspation was impaired in seven out of 20 children after placement of SSCs, and in most of them, it returned to its baseline state four weeks after the treatment [24]. In our study, changes in canine overlap approximated zero one week after general anesthesia.

Assessment of occlusion under general anesthesia is extremely difficult, and studies on this topic are scarce. Some researchers have recommended frequent closure of the mouth by the clinician to check the occlusion of SSCs under general anesthesia [13,14]. However, this method is time-consuming, inaccurate, and not practical in most cases. Dimashkieh and Pani [35] suggested the use of an occlusal template to check the occlusion of SSCs under general anesthesia. They evaluated 60 patients between the ages of 4 and 7 years and fabricated a template using a fast-set polyvinyl siloxane which had optimal dimensional stability and a one-minute procedure time; however, it had a soft consistency which may be dangerous, inaccurate or unpractical for use in children under general anesthesia since the protective functions of the muscles are impaired under general anesthesia, and the patient is in supine position. They reported that this method was less time-consuming than the frequent closure of the mouth under general anesthesia, and fewer patients complained of occlusal interference within the first 24 hours after the procedure (compared to the frequent mouth closure method). However, the difference in this respect between the two methods was not significant at one week, three months, and six months, and the success rate of SSCs was 96.2% in the control group and 98.3% in the test group after 6 months [35]. In our study, canine overlap returned to its normal baseline state after one week, which was in line with the results reported by Dimashkieh and Pani [35].

Norna Hall introduced the Hall technique which describes the placement of SSC without requiring anesthesia or tooth preparation [13,15,23, 36, 37]. In 2010, van der Zee and van Amerongen [23] evaluated the effect of the Hall

technique on the vertical dimension of primary teeth. They placed SSCs for 48 patients and showed that the mean distance between the canine tips decreased from 2.45 mm at the baseline to 0.54 mm immediately after the placement of SSCs. After 15 days, canine overlap increased from 0.54 mm to 1.96 mm, and after 30 days, this value increased to 2.75 mm although many patients were lost to follow-up at this time point [23]. In our study, canine overlap returned to the normal preoperative state within one week. This difference between the two studies is justifiable considering the greater difference in the mean distance between canine tips before and after placement of SSCs using the Hall technique (due to the lack of tooth preparation) compared to the mean distance between canine tips in our study ( $0.51 \pm 0.22$  mm at the site of the right canine and  $0.50 \pm 0.18$  mm at the site of the left canine). No previous study has assessed the correlation of the class of occlusion, tooth extraction, the number of SSCs placed, and gender with the change in the overlap of canines and the occlusion after treatment. Our results revealed a significant association between Class III canine relationship and bite opening, which may be due to the spatial relationship of the mandible and the maxilla. Considering the fact that the mandibular canine is farther from the center of rotation, even a small space created by bite opening in the posterior region would result in a greater bite opening in the anterior region; this is justifiable considering the extent of SSC restoration compared to other restorations as well as the flexibility and shaping ability of amalgam and composite restorations. Evidence shows that mild premature contacts less than 1 mm are well tolerated by children in the primary or early mixed dentition periods and are clinically compensated within a few weeks. The dentoalveolar complex probably adapts to occlusal interference in growing children [11, 13,15,16,24,34-36,38] but interferences greater than 1 or 1.5 mm should be corrected [11].

In the current study, tooth preparation was performed according to the principles of Spedding [25] to have 1-mm clearance between the respective tooth and the opposing tooth [1,3,13,26].

We did not check the occlusion or the bite of patients under general anesthesia due to several reasons such as the presence of a

pharyngeal pack which pushes the tongue forward and makes it difficult to close the mouth, swelling of the tongue, and relaxation of the muscles, which would lead to inaccuracy of the occlusal check. The results indicated that 8 out of 60 patients (13.3%) showed a reduction in overlap by  $\geq 1$  mm at the site of the right canine. At the site of the left canine, 3 patients (5%) showed  $\geq 1$  mm difference in canine overlap; however, this difference approximated zero within one week. This finding was in line with the results of studies that used more advanced techniques such as a T-Scan and concluded that the number of force outliers decreased at the end of one month [34]. However, this occurred faster in our study. In general, our findings showed that occlusal check is not necessarily required in patients receiving SSCs following tooth preparation under general anesthesia, and the interferences, in case of occurrence, would resolve within a week. Our study was performed on children in the primary dentition period. Further studies are required to assess patients in the early primary and late primary dentition periods. The size of SSCs was not evaluated in this study. Further studies should take into account the size of the selected SSC in relation to the size of the tooth and its effect on the results. Similar studies are required on larger sample sizes.

## CONCLUSION

Within the limitations of this study, it may be concluded that there is a possibility of change in the occlusion and vertical dimension following placement of SSCs under general anesthesia. The magnitude of this change may vary depending on the class of occlusion and the number of crowns placed in one quadrant. However, given that the principles of tooth preparation have been followed, this change would be temporary and would significantly improve/resolve after one week. Therefore, parents must be informed about the possibility of occlusal interference after the procedure and ensured that this would resolve by itself. Also, patients should be ideally recalled after one week for an occlusal check. In our study, the magnitude of the change in canine overlap was greater in patients with Class III canine relationship. This change was greater in patients receiving SSCs compared to other restorative procedures or no treatment.

## REFERENCES

1. McDonald RE, Avery DR, Stookey GK, Chin JR, Kowolik JE. Dental caries in the child and adolescent, in McDonald and Avery Dentistry for the Child and Adolescent. St. Louis, Mo: Mosby Elsevier, 2016:418.
2. Oral health in America: a report of the Surgeon General. J Calif Dent Assoc. 2000 Sep;28(9):685-95.
3. Nowak AJ, Casamassimo PS, American Academy of Pediatric Dentistry. The Handbook of Pediatric Dentistry. Chicago, IL, USA, American Academy of Pediatric Dentistry, 2012:2-5.
4. Harris NO, Garcia-Gobody F, Nathe CN. Primary Preventive Dentistry. Upper Saddle River, New Jersey, USA, Pearson Education, 2014:297.
5. Ward SC, Molnar S. Experimental stress analysis of topographic diversity in early hominid gnathic morphology. Am J Phys Anthropol. 1980 Sep;53(3):383-95.
6. Holan G, Rahme MA, Ram D. Parents' attitude toward their children's appearance in the case of esthetic defects of the anterior primary teeth. J Clin Pediatr Dent. 2009 Winter;34(2):141-5.
7. Ngan P, Fields H. Orthodontic diagnosis and treatment planning in the primary dentition. ASDC J Dent Child. 1995 Jan-Feb;62(1):25-33.
8. Patil RU, Sahu A, Kambalimath HV, Panchakshari BK, Jain M. Knowledge, attitude and practice among dental practitioners pertaining to preventive measures in pediatric patients. J Clin Diagn Res. 2016 Dec;10(12):ZC71-ZC75.
9. Blumer S, Costa L, Peretz B. Success of dental treatments under behavior management, sedation and general anesthesia. J Clin Pediatr Dent. 2017;41(4):308-11.
10. Patel M, McTigue DJ, Thikkurissy S, Fields HW. Parental attitudes toward advanced behavior guidance techniques used in pediatric dentistry. Pediatr Dent. 2016 Jan-Feb;38(1):30-6.
11. Kindelan SA, Day P, Nichol R, Willmott N, Fayle SA; British Society of Paediatric Dentistry. UK National Clinical Guidelines in Pediatric Dentistry: stainless steel preformed crowns for primary molars. Int J Paediatr Dent. 2008 Nov;18 Suppl 1:20-8.
12. Attari N, Roberts JF. Restoration of primary teeth with crowns: a systematic review



of the literature. *Eur Arch Paediatr Dent.* 2006 Jun;7(2):58-62; discussion 63.

13. Seale NS. The use of stainless steel crowns. *Pediatr Dent.* 2002 Sep-Oct;24(5):501-5.

14. Al-Eheideb AA, Herman NG. Outcomes of dental procedures performed on children under general anesthesia. *J Clin Pediatr Dent.* 2003 Winter;27(2):181-3.

15. Innes NP, Ricketts D, Chong LY, Keightley AJ, Lamont T, Santamaria RM. Preformed crowns for decayed primary molar teeth. *Cochrane Database Syst Rev.* 2015 Dec 31;(12):CD005512.

16. Pani SC, Dimashkieh M, Mojaleed F, Al Shammery F. The role of an occlusal template during the placement of preformed metal crowns in children under general anesthesia: a randomized control trial. *Eur Arch Paediatr Dent.* 2015 Dec;16(6):461-6.

17. Le Bell Y, Niemi PM, Jämsä T, Kylmä M, Alanen P. Subjective reactions to intervention with artificial interferences in subjects with and without a history of temporomandibular disorders. *Acta Odontol Scand.* 2006 Feb;64(1):59-63.

18. Egermark-Eriksson I, Carlsson GE, Magnusson T. A long-term epidemiologic study of the relationship between occlusal factors and mandibular dysfunction in children and adolescents. *J Dent Res.* 1987 Jan;66(1):67-71.

19. Evers AS, Crowder CM. Cellular and molecular mechanisms of anesthesia. *J Clin Anesth.* 2006 Jan;5:111-32.

20. Brown EN, Lydic R, Schiff ND. General anesthesia, sleep, and coma. *N Engl J Med.* 2010 Dec 30;363(27):2638-50.

21. Miller RD. *Miller's Anesthesia.* Philadelphia: Churchill Livingstone, Elsevier Saunders, 2015:509-514.

22. Needleman HL, Harpavat S, Wu S, Allred EN, Berde C. Postoperative pain and other sequelae of dental rehabilitations performed on children under general anesthesia. *Pediatr Dent.* 2008 Mar-Apr;30(2):111-21.

23. van der Zee V, van Amerongen WE. Short communication: Influence of preformed metal crowns (Hall technique) on the occlusal vertical dimension in the primary dentition. *Eur Arch Paediatr Dent.* 2010 Oct;11(5):225-7.

24. Gallagher S, O'Connell BC, O'Connell AC. Assessment of occlusion after placement of stainless steel crowns in children - a pilot study. *J Oral Rehabil.* 2014 Oct;41(10):730-6.

25. Spedding RH. Two principles for improving the adaptation of stainless steel crowns to primary molars. *Dent Clin North Am.* 1984 Jan;28(1):157-75.

26. Randall RC. Preformed metal crowns for primary and permanent molar teeth: review of the literature. *Pediatr Dent.* 2002 Sep-Oct;24(5):489-500.

27. Mishra A, Pandey R, Pandey N, Jain E. A pedoprosthesis rehabilitation in patients with severe early childhood caries (S-ECC). *BMJ Case Rep.* 2013 Jul 9;2013: bcr2013010269.

28. Subramaniam P, Girish Babu KL, Ifzah. Effect of restoring carious teeth on occlusal bite force in children. *J Clin Pediatr Dent.* 2016;40(4):297-300.

29. Monse B, Duijster D, Sheiham A, Grijalva-Eternod CS, van Palenstein Helderman W, Hobdell MH. The effects of extraction of pulpally involved primary teeth on weight, height and BMI in underweight Filipino children. A cluster randomized clinical trial. *BMC Public Health.* 2012 Aug 31;12:725.

30. Sheiham A. Dental caries affects body weight, growth and quality of life in pre-school children. *Br Dent J.* 2006 Nov 25;201(10):625-6.

31. de Paula JS, Sarracini KL, Meneghim MC, Pereira AC, Ortega EM, Martins NS, et al. Longitudinal evaluation of the impact of dental caries treatment on oral health-related quality of life among schoolchildren. *Eur J Oral Sci.* 2015 Jun;123(3):173-8.

32. Hyde AC, Rogers HJ, Batley HA, Morgan AG, Deery C. An Overview of Preformed Metal Crowns. Part 2: The Hall Technique. *Dent Update.* 2015 Dec;42(10):939-42, 944.

33. Prabhakar AR, Yavagal CM, Chakraborty A, Sugandhan S. Finite element stress analysis of stainless steel crowns. *J Indian Soc Pedod Prev Dent.* 2015 Jul-Sep;33(3):183-91.

34. Alshareef AA, Alkhuriaf A, Pani SC. An evaluation of bite pattern in children with severe-early childhood caries before and after complete dental rehabilitation. *Pediatr Dent.* 2017 Nov 1;39(7):455-9.

35. Dimashkieh M, Pani SC. A novel technique to check the occlusion during the placement of stainless steel crowns under general anesthesia. *Saudi J Oral Sci.* 2015 Jan;2(1):49-51.

36. Innes NP, Evans DJ, Bonifacio CC, Geneser M, Hesse D, Heimer M, et al. The Hall Technique 10 years on: Questions and answers.

Br Dent J. 2017 Mar 24;222(6):478-83.

37. Bell SJ, Morgan AG, Marshman Z, Rodd HD. Child and parental acceptance of preformed metal crowns. Eur Arch Paediatr Dent. 2010 Oct;11(5):218-24.

38. Ludwig KH, Fontana M, Vinson LA, Platt JA, Dean JA. The success of stainless steel crowns placed with the Hall technique: a retrospective study. J Am Dent Assoc. 2014 Dec;145(12):1248-53.