

2D echo can depict such findings, it is user dependent with a limited acoustic window for imaging all parts of the heart. Cardiac CTA is therefore an ideal imaging modality for CA abnormalities.

Treatment should be initiated as soon as the diagnosis is confirmed, to avoid complications. Asymptomatic ARAT can be supportively managed by use of diuretics and other medications to reduce cardiac afterload, with regular monitoring. However, symptoms inevitably worsen, and fistula closure is the definitive management.^[7] Curative options include simple ligation, or ligation with reimplantation of coronary ostium or coil embolisation in selected cases. Direct closure of the atrial opening is done with a patch of aortic origin or plication of the tunnel. If the origin of the CA is deep in the tunnel, it should be reimplanted with a part of the tunnel into the respective sinus of Valsalva.^[2]

In conclusion, ARAT is a rare congenital heart disease that is accurately diagnosed on CTA. CTA helps formulate management guidelines, which are dependent on the size and location of the tunnel, haemodynamic factors, and complications. It is ideal for follow-up of conservatively managed cases. Early diagnosis of ARAT improves prognosis and reduces postoperative morbidity.

T Kalekar, MBBS, MD (Radiodiagnosis)

Department of Radiodiagnosis, Dr D Y Patil Medical College, Hospital and Research Centre, Pune, Maharashtra, India

A S Prabhu, MBBS 

Department of Radiodiagnosis, Dr D Y Patil Medical College, Hospital and Research Centre, Pune, Maharashtra, India
aparnaprabhu5@gmail.com

D Dilip, MBBS, MD (Radiodiagnosis)

Department of Radiodiagnosis, Dr D Y Patil Medical College, Hospital and Research Centre, Pune, Maharashtra, India

A Dolas, MBBS, MS, MCh (CVTS)

Dr D Y Patil Medical College, Hospital and Research Centre, Pune, Maharashtra, India

- Huang Y-K, Lei M-H, Lu M-S, Tseng C-N, Chang J-P, Chu J-J. Bilateral coronary-to-pulmonary artery fistulas. *Ann Thorac Surg* 2006;82(5):1886-1888. <https://doi.org/10.1016/j.athoracsur.2006.02.040>
- Gajjar T, Voleti C, Matta R, Iyer R, Dash PK, Desai N. Aorta-right atrial tunnel: Clinical presentation, diagnostic criteria, and surgical options. *J Thorac Cardiovasc Surg* 2005;130(5):1287-1292. <https://doi.org/10.1016/j.jtcvs.2005.07.021>
- Mahesh K, Francis E, Kumar RK. Aorta to right atrial tunnel: Prenatal diagnosis and transcatheter management in a neonate. *J Am Coll Cardiovasc Interv* 2008;1(6):716-717. <https://doi.org/10.1016/j.jcin.2008.05.011>
- Kim SY, Seo JB, Do KH, et al. Coronary artery anomalies: Classification and ECG-gated multi-detector row CT findings with angiographic correlation. *Radiographics* 2006;26(2):317-333. <https://doi.org/10.1148/rg.262055068>
- Lee S, Kim SW, Im SI, et al. Aorta-right atrial tunnel: Is surgical correction mandatory? *Circulation* 2016;133(13):e454-e457. <https://doi.org/10.1161/CIRCULATIONAHA.115.020161>
- Jennings D, Raghunand N, Gillies RJ. Imaging hemodynamics. *Cancer Metastasis Rev* 2008;27(4):589-613. <https://doi.org/10.1007/s10555-008-9157-4>
- Jainandunsing JS, Linnemann R, Maessen J, et al. Aorto-atrial fistula formation and therapy. *J Thorac Dis* 2019;11(3):1016-1021. <https://doi.org/10.21037/jtd.2019.02.63>

Afr J Thoracic Crit Care Med 2023;29(1):e270. <https://doi.org/10.7196/AJTCCM.2023.v29i1.270>

Tracheo-oesophageal fistula in a case of organophosphate poisoning

TO THE EDITOR: Tracheo-oesophageal (TO) fistula is an abnormal connection between the trachea and the oesophagus. The fistula can be congenital or acquired, developing as a result of malignant disease, infection, trauma and ruptured diverticuli.^[1]

Prolonged mechanical ventilation with an endotracheal or tracheostomy tube can result in a TO fistula.^[2] Factors that can lead to development of a fistula include duration of intubation, cuff pressure, the type of tube used for the procedure, poor nutrition, infection and extended use of steroids, while ingestion of a corrosive substance may be a coexisting cause of necrosis of the region. Food particles and fluid from the oesophagus can enter the trachea through the fistula, leading to infection, pneumonia, congestion, bronchial obstruction and respiratory distress. Before patients develop symptoms of bronchial infection, a cough reflex immediately after ingestion of food or water is commonly noted in the initial phase. The severity of the symptoms depends on the width and length of the fistulous connection.

Investigation with bronchoscopy and contrast-enhanced computed tomography (CT) is required to exclude the possibility of a TO fistula.^[1]

A 55-year-old woman presented with complaints of coughing after ingestion of water and food for 2 months, together with difficulty in swallowing. She had ingested organophosphate 3 months previously, after which she was intubated for a prolonged period of 20 days – 12 days in the intensive care unit and 8 days in the surgical ward (further details of the intubation are not available, as it was done elsewhere). On discharge, no abnormality was noted on clinical examination. She had no similar symptoms in the past. Upper gastrointestinal endoscopy revealed a fistulous opening of ~6 mm, ~18 cm from the incisors, with the area epithelialised. No ulcer or malignant lesion was present (Fig. 1). The rest of the oesophagus and the stomach and duodenum were normal. Results of all other routine examinations were normal.

Endoscopy was followed by a plain CT scan of the neck, which showed a TO fistula measuring 6 × 4 × 6 mm (craniocaudal ×

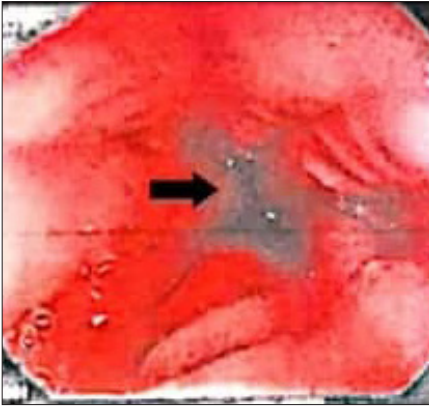


Fig. 1. Upper gastrointestinal endoscopy showing a fistulous opening ~6 mm in size and ~18 cm from the incisors, with the area epithelialised (arrow). No ulcer or malignant lesion is present.

anteroposterior × transverse) extending from the anterior wall of the cervical oesophagus to the posterior wall of the trachea on the left side of midline at C6 - C7 at the level of the 3rd - 5th tracheal rings, ~44 mm inferior to the level of the glottis (Fig. 2 - Supplementary file: <https://www.samedical.org/file/2021>). The scan was followed by an oral contrast phase (Fig. 3 - Supplementary file: <https://www.samedical.org/file/2022>).

No surgical emphysema was noted in the adjoining soft tissues and fat planes. Visualised portions of the nasopharynx and oropharynx appeared normal. The epiglottis, false cords and true cords appeared normal. The parotid and submandibular glands were bilaterally normal and the thyroid gland showed normal attenuation and enhancement. The neck soft tissues appeared normal. No significant cervical lymphadenopathy was seen. Based on the CT findings, a diagnosis of TO fistula was established. The patient underwent surgery for repair of the fistula with end-to-end anastomosis with the oesophageal repair. Written informed consent was obtained from the patient for publication of this case report and the accompanying images.

Acquired non-malignant causes of TO fistula are rare and difficult to manage. Cough while swallowing (Ono's sign) is an important clinical sign of TO fistula.^[3] Paroxysms of coughing occur on swallowing owing to an increase in tracheal secretions and aspiration while swallowing. Aspiration may result in recurrent pneumonia. Expecterated material may contain food particles. The incidence of TO fistula following endotracheal intubation

is <1%. It most often develops after prolonged mechanical ventilation, with a mean period of 42 days.^[4]

Constant monitoring of endotracheal tube cuff volume and pressure is required to avoid tracheal injury. Ischaemic damage to the trachea with resultant necrosis occurs when the cuff pressure exceeds the tracheal mucosal perfusion pressure. Cuff pressure should not exceed 20 cm H₂O. Cuff pressure of >30 cm H₂O compresses the mucosal capillaries, while pressure of 50 cm H₂O causes total occlusion of the mucosal capillaries. Cuff volume should not exceed 6 - 8 mL.^[5] However, tracheal damage can even occur when the cuff pressure is maintained within the desired range. Traumatic intubation attempts, a prolonged period of intubation (15 - 200 days, with a mean of 42 days), a wide-bore gastric tube and excessive movement of the tracheal tube during sterile swab dressing are important predisposing factors. Difficult tracheal intubation with the stylet inside the tube can result in direct rupture. Anaemia, diabetes, steroid therapy, shock, metabolic acidosis and local infection can be predisposing factors, owing to a decrease in mucosal blood flow. The incidence of TO fistula is higher in females than in males, implying that the membranous trachea is less firm in women, and in children.^[6] The exact mechanism in our case is uncertain. The fistula was probably caused by difficult/traumatic intubation, as it developed ~20 days after the patient's organophosphate poisoning (relatively short duration). It may have resulted from direct laceration by the endotracheal tube tip caught in the posterior tracheal flaccid membrane while advancing the tube. Owing to its corrosive properties, the organophosphate ingested by the patient could have resulted in thinning of the oesophageal lining, predisposing it to injury.

Before surgical repair of a TO fistula, good supportive therapy such as measures to prevent aspiration and pulmonary infection, good nutrition and spontaneous breathing are prerequisites for the success of the operation. Use of a flexible nasogastric tube, minimal endotracheal tube movement while positioning/suctioning, a cuff volume <6 - 8 mL, keeping the cuff pressure <20 mm H₂O, and selection of an endotracheal tube of appropriate size can help avoid the development of a TO fistula.^[6,7]

A high index of clinical suspicion is required for early diagnosis and treatment of TO fistula. Cuff pressure is risky when exerted


posteriorly against a rigid nasogastric tube in the oesophagus.^[7] TO fistula can be diagnosed by means of instillation of contrast medium into the oesophagus, a CT scan, flexible oesophagoscopy, or bronchoscopy (with direct visualisation). CT helps to detect the level of the fistula, providing sufficiently accurate measurements of its width and length to assess its severity. It also helps in terms of identifying any associated comorbidities. Use of contrast opacifies the pathway of the connection. CT will also reveal lung pathologies caused by the fistula.^[7]

CT is important to establish the existence of a TO fistula, because spontaneous closure of these fistulas is exceptionally rare, and surgical repair is required to close the connection. Surgical repair should be done when the patient is stable, and critically ill patients need to be conservatively managed until they become sufficiently stable.^[7]

In conclusion, endotracheal intubation after organophosphate poisoning is a rare cause of TO fistula. A high index of clinical suspicion is needed for early diagnosis and treatment. Coughing while swallowing (Ono's sign) is an important clinical indication of TO fistula. Appropriate cuff pressure and cuff volume are of the utmost importance in preventing TO fistula. A CT scan of the neck and thorax with instillation of oral contrast are important non-invasive radiological investigations. Bronchoscopy and flexible oesophagoscopy can directly diagnose the fistula. Surgical repair is the definitive treatment, as TO fistulas very rarely close spontaneously.

S M Khaladkar, MBBS, MD
(Radiodiagnosis)

Department of Radiodiagnosis, Dr D Y Patil Medical College, Hospital and Research Centre, Dr DY Patil Vidyapeeth, Pune, Maharashtra, India

S Goyal, MBBS, MD (Radiodiagnosis) 

Department of Radiodiagnosis, Dr D Y Patil Medical College, Hospital and Research Centre, Dr DY Patil Vidyapeeth, Pune, Maharashtra, India

S S Vinay Kumar Parripati, MBBS, MD
(Radiodiagnosis)

Department of Radiodiagnosis, Dr D Y Patil Medical College, Hospital and Research Centre, Dr DY Patil Vidyapeeth, Pune, Maharashtra, India

V Gupta, MBBS, MD (Radiodiagnosis)

Department of Radiodiagnosis, Dr D Y Patil Medical College, Hospital and Research Centre, Dr DY Patil Vidyapeeth, Pune, Maharashtra, India

S Goyal, MBBS, MD (O&G)

Government Medical College, Amritsar, Punjab, India
goyalshreya@gmail.com

1. Diddee R, Shaw IH. Acquired tracheo-oesophageal fistula in adults. *Cont Educ Anaesth Crit Care Pain* 2006;6(3):105-108. <https://doi.org/10.1093/bjaceaccp/mkl019>
2. Swami GA, Punpale A, Samudre SS, Asawa GR. A rare case of acquired tracheo-esophageal fistula in adult. *Int Surg J* 2021;8(9):2796-2798. <https://doi.org/10.18203/2349-2902.isj20213619>

3. Rao SV, Boralkar AK, Jirvankar PS, Sonavani MV, Kaginalkar VR, Chinte C. Tracheoesophageal fistula following endotracheal intubation for organophosphorus poisoning. *J Assoc Physicians India* 2016;64(12):84-85.
4. Epstein SK. Late complications of tracheostomy. *Respir Care* 2005;50(4):542-549.
5. Hameed AA, Mohamed H, Al-Mansoori M. Acquired tracheoesophageal fistula due to high intracuff pressure. *Ann Thorac Med* 2008;3(1):23-25. <https://doi.org/10.4103/1817-1737.37950>
6. Kaloud H, Smolle-Juettner FM, Prause G, List WF. Iatrogenic ruptures of the tracheobronchial tree. *Chest* 1997;112(3):774-778. <https://doi.org/10.1378/chest.112.3.774>
7. Babu MS, Suvarna D, Shetty C, Nadella A. Tracheo-esophageal fistula. *Br J Med Pract* 2014;7(2):a717.

Afr J Thoracic Crit Care Med 2023;29(1):e267. <https://doi.org/10.7196/AJTCCM.2023.v29i1.267>

Motor neuron disease presenting with acute hypercapnic respiratory failure

TO THE EDITOR: Motor neuron disease (MND) is rare, and respiratory failure at initial presentation is even rarer. Most patients present with asymmetrical limb weakness.^[1] We present a case of MND presenting with acute hypercapnic respiratory failure.

A previously well 61-year-old black African man who worked as a trauma nurse complained of breathlessness while at work. He reported a 3-month history of intermittent shortness of breath and a 2-week history of a non-productive cough. He was initially assessed as stable with normal vital signs. However, 45 minutes later while in the emergency department, he became tachypnoeic, hypoxic and confused. Arterial blood gas (ABG) measurement (Table 1) demonstrated acute hypercapnic respiratory failure. He was initially started on facemask oxygen and subsequently escalated to continuous positive-pressure ventilation, resulting in an improvement clinically and on repeat ABG measurement (Table 1).

The initial differential diagnosis included a pulmonary embolus and an infective process (including COVID-19). However, further investigations for these conditions were negative.

A more detailed history revealed motor deficits and fasciculations. The patient reported a 3-month history of difficulty opening glass vials of medication when at work, suggestive of intrinsic hand muscle weakness, and a 2-month history of 'jumping' pectoral muscles. He was also intermittently confused on awakening, which was suggestive of carbon dioxide narcosis, with relative hypoventilation during sleep. He had unintentional weight loss of 25 kg of muscle bulk over the last few months.

On examination, the patient was in respiratory distress and globally wasted with florid shoulder girdle fasciculations. The cranial nerves were normal. There was no nystagmus and no ophthalmoplegia. Bulbar signs were not elicited, and there was a normal jaw jerk. There was no extension or neck flexion weakness. On motor examination, he

Table 1. Serial blood gas levels and laboratory results

Variable	Initial (reference)	After non-invasive ventilation
pH	7.23 (7.35 - 7.45)	7.34
PO ₂ (mmHg)	50.9 (80 - 100)	185
PCO ₂ (mmHg)	93.4 (35 - 45)	57
H ₂ CO ₃ (mEq/L)	29.9 (22 - 26)	32
D-dimers (mg/L)	0.13 (<0.50)	n/a
C-reactive protein (mg/L)	2 (0 - 10)	n/a
Procalcitonin (ng/mL)	0.04 (<0.05)	n/a

PO₂ = partial pressure of oxygen; PCO₂ = partial pressure of carbon dioxide; H₂CO₃ = bicarbonate; n/a = not applicable.

had proximal and distal muscle wasting of the upper limbs with split hand wasting and fasciculations. He had normal tone with reduced power of 4/5 in all muscle groups and brisk reflexes of 3/4. His lower limbs had no obvious wasting, normal tone, and reduced power proximally and preserved power distally. He had brisk knee reflexes of 3/4 with no ankle jerks and an upgoing plantar reflex on the right. The findings on sensory examination were normal, and he was not ataxic. He was assessed as having a predominant or pure motor syndrome with combined upper and lower motor neuron signs.

Electrodiagnostic studies were performed. Nerve conduction studies showed normal latency and conduction velocity, with decreased amplitude in motor fibres. Sensory fibres were normal. Repetitive nerve stimulation of the accessory nerve demonstrated no decrease in the amplitude of the motor response. The patient was diagnosed with MND, amyotrophic lateral sclerosis variant. He had an atypical presentation with acute hypercapnic respiratory failure.