

Functional outcome in unstable Hangman's fracture managed with anterior approach: A prospective study

ABSTRACT

Aim: To study the functional outcome in unstable Hangman's fracture managed with anterior decompression and stabilization with cervical locking plate and tricortical bone graft.

Materials and Methods: Between 2010 and 2016, 44 patients (range: 19-75 years) with unstable Hangman's fracture underwent anterior decompression and stabilization with cervical locking plate and tricortical bone graft in our institution.

Result: According to the Levine and Edwards classification, all patients were unstable with Type IA 6 (13.6), Type IIA 35 (79.5%), Type II (0), and Type III (6.8). The mean period of follow-up was 17 months (range: 6-48 months). Neurological recovery was observed in all nine patients. All patients were relieved from axial pain. None of the patients received blood transfusion. All patients showed solid fusion with no complication related to bone graft and plate.

Conclusion: The anterior C2/C3 discectomy, fusion, and stabilization with cervical locking plate and tricortical bone graft are feasible and safe method in treating Hangman's fracture, with the benefit of high primary stability, anatomical reduction, and direct decompression of the spinal cord.

Keywords: Cervical plating, Hangman's fracture, management, traumatic spondylolisthesis of C2

INTRODUCTION

Hangman's fracture is traumatic anterior spondylolisthesis of the axis due to bilateral fracture of pars interarticularis.^[1-3] Hangman's fracture account for 23% of axis fracture.^[4] Hangman's fracture is the second most common injury of axis. The fracture may extend to posterior vertebral cortex or vertebral artery foramen. The majority of cases of vertebral artery injury are clinically silent.^[2,5]

The fracture pattern is usually seen following hyperextension and axial loading as well as sometime flexion injury also. This fracture is typically a result of high energy trauma and is commonly seen with motor vehicle accident 63.6% followed by fall from height.^[6,7]

In Hangman's fracture, stable fracture pattern (Type I and II) are managed conservatively with hard cervical collar and Halo vest traction, whereas unstable fracture pattern (Type IA, II, and III) surgery is treatment of choice.^[8] Operative management has

been described using both anterior and posterior approach with stabilization done anteriorly, posteriorly, or combined. The posterior approach preserves the motion of axis but does not address the instability on account of disc injury. The anterior approach which has the advantage of short fusion and direct decompression of spinal cord, involves C2–C3 discectomy, stabilization with cervical locking plate and tricortical bone graft. The aim of this prospective study is to assess the functional outcome of anterior discectomy, fusion with cervical locking plate, and tricortical bone graft in treatment of Hangman's fracture.

VAIBHAV JAIN, MANOJ KUMAR THAKUR, AMIT THAKUR, SACHIN SUD, MUKUND LAL, ANKIT MADAN

Department of Orthopaedics Surgery, Indira Gandhi Medical College, Shimla, Himachalpradesh, India

Address for correspondence: Dr Vaibhav Jain, 99, Chawni Road, Mangalwara, Bhopal - 462 001, Madhya Pradesh, India.
E-mail: vaibhavigmc@gmail.com

Access this article online	
Website: www.jcvjs.com	Quick Response Code 
DOI: 10.4103/jcvjs.JCVJS_113_17	

This is an open access article distributed under the terms of the Creative Commons Attribution-NonCommercial-ShareAlike 3.0 License, which allows others to remix, tweak, and build upon the work non-commercially, as long as the author is credited and the new creations are licensed under the identical terms.

For reprints contact: reprints@medknow.com

How to cite this article: Jain V, Thakur MK, Thakur A, Sud S, Lal M, Madan A. Functional outcome in unstable Hangman's fracture managed with anterior approach: A prospective study. J Craniovertebr Jun Spine 2017;8:350-3.

MATERIALS AND METHODS

A total of 260 patients of fracture of the axis vertebra, reported to the emergency department of our tertiary care teaching hospital, between January 2010 and December 2016, of which 44 patients with unstable Hangman's fracture treated and followed up in our institution and were included in this study. Anterior decompression and stabilization with cervical locking plate and tricortical bone graft was performed in each case. Nearly 65.9% patients sustain injury due to fall from height whereas 34.1% got injured in motor vehicle accidents. All patients complain of pain and neck movements were restricted. Preoperative assessment includes securing of airways and management of life-threatening injuries, followed by stabilization of cervical injury with hard cervical collar. Neurological status was assessed according to ASIA chart. Radiological assessment was then done with anteroposterior, lateral and open mouth view and computed tomography with three-dimensional reconstruction. According to the Levine–Edwards classification with Starlz–Eismont modification Unstable Hangman's fracture were Type IA 6, Type II 35, Type IIA 0, and Type III 3. In our study, associated injuries including 48% had head injury, upper limb injuries included 38%, lower limb included 32%, chest injury was present in 36%, and abdomen included 24%. Due to associated injuries and time taken to stabilize the patient delayed the surgical stabilization of Hangman's fracture by 1 week. During that period, Crutchfield tong traction was applied. After the surgery, patients were started on static neck exercise from the 3rd postoperative period and made to sit in bed from next postoperative day.

Fracture through foramen transversarium was found in eight (18.2%) patients. After clinical examination and radiological assessment, traction applied with Crutchfield tongs at an appropriate angle depending on injury mechanism.

Surgical techniques

Southwick and Robinson approach was used in all cases. The patient is positioned supine on the operating table. The Crutchfield tong is applied anterior to the ear. The patient's neck slightly extends. The head slightly rotated to about 10°–15° to the opposite side. Iliac crest is prepared to harvest bone graft. Reverse Trendelenburg position of about 10° given to decrease the dependency of the head and neck surgery and decrease venous plexus congestion. The longitudinal incision made below the mandible parallel to sternocleidomastoid over left side of neck of about 3 cm. The hyoid bone is approximately at the level of C3. C2–C3 anterior exposure was obtained and discectomy done. Tricortical graft is harvested from left iliac crest. Graft put in the disc space. Anterior cervical locking plate stabilized on the body of

C2–C3 with stabilizing pins and its position confirmed on the image intensifier on both anteroposterior and lateral view. If position is correct, anterior cervical locking plate stabilized with variable unicortical locking screw. Again the position of screw confirmed in image intensifier in both anteroposterior and lateral view. Finally, locking screws are tightened. Wound closure will be done in layers over negative suction drain antiseptic dressing will be applied and philadelphia collar applied. During surgery, displacement of the C2 body, status of the disc, displacement of disc, and status of anterior longitudinal ligament and posterior longitudinal ligament were assessed. Postoperatively, all patients were mobilized with philadelphia collar as soon as possible by 1st to 2nd day. Postoperatively, routine anteroposterior, lateral, and open mouth view of cervical spine were obtained to assess the placement of cervical locking plate. Negative suction drain was removed 2nd postoperative day after the wound inspection.

Follow-up

The patients enrolled in our study were followed up for a mean of 17 months (range: 6–48 months). Patients were evaluated after 6 weeks, than at interval of 3 months in the first 6 months a yearly thereafter. Static cervical exercises advised after surgery. Cervical movements allowed at 6 weeks. At follow-up, a detailed clinical and neurological examination was done and radiological assessment was done. Fusion of C2–C3 with bone graft was assessed using Birdwell fusion grade. Neck-specific disability was measured as per Neck Disability Index.^[9]

Statistical analysis

Statistical testing was conducted with the Statistical Package for the Social Sciences system version SPSS 17 (SPSS Inc., Chicago, USA). For all statistical tests, a $P < 0.05$ will be taken to indicate a significant difference.

RESULTS

The mean operative time was 106 min (90–130 min). No intraoperative complication was observed. No patient required blood transfusion. Intraoperatively, C2–C3 disc was found ruptured in 59.1%, degenerated in 29.6%, and prolapsed in 11.3%. Anterior longitudinal ligament was found torn in 29.5% whereas posterior longitudinal ligament was torn in 45.5%. Postoperatively, all patients had transient dysphagia which resolved within 2–3 days and did not persist. All patients had pain over graft site at iliac crest which decreased significantly by 2 weeks and did not persist beyond 6 weeks. Ten (22.7%) patients had neuropraxia of marginal mandibular branch of facial nerve which resolve completely in postoperative follow-up. No patient had wound infection. All patients were relieved from axial pain. Two patients with

preoperative ASIA chart Grade C and 7 with Grade D showed postoperative improvement to Grade E. All patients had solid fusion of the graft as assessed radiologically according to Bridwell fusion grading (72.8% Grade I, 15.9% Grade II, and 11.3% Grade III) [Figures 1 and 2]. Postoperatively, neck disability index score slowly decreased, and at final follow-up, 56.8% patients had mild disability, 38.6% had moderate disability, and only 4.6% had severe disability. Park *et al.* reported moderate disability in 54.2% according to neck disability index, in which they performed posterior surgical fixation and stabilization using polyaxial screw-rod system. The reason behind this difference might be direct decompression and stabilization with anterior approach. No bone graft or plate screw-related complication was observed in any patients during the follow-up period.

DISCUSSION

The Levine and Edward's classification is most widely accepted among several classification system for Hangman's fracture. Levine and Edward's classified the Hangman's fracture into four types based on mechanisms of trauma: Type I - fracture through neural arch with no angulation and minimal displacement; Type II - fracture with significant angulation and displacement; Type IIA - fracture with oblique fracture line and minimal translation but significant angulation; and Type III - fracture with bilateral facet dislocation. In 1993, Starlz and Eismont described an "atypical" fracture pattern. This has been labeled Type IA, in which a portion of C2 vertebral body is in continuity with one of the pars fracture fragments.^[10,11]

Most cases of Hangman's fracture responded to conservative treatment which included halo brace, skeletal traction,

and cervical collars. However, some studies also found disadvantages with conservative treatment such as recurrent axial pain, anterior dislocation, pseudarthrosis, and angulation of C2 over C3. Although anterior translation and angulation decreased by 65% by traction, recurrence of anterior translation by 60% and of angulation by 40% when it changed to halo vest.^[12,13] Accurate fracture reduction and realignment was never achieved by conservative management. In addition, halo vest need to be worn for 3–6 months which causes much discomfort and inconvenience. Therefore, orthopedic surgeons have sought surgical methods to overcome these problems. Occasionally, surgical treatment is employed in the hopes of improving neurological outcome.

Operative management has been described using both anterior and posterior approach with stabilization anteriorly or posteriorly or combined.

Posterior approach has an advantage of direct access to C2–C3 facets for reduction. Direct pars repair and fixation with screw preserve motion of axis but does not address disc and ligamentous injury.^[14] Posterior C1–C3 wiring techniques have been described as an alternative for fixation of Hangman's fracture but require postoperative halo brace immobilization. Posterior C2 screw fixation has a risk of injury to vertebral artery and spinal cord. In our study, fracture through foramen transversarium was found in eight (18.2%) patients which is an indirect evidence of vertebral artery involvement, but this injury is clinically silent and did not require any intervention. In these cases if added iatrogenic vertebral artery damage occurs, then it lead to catastrophic complication of vertebrobasilar insufficiency and neurologic deficit develops. Due to the high risk involved with posterior approach, many surgeons prefer anterior approach.

Anterior approaches to C2–C3 are safe and familiar to surgeon. The anterior cervical approach is a useful surgical technique

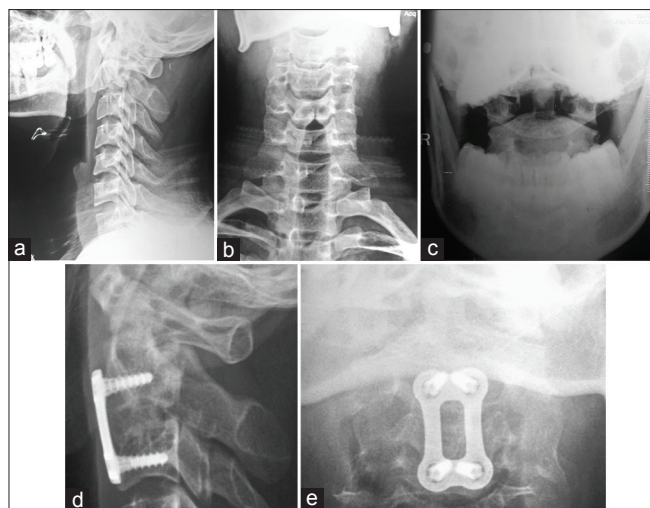


Figure 1: (a-c) Preoperative X-rays of Hangman's fracture (Levine and Edward classification with Starlz and Eismont modification Type IA). (d and e) Six month follow up showing fusion (Bridwell fusion Grade 1)

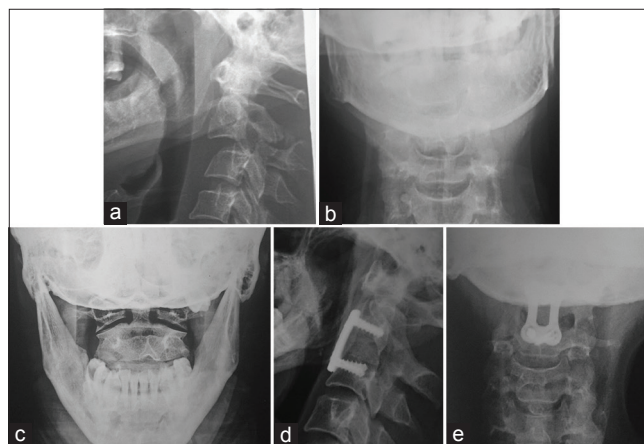


Figure 2: (a-c) Pre operative X-rays of Hangman's fracture (Levine and Edward Type II). (d and e) Six month follow up showing fusion (Bridwell fusion Grade 1)

for upper cervical spine injury, which allows direct anterior access to C2 and C3 while allowing extension to the lower cervical spine.^[15] It aids in anatomical reduction and direct decompression of the spinal cord. Complications related with high anterior approach including injury to the hypoglossal nerve, superior laryngeal nerve, branches of external carotid, and contents of carotid sheath, but in proficient and experienced hands, it is no longer a hindrance. In skill hands, anterior approach provides high primary stability, almost 100% fusion rates, anatomical reduction, direct decompression of spinal cord, and favorable clinical outcome.

A displaced Hangman's fracture is often associated with C2–C3 disc injury. Disc injury may lead to instability of cervical spine and disc herniation may cause medullary compression. Disc status and discoligamentous integrity, which determines the stability in Hangman's fracture, should be assessed by magnetic resonance imaging and intraoperatively. The posterior approach does not deal with disc herniation and cervical instability, which can be easily managed by anterior approach. In experienced hands, the anterior C2/C3 discectomy, fusion, and stabilization with cervical locking plate and tricortical bone graft are feasible and safe method in treating Hangman's fracture, with the benefit of high primary stability, superior functional, and radiological results with almost 100% fusion rates.

In our study, the anterior C2/C3 discectomy, fusion, and stabilization with cervical locking plate and tricortical bone graft is feasible and safe method in treating Hangman's fracture, with the benefit of high primary stability, anatomical reduction, and direct decompression of the spinal cord. Solid fusion with good functional outcome combined with low rate of complications was achieved in all cases following anterior cervical decompression, fusion, and stabilization with anterior cervical locking plate and tricortical bone graft in Hangman's Fracture and it is the method of choice.

CONCLUSION

In our experience, surgical method of anterior C2/C3 discectomy, fusion, and stabilization with cervical locking plate and tricortical bone graft is appropriate for treatment of Hangman's fracture. It provides good neurological recovery and solid fusion with low rate of complications. A randomized

trial of longer duration with greater number of patients would be more appropriate to obtain definitive conclusions.

Financial support and sponsorship

Nil.

Conflicts of interest

There are no conflicts of interest.

REFERENCES

1. Toretta JA, Sengupta DK. Cervical spine trauma. *Indian J Orthop* 2007;41:255-67.
2. Hartley M, Sirkis MD. Traumatic spondylolisthesis of the axis (hangman's fracture). *Appl Radiol* 2005;34:32-4.
3. Samaha C, Lazennec JY, Laporte C, Saillant G. Hangman's fracture: The relationship between asymmetry and instability. *J Bone Joint Surg Br* 2000;82:1046-52.
4. Hadley MN, Browner C, Sontag VK. Axis fracture: A comprehensive review of management and treatment in 107 cases. *Neurosurgery* 1985;17:281-90.
5. Basu S, Chatterjee S, Bhattacharya MK, Seal K. Injuries of the the upper cervical spine: A series of 28 cases. *Indian J Orthop* 2007;41:305-11.
6. Moon MS, Moon JL, Moon YW, Sun DH. Traumatic spondylolisthesis of the axis. *Bull Hosp Jt Dis* 2001;60:61-6.
7. Wang L, Liu C, Zhao QH, Tian JW. Classification and surgical management for the axis fracture complicated with adjacent segment instability. *Int J Clin Exp Med* 2014;7:657-64.
8. Christopher MP, Careas E. Cervical spine fracture and dislocation. In: Buchholz RW, Heckman JD, Brand CM, Tornetta P, editors. *Rockwood and Greens Fractures in Adult's*. 7th ed. Philadelphia: Lippincott Williams and Wilkins; 2010. p. 1352-4.
9. Vernon H, Mior S. The neck disability index: A study of reliability and validity. *J Manipulative Physiol Ther* 1991;14:409-15.
10. Park JH, Kim SH, Cho KH. Clinical outcomes of posterior C2-C3 fixation for unstable hangman's fracture compared with posterior C1-C3 fusion. *Korean J Spine* 2014;11:33-8.
11. Morvin I, Cretnik A. Surgical management of traumatic spondylolisthesis of the axis. *Acta Med Biotechnica* 2013;6:53-7.
12. Chittiboina P, Wylen E, Ogden A, Mukherjee DP, Vannemreddy P, Nanda A, *et al.* Traumatic spondylolisthesis of the axis: A biomechanical comparison of clinically relevant anterior and posterior fusion techniques. *J Neurosurg Spine* 2009;11:379-87.
13. Dalbayrak S, Yilmaz M, Firidin M, Naderi S. Traumatic spondylolisthesis of the axis treated with direct C2 pars screw. *Turk Neurosurg* 2009;19:163-7.
14. Johnson MG, Fisher CG, Boyd M, Pitzen T, Oxland TR, Dvorak MF, *et al.* The radiographic failure of single segment anterior cervical plate fixation in traumatic cervical flexion distraction injuries. *Spine* 2004;29:2815-20.
15. Xu H, Zhao J, Yuan J, Wang C. Anterior discectomy and fusion with internal fixation for unstable hangman's fracture. *Int Orthop* 2010;34:85-8.