



Contents lists available at ScienceDirect

JPRAS Open

journal homepage: www.elsevier.com/locate/jpra



Case Report

Helical rim advancement – A technique to avoid keloid recurrence[☆]

James W.M. Kwek^{*}, T.S. Lee, Ian C.Y. Loh

Department of Otolaryngology, Head and Neck Surgery, Changi General Hospital, 2 Simei Street 3, Singapore 529889, Singapore

ARTICLE INFO

Article history:

Received 9 September 2018

Revised 3 December 2018

Accepted 13 December 2018

Available online 22 December 2018

Keywords:

Keloid

Ear

Pinna

Advancement flap

Antia-Buch

ABSTRACT

Introduction: Helical rim keloids occur commonly following ear piercings, trauma and previous surgeries and can be disfiguring. Many techniques have been developed to treat these disfiguring lesions with varying successes, however, individuals prone to developing keloids inadvertently recur despite best efforts.

Objective: To determine whether helical rim advancement flap reconstruction following helical rim keloid excision can reduce recurrences.

Design: Case series followed up to 2 years.

Setting: Single Centre Tertiary Hospital Facial Plastics Service.

Participants: All patients who consented to helical rim advancement reconstruction after keloid excision.

Results: The authors report a series of 7 patients with helical rim keloids ranging from 1.2 cm to 5 cm in widest diameter treated with keloid excision and reconstruction with helical rim advancement flap technique. There were no recurrences within a mean of about 19 months post-operatively. Most patients report satisfaction with the cosmetic end-result.

Discussion: From the authors' experience, helical rim advancement reconstruction following excision of keloids about 2.5 cm in widest diameter is an excellent tension-free option to avoid recurrence of helical rim keloids. Wound tension is a key risk factor for keloid formation. We hypothesise that the reason why there was no recurrence is because in helical rim advancement flap reconstruction,

[☆] The authors have no funding or conflict of interests to declare.

^{*} Corresponding author.

E-mail address: kwekhuman@gmail.com (J.W.M. Kwek).

the underlying helical rim takes all the tension of closure off the dermis, resulting in tension-free skin closure.

Conclusion: Helical rim advancement flap reconstruction is a viable technique to avoid recurrence and minimise cosmetic deformities of the pinna for selected helical rim keloids.

© 2018 The Authors. Published by Elsevier Ltd on behalf of British Association of Plastic, Reconstructive and Aesthetic Surgeons. This is an open access article under the CC BY-NC-ND license. (<http://creativecommons.org/licenses/by-nc-nd/4.0/>)

Introduction

Many techniques have been developed to treated helical rim keloids with varying successes. Individuals prone to developing keloids inadvertently recur despite best efforts to create tension-free closures. Our case series describes 7 cases of helical rim keloids excised and closed with helical rim advancement with no reported recurrences after a mean duration of 19 months.

Case series

Over a 24-month period, the authors carefully selected and excised helical rim keloids in 7 patients. The residual defect was then closed with helical rim advancement (Antia-Buch¹) technique. See [Figure 1](#) for a step-by-step photographic illustration of the authors' technique. [Table 1](#) summarises the case series.

Findings

Patient demographics

All 7 patients were female, with a mean age of 20.1 years old at the time of surgery. 4 were of Chinese ethnicity while 3 were Malay.

Features of keloids

The cases were single keloids either located on the upper 1/3 of the helical rim (6/7), in the scaphoid fossa (4/7) or both (3/7). All keloids originated from the site of a previous ear piercing. 2 were recurrent keloids previously managed by excision and/or intra-lesional steroid injections.

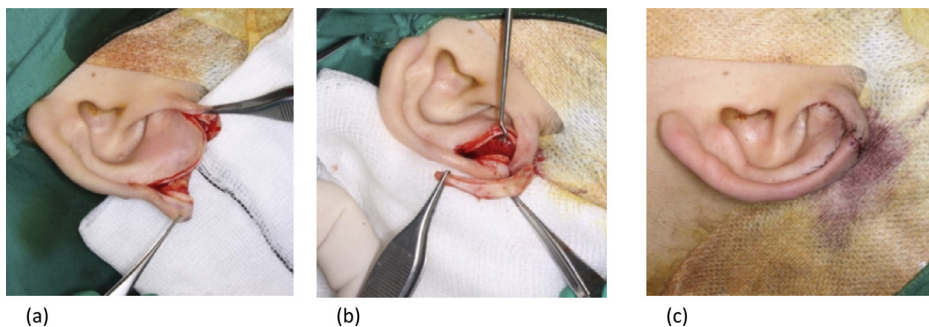


Figure 1. Step-by-step illustration of technique. From left to right: (a) Defect left behind after complete excision of keloid with underlying cartilage; (b) Composite helical rim flap raised inferiorly and posteriorly with intact posterior skin pedicle and reduction of scaphoid fossa; (c) Helical rim opposed with smooth contouring and closure with Ethilon 6-0.

Table 1
Case series of helical rim keloids excised and closed with helical rim advancement.

Patient	#1	#2	#3	#4	#5	#6	#7	
Age	17	24	19	21	21	21	18	
Gender	F	F	F	F	F	F	F	
Ethnicity	Malay	Chinese	Chinese	Malay	Chinese	Chinese	Malay	
Features of keloid	Location	Left upper 1/3 helical rim/scaphoid fossa	Left scaphoid fossa	Left upper 1/3 helical rim/scaphoid fossa	Right upper 1/3 helical rim	Left upper 1/3 helical rim	Right upper 1/3 helical rim	Right upper 1/3 helical rim/scaphoid fossa
	Recurrent	No	No	3rd episode	No	No	No	3rd episode
	Size	3 cm × 2 cm posteriorly and 0.8 cm anteriorly	2 × 1 cm	1.2 cm	5 cm × 1 cm	1.5 cm	2.5 cm posteriorly; 1 cm anteriorly	2.5 cm
	Shape	Dumbbell	Broad-based	Pedunculated	Pedunculated	Pedunculated	Dumbbell shaped	Data unavailable
Management details	Inciting Event	Ear piercing	Ear piercing	Ear piercing	Ear piercing	Ear piercing	Ear piercing	Ear piercing
	Prior treatment	Nil	Nil	ILS ^a /previous excision	Nil	Nil	Nil	Previous excision x 2
	Op duration	60 min	60 min	70 min	40 min	80 min	55 min	40 min
Management details	Periop issues	Nil	Nil	Nil	Nil	Nil	Nil	Nil
	Adjuvant therapy	ILS × 1	ILS × 3	ILS × 3	ILS × 1	Nil	ILS × 10	ILS × 6
	Recurrence	No	No	No	No	No	No	No
	Cosmesis	Happy	Happy	Happy	Happy	Data unavailable	Data unavailable	Happy
	Duration till report	23 months	15 months	13 months	13 months	31 months	26 months	14 months

^a Intra-lesional steroid injections.

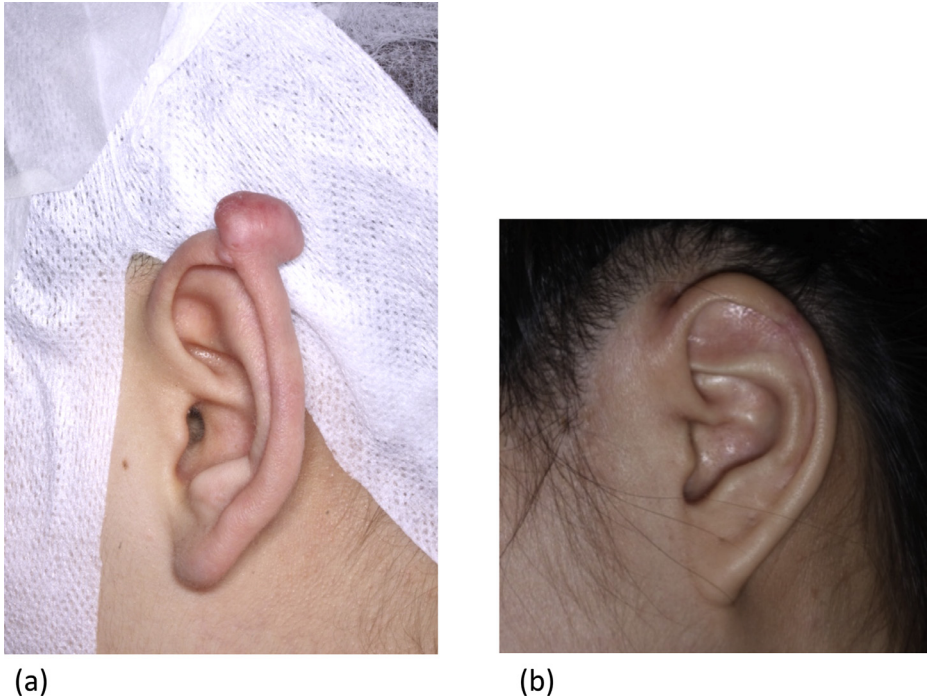


Figure 2. (a) Pre-op (b) 1 year Post-op.

The shape of the keloids varied between broad-based, pedunculated and dumb-bell shaped. The mean size was 2.5 cm (1.2 cm–5 cm) at its widest point.

Management details

All the patients underwent surgery under general anaesthesia. The mean duration of surgery was 57.9 min (range 40 min–80 min). There were no perioperative complications. No information was available on the defect sizes following excision of keloid. Post-operatively, 6 patients had an average of 4 adjuvant intra-lesional steroid injections (range 1–10 injections). No recurrences were reported after a mean of 19.2 months (range 13–31 months). Of note, 1 patient declined adjuvant intra-lesional steroid injections and is currently experiencing the longest (31 months) recurrence-free duration. However, her keloid was also one of the smallest at 1.5 cm.

Discussion

Existing modalities

Existing treatment modalities range from less invasive methods such as intra-lesional steroid injections, radiotherapy and pressure therapy^{2–4} as well as surgical procedures such as wedge excision and primary closure, use of skin grafts^{5,6} and core excision.⁷ Due to the recalcitrant nature of keloids, surgeons generally use different combinations of methods to minimise recurrences.^{8–10} Using keloid recurrence as a primary clinical outcome measure, these techniques have reported varying success rates for prevention of recurrence.

Helical rim advancement

Helical rim advancement has been used for closure of helical rim defects following excision of lesions of various pathologies.^{11–13} However, there have been no reports on utilising this technique for defects following excision of helical rim keloids.

From the authors' experience, helical rim advancement reconstruction following excision of keloids about 2.5 cm in widest diameter is an excellent option to avoid recurrence of helical rim keloids. Cartilage approximation with this technique removes tension from the overlying skin, one of the key contributing factors to keloid formation and recurrence.

A certain outcome of helical rim advancement is a smaller neoauricle. Al-shaham¹³ and Orticochea¹⁴ suggested that using Antia-Buch technique to reconstruct maximum defect sizes of 2.8 cm and 2.5 cm, respectively, was acceptable cosmetically with minimal asymmetry. A stricter 2 cm limit was suggested by Calhoun et al's¹⁵ cadaveric study to ensure preservation of normal anatomic landmarks and a near-normal appearance of the reconstructed ear. Bialostocki and Tan¹⁶ reported that where there is an associated defect in the scaphoid fossa, including a crescentic scaphal excision could enhance the post-reconstruction appearance.

The authors' case series was a retrospective review and did not provide further information on the post-excision defect sizes. Positive feedback was provided when 5 patients were specifically asked about their assessment of the cosmetic outcome. The remaining 2 patients were not contactable at the time of the study. Conducting a pre-operative and post-operative comparison of Quality of Life (QOL) or patient satisfaction scoring would have added to the strength of this small study. While pressure therapy has been found to prevent keloid formation and recurrences, it was not used in this series of patients as the department did not have any available pressure dressing that moulds well with the contours of the pinna. In addition, the authors' usual protocol of following up patients closely with timely intra-lesional steroids have been effective in preventing keloid recurrence (Figure 2).

Conclusion

Helical rim advancement flap reconstruction of selected helical rim defects following excision of keloids is a viable technique to avoid recurrence and minimise cosmetic deformities of the pinna.

References

1. Antia NH, Buch VI. Chondrocutaneous advancement flap for the marginal defect of the ear. *Plast Reconstr Surg.* 1967;39(5):472–477.
2. Bran Gregor M, Brom Jo'rn, Ho'rmann Karl, Stuck Boris A. Auricular keloids combined therapy with a new pressure device. *Arch Facial Plast Surg.* 2012;14(1):20–26.
3. Park TH, Seo SW, Kim JK, Chang CH. Outcomes of surgical excision with pressure therapy using magnets and identification of risk factors for recurrent keloids. *Plast Reconstr Surg.* 2011;128(2):431–439.
4. Park TH, Rah DK. Successful eradication of helical rim keloids with surgical excision followed by pressure therapy using a combination of magnets and silicone gel sheeting. *Int Wound J.* 2017;14:302–306.
5. Ogawa R, Akaishi S, Dohi T, Kuribayashi S, Miyashita T, Hyakusoku H. Analysis of the surgical treatments of 63 keloids on the cartilaginous part of the auricle: effectiveness of the core excision method. *Plast Reconstr Surg.* 2015;135(3):868–875.
6. Rasheed IA, Malachy AE. The management of helical rim keloids with excision, split thickness skin graft and intralesional triamcinolone acetonide. *J Cutan Aesthet Surg.* 2014;7(1):51–53.
7. Yamawaki S, Naitoh M, Ishiko T, Muneuchi G, Suzuki S. Keloids can be forced into remission with surgical excision and radiation, followed by adjuvant therapy. *Ann Plast Surg.* 2011;67(4):402–406.
8. Jones ME, Hardy C, Ridgway J. Keloid management: a retrospective case review on a new approach using surgical excision, platelet-rich plasma, and in-office superficial photon X-ray radiation therapy. *Adv Skin Wound Care.* 2016;29(7):303–307.
9. Ramsey ML1, Marks VJ, Klingensmith MR. The chondrocutaneous helical rim advancement flap of Antia and Buch. *Dermatol Surg.* 1995;21(11):970–974.
10. Stella C, Adam MF, Edward L. Helical rim reconstruction: Antia-Buch flap. *Eplasty.* 2015;8(15):ic55 eCollection 2015.
11. Al-shaham AA. Helical advancement: pearls and pitfalls. *Can J Plast Surg.* 2012;20(2):28–31.
12. Orticochea M. Reconstruction of partial loss of the auricle. *Plast Reconstr Surg.* 1970;46:403–405.

15. Calhoun KH, Slaughter D, Kassir R, Seikaly H, Hokansonj A. Biomechanics of the helical rim advancement flap. *Arch Otolaryngol Head Neck Surg.* 1996;122:1119–1123.
16. Bialostocki A, Tan ST. Modified Antia-Buch repair for fullthickness upper pole auricle. *Plast Reconstr Surg.* 1999;103:1476–1479.