



Spontaneous Heterotopic Cesarean Scar Triplet Gestation Following Uterine Ablation

Zane Frazer Aldrich, MD¹ Rena Ow, MD¹ Khyaati Modii, MD, MPH, FACOG¹
Timothy O'Leary, MD, FACOG-MFM¹

¹Obstetrics and Gynecology and Maternal Fetal Medicine, Winnie Palmer Hospital for Women and Babies, Orlando, FL

Address for correspondence Zane Frazer Aldrich, MD, Resident Physician, Obstetrics and Gynecology, Orlando Health Winnie Palmer Hospital for Women and Babies, 1401 Lucerne Terrace, Orlando, FL 32806 (e-mail: Zane.Aldrich@orlandohealth.com).

AJP Rep 2024;14:e91–e95.

Abstract

Heterotopic triplet pregnancy, cesarean scar ectopic pregnancy, and pregnancy following uterine ablation are all rare events that confer significant morbidity including spontaneous abortion, intrauterine fetal demise, preterm labor, abnormal placentation, and uterine rupture. A woman in her 30s, G6P4014, with a history of uterine ablation presented with delayed menses and vaginal spotting with imaging showing two intrauterine pregnancies (one with cardiac activity) and one live pregnancy at the cesarean scar. The patient was extensively counseled on risk to her and to the pregnancies; treatment options were discussed including expectant management and termination of pregnancy. The patient underwent an uncomplicated dilation and curettage with bilateral salpingectomy and was discharged home the day of the procedure in stable condition. This case highlights the potential compound effect of comorbid conditions that can pose difficulty in counseling and management.

Keywords

- ▶ ectopic pregnancy
- ▶ heterotopic pregnancy
- ▶ triplet gestation
- ▶ cesarean scar
- ▶ uterine ablation
- ▶ abortion

Key Points

- Patients undergoing endometrial ablation should be carefully selected and counseled extensively on highly effective contraception.
- Suspected cesarean scar pregnancies should be carefully evaluated early in gestation. Management should include thorough counseling and may be individualized.
- Many conditions pose a significant threat to maternal health and warrant a discussion of termination, which should be widely available and safe for all who need and/or desire it.

Background

Spontaneous triplet pregnancies occur at a rate of approximately 1 in 4,000 pregnancies. Heterotopic pregnancies, defined as the presence of multiple gestations with one (or more) being present in the uterine cavity and the other(s) outside the

uterus, occur at a rate of approximately 1 in 30,000 pregnancies. Heterotopic triplet pregnancies have been reported in case reports.^{1–6} Cesarean scar ectopic is a rare event with no currently reported rates, but this condition is becoming more common as women undergo more cesarean sections.⁷ Those who continue cesarean scar pregnancies are at high risk of

received
October 4, 2023
accepted
October 18, 2023

DOI <https://doi.org/10.1055/s-0044-1779654>.
ISSN 2157-6998.

© 2024. The Author(s).

This is an open access article published by Thieme under the terms of the Creative Commons Attribution-NonDerivative-NonCommercial-License, permitting copying and reproduction so long as the original work is given appropriate credit. Contents may not be used for commercial purposes, or adapted, remixed, transformed or built upon. (<https://creativecommons.org/licenses/by-nc-nd/4.0/>)

Thieme Medical Publishers, Inc., 333 Seventh Avenue, 18th Floor, New York, NY 10001, USA

morbidity such as placenta accreta spectrum (PAS), cesarean scar dehiscence/uterine rupture, postpartum hemorrhage, and postpartum hysterectomy.⁷

Pregnancy after uterine ablation is a rare complication with incidence estimated at approximately 1 to 3%. A limited number of women elect to continue pregnancy after ablation, but those who do experience high rates of PAS, preterm delivery, malpresentation, and all-cause perinatal mortality.⁸

Ours is the only reported case, per the authors' extensive review of the literature, of spontaneous heterotopic triplet pregnancy involving one cesarean scar pregnancy following uterine ablation. This confluence of conditions is unique, and each condition alone carries high risk to the pregnant patient. This case highlights the difficulty in counseling a patient with multiple such conditions and the importance in maintaining the ability to offer termination in cases of proven high-risk morbidity, even if the patient is clinically stable at diagnosis. The learning objectives from this case apply to patients with any combination of the multiple conditions that are concurrently exemplified in this one patient.

Case Presentation

This is a case of a woman in her 30s, gravida 6, para 4014, who initially presented with pelvic pain and vaginal bleeding at an outside facility. She had a positive pregnancy test and transvaginal ultrasound showed a heterotopic pregnancy with two intrauterine pregnancies and one pregnancy at the lower anterior uterus, at the prior cesarean scar. The patient had a medical history of chronic iron deficiency and possible von Willebrand's disease without a certain diagnosis. She had previously low levels of von Willebrand factor activity and a history of heavy menstrual bleeding as well as postpartum hemorrhage requiring blood transfusion. Prior hematologic workup records were not available. Her surgical history was significant for four prior cesarean sections at term as well as uterine ablation that was performed for heavy menstrual bleeding.

At the time of presentation to our facility, the patient had a known heterotopic cesarean scar pregnancy and had been discharged from several other facilities without any certain

treatment plan due to the complexity and rarity of her case and uncertainty regarding management. On presentation to our facility, she was experiencing light vaginal bleeding. She did not have significant pelvic pain and her vital signs and examination were stable.

Investigations

Transvaginal ultrasound on initial presentation showed an intrauterine tri-chorionic, tri-amniotic triplet gestation. Fetus A was within a low-lying gestational sac near the lower uterine segment near the cesarean section scar and had a crown rump length of 3.1 mm, measuring 5 weeks and 6 days with no fetal cardiac activity. Fetus B had a crown rump length of 8.9 mm, measuring 6 weeks and 6 days with normal fetal cardiac activity, and was noted to be immediately adjacent to the prior cesarean scar and adjacent to the gestational sac of fetus A (►Fig. 1). Fetus C had a crown rump length of 11.3 mm, measuring 7 weeks and 2 days with normal fetal cardiac activity, and was located at the right uterine fundus. There was a small subchorionic hemorrhage noted adjacent to fetus C. The patient was discharged in stable condition with a plan for close follow up with Maternal Fetal Medicine to discuss further management. The patient presented again the following day with continued vaginal bleeding. Her vital signs remained stable and vaginal bleeding was overall minimal. Repeat transvaginal ultrasound no longer appreciated fetus A. Fetus B was again seen with normal cardiac activity in an abnormal position in the lower uterine segment adjacent to the uterine scar with very thin myometrium measuring 0.097 cm with a distorted gestational sac with bulbous superior anterior component (►Figs. 2 and 3), highly concerning for cesarean scar ectopic. Fetus C was again seen at the fundus with normal cardiac activity.

Due to the patient's history of uterine ablation, the cesarean scar pregnancy of fetus B, triplet gestation, and missed abortion of fetus A, she was counseled on the high morbidity associated with continuing this pregnancy and was offered termination of pregnancy. This was an undesired pregnancy, and the patient understood the risks to her own health associated with continuing the pregnancy as well as

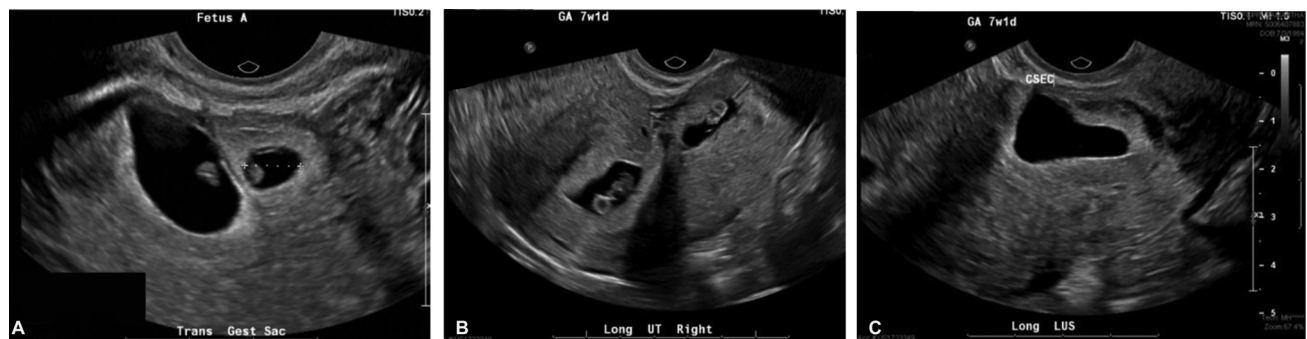

Fig. 1 Transvaginal ultrasound (TVUS) on hospital day 1. (A) A transverse view of the lower uterine segment with fetus A on the right and fetus B on the left, adjacent to each other and both abutting the cesarean section scar. (B) A longitudinal view of the uterus with fetus B in the lower anterior uterine segment and fetus C at the fundus. (C) Gestational sac for fetus B with irregular shape and immediately adjacent to the cesarean scar.

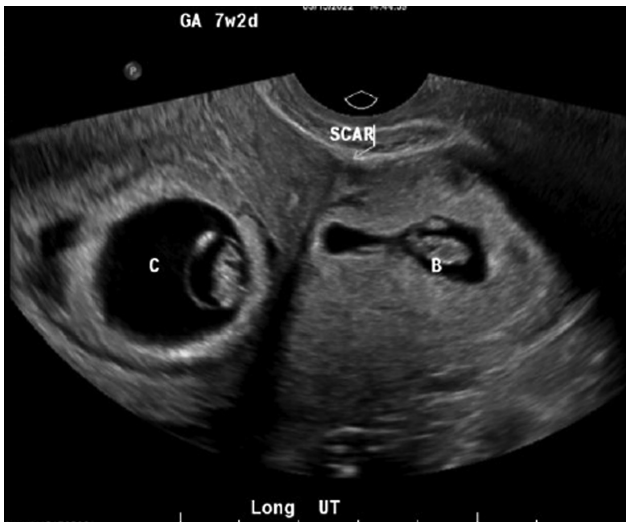

Fig. 2 Transvaginal ultrasound (TVUS) on hospital day 2, demonstrating fetus C and fetus B, with irregular gestational sac for fetus B demonstrating bulbous superior anterior component.

the very low likelihood of the pregnancy resulting in a live birth. Thus, the patient elected for termination of pregnancy. In accordance with institutional policy, the Ethics Committee met to discuss the case and approved the termination. Hematology was consulted due to the patient's history of low von Willebrand factor activity and she was found to have normal von Willebrand factor activity and antigen. It was thought that her previously low levels of von Willebrand factor activity could be due to her O blood type. Clotting factors were also checked and were normal. She was cleared for surgery by hematology.

Treatment

The patient underwent suction dilation and curettage with concurrent laparoscopic bilateral salpingectomy without complications. Intraoperatively, a survey of the patient's pelvis and abdomen revealed normal anatomy with excess scarring of the uterus anteriorly with the bladder. Her total blood loss from both procedures was 400 mL and she recovered well and was discharged home in stable condition the day of surgery.

Outcome and Follow-Up

The patient was seen for follow-up 2 weeks postoperatively, at which time she reported feeling well and had no complications. The patient was incredibly thankful for the care she received, stating that at outside institutions she was discharged home without any plan for treatment or follow-up and was told to present again when she started spontaneously miscarrying. The patient perceived that other institutions' medical teams were uncomfortable managing her multiple rare conditions compounded with physicians' discomfort with termination of the remaining two live pregnancies.

Discussion

This case highlights several high-risk pregnancy conditions and their potential implications. Pregnancies following uterine ablation, cesarean scar pregnancy, and heterotopic triplet pregnancy are all rare events. The co-occurrence of these conditions in our patient is an extremely rare event that, to the best of our knowledge, has not been previously reported in the literature. Given the rarity of the patient's conditions and the two live intrauterine pregnancies, the patient felt that the initial providers who treated her were uncertain as to the proper course of treatment. A thorough review of the literature describing cases involving each of her separate conditions is helpful in guiding counseling the patient and in determining the treatment approach. Because our patient did not desire to continue the pregnancy, she was offered termination via dilation and curettage but was also counseled on possible need for hysterectomy in the event of uncontrollable bleeding at the cesarean section scar. The patient had no surgical complications.

Pregnancy after uterine ablation is a fairly rare event, experienced in about 1 to 3% of people who have undergone this procedure.⁸ Most patients with a pregnancy following uterine ablation do not choose to continue the pregnancy; these pregnancies are more likely to result in PAS, preterm delivery, and malpresentation. A 7-year retrospective review of 7,863 women who underwent endometrial ablation (by thermal balloon, microwave, cryoablation, or radiofrequency ablation) published by Fernandez et al in 2021 found a post-

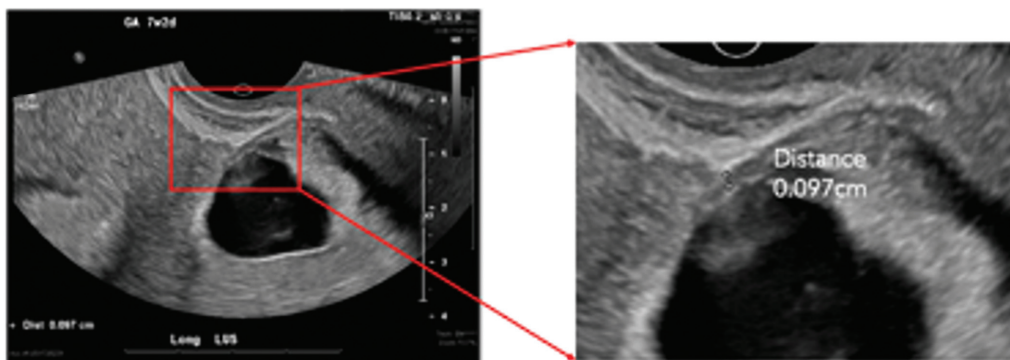


Fig. 3 Transvaginal ultrasound (TVUS) on hospital day 2, demonstrating thin myometrium (0.097 cm) anterior to the gestational sac of fetus B.

ablation pregnancy rate of 1.5% at 18 months.⁹ Another study by Ibiebele et al in 2020 followed 18,559 women with an endometrial ablation and found a post-ablation pregnancy rate of 3.1%. Among this population, there were high rates of cesarean delivery (43%), preterm birth (13%), twin or higher-order pregnancies ($n=54$, 9%), and stillbirth (13.3/1,000 births).¹⁰

Cesarean scar ectopic is a rare event as well; there are no reported rates, but this condition is becoming more common as women undergo more cesarean sections. Prompt and accurate diagnosis of cesarean scar pregnancy is difficult as presentation is variable—possibly with pelvic pain and bleeding but patients can also be asymptomatic. Treatment for cesarean scar ectopic pregnancies is not standardized, but the Society for Maternal Fetal Medicine recommends surgical management with possible intra-gestational methotrexate. Those who choose expectant management and continue cesarean scar pregnancies are at high risk of morbidity such as PAS, cesarean scar dehiscence, uterine rupture, postpartum hemorrhage, and postpartum hysterectomy.⁷

Heterotopic pregnancy is estimated to occur in approximately 1 in 30,000 pregnancies. Spontaneous heterotopic triplet pregnancies are very rare, with only three cases reported in the literature. One case from 1903 reported by Marshal et al resulted in uterine rupture and death of all three fetuses as well as the mother.² Another was a case reported by Guimarães et al in 2019. It was a case of spontaneous pregnancy in a nulliparous patient with a known intrauterine twin gestation presenting with right lower quadrant pain and presumed to have appendicitis. She underwent exploratory laparotomy and was found to have a normal appendix and a ruptured right tubal ectopic pregnancy.² Another case published by Nkurunziza et al in 2019 reported a case in Rwanda of a patient who had an intrauterine device (IUD) in place when she became pregnant. She presented in hemorrhagic shock and had to be transferred to a trauma center and had an exploratory laparotomy, which revealed an abdominal pregnancy as well as two intrauterine pregnancies with cornual uterine rupture and demise of all three triplets at 18 weeks. The patient underwent gravid hysterectomy and evacuation of 4 L of hemoperitoneum and survived.⁶

Heterotopic pregnancy most commonly refers to one tubal pregnancy and one intrauterine pregnancy. However, heterotopic cesarean scar pregnancies have been reported mostly in the context of in vitro fertilization (IVF) with embryo transfer. Ouyang et al reviewed 20 cases of cesarean scar heterotopic pregnancies, all resulting from IVF embryo transfer managed with a variety of approaches (including surgical treatment, ultrasound-guided potassium chloride injection, and expectant management) with just 1 of the 20 pregnancies resulting in a live birth of a cesarean scar pregnancy.¹¹ Another study reviewed 23 cases of heterotopic cesarean scar pregnancy with multiple approaches to management (including laparoscopic excision, hysteroscopic incision, open excision, ultrasound-guided potassium chloride injection, and expectant management). Of these 23 cases, there were 4 cases of scar rupture, 6 cases of Placenta Accreta

spectrum, 10 cases of postpartum hemorrhage, and 3 cases of peripartum hysterectomy. There were 2 first trimester losses, 2 second trimester deliveries, 11 preterm deliveries, and 8 term deliveries.⁵

Authreya et al reviewed the literature and found 23 heterotopic triplet pregnancies. The majority of these were a result of IVF embryo transfer and resulted in concurrent tubal and intrauterine pregnancies.⁵ Our literature review revealed two cases of cesarean scar heterotopic triplet pregnancy. Both cases were the result of IVF transfer of three viable embryos. One case reported by Hsieh et al in 2004 resulted in one cesarean scar pregnancy and two normal intrauterine pregnancies. This patient underwent vacuum aspiration of the contents of the gestational sac at the cesarean scar and subsequently carried the remaining two intrauterine pregnancies to 32 weeks, at which time the patient underwent an emergent cesarean delivery for preterm labor.¹² In 2011, Litwicka et al reported another case with two cesarean scar pregnancies and one normal intrauterine pregnancy, which was managed with intra-gestational potassium chloride and methotrexate followed by aspiration of the contents of the two cesarean scar gestational sacs. That patient went on to deliver a single live fetus at 36 weeks. Delivery was complicated by placental abruption and the fetus was found to have missing digits and malformed ears, which was initially thought to be a deformity related to possible methotrexate exposure but was later found to be an unrelated genetic mutation, Miller syndrome.⁴

This case is unique in that our patient was at risk of complications of cesarean scar pregnancy as well as risks associated with triplet pregnancy and pregnancy after uterine ablation. Occurring alone, each of these conditions increases the risk of spontaneous abortion, intrauterine fetal demise, preterm labor, and postpartum hemorrhage. Additional risks for the patient being discussed included dehiscence of the uterine scar, PAS, uterine rupture, and a significant risk of peripartum hysterectomy. The patient was amenable to dilation and curettage; because of these confounding risks, the patient was also offered hysterectomy, which she declined unless as a lifesaving measure. If the patient had chosen to continue this pregnancy, her management could be guided by prior reports of management of heterotopic cesarean scar pregnancy with methods such as potassium chloride injection and/or aspiration of the cesarean scar pregnancy. However, she still had significant risk associated with pregnancy after uterine ablation, which has not been reported before in the context of her other comorbid obstetric conditions. This case demonstrates the use of prior reported cases to guide counseling and management of a rare constellation of conditions. The patient was able to make an informed decision regarding her treatment because of the counseling provided using information from prior cases and was satisfied with her care. This case also highlights multiple conditions that warrant a discussion of treatment options including termination of pregnancy. This patient presented in a clinically stable condition. It is imperative to note, however, that she was referred to our care after seeking care with different health care providers, who

(according to the patient) were uncomfortable managing her care. Had the patient continued the pregnancy, she could have developed acute instability with any of the possible complications listed earlier and could have required emergency termination of the pregnancy, among other interventions, to save her life. Given this risk, her ability to terminate the pregnancy before these complications occurred serves as an example of the need for easily accessible, safe termination of pregnancy for all patients who may desire or need a termination of pregnancy. It further highlights the need to seek prompt treatment and the importance of appropriate counseling to ensure that the patient understands the importance of timely treatment and follow-up.

Funding

None.

Conflict of Interest

None declared.

Acknowledgments

We thank Anne W. Rosebrock, the Orlando Health Librarian, who was instrumental in identifying relevant articles for literature review.

References

- 1 Felekis T, Akrivis C, Tsirkas P, Korkontzelos I. Heterotopic triplet pregnancy after in vitro fertilization with favorable outcome of the intrauterine twin pregnancy subsequent to surgical treatment of the tubal pregnancy. *Case Rep Obstet Gynecol* 2014;356131
- 2 Guimarães AC, Reis LDO, Leite FC, Reis CFDD, Costa AP, Araujo WJB. Spontaneous heterotopic triplet pregnancy with two viable intrauterine embryos and an ectopic with right tubal rupture. *Rev Bras Ginecol Obstet* 2019;41(04):268–272
- 3 Inion I, Gerris J, Joostens M, De Vree B, Kockx M, Verdonk P. An unexpected triplet heterotopic pregnancy after replacement of two embryos. *Hum Reprod* 1998;13(07):1999–2001
- 4 Litwicka K, Greco E, Prefumo F, et al. Successful management of a triplet heterotopic caesarean scar pregnancy after in vitro fertilization-embryo transfer. *Fertil Steril* 2011;95(01):291.e1–291.e3
- 5 Authreya AJ, Agrawal P, Makam A. Ultrasound-guided procedures in the management of heterotopic caesarean scar pregnancy: a review of case reports and case series. *Australas J Ultrasound Med* 2021;24(02):70–77
- 6 Nkurunziza C, Rurangwa T, Ngendahimana V, Magriples U. Second trimester heterotopic triplet pregnancy with intrauterine twin pregnancy and ruptured interstitial pregnancy: a maternal near-miss case report. *Case Rep Obstet Gynecol* 2020;5240848
- 7 Miller R, Timr-Tritch I, Gyamfi-Bannerman C. Society for Maternal Fetal Medicine. Society for Maternal Fetal Medicine (SMFM) consult series #49: cesarean scar pregnancies. *Am J Obstet Gynecol* 2020;222(05):B2–B14
- 8 Endometrial Ablation. ACOG practice bulletin # 81. American College of Obstetrics and Gynecology. *Obstet Gynecol* 2007;109:1233–1248
- 9 Fernandez H, Toth D, Descamps P, Capmas P, Lamarsalle L. Post procedural pregnancy occurrence risk after endometrial ablation. *J Gynecol Obstet Hum Reprod* 2022;51(01):102259
- 10 Ibiebele I, Nippita TA, Baber R, Torvaldsen S. A study of pregnancy after endometrial ablation using linked population data. *Acta Obstet Gynecol Scand* 2021;100(02):286–293
- 11 Ouyang Y, Chen H, Lin G, et al. Heterotopic cesarean scar pregnancy: an analysis of 20 cases following in vitro fertilization-embryo transfer. *J Ultrasound Med* 2021;40(10):2239–2249
- 12 Hsieh BC, Hwang JL, Pan HS, Huang SC, Chen CY, Chen PH. Heterotopic caesarean scar pregnancy combined with intrauterine pregnancy successfully treated with embryo aspiration for selective embryo reduction: case report. *Hum Reprod* 2004;19(02):285–287