

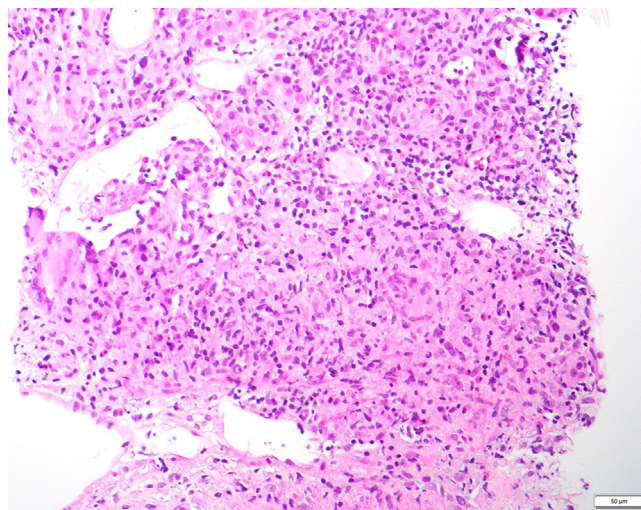
## Acute Interstitial Nephritis on Positron-Emission Tomography-Computed Tomography Imaging



Jing Miao, Mariam P. Alexander, and Ziad M. Zoghby

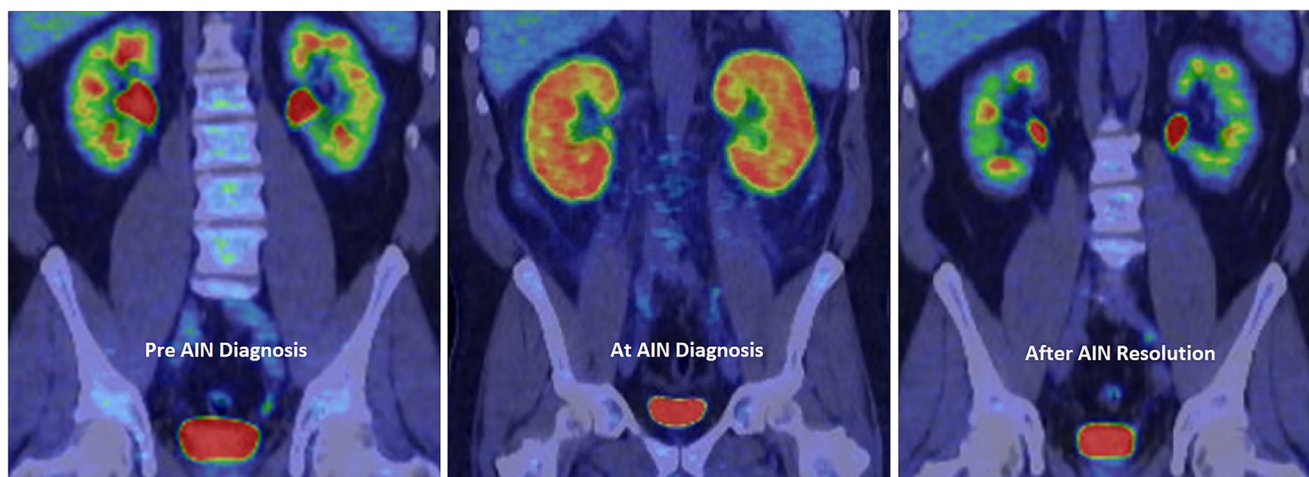
A man in his 40s with a 20-year history of relapsing Hodgkin lymphoma on multiple lines of chemotherapy was admitted to the hospital for evaluation of fever, headache, and night sweat for 7 days. Serum creatinine level was 1.72 mg/dL (baseline, 1.11–1.24 mg/dL) 1 day before admission and 2.44 mg/dL the following day. Urinalysis was bland. Six weeks earlier, after evidence of recurrence of his lymphoma on positron-emission tomography (PET-CT) scan, he received 2 doses (3 weeks apart) of an experimental drug (camidanlumab, an IgG1 drug directed against CD25) as part of a clinical trial. A repeat PET-CT scan to reassess disease burden showed intense heterogeneous fluorodeoxyglucose activity in both kidneys (Fig 1) but an almost complete metabolic response otherwise. The kidney biopsy showed granulomatous interstitial nephritis (Fig 2). After the initiation of high-dose steroids, his symptoms quickly resolved, and serum creatinine level gradually decreased to 1.34 mg/dL and to 1.27 mg/dL 4 months later. Interestingly, a repeat PET-CT scan done at that time for disease monitoring showed resolution of fluorodeoxyglucose activity in the kidneys bilaterally (Fig 1), consistent with the resolution of the inflammatory changes.

Abdominal imaging studies have been recognized as important tools to detect immune-related adverse events during cancer surveillance, and PET-CT scan can be a potential noninvasive diagnostic tool for acute interstitial nephritis in patients with malignancy



**Figure 2.** Kidney biopsy, light microscopy, hematoxylin and eosin staining (Original magnification, ×200) showing granulomatous interstitial nephritis. The interstitium is expanded with a dense inflammatory infiltrate, inclusive of plasma cells, lymphocytes, eosinophils, and ill-formed granulomata. Multinucleated giant cells are seen in the interstitium.

treated with immune check inhibitors, especially when a baseline comparison is possible.<sup>1,2</sup> This case lends further support to use PET-CT scan as an adjuvant to diagnose a presumptive diagnosis of acute interstitial



**Figure 1.** PET-CT scan prior, at the time, and after resolution of the allergic interstitial nephritis.

nephritis when other causes of acute kidney injury have been ruled out, particularly when kidney biopsy is contraindicated.

## ARTICLE INFORMATION

**Authors' Full Names and Academic Degrees:** Jing Miao, MD, Mariam P. Alexander, MD, and Ziad M. Zoghby, MD

**Authors' Affiliations:** Division of Nephrology and Hypertension, Department of Medicine, Mayo Clinic, Rochester, MN (JM, ZMZ); and Department of Laboratory Medicine and Pathology, Mayo Clinic, Rochester, MN (MPA).

**Address for Correspondence:** Z.M. Zoghby Email: [zoghby.ziad@mayo.edu](mailto:zoghby.ziad@mayo.edu)

**Financial Disclosure:** The authors declare that they have no relevant financial interests.

**Peer Review:** Received July 24, 2022. Direct editorial input from the Editor-in-Chief. Accepted in revised form August 17, 2022.

**Publication Information:** © 2022 The Authors. Published by Elsevier Inc. on behalf of the National Kidney Foundation, Inc. This is an open access article under the CC BY-NC-ND license (<http://creativecommons.org/licenses/by-nc-nd/4.0/>). Published online September 30, 2022. with doi [10.1016/j.xkme.2022.100552](https://doi.org/10.1016/j.xkme.2022.100552)

## REFERENCES

1. Anderson MA, Kurra V, Bradley W, Kilcoyne A, Mojtahed A, Lee SI. Abdominal immune-related adverse events: detection on ultrasonography, CT, MRI and 18F-fluorodeoxyglucose positron emission tomography. *Br J Radiol.* 2021;94(1118): 20200663.
2. Qualls D, Seethapathy H, Bates H, et al. Positron emission tomography as an adjuvant diagnostic test in the evaluation of checkpoint inhibitor-associated acute interstitial nephritis. *J Immunother Cancer.* 2019;7(1): 356.