

# Palatoplasty Using Alveolar Ridge Incisions: A Novel Approach for Addressing Cleft Palate Deformities

Sumun Khetpal, MD  
Harsh Patel, MD  
Michael DeLong, MD  
Mengyuan T. Liu, MD  
Wayne H. Ozaki, MD, DDS, FACS

**Background:** Traditionally, plastic surgeons have performed palatoplasties using mucoperiosteal flaps with lateral incisions that are medial to the alveolar ridge. However, narrow flaps can cause limitations in some cases. To construct larger and wider flaps and minimize exposed bone after closure, we propose a novel technique that entails creating the lateral incisions at the top of the alveolar ridge, instead of the base of the alveolar ridge, to capture more tissue when repairing the hard palate.

**Methods:** A retrospective chart review was conducted for patients undergoing cleft palate repair with the aforementioned technique. Information collected included basic demographic and diagnostic factors related to cleft palate deformity and history of previous facial surgeries. Operative report details and postoperative complications were analyzed.

**Results:** Nineteen patients with hard palate clefts were included in the analysis, with the majority being women (68%). There was a balanced representation of patients with Veau classifications of II (47%) and III (42%). The majority of patients had an isolated cleft palate (74%) and incomplete deformity (63%), with no other craniofacial deformities. One (5%) had postoperative self-limited oronasal fistula managed conservatively.

**Conclusions:** We present a novel approach for repairing cleft palate deformities by extending the lateral incision to the top of the alveolar ridge to create larger mucosal flaps. Further longitudinal studies are needed to evaluate how this unique approach compares to traditional methods—with respect to impact on maxillary growth processes, requirement for subsequent surgeries beyond two years of follow-up, and ultimately normalized speech over time. (*Plast Reconstr Surg Glob Open* 2022;10:e4275; doi: [10.1097/GOX.0000000000004275](https://doi.org/10.1097/GOX.0000000000004275); Published online 18 April 2022.)

## INTRODUCTION

Occurring in one out of 1700 births, cleft palate defects arise due to the failure of fusion of the palatine shelves during the process of embryogenesis.<sup>1</sup> The subsequent deformity may involve the soft and/or hard palate, and may extend through the alveolus in a unilateral or bilateral fashion. The manifestations of cleft palate are largely functional: patients with clefts of the hard palate may experience feeding difficulties due to the inability to generate negative intraoral pressure, whereas those with clefts of the soft palate may experience disruption of the velopharyngeal port and subsequent speech

dysfunction.<sup>1,2</sup> Thus, the aims of palatoplasty repair are primarily (1) to restore the separation of the oral and nasal cavities; (2) to create a velopharyngeal port to prevent hypernasality; and (3) to address Eustachian tube dysfunction and recurrent otitis media.<sup>1-3</sup> In addition to these goals, plastic surgeons must attempt to avoid the possibility of creating a palatal fistula and maxillary growth disturbance for these patients.

A variety of palatoplasty techniques have been reported and implemented for the restoration of cleft palate deformities; these include the Furlow palatoplasty, two-flap palatoplasty, palatoplasty with vomer flaps, and palatoplasty with veloplasty.<sup>2</sup> The elevation of bilateral hard palate mucosal flaps has historically entailed scoring incisions made at the gingivopalatal sulcus. Although these flaps may be sufficient for repairing most defects, some patients, especially those with wide U-shaped clefts or those with very inclined palatal shelves, may benefit from the mobilization of larger flaps. Extensive manipulation may predispose patients to a higher risk of wound complications, fistula formation, or maxillary growth

From the Division of Plastic and Reconstructive Surgery, University of California – Los Angeles, Los Angeles, Calif.

Received for publication January 11, 2022; accepted February 24, 2022.

Copyright © 2022 The Authors. Published by Wolters Kluwer Health, Inc. on behalf of The American Society of Plastic Surgeons. This is an open-access article distributed under the terms of the [Creative Commons Attribution-Non Commercial-No Derivatives License 4.0 \(CCBY-NC-ND\)](https://creativecommons.org/licenses/by-nc-nd/4.0/), where it is permissible to download and share the work provided it is properly cited. The work cannot be changed in any way or used commercially without permission from the journal.

DOI: [10.1097/GOX.0000000000004275](https://doi.org/10.1097/GOX.0000000000004275)

**Disclosure:** The authors have no financial interest to declare in relation to the content of this article. No funding was received for this work.

disturbance. To construct larger flaps to minimize tissue mobilization, a number of alternative methods have been proposed. The senior author (WO) prefers creating lateral incisions the top of the alveolar ridge to recruit flaps of greater area. To the authors' knowledge, this unique approach toward restoring cleft palate deformities has not yet been proposed or discussed in the literature.

The purpose of this study was multi-fold: (1) to introduce the senior author's novel technique for incision along the dental margin, as opposed to the alveolar ridge to hard palate junction, for creation of larger mucosal flaps during palatoplasty; (2) to assess clinical outcomes (ie, requirement of subsequent surgeries) associated with this technique relative to historical controls within the literature; and finally, (3) to discuss the specific anatomic considerations and criteria for utilization of this approach. We hypothesize that the proposed technique will confer lower rates of postoperative fistula by reducing closure tension without causing dental complications. Furthermore, we anticipate that the larger flaps afforded by this technique may be favorable for patients with wide or challenging cleft palate deformities.

## METHODS

### Overview of Technique

The patient is orally intubated and a Dingman retractor is used to provide exposure. Approach to the soft palate typically involves standard Furlow palatoplasty or linear closure with an intravelar veloplasty (5 mm or less Furlow palatoplasty, >5 mm linear closure with intravelar veloplasty). For the hard palate, incision is made at the cleft margin to separate nasal and oral mucosa circumferentially. Lateral incisions are made at the top of the alveolar ridge (or the dental sulcus when teeth are present) rather than in the junction between the base of the alveolar ridge and hard palate. The flaps are bluntly elevated in the subperiosteal plane from the underlying maxillary and palatine bone with care to preserve greater palatine neurovascular bundle bilaterally. For clefts extending through the alveolus, two similar mucosal flaps are elevated on either side of the cleft. Vomer flaps are elevated when required. The nasal mucosa is then repaired with 4-0 Vicryl sutures, followed by a repair in midline of the mobilized mucoperiosteal flaps with 4-0 Vicryl sutures. Posteriorly, the nasal mucosa, muscle, and oral mucosa are repaired with 4-0 Vicryl suture. A 4-0 Nylon is used for a tongue stitch, and the patient is admitted overnight for airway observation. An illustration of the senior author's technique is shown in [Figure 1](#).

### Clinical Chart Review

A retrospective chart review approved by the University of California – Los Angeles (UCLA) Institutional Review Board (IRB#20-001420) was conducted for all of the senior author's patients undergoing hard palate palatoplasty (CPT 42200) between the

## Takeaways

**Question:** In palatoplasty, can larger and wider flaps be constructed through creating incisions along the alveolar ridge? What are the clinical outcomes and complications associated with this technique?

**Findings:** A retrospective chart review was conducted for patients undergoing cleft palate repair. Demographic information, operative report details and postoperative complications were analyzed. Nineteen patients with hard palate clefts were included, with the majority being women (68%). The majority of patients had an isolated cleft palate (74%) and incomplete deformity (63%), and two (10%) had postoperative oronasal fistula managed conservatively.

**Meaning:** This technique represents a safe and effective surgical option for cleft palate patients.

years 2015 and 2020, representing all years available in electronic health records at UCLA. Patients with isolated soft palate defects (Veau I) were excluded. Basic demographic variables (ie, gender, ethnicity, age at time of repair) were extracted from charts along with relevant diagnostic variables, including Veau classification, type of palate, laterality, associated craniofacial syndrome(s), and history of previous facial surgeries. Operative report details were also recorded for each patient, including type of repair performed, duration of surgery, duration of anesthesia, length of stay, speech quality, postoperative oronasal fistula, dental anomalies, requirement of subsequent surgeries, and duration of follow-up by plastic surgery craniofacial team. All analyses conformed to Strengthening the Reporting of Observational Studies in Epidemiology guidelines.

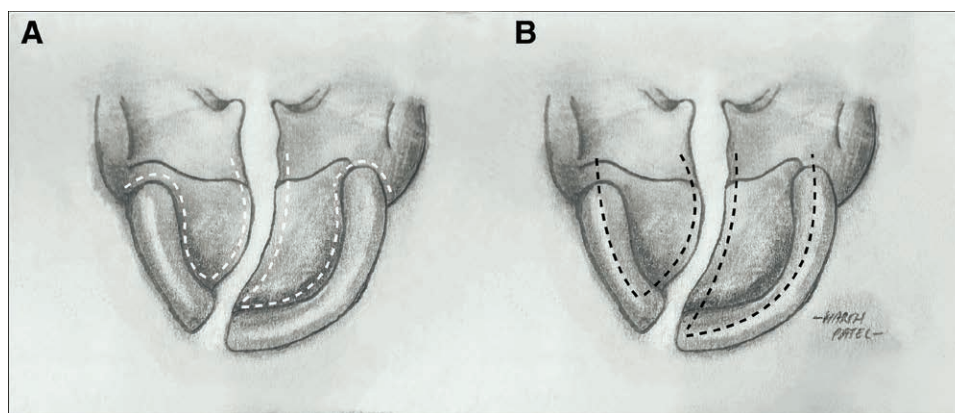
## RESULTS

### Demographic Information

Nineteen patients were included in the analysis, of which the majority were women (68%). There were a larger portion of Hispanic (61%) patients, compared with those of other ethnicities. A comprehensive summary of the demographic information can be found in [Table 1](#).

### Diagnostic Factors

There was a balanced representation of patients with Veau classifications of II (47%) and III (42%); one patient (4%) had a cleft defect of Veau IV classification. The majority of patients had an isolated cleft palate (74%) and incomplete deformity (63%), with no other craniofacial deformities. Only two (10%) had associated craniofacial syndromes. Six patients had prior facial surgery (including cleft lip repair, rhinoplasty, and mandibular distraction) before cleft palate repair. A comprehensive summary of the diagnostic information can be found in [Table 1](#). On average, the procedures lasted 124 minutes, and patients remained admitted for



**Fig. 1.** Illustration of senior author's technique. A, Illustration demonstrating the mainstay technique for correction of cleft palate deformities, specifically through the elevation of flaps with lateral incisions (dotted white lines) that are medial to the alveolar ridge, at the gingivobuccal sulcus. B, Display of the senior author's technique, which involves scoring incisions (dotted black lines) at the gum line for recruitment of larger flaps.

1.06 days. A comprehensive summary of the procedural details can be found in [Table 2](#).

**Requirement for Subsequent Surgeries and Follow-up**

Of the 19 patients, no patients required subsequent revision interventions for repair of cleft defects. In total, 81% of patients had no reported hypernasality or mispronunciations at speech pathology evaluation. One (5%) patient had postoperative oronasal fistula (at the junction between hard and soft palate, measuring 2mm) but closed spontaneously without requiring secondary surgical repair. Four (21%) patients had dental anomalies, which included class I occlusion, presence of tooth within cleft, microdontia of mandibular incisors with associated mandibular deviation, and hypoplastic #A. Of note, none

of the patients encountered issues with primary tooth eruption.

**DISCUSSION**

This study sought to introduce a novel technique in addressing cleft palate deformities, particularly those that would require extensive tissue mobilization. In all, we found that this approach confers favorable clinical outcomes for patients with cleft palate, and may be utilized to mitigate extraneous tissue mobilization and manipulation for ideal approximation of flaps.

The primary outcome of cleft palate repair lies in the achievement of velopharyngeal competence without fistula.<sup>4-14</sup> Of our 19 patients, one patient (with Veau classifications of III) had postoperative oronasal fistulas. The patient did not require further surgical intervention. This fistula rate is comparable to those stated in the literature, as studies by Yuan et al found a 4.5% rate of palatal fistula in 117 patients undergoing primary cleft palatoplasty, and Sullivan et al found a rate of 2.9% of 449 patients.<sup>4,5</sup> While the rate of postoperative fistula within our cohort

**Table 1. Overview of Patient Demographic and Diagnostic Information**

Gender	
Women	13 (68%)
Men	6 (32%)
Average body mass index	16.5
Ethnicity	
Asian American	0 (0%)
White	6 (31%)
African American	0 (0%)
Hispanic	11 (61%)
Unknown	2 (11%)
Veau classification	
2	9 (47%)
3	8 (42%)
4	1 (4%)
Not recorded	1 (5%)
Type of palate	
Isolated cleft palate	14 (74%)
Unilateral cleft lip and palate	5 (26%)
Bilateral cleft lip and palate	1 (5%)
Incomplete	
Complete	12 (63%)
Complete	7 (37%)
Syndromic	
8p22. translocation	2 (10%)
Pierre Robin sequence	1 (5%)
Nonsyndromic	17 (90%)
History of previous surgeries	6 (32%)

**Table 2. Overview of Procedural and Postoperative Details**

Type of repair	
Furlow palatoplasty	12 (44%)
Palatoplasty	4 (15%)
Palatoplasty with intravelar veloplasty	4 (15%)
Palatoplasty with vomer flap	1 (4%)
Two-flap palatoplasty	5 (19%)
Palatoplasty and cleft lip revision	1 (4%)
Speech quality	
Normal	22 (81%)
VPI	1 (4%)
Nasal speech	2 (7%)
Speech delay	1 (4%)
Unknown	1 (4%)
Oronasal fistula	2 (7%)
Dental anomalies	5 (19%)
Duration of surgery (min)	117
Duration of anesthesia (min)	193
Length of stay (d)	1.22
Subsequent surgeries	2 (7%)
Duration of follow-up (y)	1.83

was 5%, it is important to recognize the likely high degree of selection bias among our patients. Prior reports included patients with all cleft palate types, whereas the present report is limited to larger clefts that include the hard palate. The observed fistulae were also in the midline representing a potential paucity of tissue, which should theoretically be improved by the creation of larger flaps. There were no notable complications at the dental margin or with the patient dentition, suggesting no adverse effects of making the releasing incision at this location. Future studies could directly compare how traditional incision techniques compared with the discussed approach for patients of greater Veau hierarchy. This ultimately may provide helpful insight and guidance for plastic surgeons considering various techniques for correcting palatal deformities of higher severity.

In terms of speech outcomes and assessment of velopharyngeal competence, the majority (79%) of patients had normal speech quality with no apparent velopharyngeal insufficiency (VPI) after palatoplasty. Only one patient with a Veau classification of III was recorded to have VPI; two were found to have hypernasal speech; one other was determined to have speech delay. In all, the rates of VPI within our cohort were lower than those reported in the literature.<sup>4-14</sup> In fact, Sullivan et al conducted a 29-year analysis of patients undergoing palatoplasty, and found that of 449 patients, 85.1% had postoperative VPI.<sup>5</sup> The study also found significant correlation between the incidence of VPI and increased Veau hierarchy and age at the time of palatoplasty.<sup>5</sup> While our results suggest superior outcomes in maintaining velopharyngeal competence, further studies may stratify patients by Veau classification, and in doing so, achieve more accurate comparison of patient cohorts.

In terms of revision surgeries, no patients within our analyzed sample required further intervention. Of note, our investigation included 2 years of follow-up, and therefore is limited in assessing longitudinal outcomes associated with requirement for future surgeries for refinement of facial appearance—namely rhinoplasty, orthognathic surgery, and alveolar bone grafting. Future studies could explore these differences between patients who received this approach of cleft palate repair, relative to traditional incision techniques. In addition, it remains unclear to what extent the scarring along the alveolar ridge impacts primary tooth eruption. While our analysis did not reveal any patients with this complication, future longitudinal studies may explore how the senior author's technique may affect growth of primary teeth.

There are several limitations of this study that warrant consideration. First, while the average period of follow-up was nearly 2 years in this investigation, our ability to longitudinally assess the clinical outcomes of this technique is limited; specifically, information surrounding the need for subsequent surgeries, such as rhinoplasty, bone grafting, and orthognathic surgery, was incomplete within our cohort. Future studies could implement a longer follow-up period and a greater sample size for evaluation of patients to better understand how the technique may mitigate complications, as well as

the potential need for re-operation. Second, given that our study utilizes historical controls reported in the literature to assess the safety and efficacy of the discussed technique, the external validity and generalizability of results may be compromised. Third, although the study favors the utilization of this technique, it remains unclear which deformities are best addressed with this approach. Future studies could perform stratified analyses based on Veau classification, as well as other severity measurements, to better assess how the technique compares to those of traditional incision types. In doing so, objective algorithms can be developed to better help plastic surgeons navigate reconstruction of cleft palate deformities. Finally, it remains unclear how this technique impacts the ultimate tension placed along suture lines, and how this may inform differences in complication rates; future studies may incorporate geometric analysis to further quantify this aspect of the aforementioned technique.

## CONCLUSIONS

This study presents a novel approach toward the correction of cleft palate deformities—particularly those that have traditionally involved extensive tissue mobilization and manipulation. Our analysis evaluates the practice of scoring incisions at the gum line, as opposed to gingivolabial sulcus, to elevate large flaps during palatoplasty. We established that this technique offers a safe and effective surgical option for patients with clefts involving the hard palate. Future studies can explore how this unique approach compares to traditional incision techniques—with respect to maxillary growth disturbances, requirement for subsequent surgeries beyond two years, and ultimate aesthetic appearance.

Wayne H. Ozaki, MD, DDS, FACS

Department of Surgery  
Division of Plastic and Reconstructive Surgery  
University of California – Los Angeles  
200 Medical Plaza, Suite 460  
Los Angeles, CA 900995  
E-mail: WOzaki@mednet.ucla.edu

## REFERENCES

1. Yu W, Serrano M, Miguel SS, et al. Cleft lip and palate genetics and application in early embryological development. *Indian J Plast Surg.* 2009;42(Suppl):S35–S50.
2. Czerwinski M, Gosman AA. Cleft palate. *Essentials of Plastic Surgery.* New York, N.Y.: Thieme Medical Publishers; 2017:275–287.
3. Kosowski TR, Weathers WM, Wolfswinkel EM, et al. Cleft palate. *Semin Plast Surg.* 2012;26:164–169.
4. Yuan N, Dorafshar AH, Follmar KE, et al. Effects of cleft width and Veau type on incidence of palatal fistula and velopharyngeal insufficiency after cleft palate repair. *Ann Plast Surg.* 2016;76:406–410.
5. Sullivan SR, Marrinan EM, LaBrie RA, et al. Palatoplasty outcomes in nonsyndromic patients with cleft palate: a 29-year assessment of one surgeon's experience. *J Craniofac Surg.* 2009;20(Suppl 1):612–616.
6. Fisher DM, Sommerlad BC. Cleft lip, cleft palate, and velopharyngeal insufficiency. *Plast Reconstr Surg.* 2011;128:342e–360e.

7. Stein MJ, Zhang Z, Fell M, et al. Determining postoperative outcomes after cleft palate repair: a systematic review and meta-analysis. *J Plast Reconstr Aesthet Surg.* 2019;72:85–91.
8. Tse RW, Siebold B. Cleft palate repair: description of an approach, its evolution, and analysis of postoperative fistulas. *Plast Reconstr Surg.* 2018;141:1201–1214.
9. Salimi N, Aleksejūnienė J, Yen EH, et al. Fistula in cleft lip and palate patients—a systematic scoping review. *Ann Plast Surg.* 2017;78:91–102.
10. Smyth AG, Wu J. Cleft palate outcomes and prognostic impact of palatal fistula on subsequent velopharyngeal function—a retrospective cohort study. *Cleft Palate Craniofac J.* 2019;56:1008–1012.
11. Eliason MJ, Hadford S, Green L, et al. Incidence of fistula formation and velopharyngeal insufficiency in early versus standard cleft palate repair. *J Craniofac Surg.* 2020;31:980–982.
12. Pollard SH, Skirko JR, Dance D, et al. Oronasal fistula risk after palate repair. *Cleft Palate Craniofac J.* 2021;58:35–41.
13. Bykowski MR, Naran S, Winger DG, et al. The rate of oronasal fistula following primary cleft palate surgery: a meta-analysis. *Cleft Palate Craniofac J.* 2015;52:e81–e87.
14. Tache A, Mommaerts MY. On the frequency of oronasal fistulation after primary cleft palate repair. *Cleft Palate Craniofac J.* 2019;56:1302–1313.