

## Original Article

# Identification of *Mycoplasma capricolum* subspecies *capripneumoniae* and *Mycoplasma arginini* by culture, PCR, and histopathology in pneumonic lungs of slaughtered goats in Mashhad, Iran

Khodakaram-Tafti, A.<sup>1\*</sup>; Derakhshandeh, A.<sup>1</sup>; Daei, A. A.<sup>2</sup>  
and Seyedin, M.<sup>3</sup>

<sup>1</sup>Department of Pathobiology, School of Veterinary Medicine, Shiraz University, Shiraz, Iran; <sup>2</sup>Ph.D. Student in Veterinary Pathology, Department of Pathobiology, School of Veterinary Medicine, Shiraz University, Shiraz, Iran; <sup>3</sup>Division of Bacteriology, Razi Vaccine and Serum Research Institute, Agricultural Research, Education and Extension Organization (AREEO), Mashhad, Iran

\*Correspondence: A. Khodakaram-Tafti, Department of Pathobiology, School of Veterinary Medicine, Shiraz University, Shiraz, Iran. E-mail: tafti@shirazu.ac.ir



10.22099/IJVR.2023.45321.6655

(Received 5 Dec 2022; revised version 11 Mar 2023; accepted 24 Apr 2023)

This is an open access article under the CC BY-NC-ND license (<http://creativecommons.org/licenses/by-nc-nd/4.0/>)

## Abstract

**Background:** A number of *Mycoplasma* spp., often referred to as the *Mycoplasma mycoides* (Mm) cluster can produce respiratory tract infections in goats; however, only *Mycoplasma capricolum* subspecies *capripneumoniae* (Mccp) is considered to cause contagious caprine pleuropneumonia. **Aims:** Isolation and identification of *M. capricolum* subspecies *capripneumoniae* and *M. arginini* from the pneumonic lungs of slaughtered goats and their association with pathological changes. **Methods:** Lungs of 2000 goats slaughtered at an industrial abattoir in Mashhad, Iran, were examined for the presence of gross pneumonic lesions. Fifty affected lungs were selected for pathology, culture, and molecular (PCR) studies for the presence of *Mycoplasma* species. DNA was extracted from lung tissue samples and replicated using genus and species specific primers for *Mycoplasma*. **Results:** Grossly, consolidation and dark red to grey discoloration in the cranioventral to caudal lobes in fibrinopurulent bronchopneumonia and rubbery texture associated with rib impressions on the costal surfaces of the diaphragmatic lobes in interstitial pneumonia were observed. Histopathologically, bronchointerstitial pneumonia in 40 (80%), and fibrinopurulent bronchopneumonia in 10 (20%) of affected goats were diagnosed. The evidence of *Mycoplasma* growth such as turbidity and *Mycoplasma* colonies on the *Mycoplasma* agar plates was observed in 2 (4%) of samples. Genus-specific *Mycoplasma* DNA was identified in 11 (22%) of samples. Of them, 3 (6%) and 3 (6%) of tissue lung samples were positive for *M. capricolum* subspecies *capripneumoniae* and *M. arginini*, respectively, by PCR. **Conclusion:** Our results showed that *M. capricolum* subspecies *capripneumoniae* and *M. arginini* were the two agents that can involve lung consolidation and pneumonia in goats.

**Key words:** Goat, *M. arginini*, *M. capricolum* subspecies *capripneumoniae*, PCR, Pneumonia

## Introduction

Respiratory diseases are considered as important causes of mortality in lambs and kids, reduced growth rate and condemnation of the carcasses in all major small ruminants-producing countries. They impose substantial economic impact on animal husbandry due to the need for chemotherapeutic measures and vaccination (Goodwin *et al.*, 2004). *Mycoplasma* spp. is one of the major causes of pneumonia which is not frequently detected due to the lack of rapid diagnostic tests. A number of *Mycoplasma* spp., often referred to as the *Mycoplasma mycoides* (Mm) cluster, can produce respiratory tract infections in goats; however, only *M. capricolum* subspecies *capripneumoniae* (Mccp) is considered to cause contagious caprine pleuropneumonia (Lopez and Martinson, 2022). Some of the other known virulent *Mycoplasmas* are *M. mycoides* subspecies

*mycoides* large colony type (MmmLC), *M. mycoides* subspecies *capri* (Mmc), *M. mycoides* subspecies *mycoides* small colony type (MmmSC), *M. capricolum* subspecies *capricolum* (Mcc), and the bovine group 7. All these *Mycoplasmas* share genomic and antigenic features with very close biochemical and serological properties. This makes precise identification of individual isolates a difficult task and results in controversies among diagnosticians (Thiaucourt and Bölske, 1996; Hernandez *et al.*, 2006).

*Mycoplasmas* are herd problems with high morbidity and low mortality. Healthy carriers are an important part of the epidemiology of these agents (Radostits *et al.*, 2007). Several *Mycoplasma* species including *M. mycoides* subspecies *mycoides* LC, *M. capricolum* subspecies *capricolum*, *M. capricolum* subspecies *capripneumoniae* and *M. arginini* are isolated from caprine pneumonic cases (Adehan *et al.*, 2006; Radostits

*et al.*, 2007; Semmate *et al.*, 2022). However, the pathogenicity of *M. arginini*, and *M. capricolum* subspecies *capricolum* in goats is still being defined and specific description of the lesions would be necessary. These organisms probably cause disease only in circumstances that host, infectious, and environmental factors have created a complex interaction for the pathogenesis of the disease (Lopez and Martinson, 2022). Recently, lung consolidation and pneumonia due to *M. ovipneumoniae* and *M. arginini* has been reported in the lungs of sheep in Iran (Daee *et al.*, 2020). Also, a high prevalence of *M. ovipneumoniae* in association with *Mannheimia haemolytica* has been reported in the lungs of lambs in Italy (Ettorre *et al.*, 2007).

Mycoplasmas can predispose animals to bacterial and viral infections (Nicholas *et al.*, 2008). They can cause pneumonia in goats and can be isolated from the lung and trachea. Results of several studies have indicated the presence of high numbers of carriers in goat herds (Amores *et al.*, 2010). To date, no study has described the role of *M. capricolum* subspecies *capripneumoniae* and *M. arginini* in pulmonary tract of goats in Iran. Also, there is no information or data that shows co-infections of these organisms in goats. The present study was undertaken to isolate and characterize *M. capricolum* subspecies *capripneumoniae* and *M. arginini* from the pneumonic lungs of slaughtered goats in Iran by culture and PCR and their correlation with pathological changes.

## Materials and Methods

### Sample collection

Khorasan Razavi province is situated in Northeast of Iran and is one of the most important provinces in terms of small ruminants breeding. In this study, the lungs of 2000 goats slaughtered at industrial slaughterhouse of Mashhad, Iran examined grossly for the presence of pneumonic lesions. There were no details available about age, sex, breed or husbandry conditions and all the animals were submitted for routine slaughter. Following gross examination, fifty lungs with pneumonia based on texture, exudation and distribution of lesions were selected for pathological, culture and molecular investigations. In addition, ten apparently normal lungs without any gross pathological lesions were considered as control.

### Histopathology

Appropriate samples of affected lungs were fixed in 10% neutral buffered formalin, routinely processed, and embedded in paraffin. Five-micron sections were prepared and stained with hematoxylin and eosin (H&E) for light microscopic examination.

### Culture

Samples of consolidated areas of selected pneumonic lungs were aseptically collected and placed in the transport medium containing PPLO broth (HiMedia, Hungary), horse serum 7% and yeast extract (Scharlau, Spain). Samples were kept for 2 days in refrigerator and

then transported on ice to the laboratory. The samples were diluted and filtered to the fresh PPLO broth containing PPLO broth 21 g/L, yeast extract 12 g/L, RPMI 50 ml/L, penicillin 4 ml 200000 U/ml and thallium acetate (Sigma-Aldrich) 10 ml (1 ml/L) and kept for 2 days at 37°C with 98% humidity.

Then samples were plated onto PPLO agar medium containing 36 g/L PPLO agar, PPLO broth 21 g/L, yeast extract 12 g/L, RPMI 50 ml/L, penicillin 4 ml 200000 U/ml, thallium acetate 10 ml (1 ml/L) and horse serum 150 ml/L. All media were incubated at 37°C in 50% CO<sub>2</sub> atmosphere with 98% humidity and observed for 3 to 14 days. The broth media were examined daily for any signs of *Mycoplasma* growth, including slight turbidity, swirls of growth, a change in pH, or opalescence. The agar media were examined for *Mycoplasma*-like colonies and typical "fried-egg" colonies using a microscope.

### DNA extraction

Two g of each tissue sample was homogenized and then DNA extraction was carried by HiPurA™ DNA Purification kit (HiMedia, Hungary).

Because of the difficulty in scraping off the *Mycoplasma* colony from the surface of agar, a piece of agar containing *Mycoplasma* colony was cultured again in the filtrated PPLO broth. The culture was also performed with a piece of same agar medium that was not cultivated, as negative control.

Filtrated PPLO broth containing *Mycoplasma* after growth as well as negative control media were centrifuged at 11200 g for 15 min. The supernatant was removed and discarded by aspiration. Five hundred µL of TE buffer was added to the previous step pellet. Five hundred µL of the suspension was transferred to 2.0 ml screw tap conical micro tube and boiled for 20 min, then 100 µL of the suspension was mixed with 100 µL chloroform slowly in a micro centrifuge tube and centrifuged at 11200 g for 5 min. Five µL of the supernatant was used for PCR amplification (Kilic *et al.*, 2013 with some modifications).

### PCR amplifications

All PCR amplifications were carried out in 25 µL reaction volume containing 15 µL of master mix (ampliqon), 1 µL of each primer (10 pmol/µL), 5 µL genomic DNA template, and 3 µL deionized water.

All reactions were run on a Bio-Rad T100 thermal cycler. Amplification and detection *Mycoplasma* genus were carried out by universal PCR primers of GPO-1 (5'-ACT CCT ACG GGA GGC AGC AGT A-3') and MGSO (5'-TGC ACC ATC TGT CAC TCT GTT AAC CTC-3') based on species specific sequence of *16S rRNA* gene (Kilic *et al.*, 2013).

The temperature protocol was as follows: after an initial denaturation step at 94°C for 3 min, 35 cycles were performed consisting of three steps: denaturation (94°C, 45 s), annealing (60°C, 30 s), and extension (72°C, 45 s) and final extension at 72°C for 5 min.

The primers of MAGF (5'-GCA TGG AAT CGC ATG ATT CCT-3') and GP4R (5'-GGT GTT CTT CCT

TAT ATC TAC GC-3') were species-specific for detection of *M. capricolum* subspecies *capripneumoniae* and *M. arginini*, respectively (Kilic *et al.*, 2013).

The temperature protocol was the same for both species as follows: after an initial denaturation step at 94°C for 3 min, 37 cycles were performed consisting of three steps: denaturation (94°C, 45 s), annealing (55°C, 30 s), extension (72°C, 45 s), and final extension at 72°C for 5 min.

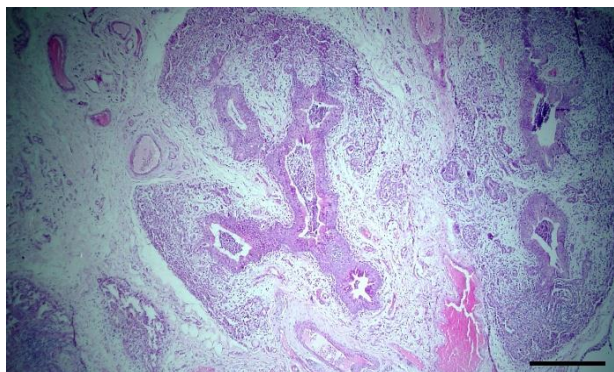
The fragment size of PCR products were 715, 316, and 545 bp for *Mycoplasma* genus, *M. capricolum* subspecies *capripneumoniae* and *M. arginini*, respectively.

The PCR products were run on 1.5% agarose gel and subjected to electrophoresis for about 2 h at 80 V. Then the bands of amplified fragments were visualized and photographed under UV transilluminator.

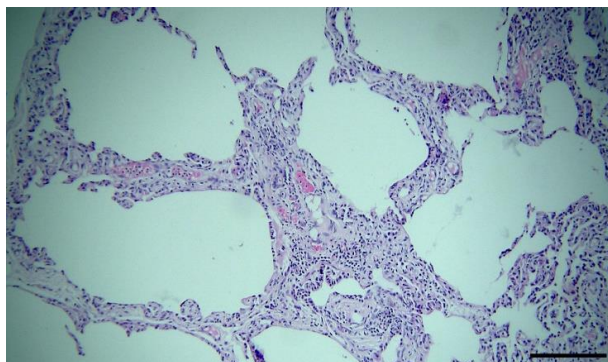
## Results

### Morphopathological findings

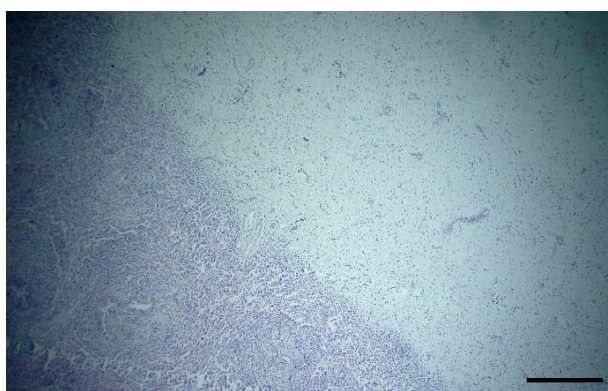
Gross examination of the affected lungs revealed consolidation and dark red to grey discoloration in the cranioventral to caudal lobes. In fibrinous bronchopneumonic cases, the lungs were firm, swollen, and covered with yellow fibrin. In the lungs with interstitial pneumonia, rubbery texture associated with rib impressions on the costal surfaces of the diaphragmatic lobes was observed. Histopathologic examination showed bronchointerstitial pneumonia in 40 goats (80%), and purulent to fibrinopurulent bronchopneumonia in 10 goats (20%). In fibrinopurulent bronchopneumonia, variable amounts of fibrin, neutrophils, and macrophages were observed in the bronchi, bronchioles, and alveoli associated with bronchus-associated lymphoid tissue (BALT) hyperplasia (Fig. 1). In bronchointerstitial pneumonia, thickening of alveolar septum mainly due to fibrosis and infiltration of lymphocytes and plasma cells were observed (Fig. 2). Thickening of pleura due to fibrin, fibrous connective tissue and infiltration of lymphocytes and plasma cells which indicate chronic pleuritis was present in some of the affected lungs (Fig. 3).



**Fig. 1:** Bronchointerstitial pneumonia: Thickened interstitial tissue between alveoli due to infiltration of mononuclear inflammatory cells and fibrous tissue, (H&E stain; scale bar, 50  $\mu$ m)



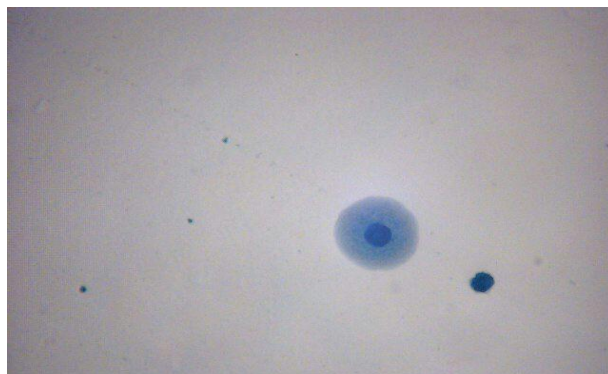
**Fig. 2:** Fibrinopurulent bronchopneumonia: Accumulation of exudate including neutrophils within affected bronchioles and alveoli associated with BALT hyperplasia around bronchioles are seen, (H&E stain; scale bar, 50  $\mu$ m)



**Fig. 3:** Thickening of pleura due to fibrin, fibrous connective tissue and infiltration of inflammatory cells showing chronic pleuritis, (H&E stain; scale bar, 50  $\mu$ m)

### Culture results

The evidence of *Mycoplasma* growth such as turbidity in the *Mycoplasma* broths and *Mycoplasma* colonies on the *Mycoplasma* agar plates was observed in 2 (4%) of tissue lung samples (Fig. 4).

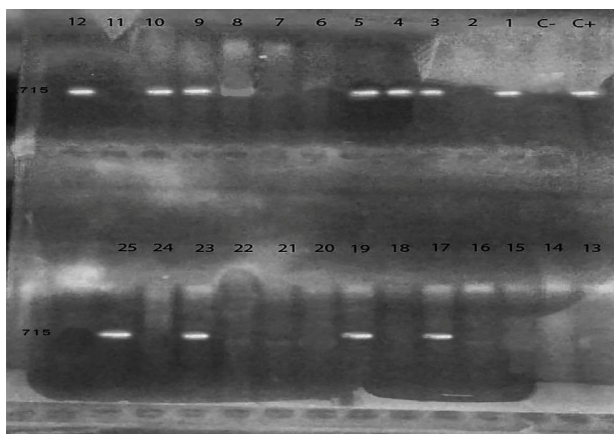


**Fig. 4:** Positive growth of *Mycoplasma* sp. colonies as typical fried-eggs after culture on agar media

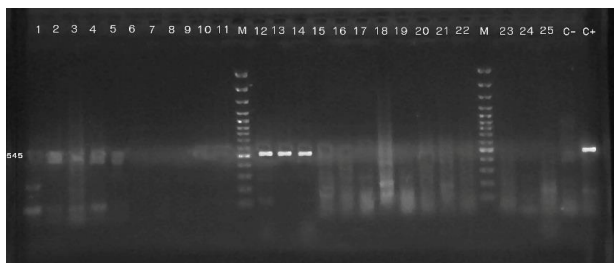
### Molecular findings

The lung samples were examined by PCR for finding *Mycoplasma* genus and 11 samples (22%) were positive (Fig. 5). Then, isolated DNA samples were tested to identify *M. capricolum* subspecies *capripneumoniae* and

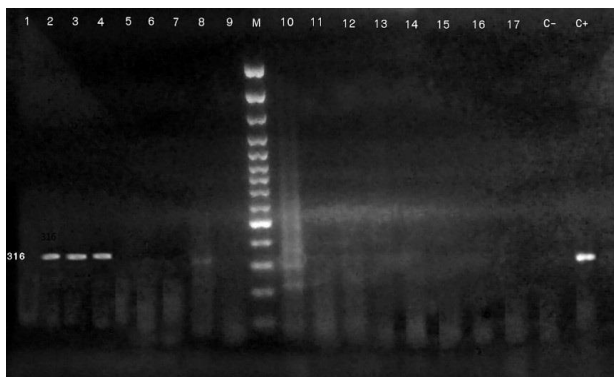*M. arginini* by PCR. The results showed that 3 goats (6%) were positive for *M. capricolum* subspecies *capripneumoniae* and 3 goats (6%) were positive for *M. arginini* (Figs. 6 and 7). All examined samples for *M. mycoides* subspecies *capri* and *M. capricolum* subspecies *capricolum* and *M. ovipneumoniae* were negative. Genomic DNA was purified from colonies of broth culture media, all of them were identified as *M. arginini*. None of the negative control culture media showed growth of *Mycoplasma* genus.



**Fig. 5:** *Mycoplasma* PCR genus electrophoresis analysis on %1.5 gel agarose. Lane C+: Positive control (715 bp band), Lane C-: Negative control, Lanes 1, 3-5, 9-10, 12, 17, 19, 23, and 25 are *Mycoplasma* spp. in goats



**Fig. 6:** *Mycoplasma capricolum* subsp. *capripneumoniae* PCR electrophoresis analysis on %1.5 gel agarose. M: Marker (100 bp DNA ladder). Lane C+: Positive control (316 bp band), Lane C-: Negative control, and Lanes 2 to 4 are positive samples



**Fig. 7:** *Mycoplasma arginini* PCR electrophoresis analysis on %1.5 gel agarose. M: Marker (100 bp DNA ladder). Lane C+: Positive control (545 bp band), Lane C-: Negative control, and Lanes 12 to 14 are positive samples

## Discussion

Mycoplasmas are slow growing microorganisms belonging to the class Mollicutes and do not have the genetic ability to produce a cell wall (Cremonesi *et al.*, 2007). Many species are veterinary pathogens causing respiratory infection, conjunctivitis, mastitis, arthritis, and occasionally abortion. Pneumonia and pleuropneumonia due to *Mycoplasma* infections can cause major health problems and economic losses in small ruminants industry (Amores *et al.*, 2010). *Mycoplasma pneumoniae* causes subtle and unnoticed clinical signs and infected animals have good appetites until severe damage due to secondary bacterial infections occurs. Several *Mycoplasma* species including *M. mycoides* subspecies *mycoides* LC, *M. capricolum* subspecies *capricolum*, *M. capricolum* subspecies *capripneumoniae* and *M. arginini* are isolated from caprine pneumonias (Adehan *et al.*, 2006; De la Fe *et al.*, 2007; Radostits *et al.*, 2007).

In the present study, two *Mycoplasma* species, *M. capricolum* subspecies *capripneumoniae* and *M. arginini* were identified from the pneumonic lung tissues of goats slaughtered at the abattoir in Northeastern Iran, by PCR technique. PCR method is an extremely sensitive and specific technique that allows direct detection of antigen and overcomes to cross reactions of conventional tests. In comparison to culture, PCR is a rapid, sensitive, and efficient method (Cremonesi *et al.*, 2007). In this investigation, positive culture was seen only in 4% (n=2/50) of samples while 22% (n=11/50) of samples were positive by PCR. The frequency of both *M. capricolum* subspecies *capripneumoniae* and *M. arginini* in pneumonic lungs of slaughtered goats were 6% (n=3/50). These organisms were isolated from lungs with fibrinopurulent bronchopneumonia and interstitial pneumonia. The observed histopathologic lesions were not pathognomonic for *Mycoplasma* that caused pneumonia in goats. It is believed that a primary infection with Mycoplasmas may predispose animals to invasion of the lower respiratory tract by other bacteria and viruses (Ruffin, 2001; Nicholas *et al.*, 2008).

*Mycoplasma capricolum* subspecies *capripneumoniae* is the etiologic agent of contagious caprine pleuropneumonia (CCPP), a severe, acute, and highly contagious respiratory condition, prevalent in many countries of Africa and Asia. The disease affects all ages and is characterized by high fever, high morbidity, and high mortality. Respiration is accelerated and painful, coughing is frequent, and, in the terminal stages, the animal is unable to move, standing base wide and neck extended. The gross lesions of the disease are typically limited to the thoracic cavity and characterized by fibrinous pleuropneumonia, lung consolidation, and accumulation of pleural fluid (Thiaucourt *et al.*, 1996). A high mortality outbreak of respiratory mycoplasmosis was reported in goats in Mexico (Hernandez *et al.*, 2006). These authors reported that clinicopathologic presentation of the disease resembled CCPP caused by *M. capricolum* subspecies *capripneumoniae*. By using a

battery of PCR assays, the *Mycoplasma* associated with this outbreak was identified as *M. mycoides* subspecies *capri* (Hernandez *et al.*, 2006). In a study to investigate the presence of CCPP in East Turkey, Çetinkaya *et al.* (2009) detected *M. capricolum* subspecies *capripneumoniae* (Mccp) in 37.5% (12/32) of lung samples from goats of ten different herds by culture and PCR. It has been reported that CCPP is one of the most important *Mycoplasma* diseases in Turkey (Ozdemir and Turkaslan, 2003; Ozdemir *et al.*, 2005; Çetinkaya *et al.*, 2009).

There are few reports that have described *M. ovipneumoniae* as a cause of severe respiratory disease in goats; but it is the most commonly isolated *Mycoplasma* from the respiratory tract of sheep often in association with *M. arginini* that may exacerbate disease signs (Ayling *et al.*, 2004; Ayling and Nicholas, 2007). Also, prevalence of *M. ovipneumoniae* in association with *Mannheimia haemolytica* has been reported in the lungs of lambs in Turkey and Italy (Hazirolu *et al.*, 1994; Ettorre *et al.*, 2007). Nicholas (2002) reported isolation of *M. ovipneumoniae*, *M. arginini*, and *Mannheimia haemolytica* from goats with a respiratory disease with high morbidity and mortality rates in United Kingdom. In a similar report, *M. ovipneumoniae*, *M. arginini*, *M. haemolytica*, and *Pasteurella multocida* have been detected in kids from a goat herd with severe respiratory signs and mortality rate of more than 20% in Portugal (Gonçalves *et al.*, 2010). *M. ovipneumoniae* facilitates lung consolidation by other organisms including *M. haemolytica*, which results in development of a more severe pathological damage (Ayling and Nicholas, 2007). Respiratory disease with isolation of *M. ovipneumoniae* is reported in goats from other countries including Nigeria, Sudan, and Spain (CABI, 2006; Gonçalves *et al.*, 2010).

Pathogenic *Mycoplasmas* have a predilection for the respiratory system, urogenital tract, mammary gland, and serous membranes. They adhere to epithelial cells and this adhesion is a prerequisite for colonization and pathogenesis (Smith, 2019). The mechanism of pathogenesis is not well understood and activation of the immune system of the host probably plays a major role in this regard (Radostits *et al.*, 2007). Certain predisposing factors are known to be required for the development of the disease such as age, gestation, parturition, crowd, and poor ventilation (Gutierrez *et al.*, 1999).

Fernandez *et al.* (2016) studied the presence of infection with *Mycoplasma* species including *M. ovipneumoniae* and *M. arginini* in association with lung consolidation, environmental temperature, and relative humidity in lambs in Spain and their results showed that higher temperatures and lower relative humidity favor the involvement of *Mycoplasma* species. *M. arginini* was associated with lung consolidation (Fernandez *et al.*, 2016). In England, *M. ovipneumoniae* has been detected with higher frequency in nasal swabs and lung samples of *Pasteurella*-vaccinated sheep with respiratory disease than small number of nasal swabs from animals with no

overt clinical signs (McAuliffe *et al.*, 2003). Hazirolu *et al.* (1994) reported 3.6% pneumonia among 13588 slaughtered lambs. *M. ovipneumoniae* was isolated from 43% and *M. hemolytica* from 51.6% of pneumonic cases while 26.2% of cases showed mixed infection by both organisms. In a study in Egypt, *M. arginini* was isolated from 35.29% of lung and nasal swab samples of goats (Ammar *et al.*, 2008).

In a slaughterhouse study on 40 pneumonic lungs of sheep in Southwest of Iran, *M. ovipneumoniae* (20%) and *M. arginini* (2.5%) were detected by PCR method (Azizi *et al.*, 2011). Valsala *et al.* (2017) studied the association of different mollicutes with caprine pneumonia. Based on biochemical and molecular tests for screening 244 caprine pneumonia lung samples in India, they identified prevalence of *M. arginini* as 5.3% and proposed that considerably higher prevalence of the organism in diseased lung samples signifies their probable role in the pathogenesis of pneumonia (Valsala *et al.*, 2017).

In conclusion, the results of this study showed that *M. capricolum* subspecies *capripneumoniae* and *M. arginini* can be involved in lung consolidation and pneumonia in goats.

## Acknowledgements

We thank School of Veterinary Medicine, Shiraz University for the support and also all the staff of the Bacteriology Department of Razi Vaccine and Serum Research Institute, Mashhad, Iran for their technical helps. This study was supported by a project of Shiraz University with the grant No. 95GCU2M1310.

## Conflict of interest

We declare that we have no conflict of interest.

## References

- Adehan, RK; Ajuwape, ATP; Adetosoye, AI and Alaka, OO (2006). Characterization of *Mycoplasmas* isolated from pneumonic lungs of sheep and goats. *Small Rumin. Res.*, 63: 44-49.
- Ammar, AM; Eissa, SI; El-Hamid, MIA; Ahmed, HA and Elaziz, AEE (2008). Advanced study on *Mycoplasmas* isolated from sheep. *Zag. Vet. J.*, 36: 128-137.
- Amores, J; Corrales, JC; Martin, AG; Sanchez, A and Conteras, A (2010). Comparison of culture and PCR to detect *Mycoplasma agalactiae* and *Mycoplasma mycoides* subsp. *capri* in ear swabs taken from goats. *Vet. Microbiol.*, 140: 105-108.
- Ayling, RD; Bashiruddin, SE and Nicholas, RAJ (2004). *Mycoplasma* species and related organisms isolated from ruminants in Britain between 1999 and 2000. *Vet. Rec.*, 155: 413-416.
- Ayling, RD and Nicholas, RAJ (2007). *Mycoplasma* respiratory infections. In: Aitken, ID (Ed.), *Diseases of sheep*. (4th Edn.), Moredun, Blackwell Publishing. PP: 231-235.
- Azizi, S; Tajbakhsh, E; Rezaii, SH; Nekouei, SH and

- Namjoo, AR** (2011). The role of *Mycoplasma ovipneumoniae* and *Mycoplasma arginini* in pneumonic lungs of slaughtered sheep. *Revue de Médecine Veterinaire*, 162: 310-315.
- CABI** (2006). Atypical non-progressive proliferative pneumonia. <http://www.cabicompendium.org/ahpc/report.asp> (accessed 18.05.07).
- Çetinkaya, B; Kalin, R; Karahan, M; Atil, E; Manso-Silvan, L and Thiaucourt, F** (2009). Detection of contagious caprine pleuropneumonia in East Turkey. *Rev. Sci. Tech.*, 28: 1037-1044.
- Cremonesi, P; Vimercati, C; Pisoni, G; Perez, G; Miranda Ribera, A; Castiglioni, A; Luzzana, B; Ruffo, M and Moroni, P** (2007). Development of DNA extraction and PCR amplification protocols for detection of *Mycoplasma bovis* directly from milk samples. *Vet. Res. Commun.*, (Suppl. 1), 31: 225-227.
- Daei, AA; Khodakaram-Tafti, A; Derakhshandeh, A and Seyedin, M** (2020). Identification of *Mycoplasma ovipneumoniae* and *Mycoplasma arginini* in sheep with pneumonia in North East of Iran. *Iranian J. Vet. Res.*, 21: 15-19.
- De la Fe, C; Gutierrez, A; Poveda, JB; Assunao, P; Ramirez, AS and Fabelo, F** (2007). First isolation of *Mycoplasma capricolum* subsp. *capricolum*, one of the causal agents of caprine contagious agalactia, on the island of Lanzarote (Spain). *Vet. J.*, 173: 440-442.
- Ettorre, C; Sacchini, F; Scacchia, M and Salda, LD** (2007). Pneumonia of lambs in the Abruzzo region of Italy: anatomopathological and histopathological studies and localisation of *Mycoplasma ovipneumoniae*. *Veterinaria Italiana*, 43: 149-155.
- Fernandez, S; Galapero, J; Rey, J; Perez, CJ; Ramos, A; Rosales, R; Ayling, R; Alonso, JM and Gomes, L** (2016). Investigations into the seasonal presence of *Mycoplasma* species in fattening lambs. *Vet. J.*, 212: 80-82.
- Gonalves, R; Mariano, I; Nunez, A; Branco, S; Fairfoul, G and Nicholas, R** (2010). Atypical non-progressive pneumonia in goats. *Vet. J.*, 183: 219-221.
- Goodwin, KA; Jackson, R; Brown, C; Davied, P; Morris, RS and Perkins, NR** (2004). Pneumonic lesions in lambs in New Zealand: Patterns of prevalence and effects on production. *N. Z. Vet. J.*, 52: 175-179.
- Gutierrez, C; Rodriguez, JL; Montoya, JA and Fernandez, A** (1999). Clinicopathological and haematological findings in goat kids experimentally infected simultaneously with *Mycoplasma mycoides* subsp. *capri* and *Mycoplasma mycoides* subsp. *mycoides* (large colony-type). *Small Rumin. Res.*, 31: 187-192.
- Haziroglu, R; Diker, KS; Gulbahar, MY; Akan, M and Guvenc, T** (1994). Studies of the pathology and microbiology of pneumonic lungs of lambs. *Deutsche Tierarztliche Wochenschrift*, 101: 441-443.
- Hernandez, L; Lopez, J; St-Jacques, M; Ontiveros, L; Acosta, J and Handel, K** (2006). *Mycoplasma mycoides* subsp. *capri* associated with goat respiratory disease and high flock mortality. *Can. Vet. J.*, 47: 366-369.
- Kilic, A; Kalender, H; Eroksuz, H; Muz, A and Tasdemir, B** (2013). Identification by culture, PCR, and immunohistochemistry of mycoplasmas and their molecular typing in sheep and lamb lungs with pneumonia in Eastern Turkey. *Trop. Anim. Health Prod.*, 45: 1525-1531. doi: 10.1007/s11250-013-0394-3.
- Lopez, A and Martinson, SA** (2022). Respiratory system, thoracic cavities, mediastinum, and pleura. In: Zachary, JF (Ed.), *Pathologic basis of veterinary disease*. (7th Edn.), Elsevier Inc., PP: 579-591.
- McAuliffe, L; Hatchell, FM; Ayling, RD; King, AI and Nicholas, RA** (2003). Detection of *Mycoplasma ovipneumoniae* in *Pasteurella*-vaccinated sheep flocks with respiratory disease in England. *Vet. Rec.*, 153: 687-688.
- Nicholas, RAJ** (2002). Improvements in the diagnosis and control of diseases of small ruminants caused by *Mycoplasmas*. *Small Rumin. Res.*, 45: 145-149.
- Nicholas, RAJ; Ayling, RD and McAuliffe, L** (2008). *Mycoplasma* diseases of ruminants. *Small Rumin. Res.*, 76: 98-114. doi: 10.1079/9780851990125.0000.
- Ozdemir, U; Ozdemir, E; March, JB; Churchward, C and Nicholas, RA** (2005). Contagious caprine pleuropneumonia in the Thrace region of Turkey. *Vet. Rec.*, 156: 286-287.
- Ozdemir, U and Turkaslan, J** (2003). *Mycoplasma* strains isolated from contagious agalactia outbreaks. *Pendik Vet. Mikrobiol. Derg.*, 34: 33-35.
- Radostits, OM; Gay, CC; Hinchcliff, KW and Constable, PD** (2007). *Veterinary medicine, A textbook of the disease of cattle, horses, sheep, pigs and goats*. 10th Edn., USA, Saunders. PP: 950-995.
- Ruffin, DC** (2001). *Mycoplasma* infections in small ruminants. *Vet. Clin. North Am. Food. Anim. Pract.*, 17: 315-332.
- Semmate, N; Zouagui, Z; Elkarhat, Z; Bamouh, Z; Fellahi, S and Tlgui, N** (2022). Molecular characterization and pathogenicity of *Mycoplasma capricolum* subsp. *capricolum* from goats in Morocco. *Anim. Dis.*, 2: 12.
- Smith, BP; Van Metre, DC and Pusterla, N** (2019). *Large animal internal medicine*. 6th Edn., United States, Mosby Elsevier. PP: 645-698.
- Thiaucourt, F and Bolske, G** (1996). Contagious caprine pleuropneumonia and other pulmonary mycoplasmoses of sheep and goats. *Rev. Sci. Tech.*, 15: 1397-1414.
- Thiaucourt, F; Bolske, G; Leneguersh, B; Smith, D and Wesonga, H** (1996). Diagnosis and control of contagious caprine pleuropneumonia. *Rev. Sci. Tech.*, 15: 1415-1429.
- Valsala, R; Rajneesh, R; Remesh, AT and Singh, VP** (2017). *Mycoplasma arginini*: high frequency involvement in goat pneumonia. *Turkish J. Vet. Anim. Sci.*, 41: 393-399.