

Review

Kamran Harati* and Marcus Lehnhardt

The changing paradigm of resection margins in sarcoma resection

<https://doi.org/10.1515/iss-2017-0043>

Received November 2, 2017; accepted November 20, 2017; previously published online December 6, 2017

Abstract: Soft tissue sarcomas (STS) are a heterogeneous group of rare mesenchymal tumors that account for approximately 1% of all adult malignancies. They can arise throughout the body due to their mesenchymal origin, although 60% of all STS occur in the extremities. Locally advanced STS can lead to significant functional morbidity and tend to local recurrences despite surgical resection. About 30% of all STS patients develop distant metastases with a median overall survival of less than 15 months. The treatment of choice in patients with localized disease is still surgical resection with negative margins. However, there has been a paradigm shift in the last few decades. Large retrospective analyses could not establish a strong association between radical resections and improved local control or survival. Previous radical concepts in STS surgery have been gradually replaced by more moderate approaches with function- and limb-sparing resections combined with radiotherapy. Here, the margin status appears to be of prognostic significance. However, several large retrospective analyses have presented inconsistent results, questioning the independent prognostic impact of surgical margins. This article reviews the literature critically, focusing on the changing role of surgical margins in STS surgery.

Keywords: margins; recurrence; soft tissue sarcoma; survival; width.

Introduction

Soft tissue sarcomas (STS) are rare mesenchymal tumors that account for approximately 1% of all adult

malignancies [1]. There is an incidence of two to four new cases of STS per 100,000 people per year in Europe [2, 3]. If all STS subtypes are taken into account, the peak age for the development of STS is between 60 and 65 years [4]. Because of their mesenchymal origin, STS can arise throughout the body. About 60% of all STS develop in the extremities, while 30% arise in the trunk, particularly retroperitoneal, and 10% in the head and neck area [5–7].

The STS are a very heterogeneous group of solid malignancies consisting of more than 50 histologic subtypes [8]. The heterogeneity is not only exhibited by their different phenotypes but also in their different clinical behaviors [8, 9]. Several subtypes, such as angiosarcomas and somatic leiomyosarcomas, are associated with high rates of local recurrence and distant metastases, while other entities, such as myxofibrosarcomas or dermatofibrosarcoma protuberans, rarely metastasize, although they are very aggressive locally [10–13]. The most frequent, adult STS were gastrointestinal stroma tumors, liposarcomas, not otherwise specified sarcomas, and leiomyosarcomas [3, 4]. However, the heterogeneity and rarity of STS pose epidemiological challenges, and the data available regarding the frequencies have been inconsistent.

Somatic STS of the extremities and the truncal wall emerge as indolent, palpable tumors. Patients with STS usually have no B symptoms. Skin reactions, pain, or palsies appear only in advanced disease stages where the tumors extrude or infiltrate the skin or the nerves. Most STS subtypes metastasize systemically into the lungs. Lymph node metastases are only rare and restricted to certain subtypes, such as epithelioid or clear-cell sarcomas. About 30% of all STS patients develop distant metastases of the lungs [5, 14]. The median overall survival after diagnosis of distant metastasis is less than 15 months despite chemotherapy [14]. To date, there have been several analyses of the prognostic factors influencing the survival in patients with STS. Among these factors, histological grade, tumor size, depth, and histological subtype are considered the most significant [5, 6, 15–24].

The standard treatment in patients with localized STS has always been complete surgical resection. However, there has been a paradigm shift in the last few decades

*Corresponding author: Dr. Kamran Harati, Department of Plastic Surgery, BG-University Hospital Bergmannsheil, Buerkle-de-la-Camp-Platz 1, Bochum D-44789, Germany, Phone: +49 234 302 3445, Fax: +49 234 6379, E-mail: kamran.harati@t-online.de

Marcus Lehnhardt: Department of Plastic Surgery, BG-University Hospital Bergmannsheil, Bochum, Germany

supporting a less radical approach with more limb- and function-sparing resections. Large retrospective analyses could not establish an association between radical resections and improved local control or survival. In this article, we give an overview of the most important studies regarding the role of surgical margins in STS.

Previous concepts of sarcoma surgery

The treatment of STS is conducted in an interdisciplinary setting. Surgery, radiotherapy, and chemotherapy are part of the multimodal treatment. The treatment of choice in patients with localized STS without distant metastases involves surgical resection with microscopically negative margins (R0 resection). In theory, the resection should remove all tumor cells that could potentially develop local recurrences or metastases.

In the 1980s, Enneking et al. presented their concept of safe sarcoma resections to minimize the risk of local failures [25, 26]. Their concept was based on the theory that the pseudocapsule of sarcomas would be surrounded by a reactive zone that might contain tumor cells. Thus, resections through this layer were defined as marginal resections, leaving both potential microscopic satellites in the reactive zone and skip lesions in the surrounding normal tissues. Furthermore, they also defined wide and radical resections. Wide resections involved the whole reactive zone, but would leave skip lesions in the remaining compartment. Finally, the radical resections encompassed whole compartments, including the surrounding fascia sheaths. Although the authors generally preferred non-ablative procedures, they recommended radical resections for high-grade sarcomas that often resulted in amputations or function losses. However, this radical approach was based on their own findings and could

not be reproduced by subsequent studies. In the following decades, first treatment centers began to perform limb-sparing resections combined with adjuvant radiotherapy preferably and could demonstrate that amputation, indeed, led to a better local control, but did not improve survival [27, 28]. Finally, patients who underwent limb-sparing resections had a similar overall survival rate. Nonetheless, the question remained which surgical margin width would be the best to reduce local failure and disease-related death if limb-sparing surgery was feasible.

The changing role of the surgical margin widths

The lack of clear definitions in sarcoma surgery impeded the validity and comparability of retrospective analyses on resection margins. Although the definitions by Enneking et al. were used throughout many tertiary centers for decades, they were not exact enough. The layer of the reactive zone was not defined clearly, and therefore, marginal and wide resections could not be differentiated exactly. Different centers used different definitions for marginal and wide margins [29, 30]. One large center even classified clear margins ≤ 1 mm as positive margins (R1 resection) [18]. Hence, the data and the survival analyses of the different centers could not be compared without problems. Most of the studies provided information about the microscopic margin status (R0 vs. R1), but did not assess the negative margin widths quantitatively within the histologic specimen and did not provide information about the quality of the margins (e.g. fascia, periosteum, fat).

In 2004, McKee et al. [31] were one of the first who assessed negative margin widths quantitatively in 111 patients after R0 resections. In their multivariate analysis, negative margins ≥ 10 mm were associated with a better local control than close negative margins

Table 1: Overview of retrospective analyses on surgical margin widths in STS.

Author (year)	n	Prognostic effect of negative surgical margin width on		Conclusion
		LRFS	OS	
McKee (2004)	111	+	–	<10 mm clear margin suggested
Dickinson (2006)	279	+	–	<1 mm clear margin suggested
Kainhofer (2016)	265	+	–	<1 mm clear margin suggested
Ahmad (2016)	235	–	–	Close clear margins adequate
Harati (2017)	590	–	–	Close clear margins adequate

LRFS, Local recurrence-free survival; OS, overall survival.

(<10 mm). However, wide negative margins did not lead to a better overall survival (Table 1). Finally, the authors recommended a safety margin of ≥ 10 mm in the histologic specimen to minimize the risk of local failure. Two years later, Dickinson et al. [32] presented a retrospective analysis involving 279 patients with localized STS. Similar to the findings of McKee et al., negative margin widths did not affect survival, but influenced local control rates. However, negative margin widths >1 mm were found to be adequate to improve local control in the analysis of Dickinson et al. A similar observation was also made by Kainhofer et al. [33] analyzing 265 patients with localized STS of the extremities and the truncal wall. Here, patients with negative margins <1 mm had a slightly higher local recurrence rate than patients with negative margins ≥ 1 mm.

In 2016, Ahmad et al. [34] presented a retrospective study in which they determined the prognostic significance of quantitatively assessed clear margin widths in 235 patients undergoing limb-sparing surgery and pre- or postoperative radiotherapy for extremity and truncal wall STS. They categorized the negative margin widths as ≤ 1 mm, 1–5 mm, and >5 mm. Here, all three subgroups had the same outcome regarding local control and overall survival. Thus, the question remained whether surgical margin widths had an impact on patients who did not undergo radiotherapy. A recently published retrospective study of 590 patients with R0 resected extremity STS showed that the negative margin width attained did not alter local control, disease-specific or metastasis-free survival regardless of whether adjuvant radiation was applied or not [35]. In line with the findings of Ahmad et al., negative margin widths <1 mm had a similar favorable outcome when compared with wider margins. Subsequently, the authors concluded, based on their retrospective findings, that clear margins can be close, as long as the tumor is R0 resected.

The controversial role of the margin status

Interestingly, the controversial debates are not only restricted to the margin widths. There are still issues about the prognostic significance of margins, generally. The discussions are ongoing whether an R0 resection is an independent factor that influences survival, itself, or only a factor that is dependent on tumor-related aspects, such as grade, size, and depth, that might ultimately dictate the outcome. Subsequently, an R0 resection – or R0 resectability – would be only an indicator for a less aggressive tumor biology. Several authors believe that tumors, which can only be resected with R1 or R2 margins, have not only a more aggressive growth pattern but also a higher potential to metastasize [5, 16, 18, 36]. Positive margin status would, therefore, be rather a result of aggressive tumor biology and would not dictate the outcome by itself. To date, there have been several retrospective analyses that assessed the prognostic significance of the surgical margin status. Unfortunately, the large sarcoma centers have presented inconsistent results (Table 2). The Memorial Sloan-Kettering Center in New York has published the largest series of STS patients and could establish an association between the margin status and survival [6, 19]. Microscopic negative margins emerged as an independent prognostic factor for better local control and disease-specific survival in patients with STS of all sites. Although the results of the Memorial Sloan-Kettering Center were significant, other large centers presented contradictory findings. Eilber et al. [17] from the University of California Los Angeles analyzed 753 patients with extremity STS and did not find an association between margin status and survival. Similarly, the Istituto Nazionale dei Tumori in Milan presented the data of 911 patients with extremity STS and could not establish a strong association between margins and survival [18].

Table 2: Overview of retrospective analyses on surgical margin status and STS.

Author (year)	n	Time period	Median FU (years)	5-LRFS (%)	5-DSS (%)	Independent prognostic effect of margins on		
						LRFS	DSS (or OS)	MFS
Pisters (1996)	1041	1982–1994	4.0	79	75	+	+	–
Eilber (2002)	753	1975–1997	8.2	88	70 ^a	–	–	NA
Zagars (2003)	1225	1960–1999	9.5	83	73	+	+	–
Gronchi (2005)	911	1980–2000	8.9	83	76	+	–	–
Bonvalot (2016)	532	1993–2012	7.0	92	80 ^b	+	–	–
Harati (2017)	643	1996–2016	4.6	65	85	+	+	+

FU, Follow-up; 5-LRFS, local recurrence-free survival rate at 5 years; 5-DSS, disease-specific survival at 5 years; OS, overall survival; MFS, metastasis-free survival; NA, data not available. ^aValue for 5-year OS.

Comparable findings were made by the Scandinavian Sarcoma Group after the analysis of 559 patients [16]. In 2016, Bonvalot et al. [23] determined the prognostic significance of surgical margins in 531 patients with extremity STS and could only find a prognostic impact on the local control, but not on survival. However, R0 margins were an independent prognostic factor for local control, disease-specific survival, and metastasis-free survival in our own series with 643 extremity STS patients [35]. Finally, differences in the patient, tumor, and treatment characteristics of the reporting centers might explain the discrepant

results to a certain degree, but the exact reasons remain unclear.

Surgical decision-making in borderline cases

The controversial prognostic significance of surgical margins poses challenges in the surgical treatment of advanced intermediate- and high-grade tumors (Figure 1).

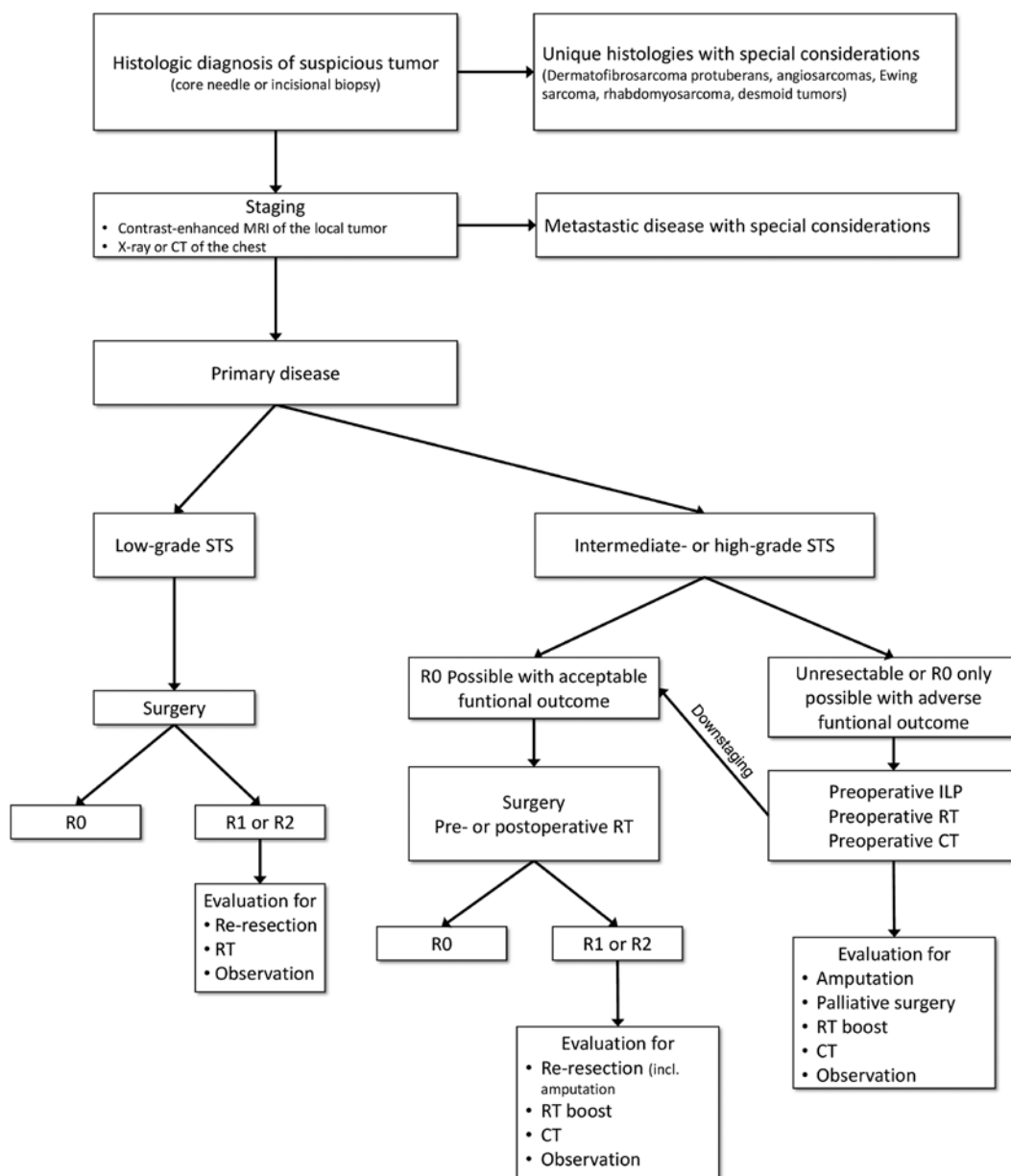


Figure 1: Algorithm for the treatment of non-intraabdominal STS. The histologic grades refer to the grading system of the French Federation of Cancer Centers. RT, Radiotherapy; CT, chemotherapy.

In contrast to strictly patient- and tumor-related factors, the margin status is apparently a factor, which can be influenced to a certain degree by the surgeon. Surgical decision-making gets problematic in locally advanced tumors when neoadjuvant treatment modalities fail, and an R0 resection requires a drastic functional impairment or even an amputation. Such radical approaches should be critically evaluated in patients with simultaneous distant metastases that cannot be resected surgically. Local control should be achieved by radiation, chemotherapy, or surgical debulking, as recommended by the current National Comprehensive Cancer Network guidelines [37]. If the patients respond to systemic chemotherapy, or the metastases are surgically removable, then, a curative R0 resection of the local tumor can be reasonable.

The surgical intent in young patients with locally advanced high-grade tumors and no simultaneous metastases is clearly curative and would prefer an R0 resection at all costs rather than a planned incomplete resection. However, such a radical surgical approach cannot be justified by the data available. Several studies could not find a survival benefit in patients where localized STS were completely removed with negative margins by an amputation [38–42]. They concluded that tumors that could only be resected completely through an amputation had more aggressive biological features and might have metastasized before the amputation. However, such surgical decisions cannot be based on retrospective analyses. As long as the patient has no detectable metastases, the treatment should aim at negative margins in curative intent. When the goal of achieving clear surgical margins requires amputation or major functional impairment of the extremity, the decision should ultimately be made in each case based on the biology of the STS, the health status of the patient, and the decision of the informed patient.

Summary

There have been several large studies that analyzed the prognostic significance of surgical margins. Unfortunately, they presented inconsistent results questioning the prognostic impact of the quality of surgery. The biology of the tumor might ultimately dictate the outcome; however, given the diminished outcome of patients left with positive margins, surgical efforts should aim to achieve microscopically clear margins whenever feasible. Here, only the quality of surgical margins and not the negative margin width attained appears to have an influence on survival. A radical surgical approach with the goal of wide negative margins cannot be justified by the current data.

Author Statement

Research funding: Authors state no funding involved. Conflict of interest: Authors state no conflict of interest. Informed consent: Informed consent is not applicable. Ethical approval: The conducted research is not related to either human or animal use.

Author Contributions

Kamran Harati: Conceptualization; data curation; formal analysis; writing – original draft. Marcus Lehnhardt: Supervision; validation; writing – original draft; writing – review and editing.

References

- [1] Jemal A, Siegel R, Ward E, et al. Cancer statistics, 2007. *CA Cancer J Clin* 2007;57:43–66.
- [2] Mastrangelo G, Coindre JM, Ducimetiere F, et al. Incidence of soft tissue sarcoma and beyond: a population-based prospective study in 3 European regions. *Cancer* 2012;118:5339–48.
- [3] Wibmer C, Leithner A, Zielonke N, Sperl M, Windhager R. Increasing incidence rates of soft tissue sarcomas? A population-based epidemiologic study and literature review. *Ann Oncol* 2010;21:1106–11.
- [4] Goldblum JR, Weiss SW, Folpe AL. *Enzinger and Weiss's Soft Tissue Tumors*. 6th ed. Ontario: Elsevier Canada; 2014.
- [5] Zagars GK, Ballo MT, Pisters PW, et al. Prognostic factors for patients with localized soft-tissue sarcoma treated with conservation surgery and radiation therapy: an analysis of 1225 patients. *Cancer* 2003;97:2530–43.
- [6] Stojadinovic A, Leung DH, Hoos A, et al. Analysis of the prognostic significance of microscopic margins in 2,084 localized primary adult soft tissue sarcomas. *Ann Surg* 2002;235:424–34.
- [7] Fernebro J, Bladstrom A, Rydholm A, et al. Increased risk of malignancies in a population-based study of 818 soft-tissue sarcoma patients. *Br J Cancer* 2006;95:986–90.
- [8] Fletcher CD. The evolving classification of soft tissue tumours – an update based on the new 2013 WHO classification. *Histopathology* 2014;64:2–11.
- [9] Coindre JM, Terrier P, Guillou L, et al. Predictive value of grade for metastasis development in the main histologic types of adult soft tissue sarcomas: a study of 1240 patients from the French Federation of Cancer Centers Sarcoma Group. *Cancer* 2001;91:1914–26.
- [10] Harati K, Daigeler A, Lange K, et al. Somatic leiomyosarcoma of the soft tissues: a single-institutional analysis of factors predictive of survival in 164 patients. *World J Surg* 2017;41:1534–41.
- [11] Harati K, Daigeler A, Goertz O, et al. Primary and secondary soft tissue angiosarcomas: prognostic significance of surgical margins in 43 patients. *Anticancer Res* 2016;36:4321–8.
- [12] Fiore M, Miceli R, Mussi C, et al. Dermatofibrosarcoma protuberans treated at a single institution: a surgical disease with a high cure rate. *J Clin Oncol* 2005;23:7669–75.

- [13] Sanfilippo R, Miceli R, Grosso F, et al. Myxofibrosarcoma: prognostic factors and survival in a series of patients treated at a single institution. *Ann Surg Oncol* 2011;18:720–5.
- [14] Billingsley KG, Burt ME, Jara E, et al. Pulmonary metastases from soft tissue sarcoma: analysis of patterns of diseases and postmetastasis survival. *Ann Surg* 1999;229:602–10; discussion 10–2.
- [15] Novais EN, Demiralp B, Alderete J, et al. Do surgical margin and local recurrence influence survival in soft tissue sarcomas? *Clin Orthop Relat Res* 2010;468:3003–11.
- [16] Trovik CS, Bauer HC, Alvegard TA, et al. Surgical margins, local recurrence and metastasis in soft tissue sarcomas: 559 surgically-treated patients from the Scandinavian Sarcoma Group Register. *Eur J Cancer* 2000;36:710–6.
- [17] Eilber FC, Rosen G, Nelson SD, et al. High-grade extremity soft tissue sarcomas: factors predictive of local recurrence and its effect on morbidity and mortality. *Ann Surg* 2003;237:218–26.
- [18] Gronchi A, Casali PG, Mariani L, et al. Status of surgical margins and prognosis in adult soft tissue sarcomas of the extremities: a series of patients treated at a single institution. *J Clin Oncol* 2005;23:96–104.
- [19] Pisters PW, Leung DH, Woodruff J, Shi W, Brennan MF. Analysis of prognostic factors in 1,041 patients with localized soft tissue sarcomas of the extremities. *J Clin Oncol* 1996;14:1679–89.
- [20] Lewis JJ, Leung D, Casper ES, et al. Multifactorial analysis of long-term follow-up (more than 5 years) of primary extremity sarcoma. *Arch Surg* 1999;134:190–4.
- [21] Potter BK, Hwang PF, Forsberg JA, et al. Impact of margin status and local recurrence on soft-tissue sarcoma outcomes. *J Bone Joint Surg Am* 2013;95:e151.
- [22] Willeumier J, Fiocco M, Nout R, et al. High-grade soft tissue sarcomas of the extremities: surgical margins influence only local recurrence not overall survival. *Int Orthop* 2015;39: 935–41.
- [23] Bonvalot S, Levy A, Terrier P, et al. Primary extremity soft tissue sarcomas: does local control impact survival? *Ann Surg Oncol* 2016;24:194–201.
- [24] Gronchi A, Lo Vullo S, Colombo C, et al. Extremity soft tissue sarcoma in a series of patients treated at a single institution: local control directly impacts survival. *Ann Surg* 2010;251: 506–11.
- [25] Enneking WF, Spanier SS, Malawer MM. The effect of the anatomic setting on the results of surgical procedures for soft parts sarcoma of the thigh. *Cancer* 1981;47:1005–22.
- [26] Grimer RJ. On the effect of setting of a positive surgical margin in soft tissue sarcoma. *Cancer* 2014;120:2803–5.
- [27] Rosenberg SA, Tepper J, Glatstein E, et al. The treatment of soft-tissue sarcomas of the extremities: prospective randomized evaluations of (1) limb-sparing surgery plus radiation therapy compared with amputation and (2) the role of adjuvant chemotherapy. *Ann Surg* 1982;196:305–15.
- [28] Williard WC, Hajdu SI, Casper ES, Brennan MF. Comparison of amputation with limb-sparing operations for adult soft tissue sarcoma of the extremity. *Ann Surg* 1992;215:269–75.
- [29] Reilly JJ, Goodgame JT, Jones DC, Brennan MF. DNA synthesis in rat sarcoma and liver: the effect of starvation. *J Surg Res* 1977;22:281–6.
- [30] Gross JL, Younes RN, Haddad FJ, et al. Soft-tissue sarcomas of the chest wall: prognostic factors. *Chest* 2005;127:902–8.
- [31] McKee MD, Liu DF, Brooks JJ, et al. The prognostic significance of margin width for extremity and trunk sarcoma. *J Surg Oncol* 2004;85:68–76.
- [32] Dickinson IC, Whitwell DJ, Battistuta D, et al. Surgical margin and its influence on survival in soft tissue sarcoma. *ANZ J Surg* 2006;76:104–9.
- [33] Kainhofer V, Smolle MA, Szkandera J, et al. The width of resection margins influences local recurrence in soft tissue sarcoma patients. *Eur J Surg Oncol* 2016;42:899–906.
- [34] Ahmad R, Jacobson A, Hornicek F, et al. The width of the surgical margin does not influence outcomes in extremity and truncal soft tissue sarcoma treated with radiotherapy. *Oncologist* 2016;21:1269–76.
- [35] Harati K, Goertz O, Pieper A, et al. Soft tissue sarcomas of the extremities: surgical margins can be close as long as the resected tumor has no ink on it. *Oncologist* 2017;22:1400–10.
- [36] Trovik CS, Skjeldal S, Bauer H, Rydholm A, Jepsen N. Reliability of margin assessment after surgery for extremity soft tissue sarcoma: the SSG experience. *Sarcoma* 2012;2012:290698.
- [37] von Mehren M, Randall RL, Benjamin RS, et al. Soft tissue sarcoma, version 2.2016, NCCN Clinical Practice Guidelines in Oncology. *J Natl Compr Canc Netw* 2016;14:758–86.
- [38] Lin PP, Guzel VB, Pisters PW, et al. Surgical management of soft tissue sarcomas of the hand and foot. *Cancer* 2002;95:852–61.
- [39] Brennan MF. Lessons learned from the study of soft tissue sarcoma. *Int J Surg* 2013;11(Suppl 1):8–10.
- [40] Stojadinovic A, Jaques DP, Leung DH, Healey JH, Brennan MF. Amputation for recurrent soft tissue sarcoma of the extremity: indications and outcome. *Ann Surg Oncol* 2001;8:509–18.
- [41] Tanabe KK, Pollock RE, Ellis LM, et al. Influence of surgical margins on outcome in patients with preoperatively irradiated extremity soft tissue sarcomas. *Cancer* 1994;73:1652–9.
- [42] Williard WC, Collin C, Casper ES, Hajdu SI, Brennan MF. The changing role of amputation for soft tissue sarcoma of the extremity in adults. *Surg Gynecol Obstet* 1992;175:389–96.

Supplemental Material: The article (<https://doi.org/10.1515/iss-2017-0043>) offers reviewer assessments as supplementary material.



Reviewer Assessment

Kamran Harati* and Marcus Lehnhardt

The changing paradigm of resection margins in sarcoma resection

<https://doi.org/10.1515/iss-2017-0043>

Received November 2, 2017; accepted November 20, 2017

***Corresponding author: Dr. Kamran Harati**, Department of Plastic Surgery, BG-University Hospital Bergmannsheil, Buerkle-de-la-Camp-Platz 1, Bochum D-44789, Germany, Phone: +49 234 302 3445, Fax: +49 234 6379, E-mail: kamran.harati@t-online.de

Reviewers' Comments to Original Submission

Reviewer 1: Christiane Bruns

Nov 14, 2017

Reviewer Recommendation Term:	Accept
Overall Reviewer Manuscript Rating:	80
Custom Review Questions	Response
Is the subject area appropriate for you?	5 - High/Yes
Does the title clearly reflect the paper's content?	5 - High/Yes
Does the abstract clearly reflect the paper's content?	5 - High/Yes
Do the keywords clearly reflect the paper's content?	5 - High/Yes
Does the introduction present the problem clearly?	5 - High/Yes
Are the results/conclusions justified?	5 - High/Yes
How comprehensive and up-to-date is the subject matter presented?	5 - High/Yes
How adequate is the data presentation?	5 - High/Yes
Are units and terminology used correctly?	5 - High/Yes
Is the number of cases adequate?	5 - High/Yes
Are the experimental methods/clinical studies adequate?	5 - High/Yes
Is the length appropriate in relation to the content?	5 - High/Yes
Does the reader get new insights from the article?	4
Please rate the practical significance.	5 - High/Yes
Please rate the accuracy of methods.	5 - High/Yes
Please rate the statistical evaluation and quality control.	5 - High/Yes
Please rate the appropriateness of the figures and tables.	5 - High/Yes
Please rate the appropriateness of the references.	5 - High/Yes
Please evaluate the writing style and use of language.	5 - High/Yes
Please judge the overall scientific quality of the manuscript.	4
Are you willing to review the revision of this manuscript?	Yes

Comments to Authors:

This is a comprehensive review, which focuses a highly relevant, yet not completely understood subject. The authors include all relevant publications of the last 25 years into their analysis. Methodology and conclusions are consistent. We have no objections and recommend accepting this review article for publication.

Reviewer 2: anonymous

Nov 20, 2017

Reviewer Recommendation Term:	Accept
Overall Reviewer Manuscript Rating:	90
Custom Review Questions	Response
Is the subject area appropriate for you?	5 - High/Yes
Does the title clearly reflect the paper's content?	5 - High/Yes
Does the abstract clearly reflect the paper's content?	5 - High/Yes
Do the keywords clearly reflect the paper's content?	5 - High/Yes
Does the introduction present the problem clearly?	4
Are the results/conclusions justified?	4
How comprehensive and up-to-date is the subject matter presented?	5 - High/Yes
How adequate is the data presentation?	4
Are units and terminology used correctly?	5 - High/Yes
Is the number of cases adequate?	N/A
Are the experimental methods/clinical studies adequate?	N/A
Is the length appropriate in relation to the content?	5 - High/Yes
Does the reader get new insights from the article?	4
Please rate the practical significance.	4
Please rate the accuracy of methods.	N/A
Please rate the statistical evaluation and quality control.	N/A
Please rate the appropriateness of the figures and tables.	5 - High/Yes
Please rate the appropriateness of the references.	5 - High/Yes
Please evaluate the writing style and use of language.	5 - High/Yes
Please judge the overall scientific quality of the manuscript.	4
Are you willing to review the revision of this manuscript?	Yes

Comments to Authors:

The article gives an excellent overview on the challenging surgical aspects of soft tissue sarcomas. The paper is well written and reflects nicely all relevant publications. I have no concern that it is published as submitted.
