

Recurrent Cervical Spinal Epidural Hematoma: Case Report and Literature Review

Daijiro Morimoto,¹ Kyongsong Kim,² Asami Kubota,¹ Rinko Kokubo,² Naotaka Iwamoto,¹ Yujiro Hattori,¹ and Akio Morita¹

Spinal epidural hematoma (SEDH) is an uncommon pathology. Here, we report a case of SEDH with recurrences, along with a literature review of relevant cases to identify characteristics of SEDH recurrence. A 13-year-old girl experienced sudden-onset of back pain and bilateral leg weakness. She was diagnosed with a cervical idiopathic epidural hematoma, and the symptoms subsided with conservative management. Four months after the event, she again experienced back pain due to recurrence of the cervical epidural hematoma, but she was observed because no neurological deficits could be detected. Fifteen months after the initial SEDH, she experienced severe back pain and tetra-paresis due to recurrence. The SEDH was located in the left ventral and dorsal aspect at the C6–T1 level, with severe spinal cord compression. The hematoma was removed through left hemilaminectomy. Bleeding was noted from the epidural venous plexus along the left C6 spinal root, which had coagulated. After hematoma resection, her symptoms gradually improved, and she was discharged 3 weeks after surgery without any neurological deficits. No hematoma recurrence has since been experienced. Recurrent SEDH is relatively rare, with only 11 cases previously reported. Recurrent hematoma cases are more common in young, female patients, while SEDH, in general, is more common in males in their late forties. The recurrence interval is shorter in non-surgical cases than those requiring surgery. Knowledge of these characteristics may be useful in the future management of SEDH.

Keywords: spinal epidural hematoma, recurrence, surgical treatment, back pain

Introduction

Idiopathic spinal epidural hematoma (SEDH) is an infrequent pathology. It occurs suddenly, and results in severe neurological symptoms that can be effectively treated with precise surgery. In some cases, SEDH produces only mild symptoms and observation alone may be adequate.^{1–3)} The recurrence of SEDH is relatively rare, but it is the main concern

in the follow-up period. However, the details regarding recurrence are unclear, with very few reports in the literature. Here, we report a case of repeated recurrence of SEDH and analyze the features of SEDH recurrence based on previous studies.

Case Report

A 13-year-old female with no significant medical history experienced sudden-onset back pain. Thoracic magnetic resonance imaging (MRI) performed in a local hospital did not reveal any abnormalities; consequently, the patient was placed under observation. Two months after the first episode, she abruptly experienced back pain and bilateral leg weakness without any apparent cause. She was diagnosed with cervical SEDH through cervical MRI (Fig. 1A). Her symptoms gradually improved under observation. Follow-up cervical MRI after 1 month revealed a decrease in the SEDH size (Fig. 1B). After these episodes, the patient experienced back pain on two occasions, and cervical MRI revealed mild SEDH (Fig. 1C). Despite the diagnosis, she was placed under observation due to a lack of neurological symptoms.

Fifteen months after the first event, the patient experienced severe back pain and left-hand numbness (Fig. 1D). One week after this, her symptoms worsened to include tetra-paresis (upper limb, 1–3/manual muscle testing [MMT], lower limb, 3–4/MMT), and numbness of the left arm. Cervical MRI demonstrated an increase in the size of the cervical SEDH on the left ventral and dorsal side of the dural sac from the C6 to T1 levels (same region as previously diagnosed) and resultant severe compression of the spinal cord (Fig. 1E). She was admitted to our department. Enhanced MRI and selective spinal angiography did not reveal any underlying cause for the SEDH.

The cervical SEDH was removed through left hemilaminectomy. We observed a thick capsule that covered the cervical SEDH, with a gelatinous consistency, which extended into the ventral side of the dural sac. Following removal, non-pulsatile bleeding from the epidural venous plexus along the left C6 nerve root—which was determined to be the possible origin of the SEDH—was eliminated with bipolar forceps (Figs. 2 and 3). The patient's symptoms gradually improved, and after 30 months of regular follow-ups, she had no neurological deficits, back pain, or recurrence on cervical MRI (Fig. 1F). Pathological examination of the tissue around the hematoma revealed only a hematoma capsule and no findings that could suggest the presence of organic diseases such as an arteriovenous malformation.

¹Department of Neurological Surgery, Nippon Medical School, Tokyo, Japan

²Department of Neurosurgery, Chiba Hokusyo Hospital, Nippon Medical School, Inzai, Chiba, Japan

Received: November 5, 2019; Accepted: January 28, 2020
Online September 15, 2020

Copyright© 2020 by The Japan Neurosurgical Society
This work is licensed under a Creative Commons Attribution-NonCommercial-NoDerivatives International License.

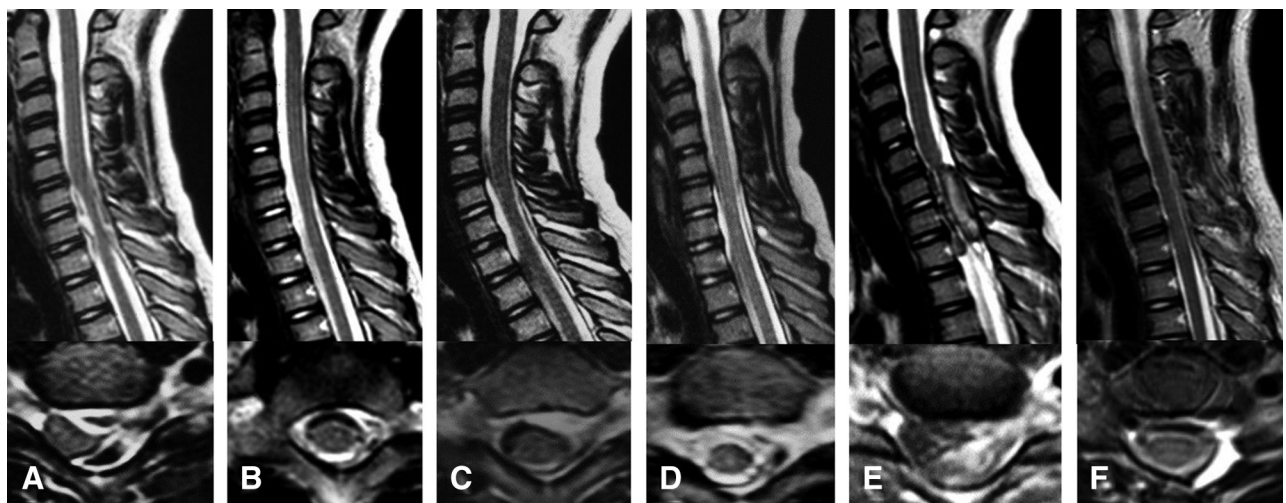


Fig. 1 Serial cervical T2-weighted MRI of the C6/C7 vertebrae (sagittal view, upper; axial view lower). (A) At the time of the initial bleeding. These images demonstrate a SEDH on the left ventral and dorsal side of the spinal cord, which is severely compressing the spinal cord at the C6 to the T1 level. (B) One month after the initial bleeding. These images show decreasing SEDH. (C) Four months after the initial bleeding. Recurrence of the SEDH on the left ventral side of the spinal cord compression is observed. (D) Fifteen months after the initial bleeding. The third recurrence of SEDH is observed. (E) One week after the third bleeding event. These images show a third recurrence of the SEDH on the left ventral and dorsal side of the dural sac, similar to the first bleeding event. (F) Eighteen months after the operation, where the SEDH has been removed, and the spinal cord is now decompressed. SEDH: spinal epidural hematoma.

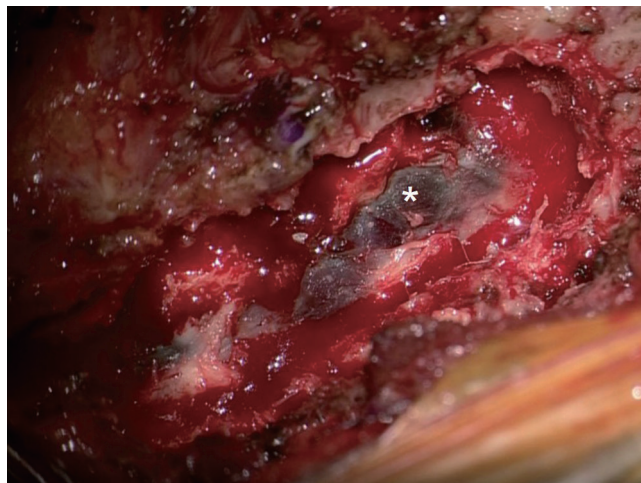


Fig. 2 After hemilaminectomy from the C6 to T1 level, a thick capsule (asterisk) covering the cervical SEDH was confirmed. SEDH: spinal epidural hematoma.

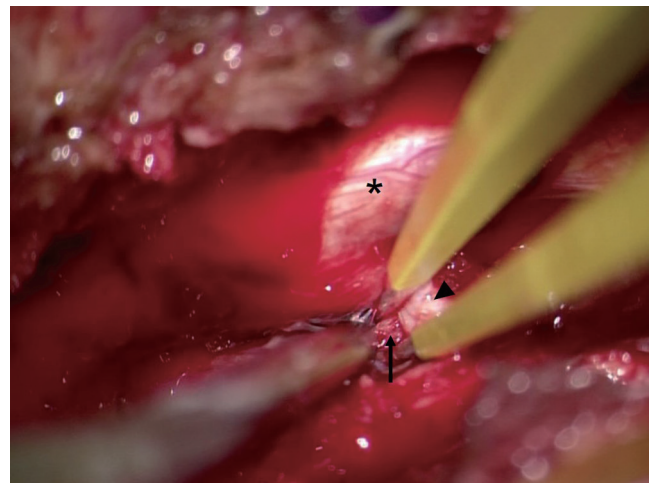


Fig. 3 After the removal of the dorsal side epidural hematoma, the bleeding from the epidural venous plexus (arrow) along the left C6 nerve root (arrowhead) was eliminated with bipolar forceps. Asterisk (**) indicates the dura mater of the spinal cord.

Discussion

Idiopathic SEDH can cause sudden clinical deterioration that necessitates surgical treatment. Otherwise, conservative therapy is useful in SEDH cases with mild neurological symptoms, and this typically results in symptom improvement.¹⁻³⁾ Recurrence of SEDH after treatment is the main clinical consideration and should be carefully observed during the follow-up period. However, there are currently few reports about SEDH recurrence and their clinical course. This report presented a relatively rare case of repeated SEDH recurrence.

Recurrence of SEDH is relatively rare, as only 11 cases have been reported in the English-based literature (Table 1).⁴⁻¹⁴⁾

In these reports, the locations of the recurrences were in the lower cervical to the upper thoracic region, which was the same as the case of idiopathic SEDH outlined here.^{3,15)} In most cases of recurrent SEDH, no disease that could explain any bleeding tendencies were present. This is similar to our case, although the coagulopathies may affect idiopathic SEDH in 26–36% of cases.^{3,15)} The average patient age for recurrent SEDH is 21.8 years, with 7 out of 12 patients younger than 20 years of age. Idiopathic recurrent SEDH is more commonly found in young female patients, as 8 out of the 12 reported recurrent SEDH cases were female. However,

Table 1 Patients with recurrence spinal epidural hematoma

Case	Age/sex	Back ground	Hematoma location	Ventral hematoma	Treatment (duration to recurrence)			Source of bleeding
					1st	2nd	3rd	
1 Harisk (1971) ¹⁾	20 / M	–	T1-2	–	ob	ob	ob (3 m)	–
2 Iwatsuki (1971) ⁵⁾	43 / M	GPD	T10-12	–	ob	ope (1.5 m)	–	Not listed
3 Pear (1972) ²⁾	27 / F	pregnancy	C4-T1	–	ope	ob (9 y)	–	–
4 Matsumae (1987) ⁹⁾	8 / F	–	1 st ; C2-4 2 nd ; C3-T8	–	ope	ope (6 y)	–	Engorged epidural vessels
5 Franscini (1994) ⁸⁾	50 / M	–	T2-3	+	ob	ob (1 y)	ope (1 m)	Not listed
6 Chen (1997) ¹¹⁾	17 / F	–	C7-T1	–	ob	ob (14 m)	ope (4 m)	Angioma
7 Sano (2004) ¹⁰⁾	16 / F	–	C7-T2	+	ob	ope (5 m)	ope (11 m)	Not listed
8 Groen (2004) ³⁾	10 / F	–	C7-T1	–	ob	ob (2 m)	ope (12 m)	Not listed
9 Abram (2007) ⁶⁾	13 / M	–	C4-7	–	ob	ope (38 m)	–	Not listed
10 Jain (2014) ⁴⁾	39 / F	–	C6-T1	–	ob	ob (15 m)	ope (4 m)	Venous plexus
11 Yamao (2015) ⁷⁾	6 / F	–	T1-3	–	ob	ope (2 m)	–	Not listed
12 Present case	13 / F	–	C6-T1	+	ob	ob (2 m)	ope (13 m)	Free epidural artery

C: cervical, GPD: partial platelet glycoprotein Ia/IIa deficiency, F: female, M: male, m: months, ob: observative therapy, ope: operation pregnancy, T: thoracic, y: years.

the literature states that idiopathic SEDH (without recurrence) was 1.4–2.8 times more likely in males, particularly in later life, as more than half of these patients were between 50 and 80-years old.^{3,15)} These characteristics of age and gender in recurrent idiopathic SEDH, therefore, appear to be different than those of non-recurrent idiopathic SEDH, and may present possible risk factors for this pathology.

The reasons why recurrent SEDH tends to occur in younger patients have not yet been documented. One explanation may be that the range of motion of the cervical spine decreases with increasing age.^{16–18)} Bleeding vessels in children and adolescents may, therefore, be subjected to greater tractive forces following the initial event, which may increase the risk of re-bleeding compared to adults. However, there is no explanation for why recurrent hematomas are more common in females. Although the range of motion of the cervical spine in adult females is greater than males, this gender difference is not found in children.^{16–21)} One possible explanation for the higher risk in young females could be the specific hormonal events exclusive to young females.

The posterior internal vertebral venous plexus plays an important role in the etiology of SEDH, which have a posterolateral locus in 99% of the cases.^{3,15)} Epidural-free arteries were involved in the SEDH of some cases.^{15,22,23)} Among the nine previously reported cases of recurrent SEDH that required surgical treatment, the causes of bleeding were as follows: angioma (n = 1), venous plexus (n = 1), engorged epidural vessels (n = 1), and no cause (n = 6).^{7,11,14)} In our patient, the SEDH extended to the front of the dural sac, and may have been a result of bleeding from the high pressure epidural venous plexus, even though we could not clearly prove it as venous plexus because there was no pathological finding, it was not pulsatile bleeding and we judged it

was venous plexus. In two out of the nine reported cases of recurrent SEDH, the hematoma also extended to the front of the dural sac, although the source of the hematoma was not described in these reports.^{11,13)} It is not possible to determine whether this is a shared feature of recurrent SEDH, but we expect that future reporting of similar cases may provide more information.

Various periods from initial SEDH diagnosis to recurrence have been reported, varying from 1.5 months to 9 years. Only three cases of recurrence after surgery have been reported, and a higher risk may be associated with observational, rather than surgical, treatment. The three cases that recurred after surgical treatment had long durations until recurrence of 6 months, 6 years, and 9 years, respectively.^{5,12,13)} In the other nine cases that showed recurrence after observation, the duration to the first recurrence was comparatively short; the median time was 3 months. This may be explained by the fact that surgical hemostasis may make the patient less susceptible to re-bleeding than natural hemostasis. This result may provide useful information for observation after treatment for SEDH. This suggests another reason for recurrent SEDH being more common in young females; physicians may avoid unnecessary surgery on children and adolescents.

In conclusion, recurrent SEDH appears to be more common in young females and is usually located ventrally in the lower cervical and upper thoracic region. These results might be useful for observation after the diagnosis of idiopathic SEDH.

Informed Consent

The patient has consented to the submission of the case report to the journal.

Acknowledgments

We would like to thank Editage (www.editage.jp) for English language editing.

Conflicts of Interest Disclosure

The authors declare that they have no conflict of interest.

References

- 1) Harik SI, Raichle ME, Reis DJ: Spontaneously remitting spinal epidural hematoma in a patient on anticoagulants. *N Engl J Med* 284: 1355–1357, 1971
- 2) Pear BL: Spinal Epidural Hematoma. *AJR* 115: 155–164, 1972
- 3) Groen RJ: Non-operative treatment of spontaneous spinal epidural hematomas: a review of the literature and a comparison with operative cases. *Acta Neurochir (Wien)* 146: 103–110, 2004
- 4) Jain RS, Handa R, Nagpal K, Prakash S, Gupta PK, Agrawal R: Recurrent spontaneous spinal epidural hematoma leading to compressive myelopathy. *Am J Emerg Med* 32: 818, 2014
- 5) Iwatsuki K, Deguchi M, Hirata H, Kanamono T: Spontaneously resolved recurrent cervical epidural hematoma in a 37-week primigravida. *Global Spine J* 5: e44–e47, 2015
- 6) Abram HS, DeLaHunt MJ, Merinbaum DJ, Hammond DN: Recurrent spontaneous spinal epidural hematoma in a child: first case report. *Pediatr Neurol* 36: 177–180, 2007
- 7) Yamao Y, Takagi Y, Kawauchi T, Arakawa Y, Takayama M, Miyamoto S: Surgical management of recurrent spontaneous spinal epidural hematoma with 3 episodes. *Spine* 40: E996–E998, 2015
- 8) Franscini L, Ballmer PE, Sturzenegger M, Beer JH, Tuncdogan E, Straub PW: Evaluation of back pain secondary to spinal epidural hematoma associated with aspirin intake and a partial platelet glycoprotein Ia/IIa deficiency. *Arch Intern Med* 154: 2769–2771, 1994
- 9) Matsumae M, Shimoda M, Shibuya N, Ueda M, Yamamoto I, Sato O: Spontaneous cervical epidural hematoma. *Surg Neurol* 28: 381–384, 1987
- 10) Sano H, Satomi K, Hirano J: Recurrent idiopathic epidural hematoma: a case report. *J Orthop Sci* 9: 625–628, 2004
- 11) Chen CJ, Fang W, Chen CM, Wan YL: Spontaneous spinal epidural haematomas with repeated remission and relapse. *Neuroradiology* 39: 737–740, 1997
- 12) Liao CC, Hsieh PC, Lin TK, Lin CL, Lo YL, Lee SC: Surgical treatment of spontaneous spinal epidural hematoma: a 5-year experience. *J Neurosurg Spine* 11: 480–486, 2009
- 13) Shin YI, Yang CY, Joo MC, Moon SK, Park JT, Kim TJ: Spontaneous epidural hematoma recurred three times. *NeuroRehabilitation* 22: 147–150, 2007
- 14) Mayer JA: Extradural spinal hemorrhage. *Can Med Assoc J* 89: 1034–1037, 1963
- 15) Groen RJ, Ponssen H: The spontaneous spinal epidural hematoma. A study of the etiology. *J Neurol Sci* 98: 121–138, 1990
- 16) Castro WH, Sautmann A, Schilgen M, Sautmann M: Noninvasive three-dimensional analysis of cervical spine motion in normal subjects in relation to age and sex. An experimental examination. *Spine (Phila Pa 1976)* 25: 443–449, 2000
- 17) Kuhlman KA: Cervical range of motion in the elderly. *Arch Phys Med Rehabil* 74: 1071–1079, 1993
- 18) Walmsley RP, Kimber P, Culham E: The effect of initial head position on active cervical axial rotation range of motion in two age populations. *Spine* 21: 2435–2442, 1996
- 19) Arbogast KB, Gholve PA, Friedman JE, Maltese MR, Tomasello MF, Dormans JP: Normal cervical spine range of motion in children 3–12 years old. *Spine* 32: E309–315, 2007
- 20) Feipel V, Rondelet B, Le Pallec J, Rooze M: Normal global motion of the cervical spine: an electrogoniometric study. *Clin Biomech (Bristol, Avon)* 14: 462–470, 1999
- 21) Lewandowski J, Szulc P: The range of motion of the cervical spine in children aged from 3 to 7 years - an electrogoniometric study. *Folia Morphol (Warsz)* 62: 459–461, 2003
- 22) Beatty RM, Winston KR: Spontaneous cervical epidural hematoma. A consideration of etiology. *J Neurosurg* 61: 143–148, 1984
- 23) Lonjon MM, Paquis P, Chanalet S, Grellier P: Nontraumatic spinal epidural hematoma: report of four cases and review of the literature. *Neurosurgery* 41: 483–486; discussion 486–487, 1997

Corresponding author:

Daijiro Morimoto, MD, PhD, Department of Neurological Surgery, Nippon Medical School, 1-1-5 Sendagi, Bunkyo-ku, Tokyo 113-8603, Japan.

✉daijiro@nms.ac.jp