



## Case report

# An unusual case of varicella zoster encephalitis mimicking a glioblastoma on magnetic resonance imaging and magnetic resonance spectroscopy

Brenden Nago<sup>a,b,\*</sup>, Jeffrey E. Liu<sup>a</sup>

<sup>a</sup> University of Hawaii, John A. Burns School of Medicine, Honolulu, HI, United States

<sup>b</sup> Bellevue High School, Bellevue, WA, United States

## ARTICLE INFO

## Keywords:

Varicella Zoster  
Encephalitis  
Corpus Callosum

## ABSTRACT

The authors report a case of varicella zoster encephalitis, mimicking a glioblastoma on Magnetic Resonance Imaging (MRI) and Magnetic Resonance Spectroscopy (MRS). The limitations of MRI/MRS, may lead to delayed treatment with antiviral agents, which can result in increased morbidity and mortality. The possibility of viral encephalitis should remain in the differential diagnosis of all patients presenting with headaches and confusion, even when imaging results are indicative of a neoplastic process.

## Introduction

Encephalitis is a rare neurological complication of varicella zoster virus (VZV) skin infection in immunocompetent patients, but it has been reported more frequently in immunocompromised patients [1,2]. It can occur acutely during the rash, but may be delayed and have a more chronic course in the immunocompromised patient [2]. Typical MRI findings of VZV encephalitis consist of discrete enhancing, subcortical, clustered plaque-like lesions [2,3]. Over the past 10 years, many cases describing the diagnostic similarities between herpes encephalitis and glioblastoma have been reported in the literature [4]. We present a patient who in 1999, developed VZV encephalitis following dermatomal zoster, in whom the MRI scans showed involvement of the corpus callosum. At that time, literature reports comparing and contrasting herpes encephalitis and glioblastoma were lacking, making this case a diagnostic dilemma.

## Case report

An 81 year-old right handed man with a two-week history of gradually worsening headaches presented to the emergency department. His past medical history was significant for lung cancer two years previously, treated with chemotherapy and radiation. He had no cancer since treatment. Physical and neurological examination was normal, except for an active eruption of shingles over the left C4 dermatome. CBC was normal, but the erythrocyte sedimentation rate was elevated at 79. CT head was normal, except for small bilateral hygromas. He was

discharged with oxycontin for pain, prednisone for possible temporal arteritis, and Famvir for herpes zoster.

Approximately 24 h later, he returned to the emergency department with hallucinations and progressive obtundation. His temperature was 99.0 and blood pressure 136/79. His neck was mildly stiff, but without clear meningeal signs (negative Kernig's and Brudzinski's signs). Neurological examination revealed a non-verbal, obtunded and mildly agitated patient, who was unable to follow commands. Cranial nerves were intact. The right fundus was normal, but the left fundus was difficult to visualize because of a cataract. The patient moved all extremities equally. Sensation, coordination, and gait could not be tested because of the patient's obtundation. Reflexes were 1+. Plantar reflexes were upgoing.

WBC was 12,700 with a differential of 84 % neutrophils, 11 % lymphocytes, and 5 % monocytes. HIV antibody was negative. Lumbar puncture showed an opening pressure of 240 mm H<sub>2</sub>O, with hazy pink CSF. The CSF showed 3600 WBCs with 78 % segmented cells, 19 % monocytes, 3 % lymphocytes, and 2800 RBCs in Tube 1; 6500 WBCs with 92 % segmented cells, 6 % monocytes, 2 % lymphocytes, and 24,900 RBCs in Tube 3; protein 501, and glucose 31 in Tube 2. CSF cultures and cytology were negative, and the CSF encephalitis panel showed a positive varicella zoster antibody (qualitative). EEG showed disorganized high amplitude delta and occasional theta waves.

MRI brain showed T2 sagittal hyperintensities in the splenium and body of the corpus callosum symmetrically extending into the posterior parietal-occipital lobes and with vasogenic edema (Fig. 1). T1 weighted axial imaging with gadolinium showed enhancement of the corpus

\* Correspondence to: 10416 SE Wolverine Way, Bellevue, WA 98004, United States.

E-mail address: [brendennago@gmail.com](mailto:brendennago@gmail.com) (B. Nago).

<https://doi.org/10.1016/j.idcr.2024.e02124>

Received 16 October 2024; Received in revised form 2 December 2024; Accepted 3 December 2024

Available online 4 December 2024

2214-2509/© 2024 Published by Elsevier Ltd. This is an open access article under the CC BY-NC-ND license (<http://creativecommons.org/licenses/by-nc-nd/4.0/>).

callosum (Fig. 2). Magnetic Resonance Angiogram (MRA) showed moderate stenosis of the intracavernous portion of the right internal carotid artery, hypoplasia of the A1 segment of the right anterior cerebral artery, and minor irregularity of the distal right posterior cerebral artery. The initial MRI interpretation by radiology was most consistent with a “butterfly glioma.” MRS of the right parietal-occipital white matter showed elevated lipids, reduced N-acetyl aspartate, and a choline to creatinine ratio of 1.7.

Brain biopsy performed a week later showed liquefactive necrosis of the left and right occipital lobes. There were focal areas of necrosis with numerous foamy macrophages. Deeper cells showed dense eosinophilic cytoplasm with pale nuclei as well as a few neutrophils and lymphocytes.

The patient was treated with intravenous acyclovir and dexamethasone, but remained in a comatose state. Follow-up MRI (T2 weighted) showed hemorrhagic necrosis involving the corpus callosum and posterior parietal-occipital white matter (Fig. 3). He expired a few months later.

## Discussion

The presentation and routine CSF studies of this patient were consistent with encephalitis. Clinically, it was suspected that the most likely cause of the encephalitis was herpes zoster because of the shingles. Although the brain biopsy was nondiagnostic, the positive CSF varicella zoster antibody was supportive of the diagnosis of VZV encephalitis.

The MRI and MRS findings in this patient are unique. Originally, it was interpreted as a glioma, due to involvement of the corpus callosum. As previously mentioned, over the past 10 years, many case reports have documented the similarities between glioblastoma and VZV on MRI. However, involvement of the corpus callosum still remains unique even to this day. The differential diagnosis of corpus callosum lesions include glioblastoma multiforme, primary malignant CNS lymphoma, lipoma, aquaporin-4 disease, Susac syndrome, and multiple sclerosis [4,5]. Involvement of the splenium has been described in subacute sclerosing panencephalitis [6]. Progressive multifocal leukoencephalopathy in HIV patients can also involve the corpus callosum [7]. There is one reported case of toxoplasmosis in an HIV patient involving the corpus callosum [8]. There has been a single case of infarction of the corpus callosum due to VZV described in 2022, but further reports are still very limited [9].

We hypothesize that the corpus callosum was affected because VZV may have caused a vasculopathy involving the pericallosal arteries with subsequent demyelination. VZV encephalitis is a vasculopathy that can affect both large and small vessels, because of VZV infection within the arteries [10,11]. The large vessel vasculopathy can cause ischemic or hemorrhagic infarctions [11]. The small vessel vasculopathy can cause deep white matter, ovoid mixed necrotic, and demyelinating lesions, with demyelination dependent on the degree of additional oligodendrocyte infection [11]. The large vessel vasculopathy usually occurs in immunocompetent patients, and the small vessel vasculopathy usually occurs in immunosuppressed patients [10,11]. Gross pathologic hallmarks of VZV include multifocal plaque-like white matter lesions, predominantly occurring near the gray-white junction, that progress in size and coalesce [10].

The typical MRI findings of VZV encephalitis are reflective of this pathology. There are usually discrete, subcortical, clustered plaque-like lesions that demonstrate rapid demyelination [2,3]. Active lesions enhanced with gadolinium. Edema and hemorrhage can develop as the infection evolves [3]. This patient's MRI showed enhancement of the corpus callosum and demyelination of the adjacent white matter, suggestive of active herpes zoster infection. MRA did not show a definite large vessel vasculopathy, so a small vessel vasculopathy likely occurred. He was predisposed to VZV encephalitis and small vessel vasculopathy because of a relative immunosuppressed state related to his advanced age and previous cancer.

MRS (a noninvasive diagnostic test for measuring biochemical changes in the brain, such as tumors, utilizing ratios of various metabolites to differentiate between tumor types), was performed on this patient. The ratio of 1.7 is seen in gliomas of all types including glioblastomas, which was thought to be the initial cause of this patient's presentation (range for glioblastoma is 1.61–3.66) [12]. Brain biopsy was necessary to make a more definitive diagnosis. The biopsy demonstrated necrosis with inflammatory changes, but excluded tumor as a diagnosis.

With regards to clinical outcome, this patient did not respond to dexamethasone and antiviral treatment. Meta-analyses have failed to show adequate benefit with steroids to this day [13]. Furthermore, delayed initiation of antiviral therapy in herpes encephalitis of more than 48 h has been shown to result in an increased risk of neurological sequelae and death [14]. In this case, the diagnostic dilemma of imaging

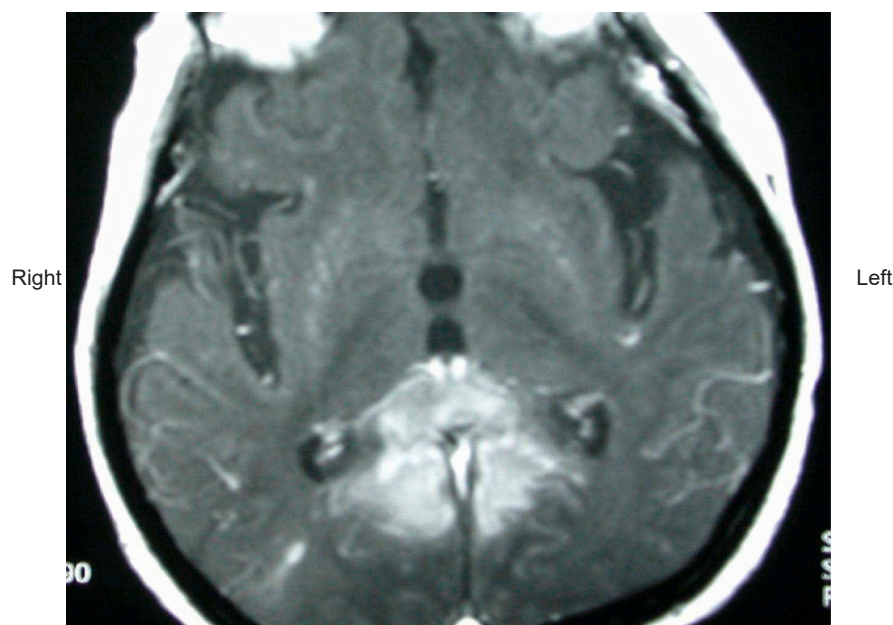
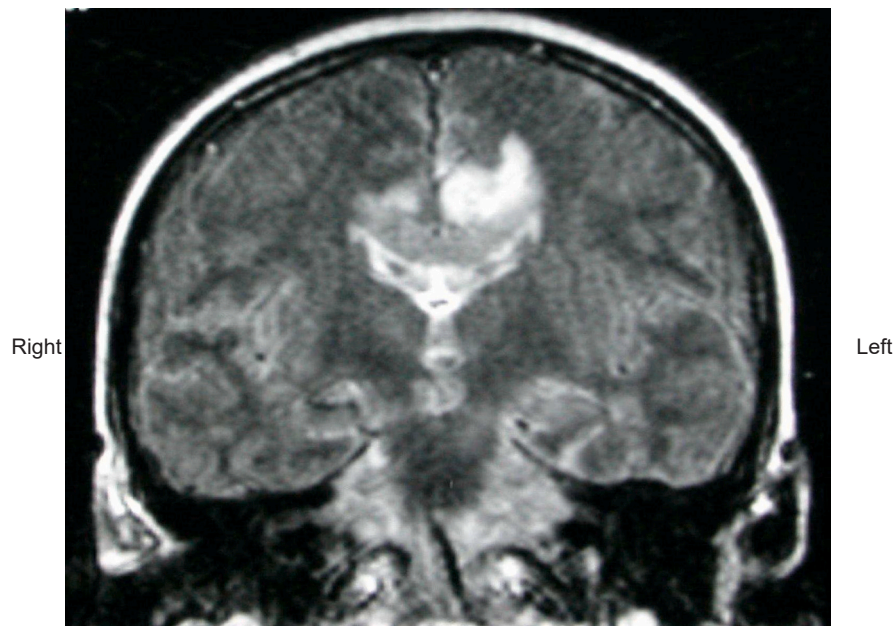
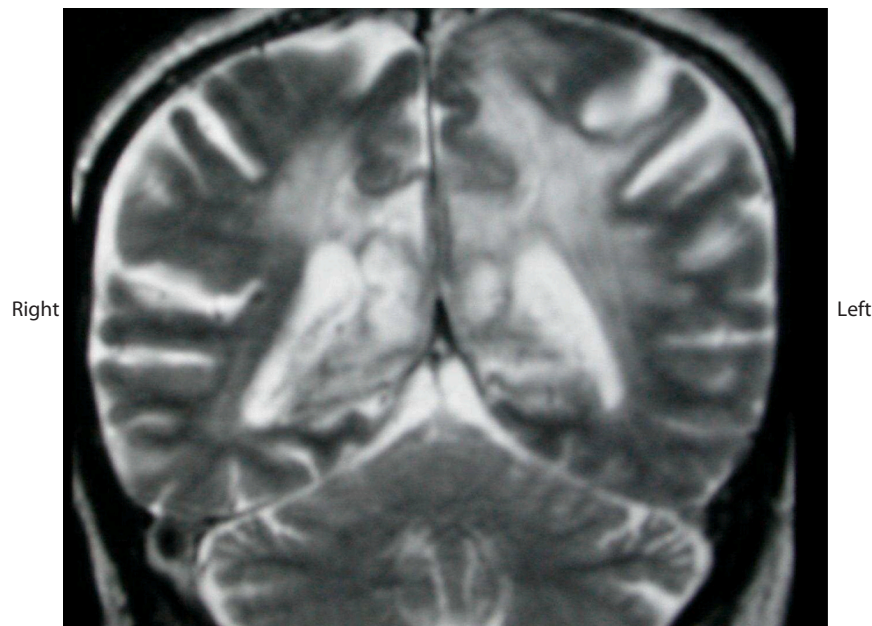


Fig. 1. T1 weighted MRI Brain post-gadolinium (axial) demonstrating enhancement of the corpus callosum.



**Fig. 2.** T2 weighted MRI Brain (sagittal) demonstrating hyperintensities in the splenium and body of the corpus callosum symmetrically extending into the posterior parietal-occipital lobes and with vasogenic edema.



**Fig. 3.** T2 weighted MRI Brain (sagittal) showing hemorrhagic necrosis involving the corpus callosum and posterior parietal-occipital white matter.

studies mimicking a glioma, probably led to delayed treatment with antiviral therapy.

This is an unusual case of VZV encephalitis in a patient who presented in 1999, due to corpus callosum involvement and tumor-like characteristics on MRI/MRS. At that time, literature was lacking. Now, 25 years later, cases like these still remain unusual and rarely seen. The exact pathophysiology of how VZV encephalitis can mimic a glioblastoma on MRI and MRS remains quite unclear and is open to further investigation. The possibility of infection, mimicking as a neoplasm on imaging, should always be a diagnostic consideration, as early treatment with antivirals can reduce neurologic morbidity and mortality.

#### Author Agreement

We confirm that this work is original, we have all seen and approved the final version. This has not been previously published elsewhere, and is not under consideration by another journal or book. We will also not submit the material to another journal until the completion of the editorial decision process at *ID Cases*. We have no conflicts of interest to disclose. We approve the manuscript and have contributed significantly to the work.

#### Ethical approval

This is a case report and did not involve any human subjects or animals.

## Consent

This case report does not contain any identifiable information. The patient expired 26 years ago. We attest that written consent was obtained from the patient's family at the time.

## Disclosures

None.

## Funding

None.

## CRediT authorship contribution statement

**Jeffrey Liu:** Writing – review & editing, Supervision. **Brenden Nago:** Writing – review & editing, Writing – original draft.

## Declaration of Competing Interest

The authors declare that they have no known competing financial interests or personal relationships that could have appeared to influence the work reported in this paper.

## References

- [1] Hausler M, Schaade L, Kemeny S. Encephalitis related to primary varicella-zoster virus infection in immunocompetent children. *J Neurol Sci* 2002;195:111–6.
- [2] Weaver S, Rosenblum MK, DeAngelis LM. Herpes varicella zoster encephalitis in immunocompromised patients. *Neurology* 1999;52:193–5.
- [3] Lentz D, Jordan JE. MRI in varicella-zoster virus leukoencephalitis in the immunocompromised host. *J Comput Assist Tomogr* 1993;17:313–6.
- [4] Takesh M, Sonnen J. Unusual rapid progression of glioblastoma initially mimicking herpes encephalitis. *Interdiscip Neurosurg* 2020;21.
- [5] Chia N, Redenbaugh V, Chen J, Pittock S, Flanagan E. Corpus callosum involvement in MOG antibody-associated disease in comparison to AQP4-IgG-seropositive neuromyelitis optica spectrum disorder and multiple sclerosis. *Mult Scler* 2023;29(6):748–52.
- [6] Taverl J, Spellman J. *Neuroradiology* 3rd edition. Baltimore: Williams and Wilkins; 1996.
- [7] Anlar B, Saatci I, Kose G, Yalaz K. MRI findings in subacute sclerosing panencephalitis. *Neurology* 1996;47:1278–83.
- [8] Whiteman ML, Post MJ, Berger JR, Tate LG, Bell MD, Limonte LP. Progressive multifocal leukoencephalopathy in 47 HIV seropositive patients: neuroimaging with clinical and pathological correlation. *Radiology* 1993;187:223–40.
- [9] Farooq Hira, Ziad Alishbah. Corpus callosum infarct in the background of Varicella-Zoster infection: a report of a rare case. *Cureus* 2022;14(10) (Oct).
- [10] Supiot F, Guillaume MP, Hermanus N, Telerman-Toppet N, Karmali R. Toxoplasma encephalitis in a HIV patient: unusual involvement of the corpus callosum. *Clin Neurol Neurosurg* 1997;99:287–90.
- [11] Gilden DH. Varicella zoster virus vasculopathy and disseminated encephalomyelitis. *J Neurol Sci* 2002;195:99–101.
- [12] Fayed Nicolás, Modrego Pedro. The contribution of Magnetic Resonance Spectroscopy and echoplanar perfusion-weighted MRI in the initial assessment of brain tumors. *J Neuro-Oncol* 2005;72:261–5.
- [13] Hodzic E, Hasbun R. Steroids for the treatment of viral encephalitis: a systematic literature review and meta-analysis. *J Neurol* 2023;270(7):3603–15. Apr 15.
- [14] Raschilas F, Wolff M, Delatour F, Chaffaut C, De Broucker T, Chevret S, et al. Outcome of and prognostic factors for herpes simplex encephalitis in adult patients: results of a multicenter study. *Clin Infect Dis* 2002;35:254–60.