



Contents lists available at ScienceDirect

## Gynecology and Minimally Invasive Therapy

journal homepage: [www.e-gmit.com](http://www.e-gmit.com)

Original article

## How to reduce the operative time of laparoscopic sacrocolpopexy?

Kaori Hoshino <sup>a</sup>, Kazuaki Yoshimura <sup>a,\*</sup>, Kazuaki Nishimura <sup>a</sup>, Toru Hachisuga <sup>b</sup><sup>a</sup> Department of Obstetrics and Gynecology, Wakamatsu Hospital of University of Occupational and Environmental Health, Wakamatsu-ku, Kitakyushu, Japan<sup>b</sup> University of Occupational and Environmental Health, Kitakyushu, Fukuoka, Japan

## ARTICLE INFO

## Article history:

Received 21 December 2015

Received in revised form

17 May 2016

Accepted 23 May 2016

Available online 5 July 2016

## Keywords:

absorbable tack  
 laparoscopic sacrocolpopexy  
 pelvic organ prolapse  
 short operative time  
 surgical technique

## ABSTRACT

**Objective:** Laparoscopic sacrocolpopexy (LSC) has been reported to achieve lower recurrence rates, shorter recovery time, and less dyspareunia. However, as a pelvic organ prolapse (POP) surgery, LSC is problematic because it requires specific techniques and it takes a comparatively longer operative time. In this study, we present our surgical techniques of LSC and their effectiveness for shortening operative times and raising safety.

**Methods:** Thirty-four women with stage 2 or greater POP who underwent LSC in our hospital between September 2014 and October 2015 were enrolled in this study. The notable points of our operative procedures are as follows: (1) fixing the sigmoid colon to the left lateral abdominal wall for a clearer visualization of the sacral promontory, (2) making a retroperitoneal tunnel (not opening the peritoneum) from the sacral promontory to the Douglas pouch, (3) dissection of the vaginal wall after transvaginal hydrodissection, (4) fixation of mesh to the vaginal wall by using absorbable tacks, and (5) limiting usage of posterior mesh for the patients with posterior vaginal wall descent.

**Results:** The median operative time was 140 (range, 90–255) minutes, and blood loss was 50 (range, 10–1600) mL. The operative time decreased as the surgical techniques improved through experience. No major intra- or postoperative complications occurred. The mean follow-up period was 4 (range, 1–14) months, and only one patient presented a recurrent grade 2 cystocele.

**Conclusion:** Our unique procedures will help shorten operative times and reduce complications of LSC.

Copyright © 2016, The Asia-Pacific Association for Gynecologic Endoscopy and Minimally Invasive Therapy. Published by Elsevier Taiwan LLC. This is an open access article under the CC BY-NC-ND license (<http://creativecommons.org/licenses/by-nc-nd/4.0/>).

## Introduction

Pelvic organ prolapse (POP) is not life threatening, but it is one of the common diseases that decrease women's quality of life. The Women's Health Initiative reported that 41% of women aged 50 to 79 years show some degree of POP, including cystocele (34%), rectocele (19%), and uterine prolapse (14%).<sup>1</sup> Olsen et al<sup>2</sup> and Wu et al<sup>3</sup> reported that women's lifetime risks of surgery for incontinence and/or POP by the age of 80 were 11.1% and 20.0%, respectively. It is known that the prevalence of POP increases with aging. The Japanese government reported that the female population aged 65 years or older was 17.6 million in 2014 and predicts that it will

increase until 2040.<sup>4</sup> This means that we can also expect the number of patients who require POP surgery to increase during this period.

There are many operative procedures for treating POP. Laparoscopic sacrocolpopexy (LSC) is one of the most effective surgical procedures, especially in women who wish to remain sexually active. LSC appears to be feasible and effective in treatment of not only apical vaginal defects but also multicompartiment POP.<sup>5</sup> Although sacrocolpopexy has been reported to achieve lower recurrence rates, less dyspareunia, and shorter recovery time (especially in LSC), it usually takes a longer operative time than the other procedures.<sup>6,7</sup> As with other POP operations, LSC must be completed in the shortest time possible, and less invasively, especially with advanced age patients. To overcome these problems, we improved some surgical procedures in LSC. The purpose of this paper is to introduce our operative procedures in LSC and to report on the effectiveness of our procedures for shortening operative times and for raising safety.

Conflicts of interest: The authors have no conflicts of interest relevant to this article.

\* Corresponding author. 1-17-1 Hamamachi, Wakamatsu-ku, Kitakyushu 808-0024, Japan.

E-mail address: [yoppy@med.uoeh-u.ac.jp](mailto:yoppy@med.uoeh-u.ac.jp) (K. Yoshimura).

<http://dx.doi.org/10.1016/j.gmit.2016.05.005>

2213-3070/Copyright © 2016, The Asia-Pacific Association for Gynecologic Endoscopy and Minimally Invasive Therapy. Published by Elsevier Taiwan LLC. This is an open access article under the CC BY-NC-ND license (<http://creativecommons.org/licenses/by-nc-nd/4.0/>).

## Materials and methods

Thirty-four consecutive LSC cases from our hospital, between September 2014 and October 2015, were studied for this report. The patients were diagnosed with symptomatic pelvic organ prolapse quantification (POP-Q) stage 2 or greater POP. Written informed consent was obtained from each patient regarding the usage of perioperative data. Age, body mass index, parity, and preoperative POP-Q score were recorded for all patients as preoperative characteristics. The operative time, intraoperative blood loss, and perioperative complications were also recorded.

### Surgical procedure

Patients were placed in the lithotomy position under general anesthesia. A camera port was inserted through a 12-mm vertical umbilical incision, two 5-mm trocars were placed at the midpoint between umbilicus and bilateral anterior superior iliac spines, and one 5-mm trocar was placed at the center of the lower abdomen. Together, they formed a diamond-shaped configuration. After this, the patients were repositioned to the Trendelenburg position ( $15^\circ$ ). The sigmoid colon was fixed to the left lateral abdominal wall to better visualize the areas surrounding the sacral promontory by using a straight needle (#2-0 SC-2 Monosof; Covidien, Mansfield, MA, USA); the anterior longitudinal ligament will then be exposed. A retroperitoneal tunnel was made from the sacral promontory to the Douglas pouch and the retroperitoneum was not fully opened (Figure 1). A supracervical hysterectomy (with or without bilateral salpingo-oophorectomy) was performed. Prior to the dissection of the anterior vaginal wall, a transvaginal hydrodissection was completed, followed by the dissection of the anterior vaginal wall to the Aa point (3 cm from the external urethral meatus). After this, a nonabsorbable suture (#0-SH ETHIBOND EXCEL; Ethicon, Somerville, NJ, USA) was tied to the distal tip of a self-cut polypropylene mesh (Polyform; Boston Scientific, Marlborough, MA, USA) (Figure 2) and then inserted into the abdominal cavity. We fixed the mesh to the anterior vaginal wall by that suture at the distal point and by another three nonabsorbable sutures (#1-CT1 ETHIBOND EXCEL; Ethicon) at the uterine cervix. We used approximately 10 absorbable tacks (AbsorbaTack; Covidien) for the other parts of the anterior vaginal wall (Figure 3). Dissection of the posterior vaginal wall and mesh insertion were performed only for cases with rectocele. The mesh was passed through the retroperitoneal tunnel and was fixed to the sacral promontory by two nonabsorbable sutures (#1-CT1 ETHIBOND EXCEL; Ethicon). The retroperitoneal

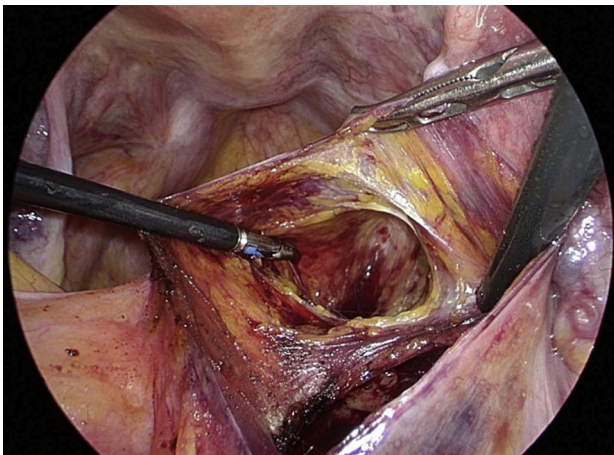


Figure 1. Retroperitoneal tunnel.




Figure 2. The anterior mesh with the nonabsorbable suture at the distal tip.

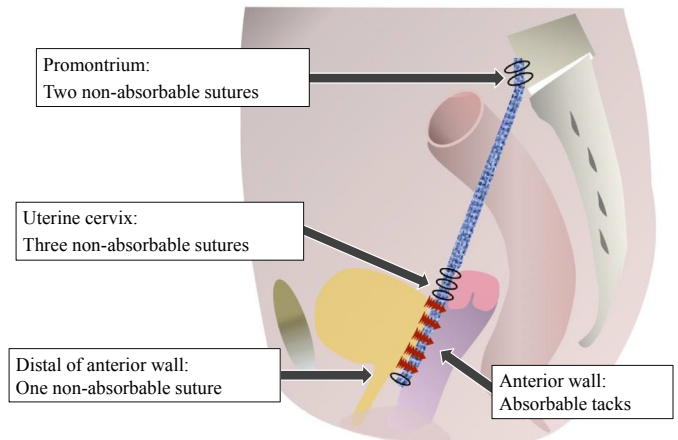
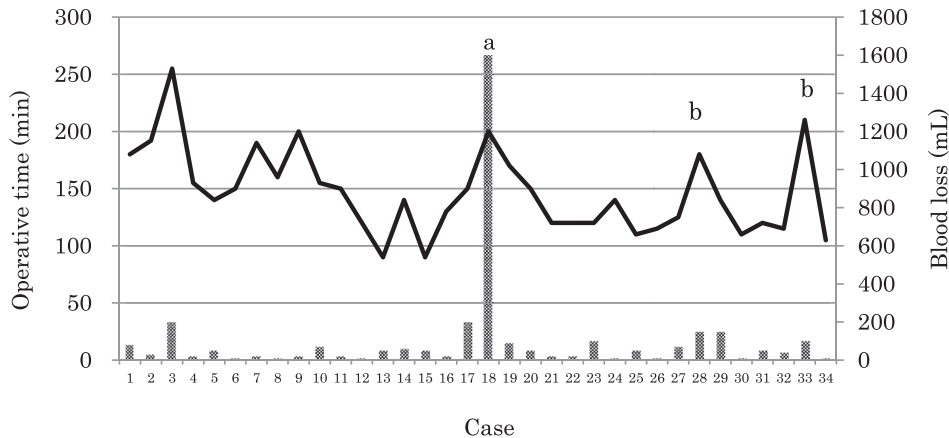


Figure 3. The schema of sagittal view after laparoscopic sacrocolpopexy (LSC). Sacral promontory, uterine cervix, and distal point of anterior vaginal wall were fixed by nonabsorbable sutures. Absorbable tacks were used at anterior vaginal wall.

space was closed with absorbable continuous sutures (#0-HR37 Monosyn; B. Braun, Rubí, Spain).

## Results

The baseline characteristics of patients are as follows. The median age was 60 (range 36–70) years, and the median body mass index was 23.5 (range, 19.0–31.4)  $\text{kg}/\text{m}^2$ . Seventeen (50%) women had stage 2 and 17 (50%) women had stage 3 POP. None of them had a history of hysterectomy. The median operative time was 140 (range, 90–255) minutes. The intraoperative blood loss was 50 (range 10–1600) mL (Figure 4). A single anterior mesh was used for 32 patients diagnosed with cystocele and/or uterine prolapse. Anterior and posterior double mesh was used for two patients (no. 28 and 33) because of rectocele. One patient (no. 18) had a large uterine myoma that caused massive bleeding during supracervical hysterectomy. No other intraoperative complications (such as bladder injury or bowel injury) occurred. No case was converted to laparotomy or transvaginal surgery. As shown in Figure 4, the operating time shortened as we gained experience, except for the huge myoma case and the double mesh cases, both referred to above. The single-mesh LSC procedure was cut to under a 2-hour average after 20 cases. No patient had any early postoperative



**Figure 4.** The operative time (black line) and intraoperative blood loss (gray bar). <sup>a</sup> Number 18 had a huge myoma. <sup>b</sup> Numbers 28 and 33 underwent double mesh laparoscopic sacrocolpopexy (LSC).

complications including hematoma, voiding difficulty, defecating difficulty, and infection. The mean postoperative follow-up period was 4 months. One patient presented recurrent stage 2 cystocele and was followed up conservatively. One patient presented *de novo* stress urinary incontinence and underwent midurethral sling (tension-free vaginal tape) surgery. No mesh erosion or chronic pelvic pain occurred.

## Discussion

Choosing the most appropriate POP procedure for the patient is extremely important in reducing risks and operative times. Needless to say, for laparoscopic surgery, severely obese patients should be excluded, whereas relatively young patients with sexual coital habits should be the most suitable candidates for minimally invasive LSC. In our opinion, POP surgeries must be completed in as short a time as possible, to minimize the intra- or postoperative complications.

There are several steps that take time in LSC: (1) visualization of sacral promontory, (2) dissection of anterior and posterior vaginal wall, and (3) fixation of mesh with the vaginal wall by suture. Notable points of our surgical procedures are as follows. The first one involves fixing the sigmoid colon to the left lateral abdominal wall to clearly visualize the areas surrounding the sacral promontory. This is effective in shortening the operative time (fixing mesh to the promontory, avoiding vessel injury). Second, making the retroperitoneal tunnel (not opening the peritoneum between the sacral promontory and Douglas pouch) can avoid hypogastric nerve injury and mesh erosion into the abdominal cavity. Third, transvaginal hydrodissection with saline prior to the laparoscopic dissection of the anterior vaginal wall enables easier dissection at the correct layer, resulting in the avoidance of bladder injury. It may also decrease bleeding. Fourth, the use of absorbable tacks for the fixation of mesh to the vaginal wall can shorten operative time and avoid mesh shrinkage. The important mesh fixation points are the distal point of the anterior wall, uterine cervix, and sacral promontory. Therefore, we use nonabsorbable sutures at the three key points and use absorbable tacks at the other points.

In addition, the most important conviction of POP surgeries is a focus on “site-specific repair,” which means to diagnose the injured part of the pelvic floor correctly and to only repair the injured site. LSC is a total repair. By contrast, if we use anterior and/or posterior LSC based on the clinical findings of each patient, LSC can be a “site-specific repair” procedure. Therefore, mesh usage should be limited; and to reduce the operative time and risks, posterior mesh is skipped for POP patients without rectocele.

Our primary experience was similar to some of the published reports. The mean operative times for LSC have been reported between 105 and 286 minutes.<sup>5,8–10</sup> And the learning curve of LSC was reported to show a steady decrease of operative times; a turning point was observed after 18–40 cases.<sup>11,12</sup>

There are several limitations in this study. First, this is a retrospective study with a small number of cases (34 cases) and a short follow-up period. Second, it was difficult to compare our data to previous reports because each case had slightly different procedures and the surgeons' techniques often improved with time, making direct comparisons difficult, if not impossible.

In conclusion, our techniques will be effective in shortening operative times, and in the reduction of the perioperative risks. It is our hope that our procedure will help make LSC more commonly used around the world.

## References

- Hendrix SL, Clark A, Nygaard I, Aragaki A, Barnabei V, McTiernan A. Pelvic organ prolapse in the Women's Health Initiative: gravity and gravidity. *Am J Obstet Gynecol.* 2002;186:1160–1166.
- Olsen AL, Smith VJ, Bergstrom JO, Colling JC, Clark AL. Epidemiology of surgically managed pelvic organ prolapse and urinary incontinence. *Obstet Gynecol.* 1997;89:501–506.
- Wu JM, Matthews CA, Conover MM, Pate V, Jonsson Funk M. Lifetime risk of stress urinary incontinence or pelvic organ prolapse surgery. *Obstet Gynecol.* 2014;123:1201–1206.
- Boue A, Drouhet V. Type I poliomyelitis epidemic in France and use of homotypic vaccine (Sabin I LSc 2 ab) by oral administration: II. Study of the results of vaccination. Characterization of the virus eliminated by the vaccines. *Arch Gesamte Virusforsch.* 1966;18:59–71.
- Gadonneix P, Ercoli A, Salet-Lizee D, et al. Laparoscopic sacrocolpopexy with two separate meshes along the anterior and posterior vaginal walls for multicompartiment pelvic organ prolapse. *J Am Assoc Gynecol Laparosc.* 2004;11:29–35.
- Maher C, Feiner B, Baessler K, Schmid C. Surgical management of pelvic organ prolapse in women. *Cochrane Database Syst Rev.* 2013;4:CD004014.
- Parke IL, Shveiky D. Sacrocolpopexy for treatment of vaginal prolapse: evidence-based surgery. *Jo Minim Invas Gynecol.* 2014;21:546–557.
- Cosson M, Rajabally R, Bogaert E, Querleu D, Crepin G. Laparoscopic sacrocolpopexy, hysterectomy, and burch colposuspension: feasibility and short-term complications of 77 procedures. *JSLG.* 2002;6:115–119.
- Rivoire C, Botchorishvili R, Canis M, et al. Complete laparoscopic treatment of genital prolapse with meshes including vaginal promontofixation and anterior repair: a series of 138 patients. *J Minim Invasive Gynecol.* 2007;14:712–718.
- Xiromeritis P, Marotta ML, Royer N, Kalogiannidis I, Degeest P, Devos F. Outcome of laparoscopic sacrocolpopexy with anterior and posterior mesh. *Hippokratia.* 2009;13:101–105.
- Akladios CY, Dautun D, Saussine C, Baldauf JJ, Mathelin C, Wattiez A. Laparoscopic sacrocolpopexy for female genital organ prolapse: establishment of a learning curve. *Eur J Obstet Gynecol Reprod Biol.* 2010;149:218–221.
- Mustafa S, Amit A, Filmar S, et al. Implementation of laparoscopic sacrocolpopexy: establishment of a learning curve and short-term outcomes. *Arch Gynecol Obstet.* 2012;286:983–988.