

A case of keratitis, ichthyosis, and deafness syndrome with rickets



Sabina Bhattarai, MD,^a Arti S. Pandey, PhD,^b Sherya Bastakoti, MD,^a Peter Soderkvist, PhD,^c and Mohan Bhusal, MBBS^a

Kathmandu, Nepal and Linköping, Sweden

Key words: connexin 26; keratosis; ichthyosis and deafness syndrome; rickets; systemic retinoids.

INTRODUCTION

Keratitis, ichthyosis, deafness (KID) syndrome is a rare disorder of cornification and a distinct type of congenital ichthyosis with predominantly autosomal dominant inheritance. The classical triad is keratitis, progressive erythrokeratoderma, and hearing loss.^{1,2} KID syndrome is a result of missense mutation in the *GJB2* (gap junction $\beta 2$) gene on chromosome 13q11-q12, which encodes connexin 26 protein. This protein is involved in formation of intercellular channels and has a role in epithelial differentiation.³ There are only around 100 cases of KID syndrome reported in literature to date.⁴ Although rickets has been reported to be associated with congenital ichthyosis and keratinizing disorders with erythroderma and scaling, KID syndrome with associated rickets has not been.⁵ We report a rare case of KID syndrome with rickets.

CASE REPORT

A 10-year-old boy presented to the dermatology outpatient clinic with complaints of progressive skin changes soon after birth along with progressive lower limb deformity for 5 years and progressive blurring of vision for the last 3 years. According to his parents, he was apparently well with normal-looking skin until the seventh day of life, after which there was gradual and generalized peeling of skin, which left behind a reddish base with spiky lesions protruding from the skin. His skin gradually became darker and thicker.

At the age of five, painful contractures of all four limbs developed, leading to inability to change



Fig 1. Hyperkeratotic warty plaques present all over the body (before treatment) with contractures of bilateral upper and lower extremities.

position. His permanent teeth started to develop from 7 years of age and are sparse, immature, and malformed. His vision started diminishing gradually to the point that he could only see things kept at near distance for the last 3 years. He was a preterm baby delivered by normal vaginal home delivery and has 3 siblings who do not have similar complaints. There is no history of consanguinity in his family.

On cutaneous examination, generalized dark-colored hyperkeratotic warty plaques were present

From the Departments of Dermatology and Venereology^a and Biochemistry,^b Kathmandu Medical College and Teaching Hospital and the Department of Clinical and Experimental Medicine, Linköping University,^c

Funding sources: None.

Conflicts of interest: None disclosed.

Correspondence to: Sabina Bhattarai, MD, Professor, Department of Dermatology and Venereology, Kathmandu Medical College and Teaching Hospital, Sinamangal, Nepal. E-mail: sabeenab@gmail.com.

JAAD Case Reports 2020;6:9-12.

2352-5126

© 2019 by the American Academy of Dermatology, Inc. Published by Elsevier, Inc. This is an open access article under the CC BY-NC-ND license (<http://creativecommons.org/licenses/by-nc-nd/4.0/>).

<https://doi.org/10.1016/j.jdc.2019.10.024>

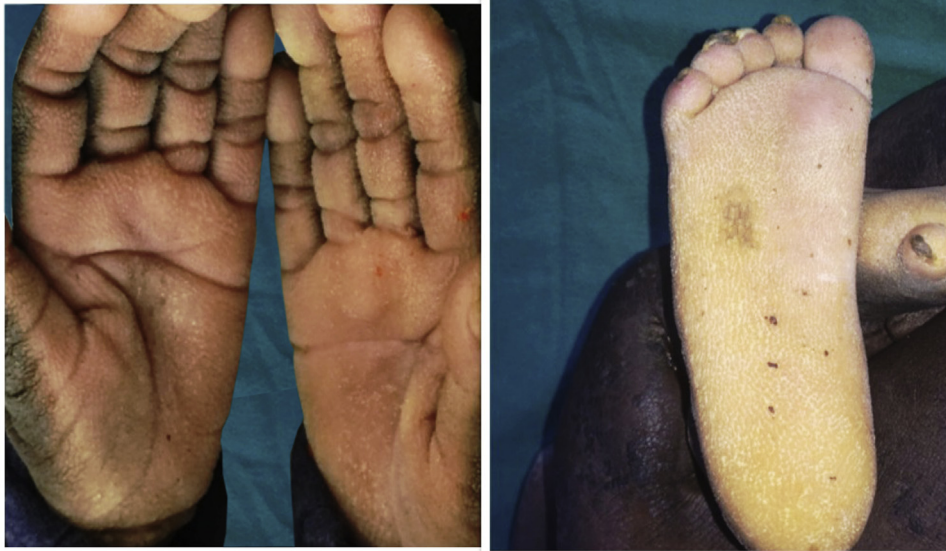

Fig 2. Stippled palmoplantar keratoderma of palms and soles.

on his entire face, neck, and upper and lower extremities; they were more thickened and spiky on back of the neck, extensor aspects of limbs, and nasal bridge with loss of hair of entire body (alopecia totalis; Fig 1).

His nails showed subungual hyperkeratosis of bilateral thumbs, ring, and little fingers along with onychodystrophy. Stippled palmoplantar keratoderma (Fig 2) was also evident. His scalp showed whitish to yellowish thick and dry plaques extending to the lateral part of his face (Fig 1). Left upper central and lateral incisors were absent and bilateral lower lateral incisors were poorly developed.

Ophthalmologic examination found conjunctival congestion and corneal neovascularization in both eyes—highly suggestive of KID syndrome. The fundal view was obscured because of corneal opacity. Ear, nose, and throat examination found mild hearing loss detected by free field test. On musculoskeletal examination, proportionate short stature with bowing of legs and arms of bilateral upper and lower limbs were seen (Fig 1). Radiographs showed osteopenia, cupping and fraying of metaphysis, increased bone formation in the upper and lower ends of long bones, and pathologic fractures suggestive of rickets (Fig 3). Routine blood investigations found increased alkaline phosphatase and parathyroid hormone and decreased calcium and 25-hydroxy vitamin D, favoring rickets (Table I). Histopathologic examination of skin was suggestive of ichthyosis vulgaris, and gene sequencing done from a blood sample found a mutation in the single coding exon of the *GJB2* gene at position 148 (c.148G>A) causing

substitution of aspartate by asparagines at position 50 (D50N).

The patient was treated with moisturizers, topical salicylic acid, oral isotretinoin, 10 mg/d, oral vitamin B complex, vitamin D, protein and calcium supplements, and antibiotic eye drops during his hospital stay. He is currently on 10 mg/d of isotretinoin and on monthly follow-up. He shows improvement and is treated at the orthopedic rehabilitation center (Fig 4).

DISCUSSION

KID syndrome is a disorder of ectodermally derived tissues—skin, cornea and inner ear.¹ The male/female ratio is 32:29.⁶ The mode of inheritance is usually autosomal dominant with few families having an autosomal recessive pattern.⁷ However, most cases result from new mutations in the gene.⁶ Because parental genetic analysis was not done in our case, we cannot comment on the exact mode of inheritance.

KID syndrome is associated with a mutation in the *GJB2* gene on chromosome 13q11-q12, which encodes connexin 26.³ The genes *GJB2*, *GJB3*, *GJB4*, *GJB5* and *GJA4* are known or expected to be involved in skin disorders sometimes accompanied by deafness.⁸ The most common mutation is D50N missense mutation within the *GJB2* gene encoding connexin 26 due to substitution of aspartate by asparagines at position 50 of the protein.⁹ This same pathogenic mutation (D50N) was detected in our patient at position 148 of *GJB2* (c.148G>A).

Coggsall et al⁴ compiled the associated features of KID syndrome and Caceres-Rios et al⁶ also

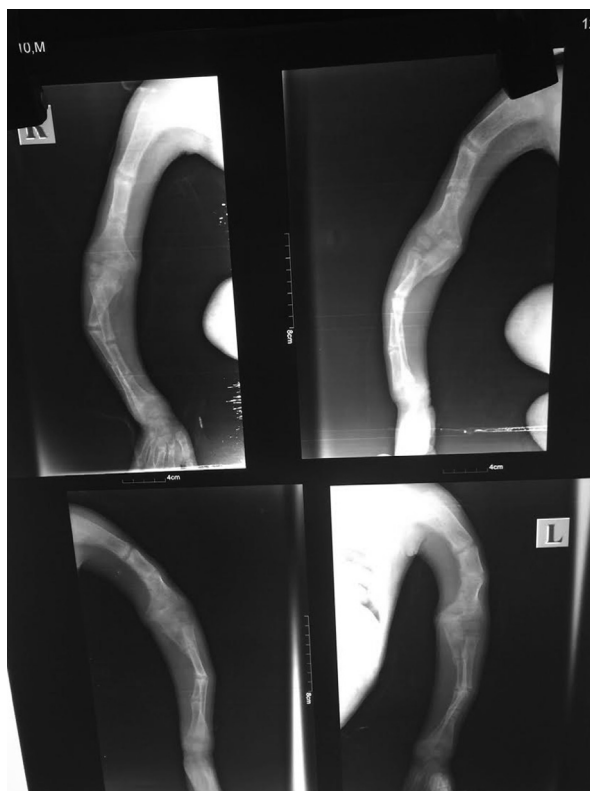


Fig 3. Radiograph changes in the long bones (osteopenia, cupping, and fraying of metaphysis, pathologic fractures).

Table I. Laboratory investigations

Hemoglobin	13.8 g/dL (13.8-17.2 g/dL)
Total count	11400/ μ L (4,500-11,000)
Platelets	379000/ μ L (150000-450000)
Erythrocyte sedimentation rate	11 mm/h (0-22 mm/h)
C-reactive protein	Negative
Antinuclear antibody	Negative
Calcium	8.4 (8.5-10.2 mg/dL)
Phosphorus	2.5 (2.5-4.5 mg/dL)
Uric acid	6.1 (3.4-7 mg/dL)
25-OH vitamin D	13.78 (20-50 ng/mL)
Parathyroid hormone	619.46 (10-65ng/L)
Alkaline phosphatase	6320 (44-147IU/L)
Scalp skin scraping for potassium hydroxide	Fungal hyphae absent

developed a diagnostic criteria of KID syndrome based on features found in their review. In our case, erythrokeratoderma, vascularizing keratitis, reticulated palmoplantar hyperkeratosis and alopecia were evident as major criteria, whereas dental dysplasia, hypohidrosis, and growth delay were minor criteria.

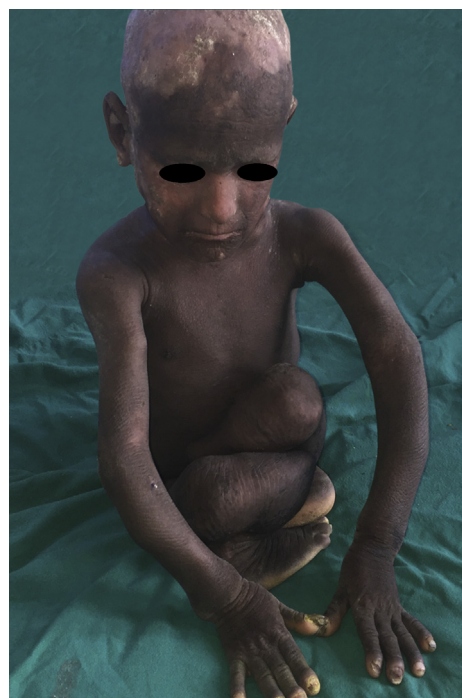

Fig 4. Follow-up of the patient (smooth skin with disappearance of warty plaques) after 2 months of treatment with emollients, topical/oral retinoids and conservative management

In a case report by Yang et al,¹⁰ there was an association of KID with flexion contracture of upper limbs and knees similar to our case. The most striking feature in our patient was the development of rickets. A study done by Chouhan et al,⁵ found that patients having ichthyosiform erythroderma are at increased risk of vitamin D deficiency and rickets, especially those with darker skin types (type IV-VD). The thick scales acting as a physical photo blocker and social stigmatization leading the child to be kept inside could have contributed to the severe vitamin D deficiency.

KID syndrome needs multidisciplinary treatment to maintain skin barrier, prevent or treat cutaneous infections, and screen for cutaneous malignancies. Treatment consists of emollients, keratolytics and topical/oral retinoids. These patients also need regular screening for vitamin D deficiency and lifelong prophylactic vitamin D supplementation to prevent development of clinical rickets and irreversible bony changes.

REFERENCES

1. Oji V, Metzger D, Traupe H. Inherited disorders of cornification. In: Burns T, Breathnach S, Cox N, Griffiths C, eds. *Rook's Textbook of Dermatology* 9th ed. Edinburgh, U.K: Wiley-Blackwell; 2016: 65.30-65.32.

2. Skinner BA, Greist MC, Norins AL. The keratitis, ichthyosis, and deafness (KID) syndrome. *Arch Dermatol*. 1981;117(5):285-289.
3. Van Geel M, Van Steensel M, Kuster W. HID and KID syndromes are associated with the same connexin 26 mutation. *Br J Dermatol*. 2002;146(6):938-942.
4. Coggshall K, Farsani T, Ruben B, et al. Keratitis, ichthyosis, and deafness (KID) syndrome: a review of infectious and neoplastic complications. *J Am Acad Dermatol*. 2013;69(1):127-134.
5. Chouhan K, Sethuraman G, Gupta N, et al. Vitamin D deficiency and rickets in children and adolescents with ichthyosiform erythroderma in type IV and V skin. *Br J Dermatol*. 2012;166(3):608-615.
6. Caceres-Rios H, Tamayo-Sanchez L, Duran-Mckinster C, de la Luz Orozco M, Ruiz-Maldonado R. Keratitis, ichthyosis, and deafness (KID) syndrome: review of the literature and proposal of a new terminology. *Pediatr Dermatol*. 1996;13(2):105-113.
7. Nazzaro V, Blanchet-Bardon C, Lorette G, Civatte J. Familial occurrence of KID (keratitis, ichthyosis, deafness) syndrome. Case reports of a mother and daughter. *J Am Acad Dermatol*. 1990;23(2 Pt 2):385-388.
8. Iossa S, Marciano E, Franze A. GJB2 gene mutations in syndromic skin diseases with sensorineural hearing loss. *Curr Genomics*. 2011;12(7):475-485.
9. van Steensel MA, van Geel M, Nahuys M, Smitt JH, Steijlen PM. A novel connexin 26 mutation in a patient diagnosed with keratitis-ichthyosis-deafness syndrome. *J Invest Dermatol*. 2002;118(4):724-727.
10. Yang CY, Chen YJ, Shen JL. Keratitis, ichthyosis and deafness syndrome—a case report and literature review. *Dermatol Sinica*. 2008;26:151-156.