

Review  
Article

# Atrial Hemangioma: A Case Report and Review of the Literature

Huikai Miao, MD,<sup>1</sup> Wenlong Yang, BM,<sup>2</sup> Mengmeng Zhou, MD,<sup>3</sup> Qiang Zhu, MD, PhD,<sup>1</sup> and Zhongmin Jiang, MD, PhD<sup>1</sup>

**A primary cardiac tumor is a rare clinical entity which was reported an incidence of 0.03% in previous autopsy series. 75% cardiac tumors are cardiac myxoma and cardiac hemangiomas constitute only 1–2% of primary cardiac tumors. With the development of modern medical imaging technology and the enhancement of people's health awareness, more and more asymptomatic cardiac hemangiomas were found and confirmed eventually. Here, we described a case of a 71-year-old man, who was hospitalized with intermittent palpitation for 1 year and a large mass of the heart was removed successfully via sternotomy which was confirmed as atrial hemangioma by postoperative histopathology. Furthermore, a comprehensive review of atrial hemangioma was conducted to date and a few recommendations for the diagnosis and treatment of this uncommon disorder were provided for clinicians.**

**Keywords:** atrial hemangioma, diagnosis, surgery, case report, literature review

## Introduction

Cardiac hemangioma is a rare benign tumor of the heart.<sup>1)</sup> The first report of cardiac hemangioma was put forward by Uskoff in 1893.<sup>2)</sup> The atrium is the most common site of hemangioma.<sup>3)</sup> The clinical symptoms and imaging examinations of atrial hemangioma are lack of specificity.<sup>4)</sup> Many patients manifested inapparent

clinical manifestations and underwent surgical treatment because of an unidentifiable atrial mass found by routine physical examination. The preoperative misdiagnosis rate is much higher and mostly confirmed by postoperative histopathology. The main treatment of atrial hemangioma is surgical resection. Most of the patients have a good prognosis after surgery. However, due to their low incidence, there are still no clear conclusions about indications for operation and operative methods of atrial hemangioma.<sup>5)</sup> In this study, we reported an atrial hemangioma case which has obtained better therapy results, and summarized the review of currently published atrial hemangioma cases and discussed the clinical manifestation, image characteristics, treatment, surgical indications, to improve the accuracy of preoperative diagnosis of atrial hemangioma, thus to provide reference in clinics.

## Case Presentation

A 71-year-old man with intermittent heart palpitation for more than 1 year and nausea for 2 days was admitted to the hospital. The patient was healthy before and denied

<sup>1</sup>Department of Thoracic Surgery, Shandong Provincial Qianfoshan Hospital, Shandong University, Jinan, China

<sup>2</sup>Department of Thoracic and Cardiovascular Surgery, Shandong Provincial Lanling People's Hospital, Linyi, China

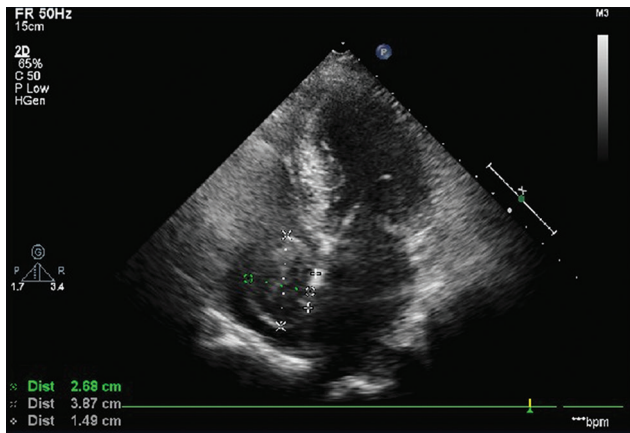
<sup>3</sup>Department of Thoracic Surgery, Shandong Provincial Qianfoshan Hospital, Taishan Medical University, Taian, China

Received: August 29, 2018; Accepted: December 17, 2018

Corresponding authors: Qiang Zhu, MD, PhD; Zhongmin Jiang, MD, PhD. Department of Thoracic Surgery, Shandong Provincial Qianfoshan Hospital, Shandong University, Jinan 250014, China

Emails: qiangzhu2018@gmail.com; qyjzm@sina.com

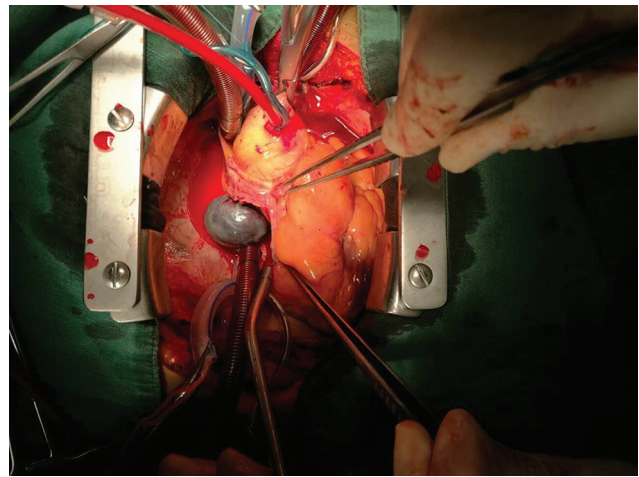
©2019 The Editorial Committee of *Annals of Thoracic and Cardiovascular Surgery*. This work is licensed under a Creative Commons Attribution-NonCommercial-NonDerivatives International License.



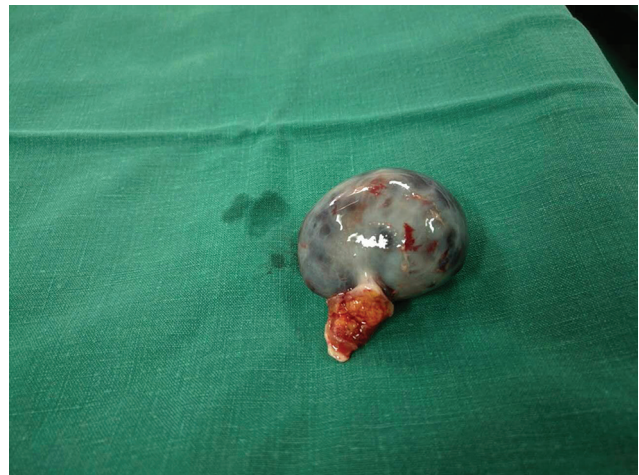**Fig. 1** Echocardiography shows a mass (3.8 × 2.6 cm) of the right atrium.

hypertension, coronary heart disease, and other cardiovascular diseases. No history of smoking and drinking and no fever, shiver, dizziness, shortness of breath, and chest pain were observed. Physical examination showed 164/68 mmHg of blood pressure, 71 beats per minute of pulse, and no abnormalities were found. Both chest X-ray and electrocardiogram identified normal. Echocardiography showed left ventricular ejection fraction (LVEF) was 62% and an inhomogeneous echogenic mass was found in the right atrium (**Fig. 1**). The transthoracic echocardiography confirmed a large (3.8 × 2.6 cm) right atrial mass with smooth edge and integrated membrane. Mass' base, which was 14 mm, was attached to the middle and lower segment of the atrial septum, and the mass oscillated slightly with the cardiac cycle. No obvious abnormalities and obstructive coronary artery disease were found by computed tomography (CT) scans and coronary angiography, respectively.

After full preoperative preparation, we successfully completed surgery. During operation, we confirmed that mass was attached to the atrial septum which was consistent with preoperative echocardiography (**Fig. 2**). A standard midline sternotomy was performed, and the pericardium was incised. Palpation along right atrium immediately revealed the presence of a large (4.3 × 3.2 × 2.6 cm) purple cystic tumor. The heart was displaced anteriorly and rotated toward the right. It turned out to be mobile and soft with complete capsule. Tumor pedicle was about 1.0 cm in length and attached to the lower part of the fossa ovalis. And the pedicle distanced 1.0 cm from the inferior vena cava opening and 1.2 cm from the coronary sinus opening. After the right atrium incision was exposed, the atrial septal tissue attached to



**Fig. 2** Surgeon's view of the open right atrium revealed the presence of a large (4.3 × 3.2 × 2.6 cm) purple and black cystic tumor.



**Fig. 3** Gross view of resected right atrial mass.

the tumor pedicle was removed and the tumor was completely excised (**Fig. 3**). The inferior border of the atrial septal defect was 0.5 cm from the inferior vena cava opening and the atrial septal partial defect was sutured continuously by a Standard 3-0 PROLENE Polypropylene Suture (Ethicon, Somerville, NJ, USA). In addition, 2.5 × 1.5 cm autologous pericardial slices and a 4-0 PROLENE suture were used to continuously suture the atrial septal defect. The 5-0 PROLENE was used to repair the right atrium through continuous round-trip suture. No malformation was found in the left superior vena cava and pulmonary vein. The extracorporeal circulation lasted for 86 minutes and the aortic clamping time was 34 minutes. After stopping aortic clamping and cardiac reperfusion, the patient returned to sinus rhythm.

Histopathologic examination of mass section showed no obvious cell proliferation, atypical hyperplasia, or mitotic activity and a hemangioma was confirmedly diagnosed. The patient recovered smoothly after surgery and was discharged on the 11th day after the operation. Two years after the surgery, the patient is asymptomatic.

## Results

A search of PubMed, Embase, Sinomad, CNKI, Wanfang, and VIP database was performed to identify the relevant case reports and case series using the following terms: “cardiac hemangioma” or “cardiac vascular hamartoma” or “cardiac angioma” or “atrial hemangioma.” We identified a total of 67 articles published between 1996 and 2018, among which 65 cases of atrial hemangioma had complete operation information. Of all included cases, 65 were surgical cases and 2 were no surgery. A systematic review has been summarized in **Table 1** by combining the clinical data of these published cases.

The clinical data of 67 patients were included. Sixty-one patients were over 1-year old and six infants were under 1-year old. The average age of onset in patients over 1-year old was 56.2 years (range: 26–82 years old), and the predominant age was middle-aged (45 years old and above), accounting for 68.7% (46/67) of all cases. Gender information was reported in 60 cases, and 25 were males, accounting for 41.7% and 35 were females, accounting for 58.3% among them. The incidence rate was higher in female than that in male. Sixty-five patients were confirmedly diagnosed by postoperative histopathology. The size of hemangiomas varied from 20 mm to 130 mm with an average size of 52.3 mm. Cardiac hemangioma occurs anywhere in the heart and could be located in the pericardium, endocardium, and myocardium. Atrial hemangioma (including atrial septum) accounts for approximately 47% of cardiac hemangioma.<sup>6)</sup> In our included cases, 24 cases of the hemangioma were located in the left atrium, which accounted for 35.8%; 42 cases were in the right atrium, accounting for 62.7%; only one case was in the right and left atria, accounting for 1.5%. Atrial hemangioma most commonly occurs in the right atrium and mostly is a single tumor. However, cardiac hemangiomas were also found to be two tumors in the same patient, accounting for only 1%,<sup>6)</sup> which was consistent with data of 1.5% (1/67) conducted by us. In addition, in our research, approximately 3% atrial hemangioma (2/67) was found concomitant with liver hemangiomas, which was similar to the proportion (4%)

of total cardiac hemangioma previously reported in the literature.<sup>4)</sup>

According to pathology, a cardiac hemangioma can be classified into simple cavernous hemangioma, simple capillary hemangioma, arteriovenous hemangioma, and mixed type. In our statistical data of atrial hemangioma, cavernous hemangioma is the most common pathological type, which accounted for 58.5% (38/65), followed by simple capillary hemangioma, accounting for 9.2% (6/65).

Many atrial hemangiomas are diagnosed accidentally in the physical examination with no discomfort. In our results of 67 cases, atrial hemangiomas were found only in 27.9% patients by physical examination. The main symptoms of the remaining 72.1% patients were circulatory and respiratory symptoms, including pericardial effusion (16.7%), shortness of breath (13.1%), palpitations (13.1%), chest pain (11.5%), and chest discomfort (6.6%). In addition, four patients were admitted to the hospital due to emergency including cardiac arrest (1/4), chest pain (2/4), and stroke (1/4). There were still a few cases that died for severe pericardial infection and arrhythmia eventually.<sup>7)</sup>

As for auxiliary examination, a total of 18 patients had descriptions of electrocardiography (ECG), 4 of them had completely normal ECG, 2 had atrioventricular (AV) block, 1 had bradycardia, 1 had tachycardia, 1 had atrial fibrillation, 1 had ectopic cardiac rhythm, and 8 had non-specific S-T and T wave changes, among which 2 had obvious S-T depression.

Echocardiography examination was mentioned in 58 patients (86.6%). Fifty-five patients (55/58) were definitely found in atrial masses, and the other three cases (3/58) were only found pericardial liquid. Four patients were admitted to the hospital due to emergency and underwent bedside cardiac ultrasound examination followed by the finding of an atrial hemangioma.

CT report was described in 23 cases. 91.3% (21/23) cases were found atrial tumors and remaining 8.7% (2/23) cases were found no tumor. In our included cases with complete enhanced CT data, 75% (3/4) had significant delayed enhancing performance.

Magnetic resonance imaging (MRI) is good at describing the high vascularity of atrial hemangioma. We have collected 23 cases which provided description for MRI examination. However, in these cases with a complete MRI description, 57.1% atrial hemangioma showed a mediate signal in T1 and 85.7% showed a high signal in T2-weighted images, which suggested that high signal

Table 1 Summary of data in 67 cases of atrial hemangioma reported in the literature

	First author	Year	Age (Y)	Sex	Camber	Size (mm)	Presenting symptoms	Treatment	Patch material
1	Nakamura E	2018	82	F	LA	100 × 71	Dyspnea	Resection	—
2	Abu Saleh WK	2016	67	F	LA	90 × 70	Dyspnea, palpitations	Excision and repair	Porcine urinary bladder membrane
3	Zhang D	2016	65	F	LA	40 × 30	Chest distress	Excision and repair	Bovine pericardial patch
4	Contrafouris C	2016	42	F	RA	44 × 50	Asymptomatic	Excision and repair	Bovine pericardial patch
5	Spanò F	2015	47	M	RA	85 × 55 × 50	Asymptomatic	Resection	—
6	Darwazah AK	2015	62	F	LA	10 × 10	Cardiac arrest	Resection	—
7	Lin TW	2015	34 W	NA	RA	NA	Asymptomatic	Excision and repair	Equine pericardial patch
8	Sánchez-E C	2015	74	M	RA	60 × 60	Asymptomatic	Excision and repair	Auto pericardial patch
9	Nishio S	2015	35	F	LA	20 × 15	Malaise, anasarca	Resection	—
10	Martínez JM	2015	38	F	RA-LA	90 × 75 × 45	Palpitations	Excision and repair	Auto pericardial patch
11	Kitahara H	2015	53	M	RA	30 × 25	Asymptomatic	Excision and repair	Auto pericardial patch
12	Sengodan P	2014	46	F	RA	35 × 35	Asymptomatic	No surgery	—
13	Hong SY	2014	74	M	LA	20 × 15	Dyspnea	Resection + CABG	—
14	Jonjev ZS	2014	72	F	LA	28 × 17	Loss of consciousness	Resection	—
15	Olivotti L	2014	57	M	LA	50 × 50 × 70	Asymptomatic	Resection	—
16	Bandyopadhyay S	2013	68	M	LA	50 × 40	Dyspnea, chest pain	Excision and repair	Auto pericardial patch
17	Li W	2013	26	M	RA	65 × 60 × 50	Asymptomatic	Resection	—
18	Szymski FM	2013	51	F	RA	75 × 65	Asymptomatic	Partly resection	—
19	Takahashi A	2013	61	F	LA	60 × 60	Dyspnea	Resection	—
20	Turak O	2012	54	M	RA	24 × 25	Dizziness	Resection	—
21	Baird C	2012	6 D	NA	RA	20 × 20	Asymptomatic	Excision and repair	Auto pericardial patch
22	Husain Z	2011	42	F	RA	110 × 65	Shortness of breath	Resection	—
23	González López MT	2011	49	M	LA	10 × 5	Angina	Resection + CABG	—
24	Para M	2011	64	F	RA	22 × 19	Cerebral strokes	Resection	—
25	Onan B	2011	5 M	F	RA	53 × 44	Intractable colic	Resection	—
26	Hrabak-Paar M	2011	61	F	RA	54 × 66 × 54	Asymptomatic	Resection	NA
27	Eichler T	2011	36 W	M	RA	45 × 35 × 28	Cyanosis, tachypnea	Excision and repair	NA
28	De Filippo M	2010	49	F	RA	35 × 35 × 25	Dyspnea, arrhythmias	Excision and repair	Auto pericardial patch
29	van Buuren F	2010	73	F	LA	19 × 21	Asymptomatic	No surgery	—
30	KasMi R	2009	70	M	RA	37 × 26 × 14	Shortness of breath	Resection	—
31	Novitzky D	2009	48	M	LA	60 × 40 × 50	Heart failure	Excision and repair	Auto pericardial patch
32	Mongal LS	2009	42	F	RA	110 × 65	Asymptomatic	Excision and repair	Bovine pericardial patch
33	Acikel S	2009	71	F	RA	25 × 10	Ischemic stroke	Resection	—
34	Sadik Acikel	2009	71	F	LA	40 × 10	Ischemic stroke	Resection	—
35	Ediae J	2009	75	M	LA	86 × 70	Asymptomatic	Excision and repair	—



Table 1 (Continued)

	First author	Year	Age (Y)	Sex	Camber	Size (mm)	Presenting symptoms	Treatment	Patch material
36	Zanati SG	2008	30	M	RA	130 × 120	Cough, chest pain	Resection	—
37	Yuan SM	2008	60	M	RA	60 × 60 × 50	Chest discomfort	Excision and repair	Bovine pericardial patch
38	Wang X	2008	61	F	RA	20 × 25 × 35	Chest pain	Excision and repair	Auto pericardial patch
39	Venturini E	2008	71	F	RA	72 × 62	Asymptomatic	Excision and repair	Patch of Dacron
40	Jo SH	2008	40	F	RA	80	Weakness	Resection	—
41	Fitzsimons B	2008	35	M	LA	25 × 27	Palpitations, substernal	Resection	—
42	Huang CL	2008	46	F	RA	79.8 × 57	Syncope	Resection + pacemaker implant	—
43	Abad C	2008	76	F	LA	20 × 20	Dyspnea	Resection	—
44	Thung KH	2008	57	M	RA	40	Cerebellar stroke	Resection	—
45	Safirstein J	2007	57	M	RA	50 × 60	OSA	Resection	—
46	Alpesh AP	2007	50	M	RA	25 × 35	Atrial fibrillation	Resection	—
47	Solum AM	2007	43	M	LA	86 × 40 × 70	Weakness, dyspnea	Excision and repair	Bovine pericardial patch
48	Esmailzadeh M	2007	6 D	—	RA	20 × 15 × 10	Asymptomatic	Excision and repair	Xeno pericardial patch
49	Laga S	2006	40	F	LA	35 × 35	Chest discomfort	Excision and repair	Auto pericardial patch
50	Langer C	2006	65	F	RA	40 × 30	Chest pain, dyspnea	Resection	—
51	Perk G	2005	49	F	RA	60 × 60	Dyspnea	Resection	—
52	Sebastian V	2005	1 D	NA	RA	23.5 × 25	Asymptomatic	Partly resection	—
53	Ramasubbu K	2005	41	M	LA	46 × 29 × 39	Chest pain	Excision and repair	Auto pericardial patch
54	Mehmood F	2005	66	M	LA	30 × 15	Exertional, dyspnea	Resection	—
55	Gersak B	2005	46	M	LA	31 × 22	Hypertension	Resection	—
56	Thomas JE	2004	50	M	RA	20 × 10 × 10	Asymptomatic	Resection	—
57	Sata N	2004	72	F	LA	45 × 45	Dyspnea, chest pain	Resection	—
58	Kojima S	2003	60	F	RA	30 × 18 × 15	Asymptomatic	Resection	—
59	Oshima H	2003	70	F	LA	45 × 36	Asymptomatic	Resection	—
60	Orlandi A	2003	75	F	RA	40 × 50 × 35	Dyspnea, cough	Excision and repair	Auto pericardial patch
61	Wang HJ	2002	39	M	RA	60 × 40 × 30	Dyspnea	Resection	—
62	Lo LJ	2002	50	F	LA	80 × 50 × 40	Shortness of breath	Resection	—
63	Lev-Ran O	2000	80	F	RA	80 × 60	Atrial fibrillation	Resection	—
64	Eckstein FS	1999	34 W	NA	RA	25	Asymptomatic	Excision and repair	Auto pericardial patch
65	Pigato JB	1998	74	F	LA	100	Shortness of breath	Resection	—
66	Yamaguchi M	1998	58	M	RA	NA	Chest discomfort	Resection	—
67	Hangler HB	1997	58	F	RA	75	Retrosternal pain	Resection	—

F: female; M: male; RA: right atrium; LA: left atrium; NA: not available; Y: years; M: months; W: weeks; D: days; CABG: coronary artery bypass graft; OSA: obstructive sleep apnea syndrome

intensity in T2-weighted images was also important for the diagnosis of atrial hemangioma.

Coronary angiography can detect tumor blush sign in 22 cases, accounting for 59.5% of all 37 cases, which is significantly lower than 80% reported previously.<sup>8)</sup> Eighteen cases provided detailed information of feeding vessels, including right coronary artery (10 cases, 55.6%), left circumflex artery (4 cases, 22.2%), right coronary artery and left circumflex artery (1 case, 5.6%), left anterior descending artery (2 cases, 11.1%), and left main coronary artery (1 case, 5.6%).

Positron emission tomography (PET)-CT can make a further diagnosis of atrial hemangiomas. We found three case reports involving application of PET-CT. All manifested as hypermetabolic area without any mediastinal tracer enrichment ruling out malignancies.

An operation is necessary for treatment. In all, 63 patients had complete resection of hemangiomas and 2 patients had partial resection of the hemangiomas due to extensive invasion of heart. Among them, 39 patients had simple resection of the atrial hemangiomas, 23 patients had resection and repair, 2 cases had resection and coronary artery bypass graft, and 1 case had a resection and pacemaker implantation.

After atrial hemangioma resection, atrial defect reconstruction was performed using auto pericardium patch. Other patches included bovine pericardium patch, pig pericardial patch, horse pericardial patch, and artificial biomaterials. In our results, 12 cases were treated with auto pericardium patch. Among them, 5 cases were a bovine pericardial patch, 1 case was horse pericardial patch, 1 case was porcine bladder patch, and 2 cases were an artificial patch.

Based on our study, we found that the cure rate of surgical resection was 98.5% (64/65), and only one patient died for recurrent epicardial complications. In all, 22 patients had complete follow-up information and follow-up time which varied from 1 month to 13 years, and an average time was 19.1 months. The patients' symptoms improved significantly after surgery. Only one patient with atrial hemangiomas had the operation again in 10 years after the surgery due to recurrence.<sup>9)</sup>

## Discussion

Cardiac hemangioma mainly originated from the abnormal hyperplasia or dilatation of small arterioles, venules and capillaries.<sup>10)</sup> About 75%–94% of the

primary heart tumors are benign, such as myxoma, hemangiomas, fibroma, and so on. Among them, one of the rarest is the hemangioma, with an incidence of 1%–2% of primary cardiac tumors. In 1950, Hochberg and Robinson first removed the cardiac hemangioma in the world.<sup>11)</sup>

## Clinical Manifestation

We speculated that the symptoms of an atrial hemangioma mainly depended on the age of the patient, the size and growth rate of the tumor, and myocardial or pericardial infiltration. And the effects of atrial hemangiomas on the cardiac hemodynamics, heart valves, coronary vessels, and heart conduction systems and the aggression or compression of adjacent tissues and organs (such as the trachea, esophagus) of hemangiomas will result in multiple clinical manifestations. In addition, these patients may also experience some circulatory and respiratory manifestations, such as respiratory apnea syndrome,<sup>12)</sup> cerebral stroke symptoms, and so on.<sup>13)</sup> The hemangiomas of the heart are often concomitant with hepatic, skin,<sup>14)</sup> pleural,<sup>15)</sup> or pulmonary<sup>16)</sup> hemangiomas. Therefore, for patients with clinical findings of atrial hemangioma, we recommend a systemic examination to determine whether other hemangioma lesions exist.

## Imaging Examination

Imaging is a useful tool in the preoperative screening and diagnosis of atrial hemangiomas and is mainly used to evaluate the size, lesion, morphology, its relation with surrounding structure, and the possibility of surgical resection.<sup>17)</sup>

Electronic cardiogram is one of the general clinical examination for the heart. Among the information we have collected, a total of 18 patients had descriptions of ECG, but no description of underlying disease was obtained except for four patients with nonspecific S-T and T wave changes undergoing coronary angiography and none of them showed significant coronary stenosis. After atrial hemangioma resection, no significant improvement in ECG was found in the patients with S-T and T-wave abnormalities before. Due to insufficient information about underlying disease and data about ECG changes after surgery, we were unable to determine whether ECG changes were caused by atrial hemangioma or surgical resection. According to our research and previous

studies,<sup>18)</sup> the patients with atrial hemangioma have no specific ECG findings.

Echocardiography is the best imaging technique for atrial hemangiomas. Portable echo, especially pocket-sized echo, is flexible, compact, and convenient, especially for patients with emergency admission, out of action or in the serious conditions.<sup>19)</sup> By bedside cardiac ultrasound, we can quickly assess cardiac structural and functional abnormalities and make a diagnosis as early as possible to determine the atrial tumor.<sup>20)</sup> Routine two-dimensional echocardiography can determine the size, location, activity, and compression of the tumor. It most commonly appears as “homogeneous solid tumor signs” in two-dimensional echocardiography. The features of cardiac tumor manifest as clear boundaries, regular figures, and uniform density. In addition, a moderate echo and a mass that can oscillate with the cardiac cycle are observed. Color Doppler echocardiography detects blood flow signals in the tumor which are often accompanied by an enlargement of the heart chamber, valve insufficiency, and different degrees of valve regurgitation.<sup>21)</sup>

It is worth noting that due to the lack of three-dimensionality, two-dimensional echocardiography often mistakes the bulge caused by compression of the extraluminal mass on the heart muscle as an intracardiac mass. However, three-dimensional echocardiography can overcome this shortcoming and has a better display of tumors in some complex locations. Note that only one patient performed preoperative three-dimensional echocardiography in our results, indicating that many clinicians still have not noticed the advantages of three-dimensional echocardiography in the diagnosis of atrial hemangioma. Three-dimensional echocardiography can not only determine the tumor structure but also observe intratumoral vascular aggregation and complete intratumoral multi-echoes contrast, thus providing more detailed preoperative evaluation.

Atrial hemangioma is characterized by low density or equal density on CT and could manifest as localized high-density shadows due to hemangioma fibers or calcification. CT scan can show the size, the location of hemangiomas, and the relationship with surrounding tissues, and can exclude extracardiac metastases of cancer.<sup>22)</sup> The typical manifestation of atrial hemangiomas on contrast-enhanced CT is that after intravenous injection of contrast agent, the central region of the hemangiomas does not be enhanced immediately, but it

has delayed enhancement to the same degree as the blood pool. Through the “virtual removal” and other image post-processing techniques, cardiac volumetric CT imaging of atrial hemangioma can be performed to preliminarily assess the anatomy of hemangioma.<sup>23)</sup>

The manifestation on MRI correlates with “avid first-pass enhancement” which is caused by the highly vascularized structure within the hemangiomas and the slower internal blood flow rate.<sup>24)</sup> Typically, atrial hemangioma shows intermediate and equal signal intensity in T1 and high signal intensity in T2-weighted images compared with myocardium, respectively.<sup>24)</sup> Nuclear magnetic resonance free state stability sequences can also assess the mobility of tumors.<sup>24)</sup> By combining the MRI sequence, it is possible to identify the histology characteristics of the hemangioma, which is very significant for the patient’s prognosis and follow-up treatment.

In 1976, Daniel S. diagnosed cardiac hemangioma using coronary angiography for the first time.<sup>25)</sup> Due to multiple coronary artery branches supplying for atrial hemangioma, tumor blush is a typical sign of atrial hemangioma. Nearly 60% of patients undergoing coronary angiography have typical tumor blush sign in the article. The different sign of atrial hemangioma resulted from some factors such as the origin of the blood vessels supplying for the hemangioma, the degree of vascularization in the tumor, and the blood flow rate. Currently, coronary angiography is mainly used in patients with atrial hemangioma to evaluate the presence of feeding vessels and its extent, and the degree of vascularization in the tumor, which provides preoperative evaluation of coronary arteries conditions to exclude obstructive coronary artery disease for the diagnosis of atrial hemangioma and provide the reference for further surgical resection.

The features of PET-CT imaging of atrial hemangiomas are “abnormal aggregation of focal radioactivity distribution.” The uptake of fluorodeoxyglucose (FDG) of hemangiomas in PET-CT mainly depends on the retention of FDG in intratumoral vessels.<sup>26)</sup> Therefore, PET-CT could offer the advantage of differentiating benign atrial hemangioma from malignant tumors according to the level of FDG uptake and metabolism of the cardiac mass.

## Diagnosis and Differential Diagnosis

The diagnosis of cardiac hemangioma mainly depends on imaging features. Histopathologic examination is

essential for a final diagnosis.<sup>27)</sup> The most common type of cardiac tumor is the secondary tumor, and primary tumor only accounts for a small proportion. Myxoma is the most common and accounts for half of all primary cardiac tumors. Other common primary cardiac tumors include papillary fibroelastomas, rhabdomyomas, fibroids, hemangiomas, and lipomas. Preoperative misdiagnosis for cardiac hemangiomas was common in 65.9% of cases.<sup>1)</sup> Therefore, an accurate diagnosis is primarily concerned with the patient's further treatment plan and prognosis of the patients. The clinical manifestations of cardiac tumors differ according to the tumor location, size, growth rate, embolism, and invasiveness. Distinct types of cardiac tumors have no significant specificity on the clinical manifestations. Thus, it is difficult to distinguish cardiac hemangiomas from other types of cardiac tumors by clinical manifestations. Differential diagnosis between hemangiomas and other heart tumors is conducted only by imaging analysis for preliminary identification.

Myxoma is the most common primary cardiac tumor, which was detected predominantly in adult females. Cardiac myxoma tends to occur in the left atrium.<sup>28)</sup> Most often, myxoma originates from the interatrial septum which is closed to the fossa ovalis and the occurrence shows a familial hereditary tendency. Imaging of myxoma manifests as lobulated spherical or oval tumors adhering to the endocardial surface with soft texture and high mobility.

Cardiac papillary fibroelastoma is more common in elderly men, with the average age of 60 years old.<sup>29)</sup> About 90% of papillary fibroelastomas occur in heart valves, especially aortic valves, and they are the most common primary tumors of heart valves. The typical radiographic appearance is a tumor with a diameter of less than 1 cm, which is pedunculated and attached to the endocardial surface and can oscillate with the cardiac cycle.

Rhabdomyosarcoma is more common in young children which are less than 1-year old.<sup>30)</sup> Rhabdomyosarcoma originates from the myocardium and grows into the heart cavity. The typical imaging manifestation is cardiac hypertrophy and 25% of patients imaging can find intratumoral calcification.

Lipoma frequently occurs in adults. Histological manifestation is a spherical or oval yellow mass with smooth surface and capsule, and the mass is relatively fixed. CT and MRI scan mostly manifested as fat density.<sup>31)</sup>

## Treatments

Currently, major treatment options for atrial hemangiomas include corticosteroids,  $\beta$ -blockers, interferon- $\alpha$ , anticancer drugs (vincristine, cyclophosphamide), radiation therapy, and surgical resection.

Glucocorticoids are the main means of treating extensive hemangiomas in the past few decades. And only about 16% of hemangioma patients do not respond to glucocorticoid therapy.<sup>32)</sup> However, the specific mechanism of glucocorticoid to treat the hemangiomas is still not clear.

Beta-receptor blockers play an important role in the treatment of hemangiomas. Many medical centers have replaced glucocorticoids for propranolol as first-line agents to treat hemangiomas. Propranolol works by antagonizing  $\beta_2$  adrenergic receptors to promote vasoconstriction, inhibit angiogenesis, and induce apoptosis.<sup>33)</sup> In terms of clinical cases, Velthuis successfully used  $\beta$ -blockers to reduce the volume of hemangiomas in a patient with ventricular hemangiomas,<sup>34)</sup> but the same therapy had no significant effect on Christian Brizard's patients.<sup>8)</sup>

Interferon- $\alpha$  inhibits angiogenesis by suppressing the proliferation of epithelial cells and fibroblasts, and contributes to the reduction of hemangioma.<sup>35)</sup> Ezekowitz et al. reported 20 cases of hemangiomas who was treated with interferon- $\alpha$ . Among them, 18 patients with atrial hemangioma received an average of 7–8 months' treatment with interferon- $\alpha$ , which took effect eventually. The average tumor size was reduced by more than 50% and the mass in patients completely subsided.

Clinically, vincristine, cyclophosphamide, bevacizumab, and rapamycin are also commonly used anticancer drugs for the treatment of hemangiomas. The use of these drugs can reduce the dose of glucocorticoids, even contribute to glucocorticoids withdrawal, and then mitigate the related side effects of hormone therapy.<sup>36)</sup>

For radiotherapy, Yoshikawa reported the use of X-ray radiotherapy to cure a 10-week-old patient with atrial hemangioma who could not be surgically resected. And symptom remission was not observed after follow-up for 3 years.<sup>37)</sup>

The natural history of atrial hemangiomas is unpredictable, thus surgical resection is mainly chosen for the patients with clinical symptoms. For patients with clinical symptoms, whether patients have surgery or not depends generally on severity of their symptoms, age, and general physical condition. The feasibility of surgery



was judged mainly by considering the size, attachment site, and growth rate of the atrial hemangiomas.<sup>38)</sup> And the relationship between atrial hemangiomas and the heart conduction system and the coronary arteries may bring difficulties to surgery.

By the surgical operation, we can find the margin of hemangioma tissue that varies from different types. According to tumor location, heart hemangioma may be an intramyocardial or endocardial tumor. Intramural hemangiomas are often poorly circumscribed, spongy masses that appear variably hemorrhagic or congested. In contrast, endocardial hemangiomas are well-circumscribed, variably myxoid, soft masses.<sup>39)</sup> Although only one patient was found a recurrence after surgical treatment in our study, we still recommend expanded resection of atrial hemangioma, if the tumor does not exist in a critical region, such as cardiac conduction system or coronary artery.

In 2009, Sheffield successfully treated a patient by autologous heart transplantation who had a large atrial hemangioma by preoperative evaluation and could not be resected in situ. During operation, autologous heart transplantation was used to remove the tumor and reconstruct the defective atrium. The major surgical procedures included that splitting the center of sternum and opening the pericardium, exploring the tumor, establishing an extracorporeal circulation, exposing the tumor and removing the heart; then removing the atrial hemangioma and the adjacent tissues which was 0.5 cm from the edge of tumor; using a bovine pericardial patch and a 4-0 polypropylene suture to repair the atrial defect, and finally implanting the heart into the chest. The entire operation was successful and the patient was discharged on the 12th day after surgery.<sup>40)</sup> The application of autologous heart transplantation in other cardiac tumor resections has been relatively common, especially for patients with large tumors and complicated anatomy of heart tumors.<sup>41)</sup> The surgical procedures will provide the surgeons with a wide range of intraoperative views and a new surgical approach to patients who are unable to undergo resection and repairment of the hemangiomas in situ.

For young patients with clinical or asymptomatic atrial hemangioma, if there are no obvious surgical contraindications, surgical resection is feasible. For the patients with huge atrial hemangioma which is difficult to remove, autologous heart transplantation can be used. For asymptomatic elderly patients, the benefit of surgery is difficult to assess. It is recommended to follow-up closely and if the volume of atrial hemangioma increases

significantly in the short term, or obviously clinical symptoms appear, surgical resection is also considered to be performed. The surgical methods for atrial hemangiomas include tumor resection, defect reconstruction, and heart transplantation. The purposes of surgery include the removal of tumors, relief of symptoms, improvement of life and treatment, making pathological diagnosis and excluding malignant tumor, reducing the potential risk, such as embolism and rupture hemorrhage leading to sudden death and relieving the psychological burden on patients.

## Prognosis

In addition to common complications of open heart surgery such as valve regurgitation and conduction disturbances, cardiac fistula is a rare but potential complication that occurs most often when the supply of blood vessels to the hemangiomas has not been accurately ligated.<sup>24)</sup>

After a complete resection, the recurrence rate is generally low, and a partial resection of the hemangiomas may be beneficial to improve long-term survival.<sup>42)</sup> Hoffmeier proposed that a 5-year survival rate of benign tumors in heart was 83% and a 10-year survival rate was 75%.<sup>43)</sup> In our data, patients showed no sign of recurrence in 2 years following the surgery. Therefore, long-term and regular follow-up after surgery is still very important for patients with atrial hemangioma.

One limitation of prognosis data is that we only collected cases of atrial hemangioma but ventricular hemangioma data were not included in the study, so we failed to conduct comparative analysis between the prognosis of two hemangiomas. And up to now, we have not acquired detailed information about follow-up data, including the case we reported in this article. Therefore, we cannot determine whether and when the tumor recurrence occurs.

## Conclusion

Atrial hemangioma is a rare solid tumor of the heart that occurs in the middle-aged and elderly population. Atrial hemangioma has no specific clinical symptoms, which mainly manifests as some cardiopulmonary symptoms, and was accidentally found by physical examination. Echocardiography, multi-slice spiral CT, MRI, coronary angiography, and PET-CT could contribute to the diagnosis of this disease, but the final diagnosis still

depends on histopathologic examination. In terms of treatment, for patients with obvious clinical symptoms, drug, radiation, and surgical resection should be selected based on the general physical condition of the patient, the anatomical site of the lesion and other factors. Surgery has the best therapeutic effect on atrial hemangioma with low recurrence rates and the symptoms of patients were improved evidently or completely relieved. For asymptomatic patients with atrial hemangioma, the best treatment option has not yet been determined. Given the potential effect of atrial hemangioma on the occurrence thrombosis or embolism, surgical treatment should be recommended as soon as possible if there are no contraindications.

## Acknowledgment

We thank Yiyang Peng for his linguistic assistance during the preparation of this manuscript.

## Disclosure Statement

The authors report no conflict of interest regarding the content herein.

## References

- 1) Cina SJ, Smialek JE, Burke AP, et al. Primary cardiac tumors causing sudden death: a review of the literature. *Am J Forensic Med Pathol* 1996; **17**: 271-81.
- 2) Sulayman R, Cassels DE. Myocardial coronary hemangiomas in children. *Chest* 1975; **68**: 113-5.
- 3) Uğraş S. Cavernous haemangioma of the mitral valve in a child: report of a case and review of the literature. *Pathology* 2005; **37**: 396-398.
- 4) Liu Y, Maureira P, Selton-Suty C, et al. Small cardiac hemangioma: a challenge for diagnosis and dilemma for management. *Ann Thorac Surg* 2014; **97**: e11-3.
- 5) Abad C, de Varona S, Limeres MA, et al. Resection of a left atrial hemangioma. Report of a case and overview of the literature on resected cardiac hemangiomas. *Tex Heart Inst J* 2008; **35**: 69-72.
- 6) Li W, Teng P, Xu H, et al. Cardiac hemangioma: a comprehensive analysis of 200 cases. *Ann Thorac Surg* 2015; **99**: 2246-52.
- 7) Zanati SG, Hueb JC, Cogni AL, et al. Cardiac hemangioma of the right atrium. *Eur J Echocardiogr* 2008; **9**: 52-3.
- 8) Brizard C, Latremouille C, Jebara VA, et al. Cardiac hemangiomas. *Ann Thorac Surg* 1993; **56**: 390-4.
- 9) Colli A, Budillon AM, DeCicco G, et al. Recurrence of a right ventricular hemangioma. *J Thorac Cardiovasc Surg* 2003; **126**: 881-3.
- 10) Mulliken JB, Glowacki J. Hemangiomas and vascular malformations in infants and children: a classification based on endothelial characteristics. *Plast Reconstr Surg* 1982; **69**: 412-22.
- 11) Hochberg L, Robinson A. Primary tumor of the pericardium involving the myocardium: surgical removal. *Circulation* 1950; **1**: 805-8.
- 12) Thung KH, Wan IY, Yip G, et al. Cardiac tumor masquerading as obstructive sleep apnea syndrome. *Interact Cardiovasc Thorac Surg* 2008; **7**: 358-9.
- 13) Pasquino S, Balucani C, di Bella I, et al. Cardiac hemangioma of the right atrium: a possible cause of cerebellar stroke. *Cerebrovasc Dis* 2007; **24**: 154-5.
- 14) Weston CF, Hayward MW, Seymour RM, et al. Cardiac haemangioma associated with a facial port-wine stain and recurrent atrial tachycardia. *Eur Heart J* 1988; **9**: 668-71.
- 15) Wender C, Acker JE. Constrictive pericarditis associated with hemangioma of the pericardium. *Am Heart J* 1966; **72**: 255-8.
- 16) Yang L, Dai J, Xiao Y, et al. Cardiac cavernous hemangioma and multiple pulmonary cavernous hemangiomas. *Ann Thorac Surg* 2014; **97**: 687-9.
- 17) González López MT, Aranda Granados PJ, Delange Segura L, et al. An unexpected left atrial cavernous hemangioma: the cardiac surgeon needs an optimal preoperative study! *Interact Cardiovasc Thorac Surg* 2011; **13**: 529-53.
- 18) Wang Y, Liu S, Yang J, et al. Cardiac hemangioma caused ventricular arrhythmia: a rare case and literature review. *J Electrocardiol* 2017; **50**: 667-70.
- 19) Colclough A, Nihoyannopoulos P. Pocket-sized point-of-care cardiac ultrasound devices: role in the emergency department. *Herz* 2017; **42**: 255-61.
- 20) Tsai BT, Dahms EB, Waalen J, et al. Actual use of pocket-sized ultrasound devices for cardiovascular examination by trained physicians during a hospitalist rotation. *J Community Hosp Intern Med Perspect* 2016; **6**: 33358.
- 21) De Filippo M, Corradi D, Nicolini F, et al. Hemangioma of the right atrium: imaging and pathology. *Cardiovasc Pathol* 2010; **19**: 121-4.
- 22) Szymanski FM, Marchel M, Platek AE, et al. Atrial fibrillation as a first clinical manifestation of right atrial cavernous haemangioma. *Acta Cardiol* 2013; **68**: 197-9.
- 23) Olivotti L, Botta L, Gandolfo A, et al. Coronary and atrial compression by a giant cardiac hemangioma. *Cardiovasc Pathol* 2014; **23**: 366-8.
- 24) Sánchez-Enrique C, Vivas D, Carnero Alcázar M, et al. Giant right atrial hemangioma: correlation between magnetic resonance imaging and histopathologic evaluation. *J Thorac Cardiovasc Surg* 2015; **150**: e51-3.
- 25) Raabe DS, Fischer JC, Brandt RL. Cavernous hemangioma of the right atrium: presumptive diagnosis by coronary angiography. *Cathet Cardiovasc Diagn* 1976; **2**: 389-95.

- 26) Hatayama K, Watanabe H, Ahmed AR, et al. Evaluation of hemangioma by positron emission tomography: role in a multimodality approach. *J Comput Assist Tomogr* 2003; **27**: 70-7.
- 27) Orlandi A, Ferlosio A, Pellegrino A, et al. Right atrial hemangioma: clinicopathological considerations of a case. *Interact Cardiovasc Thorac Surg* 2003; **2**: 38-9.
- 28) Irani AD, Estrera AL, Buja LM, et al. Biatrial myxoma: a case report and review of the literature. *J Card Surg* 2008; **23**: 385-90.
- 29) Gowda RM, Khan IA, Nair CK, et al. Cardiac papillary fibroelastoma: a comprehensive analysis of 725 cases. *Am Heart J* 2003; **146**: 404(3)r.
- 30) Córdoba Rovira SM, Inarejos Clemente EJ. Childhood rhabdomyosarcoma. *Radiologia* 2016; **58**: 481-90.
- 31) D'Souza J, Shah R, Abbass A, et al. Invasive cardiac lipoma: a case report and review of literature. *BMC Cardiovasc Disord* 2017; **17**: 28.
- 32) George ME, Sharma V, Jacobson J, et al. Adverse effects of systemic glucocorticosteroid therapy in infants with hemangiomas. *Arch Dermatol* 2004; **140**: 963-9.
- 33) Lawley LP, Siegfried E, Todd JL. Propranolol treatment for hemangioma of infancy: risks and recommendations. *Pediatr Dermatol* 2009; **26**: 610-4.
- 34) Velthuis BO, van Es J, van Houwelingen G, et al. Extensive left ventricular hemangioma. *J Am Coll Cardiol* 2012; **60**: e35.
- 35) Wilson MW, Hoehn ME, Haik BG, et al. Low-dose cyclophosphamide and interferon alfa 2a for the treatment of capillary hemangioma of the orbit. *Ophthalmology* 2007; **114**: 1007-11.
- 36) Wasserman JD, Mahant S, Carcao M, et al. Vincristine for successful treatment of steroid-dependent infantile hemangiomas. *Pediatrics* 2015; **135**: e1501-5.
- 37) Yoshikawa M, Hayashi T, Sato T, et al. A case of pericardial hemangioma with consumption coagulopathy cured by radiotherapy. *Pediatr Radiol* 1987; **17**: 149-50.
- 38) Nakamura E, Nakamura K, Furukawa K, et al. A giant cardiac cavernous hemangioma involving the left atrial roof in an elderly woman. *Ann Thorac Cardiovasc Surg* 2018; 17-00125.
- 39) Burke A, Johns JP, Virmani R. Hemangiomas of the heart. A clinicopathologic study of ten cases. *Am J Cardiovasc Pathol* 1990; **3**: 283-90.
- 40) Novitzky D, Guglin M, Sheffield C. Cardiac autotransplantation for removal of left atrial hemangioma and a review of the literature. *Heart Surg Forum* 2009; **12**: E279-84.
- 41) Reardon MJ, Malaisrie SC, Walkes JC, et al. Cardiac autotransplantation for primary cardiac tumors. *Ann Thorac Surg* 2006; **82**: 645-50.
- 42) Takahashi A, Sakurai M, Fujikawa T. Resection of a giant cardiac hemangioma. *Gen Thorac Cardiovasc Surg* 2013; **61**: 353-5.
- 43) Hoffmeier A, Sindermann JR, Scheld HH, et al. Cardiac tumors—diagnosis and surgical treatment. *Dtsch Arztebl Int* 2014; **111**: 205-11.