

Hemifacial hypertrophy: Exploring new avenues of treatment modalities

Department of Oral and Maxillofacial Surgery, Vokkaligara Sangha Dental College and Hospital, Bengaluru, Karnataka, India

Santosh Ashok Nandimath, G. C. Rajkumar, Tulasi Nayak, D. P. Ashwin, K. B. Rudresh, R. Prashanth

ABSTRACT

Address for correspondence:
Dr. Santosh Ashok Nandimath,
Department of Oral and Maxillofacial Surgery, Vokkaligara Sangha Dental College and Hospital, K.R. Road, V.V. Puram, Bengaluru - 560 004, Karnataka, India.
E-mail: drsantosh_n@yahoo.co.in

Congenital hemihyperplasia is a rare developmental disorder characterized by unilateral overgrowth of one or more body parts resulting in marked asymmetry. We are reporting here, a case of true hemifacial hypertrophy in a young female adult highlighting the clinical features and possible treatment options.

Key words: Deoxycholate, hemihypertrophy, phosphatidylcholine, syndrome

INTRODUCTION

"Beauty depends on size as well as symmetry"

-Aristotle

Symmetry is an important concept in biology, being related to health, mate selection strategies, and ultimately the survival of the species. While deviations from symmetry are critical perceptual units in detecting the appearance of health, the natural subtle asymmetry of the human face may be relatively unimportant for judging facial attractiveness.^[1] A grossly perceptible asymmetry of the face, however, as seen in hemifacial hypertrophy can be highly disconcerting to the patient. The treatment of this condition is unpredictable with an uncertain prognosis and remote chances of patient satisfaction.

We have reported a case of true hemifacial hypertrophy in a young female adult and attempted to summarize the possible treatment alternatives to the conventional surgical treatment.

CASE REPORT


A 23-year-old female patient presented to the Department of Oral and Maxillofacial Surgery with a chief complaint of asymmetry of her face. She gave a history of an abnormally enlarged left half of her face since birth which became more prominent following menarche. The patient had visited multiple plastic surgery units since childhood and had been diagnosed with hemihypertrophy [Figure 1]. However, no genetic studies had been carried out to confirm the diagnosis. She was under a regular follow-up regimen by her GP to look for developing cancers.

The patient was born at full term from a nonconsanguineous marriage. The patient was of normal built and intelligence. There was no history of such complaints in the family and serum chemistry revealed no abnormalities. The swelling was diffuse, soft, and extended from the frontal bone to the lower border of the mandible on the left side. The zygomatic

This is an open access article distributed under the terms of the Creative Commons Attribution-NonCommercial-ShareAlike 3.0 License, which allows others to remix, tweak, and build upon the work non-commercially, as long as the author is credited and the new creations are licensed under the identical terms.

For reprints contact: reprints@medknow.com

How to cite this article: Nandimath SA, Rajkumar GC, Nayak T, Ashwin DP, Rudresh KB, Prashanth R. Hemifacial hypertrophy: Exploring new avenues of treatment modalities. Natl J Maxillofac Surg 2016;7:100-4.

Access this article online	
Quick Response Code: 	Website: www.njms.in
	DOI: 10.4103/0975-5950.196123

root was enlarged on palpation [Figures 2 and 3]. Mouth opening and the range of movement was adequate. The left half of the hard palate was enlarged with a normal complement of teeth in the maxillary arch. The molars in the mandibular arch had been extracted at an earlier date due to caries. Three soft growths were present; at the lower labial mucosa, the buccal mucosa, and the retromolar area. An excisional biopsy of the growth at the left buccal mucosa was found to be lipomatous in origin. Body measurements were done from the midline, and no other asymmetry was present.

Panoramic radiograph showed that the left palate, mandibular body, ramus, condyle, and coronoid were asymmetrically enlarged. No other physical abnormality was noted. The computed tomography showed uniform bony enlargement of the left half of the face including the frontal bone [Figure 4]. The soft tissue window showed an enlarged radiolucency suggestive of a lipomatous enlargement. Based on the clinical and radiographic features, the patient was provisionally diagnosed with true hemifacial hypertrophy of the left face.

The patient had been informed of the possible treatment options including extensive surgery for hard and soft tissue debulking and more conservative options for only soft tissue recontouring. She had been informed that irrespective of the treatment done, it would not be possible to achieve complete symmetry. The patient, however, was adamant and wished for treatment only if complete symmetry could be achieved.

DISCUSSION

Congenital hemihypertrophy or partial gigantism was first described by Meckel in 1822 and gained widespread recognition after Gesell's classic description as "essentially a developmental deflection of the normal process of birth."^[2,3]

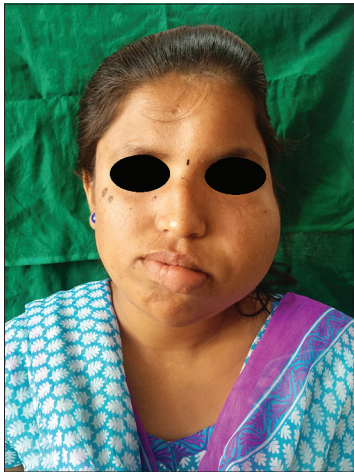

Figure 1: Frontal view

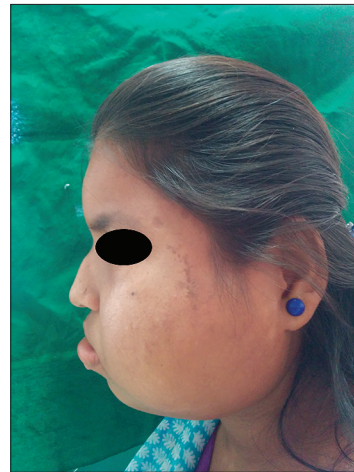

Figure 2: Profile view

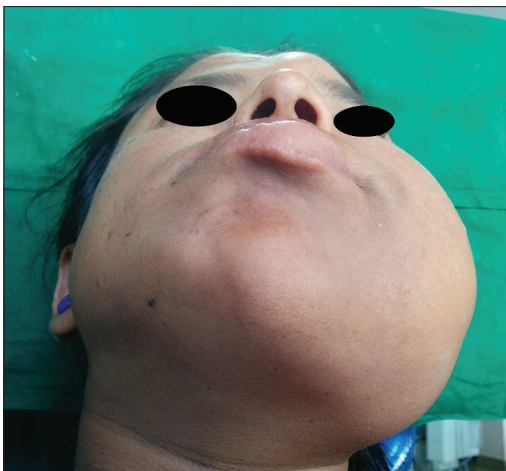

Figure 3: Waters view

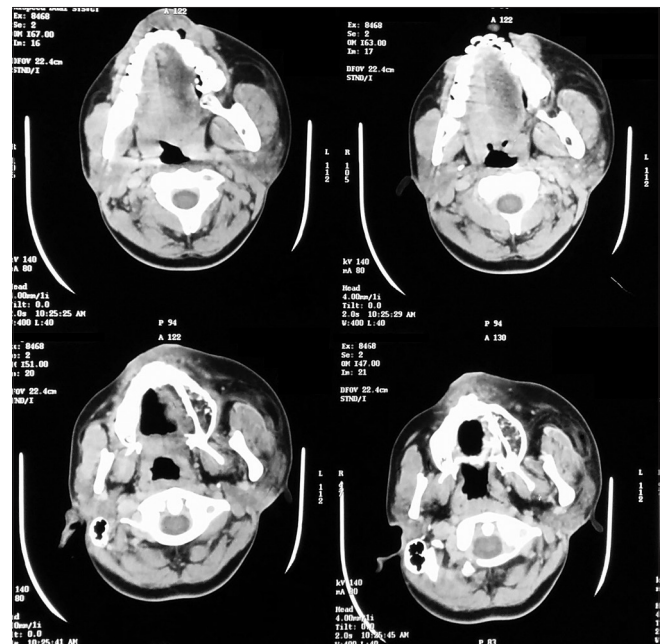


Figure 4: Axial section computed tomography scan

Hemihypertrophy or hemihyperplasia may be an isolated finding, or it may be associated with other syndromes such as Beckwith–Wiedemann, Proteus syndrome, Von Recklinghausen’s neurofibromatosis, Klippel–Trenaunay–Weber, and McCune–Albright syndromes.^[4-7] Idiopathic hemihyperplasia is associated with mild cognitive disability, genitourinary anomalies, and a high association with Wilm’s tumor. Our case showed the presence of only an enlarged half of the face with no other part of the body exhibiting asymmetry. The criteria for the hemifacial type as specified by Rowe includes unilateral enlargement of the viscerocranium, limited superiorly to the frontal bone (not including the eye), the lower border of the mandible inferiorly, the mid-line of the face medially, the ear, the pinna being included within the hypertrophic area laterally and enlargement of all tissues - teeth, bone, and soft tissues within this area [Table 1].^[8]

While Khanna and Andrade,^[2] noted that a relative disproportion is maintained due to the proportional growth of the normal and the abnormal sides,^[2] Arora *et al.*^[9] observed that the asymmetry becomes accentuated with age. In this case, the asymmetry was detected at birth but became more apparent as the affected part enlarged at a greater rate than the rest of the body, most noticeably at the onset of menarche. Our case, similar to previous case reports^[9,10] revealed lipomatosis as the dominant feature at the abnormal half. The teeth, mandible, and maxilla should be carefully scrutinized for deformities to help one reach the correct diagnosis. This is especially important if only lipomatous overgrowth is seen initially. Hemifacial hypertrophy is classified as true and partial hemihypertrophy. True hemihypertrophy involves not only the soft tissues of the body but the hard tissues as well.^[11]

The prevalence rate of hemifacial hypertrophy is 1:86,000 live births.^[12] No single theory explains the etiology adequately. The professed causes for this condition include inherited chromosomal abnormalities^[13,14] endocrine dysfunctions, vascular or lymphatic malformation, atypical forms of twinning, altered intrauterine environment, and disturbances of the central nervous system^[15,16] Pollock *et al.*^[17] advocated that an enlarged neural tube on one side is responsible for the unilateral increase in size. The growth of the neural tube follows a cephalocaudal gradient of growth and it

reasonable to expect that some tube segments are more involved than others.

Rowe^[8] described abnormalities in the dentition of the abnormal side in three respects; the crown size, the root size and shape, and rate of development. He noted that not all teeth were similarly affected. In the deciduous dentition, the second molar and in the permanent dentition the cuspids were the most commonly affected teeth followed by the first molars and premolars. The enlargement, however, did not exceed 50% over their normal counterpart. It was also interesting to note that the premolars were the most enlarged among the teeth; however, the second molars which develop around the same period are not. Early shedding of deciduous teeth, delayed eruption of permanent teeth, prematurely developed teeth with short roots and congenitally missing teeth were often seen on the affected side. Rowe^[8] described the alveolar bone to be larger and thicker on the affected side with the largest bulk distal to the largest tooth. There was also a propensity for an open bite as both posterior ridges developed exostoses which contacted each other during jaw closure. Radiographically, the mandibular canal may also be increased in size.^[11] Pollock *et al.*^[17] described the buccal mucosa as one which hangs in soft pedunculus folds. The tongue enlargement has also been described to be uniform, beginning abruptly in the midline with excrescences resembling large fungiform papillae.^[17] In the present case, the buccal mucosa on the affected side showed lipomatous growths, the tongue, lip, and palate were uniformly enlarged; however, the teeth appeared to be normal in size, and the patient gave no history of abnormalities during shedding.

To the unfamiliar clinician, this condition can constitute a baffling diagnostic problem. Deformities of the teeth and their related hard tissues in the jaw are key findings for correct diagnosis, particularly in hemihypertrophy limited to the face.^[5]

Treatment modalities

The treatment modalities extend from subtle soft tissue contouring to extensive surgeries to correct the underlying bony defect and reshape the overlying soft tissues. The surgical treatment includes hard and soft tissue surgeries. The hard tissues can be treated by a combination of condylar recontouring, osteotomies, and ostectomies to achieve the required shape, followed by debulking of soft tissues.

Extensive surgical treatment had been performed by Pollock *et al.*^[17] and Khanna and Andrade^[2] who used extra- and intra-oral approaches to the deformed skeleton. Khanna and Andrade^[2] performed extensive surgeries in three stages using a hard and soft tissue

Table 1: Classification of congenital hemihypertrophy by roubeir

Type	Areas involved
Complex hemihypertrophy	The entire half of the body
Simple hemihypertrophy	One or both limbs
Hemifacial hypertrophy	The face, head, and associated structures

debulking to achieve an acceptable result, while Pollock used osteotomies and recontouring to correct the bony deformities. He advocated the treatment of the soft tissue deformity by excision, rhytidectomy, and cheiloplasty. Condylectomy is seldom necessary but had been reported by Trapp.^[17] The occlusal deformities can be corrected by orthodontic therapy.

Even though there have been sporadic reports of acceptable results^[2,17-19] following surgical treatment, dearth of literature, the possibility of aggravating the growth, the difficulties in recontouring an entire half of the face, the uncertainties of how much soft tissue reduction should be done and the possibility of suboptimal postoperative esthetics dissuaded us from approaching the condition in an aggressive surgical manner. We had hence, wished to explore other minimally invasive options.

Soft tissue contouring such as liposuction has been in vogue for decades. The ideal conditions for the use of liposuction are the existence of sufficient elasticity of the skin; little excess skin and sufficient subcutaneous adipose tissue to be suctioned. Liposuction not only allows the flattening of contours but correction of sagging teguments, resulting in some skin retraction.^[18] Conventional liposuction (dry liposuction) was performed without any introduction of fluid. Later, a small amount of fluid was introduced into the fat (wet liposuction). However, the patients frequently required blood transfusions due to blood loss.^[20] Klein^[21] revolutionized liposuction surgery when he developed the tumescent technique that permits large-volume liposuction under local anesthesia without sedation or narcotic analgesics. Tan^[22] in his case report described tumescent liposuction in the treatment of partial hemifacial hypertrophy. He performed the procedure using almost 50 mL of modified Klein solution before the suction and reported positive results. As described by Klein^[21] <1% of the suctioned material in this technique is whole blood. Tumescent liposuction is now regarded as the gold standard method for liposuction.^[20] A number of variations of this technique has been utilized for the face and neck regions. Ultrasound assisted liposuction consist of repetitive expansion and passive contraction of adipocytes, resulting in rupture of their cellular membrane and liquefaction of fat.^[23] There are however chances of contact of the tip of the ultrasonic probe with the under surface of the skin complications such as burns, necrosis and subsequent scarring, nerve injury, and seroma formation. Another system used is the powered lipoplasty (vibroliposuction) by Rebelo;^[24] this involves a reciprocal “to-and-fro” motion of the cannula tip using a pneumatic-driven system. This movement mimics action during traditional suction-assisted liposuction due to which, surgeons experience less fatigue during power liposuction with easier penetration

and removal of adipose tissue. Disadvantages of power liposuction include seroma formation, the creation of larger diameter tunnels (more than the actual cannula size used), swelling and bruising.^[25,26] Recently, new laser systems have stimulated lipolysis by the means of small laser fibers introduced through a small cannula directly into the subcutaneous fat. A confluent red diode aiming beam at the tip of the cannula provides visual guidance through transcutaneous-illumination during treatment. Large volume liposuction may require higher laser energies, increasing the risk of burns and skin necrosis. In addition, this technique is more time consuming, as the surgeon has to move the laser cannula relatively slowly through then skin to allow for necessary time for the laser-tissue interaction and a second pass with a suction cannula is necessary for fat aspiration.^[27,28]

Phosphatidylcholine preparations have been used internationally for localized reduction of subcutaneous fat deposits. Phosphatidylcholine is safe and nontoxic with no significant acute or chronic toxicity, mutagenicity or teratogenicity.^[29] Although phosphatidylcholine is the main ingredient in most injectable preparations, it must be mixed with sodium deoxycholate (a bile salt) to make it soluble enough for injection.^[29] Once injected into the subcutaneous tissue, the chain reaction continues over a period of 8–10 weeks. Peckitt^[30] demonstrated the destabilization of the adipocyte cell membrane following injection of a critical concentration of phosphatidylcholine. This change in the physical properties of the cell membrane then appears to cause a complex enzymatic cascade involving the release of lipases and other enzymes as well as a rapid apoptotic cascade that causes adipocyte cell death. If the critical concentration is not reached, the unstable cell membrane forms gaps or pores, allowing efflux of some of the cytoplasmic contents.^[29] Despite the temporary side effects that cause a degree of discomfort, phosphatidylcholine injections can be used successfully in the treatment of localized and small fatty areas of the face, as it requires a few injections and <1 vial. Injection of phosphatidylcholine seems to be a better, safer, and more cost-effective treatment than liposuction in these specific cases.

CONCLUSION

Modern technology and understanding of human physiology have revolutionized treatment modalities. However, rare conditions like hemifacial hypertrophy are ill understood, and the possibility of achieving perfect symmetry in these cases is a herculean task. We feel that safer, conservative and cost effective options such as liposuction and subcutaneous injections of phosphatidylcholine must be done, especially so in cases where the surgical treatment would be deemed too

extensive and not without the possibility of unsatisfactory outcomes.

Declaration of patient consent

The authors certify that they have obtained all appropriate patient consent forms. In the form the patient(s) has/have given his/her/their consent for his/her/their images and other clinical information to be reported in the journal. The patients understand that their names and initials will not be published and due efforts will be made to conceal their identity, but anonymity cannot be guaranteed.

Financial support and sponsorship

Nil.

Conflicts of interest

There are no conflicts of interest.

REFERENCES

- Zaidel DW, Aarde SM, Baig K. Appearance of symmetry, beauty, and health in human faces. *Brain Cogn* 2005;57:261-3.
- Khanna JN, Andrade NN. Hemifacial hypertrophy. Report of two cases. *Int J Oral Maxillofac Surg* 1989;18:294-7.
- Nayak R, Baliga MS. Crossed hemifacial hyperplasia: A diagnostic dilemma. *J Indian Soc Pedod Prev Dent* 2007;25:39-42.
- Deshingkar SA, Barpande SR, Bhavthankar JD. Congenital hemifacial hyperplasia. *Contemp Clin Dent* 2011;2:261-4.
- Bhuta BA, Yadav A, Desai RS, Bansal SP, Chemburkar VV, Dev PV. Clinical and imaging findings of true hemifacial hyperplasia. *Case Rep Dent* 2013;2013:152528.
- Niemitz EL, Feinberg AP, Brandenburg SA, Grundy PE, DeBaun MR. Children with idiopathic hemihypertrophy and Beckwith-Wiedemann syndrome have different constitutional epigenotypes associated with Wilms tumor. *Am J Hum Genet* 2005;77:887-91.
- Mohanna MA, Sallam AK. Idiopathic hemihypertrophy. *Saudi Med J* 2014;35:403-5.
- Rowe NH. Hemifacial hypertrophy. Review of the literature and addition of four cases. *Oral Surg Oral Med Oral Pathol* 1962;15:572-87.
- Arora PC, Umarji HR, Arora A, Ramaswami E. Lipomatosis: A diverse form of hemifacial hyperplasia. *Imaging Sci Dent* 2012;42:191-5.
- Gesell A. Hemihypertrophy and twinning. *Am J Med Sci* 1927;173:542-55.
- Verma P, Gupta K, Rishi S, Triwedi A. Hemifacial hypertrophy: A rare case report. *Med Radiol* 2012;24:338-41.
- Marx RE, Stern D. *Oral and Maxillofacial Pathology: A Rationale for Diagnosis and Treatment*. 1st ed. Chicago, Ill, USA: Quintessence; 2003.
- Burchfield D, Escobar V. Familial facial asymmetry (autosomal dominant hemihypertrophy?). *Oral Surg Oral Med Oral Pathol* 1980;50:321-4.
- Scott AJ. Hemihypertrophy: Report of four cases. *J Pediatr* 1935;6:650-6.
- Fraumeni JF Jr., Geiser CF, Manning MD. Wilms' tumor and congenital hemihypertrophy: Report of five new cases and review of literature. *Pediatrics* 1967;40:886-99.
- Rudolph CE, Norvold RW. Congenital partial hemihypertrophy involving marked malocclusion. *J Dent Res* 1944;23:133-9.
- Pollock RA, Newman MH, Burdi AR, Condit DP. Congenital hemifacial hyperplasia: An embryologic hypothesis and case report. *Cleft Palate J* 1985;22:173-84.
- Duncan DI, Hasengschwandtner F. Lipodissolve for subcutaneous fat reduction and skin retraction. *Aesthet Surg J* 2005;25:530-43.
- Hall HD. An improved method for treatment of facial asymmetry secondary to jaw deformity. *J Oral Maxillofac Surg* 1984;42:673-9.
- Venkataram J. Tumescant liposuction: A review. *J Cutan Aesthet Surg* 2008;1:49-57.
- Klein JA. Tumescant technique for local anesthesia improves safety in large-volume liposuction. *Plast Reconstr Surg* 1993;92:1085-98.
- Tan O. Tumescant liposuction in the treatment of partial hemifacial hypertrophy. *Dermatol Surg* 2010;36:2064-6.
- Mann MW, Palm MD, Sengelmann RD. New advances in liposuction technology. *Semin Cutan Med Surg* 2008;27:72-82.
- Rebello A. Power-assisted liposuction. *Clin Plast Surg* 2006;33:91-105.
- Katz BE, Maiwald DC. Power liposuction. *Dermatol Clin* 2005;23:383-91.
- Katz BE, Bruck MC, Felsenfeld L, Frew KE. Power liposuction: A report on complications. *Dermatol Surg* 2003;29:925-7.
- Badin AZ, Gondek LB, Garcia MJ, Valle LC, Flizikowski FB, de Noronha L. Analysis of laser lipolysis effects on human tissue samples obtained from liposuction. *Aesthetic Plast Surg* 2005;29:281-6.
- Goldman A. Submental Nd: Yag laser-assisted liposuction. *Lasers Surg Med* 2006;38:181-4.
- Palmer M, Curran J, Bowler P. Clinical experience and safety using phosphatidylcholine injections for the localized reduction of subcutaneous fat: A multicentre, retrospective UK study. *J Cosmet Dermatol* 2006;5:218-26.
- Peckitt N. The Molecular Biology of Adipocyte Differentiation and Apoptosis. In *First International Convention for Lipodissolve*. Salzburg, Austria; 2005.