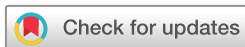

How I treat anaplastic glioma without 1p/19q codeletion



Anna Berghoff,¹ Martin van den Bent²

To cite: Berghoff A, van den Bent M. How I treat anaplastic glioma without 1p/19q codeletion. *ESMO Open* 2019;4:e000534. doi:10.1136/esmoopen-2019-000534

Received 29 April 2019
Revised 20 June 2019
Accepted 22 June 2019

ABSTRACT

Anaplastic astrocytoma without 1p/19q codeletion is a rare primary central nervous system tumour occurring primarily in middle-aged adults and associated with a median survival of 5–10 years. The major corner stone of treatment is maximal safe neurosurgical resection, followed by radiotherapy and chemotherapy. Several clinical trials addressed the optimal adjuvant treatment; however, interpretation has been challenged by the recent molecular marker-based reclassification of tumour. The interim study of the CATNON trial strongly suggests the addition of 12 adjuvant cycles of temozolomide in addition to radiotherapy after maximal safe resection in patients with anaplastic astrocytoma without 1p/19q codeletion. Based on more recently presented data from the second interim analysis of the CATNON trial and from the molecular analysis, benefit from temozolomide during and after radiotherapy is limited to patients with isocitrate dehydrogenase-mutated anaplastic astrocytoma. Given the small patient number in the single subgroups and the so far missing neurocognitive and quality of life data, more mature analyses needs to be awaited to draw final conclusions on the application of concurrent temozolomide treatment for the daily routine in patients who already are scheduled for adjuvant temozolomide. Further molecular analysis is ongoing to define personalised treatment approaches in patients with anaplastic astrocytoma.

INTRODUCTION

Lower grade astrocytomas are rare primary malignant intracranial tumours with only 0.41 cases per 100 000.¹ Histologically, anaplastic astrocytoma do not fulfil the criteria of glioblastoma (the presence of neoangiogenesis or necrosis) but show more malignant features compared with their low grade counterparts (higher cellularity, mitosis and nuclear polymorphism). The recent addition of molecular markers to the 2016 WHO glioma classification further distinguishes between anaplastic astrocytomas isocitrate dehydrogenase (IDH) mutant (mt) and IDH wild type (wt).² Anaplastic astrocytoma IDHmt are tumours with the presence of IDH1 codon 132 or IDH2 codon 172 missense mutations (IDHmut) and nuclear ATRX loss but without 1p/19q codeletion. IDHwt status in both low grade and anaplastic astrocytoma is associated with an aggressive clinical course, despite the similar histological appearance

underscoring the high clinical importance of the IDH-based molecular classification. The IDHwt subgroup of anaplastic astrocytoma is, however, no single entity and these tumours require further molecular analysis. Many show on further analysis ‘molecular features of glioblastoma’ including mutations of the TERT promoter, EGFR amplification as well as combined loss of heterozygosity of chromosome 10q and trisomy of chromosome 7.^{3–6} Patients with these histologically low grade tumours have a poor outcome, and immediate further treatment similar to glioblastoma should be considered, including combined chemoirradiation with temozolomide.

The first cornerstone in the treatment of anaplastic astrocytoma without 1p/19q codeletion—irrespective of the presence of an IDH mutation— is a maximal safe resection.⁷ The significant value of complete resection in IDHmt astrocytoma has been supported by retrospective studies that suggest even minor tumour remnants can adversely affect survival.^{8,9} Indeed, in case of incomplete resected IDHmt (anaplastic) astrocytoma, a second look surgery should be considered to achieve gross total resection, if that is considered safe and feasible.

Clinical trials on the adjuvant treatment of anaplastic astrocytoma

The interpretation of past and ongoing clinical trials on the optimal adjuvant treatment of anaplastic astrocytoma is complicated by the recent introduction of the molecular-based classification of glial malignancies, most relevant clinical trials were conducted or designed before introduction of the 2016 WHO classification of central nervous system (CNS) tumours in 2016.² Within several trials though posthoc or preplanned analysis of molecular characteristics were performed to address the efficacy of adjuvant treatment in the molecularly defined subgroups allowing recommendations for treatment in patients diagnosed today.

© Author (s) (or their employer(s)) 2019. Re-use permitted under CC BY-NC. No commercial re-use. Published by BMJ on behalf of the European Society for Medical Oncology.

¹Medical University of Vienna, Wien, Austria

²Brain Tumor Center, Erasmus MC Cancer Institute, Rotterdam, The Netherlands

Correspondence to

Martin van den Bent;
m.vandenbent@erasmusmc.nl

The PCV chemotherapeutic schema consisting of procarbazine, lomustine and vincristine was investigated in the RTOG 9402 and EORTC 26951 trials, both originally designed to address adjuvant treatment in oligodendroglioma tumours.^{10 11} However, both trials included patients with tumours lacking 1p/19q codeletion and which thus represent anaplastic astrocytoma according to the 2016 WHO classification of CNS tumours. In neither trial, the addition of PCV to adjuvant radiotherapy resulted in a statistically significant overall survival (OS) benefit in the 1p/19q intact tumours, but both showed trends for a benefit of additional PCV therapy in that particular population (HR RTOG study 0.85, 95% CI 0.58 to 1.23, $p=0.39$; EORTC study 0.83; 95% CI 0.62 to 1.10, $p=0.18$). Of note, the PCV regimen is associated with a rather challenging toxicity profile. In the EORTC 26951 study, about two-thirds of patients did not receive the fifth or sixth of the planned six cycles of therapy, and in 40% of patients early discontinuation occurred because of toxicity.¹²

Temozolomide, an alkylating oral chemotherapeutic agent, has a much better toxicity profile and is part of the standard combined radiochemotherapy approach in glioblastoma.⁷ The NOA-04 trial aimed to compare the clinical efficacy of radiotherapy to chemotherapy (either PCV or temozolomide) in anaplastic glioma. No statistical significant difference in the efficacy between chemotherapy alone versus radiotherapy alone was observed. The results suggest that the efficacy of temozolomide is similar to that of the PCV regimen in patients without 1p/19q codeletion.¹³ The CATNON trial (EORTC 26053–22054) was the first study on anaplastic glioma to include patients based on molecular characteristics as study inclusion required the presence of an anaplastic glioma without a 1p/19q codeletion.¹⁴ In a 2×2 factorial design, the clinical efficacy of concomitant and adjuvant chemotherapy with temozolomide added to radiotherapy was investigated (figure 1). Importantly, the first reported results represent a predefined interim analysis, while follow-up is still immature with 70% of patients still alive and only 46% having experienced disease progression. At the time of the interim analysis, OS was substantially longer in patients assigned to adjuvant temozolomide (median OS: not reached vs 41.1 months; HR 0.67, 95% CI 0.51 to 0.88; 5-year survival increase from 44% to 56%).¹⁴ At the Annual Meeting of the American Society of Clinical Oncology 2019, the second interim analysis of the CATNON trial focusing of the clinical efficacy of concurrent temozolomide treatment was presented. In

the entire study population, the addition of temozolomide during radiotherapy did not result in a statistically significant improvement of the OS.¹⁵ The numerically the 5-year OS rate in patients with concurrent treatment was 53% compared with 50% in patients without concurrent treatment. However, results were clearly different in patients with IDH-mutated tumours (see below).

Predictive molecular biomarkers

In the large randomised studies, molecular studies have been performed to investigate the predictive impact of IDH and MGMT promoter methylation on outcome to chemotherapy.¹³ In the NOA-04 study, in IDHwt subpopulation MGMT promoter methylation was found to be a predictive marker for response towards temozolomide, while no predictive value for MGMT promoter methylation was evident in IDHmt anaplastic glioma.¹⁶ This is explained by the frequent methylation of the MGMT promoter in IDHmt tumours. Accordingly, in the RTOG study, IDHmt appeared to be predictive of benefit to PCV chemotherapy, but the similar EORTC study still suggested a major role for MGMT promoter methylation.^{10 17}

In the second interim analysis of the CATNON trial, also the results of the molecular analysis were presented. As expected IDH mutational status as well as MGMT methylation status were prognostically highly relevant biomarkers. In terms of prediction of benefit to concurrent temozolomide during as well as adjuvant temozolomide after radiotherapy, the clinical benefit was present in patients with an IDH mutation or MGMT promoter methylation. In patients with IDHmt tumours already receiving adjuvant temozolomide, a small additional benefit seems present if temozolomide is also given during radiotherapy but this difference was statistically not significant. In numbers, patients with IDHmt anaplastic astrocytoma treated with concurrent as well as adjuvant temozolomide presented with a 5-year OS rate of 84.4% compared with 80.4% in patients treated only with adjuvant but without concurrent temozolomide. Given the potential neurotoxic impact of the concurrent temozolomide treatment to radiotherapy, the pro and contra discussion for concurrent temozolomide treatment has to be addressed with great caution and more follow-up of the study is clearly needed.

Importantly, concurrent and adjuvant temozolomide treatment did not improve the survival time the subgroup of patients with IDHwt or MGMT unmethylated anaplastic astrocytomas.¹⁵ However, due to the small sample size in the molecular subgroups, conclusions have to be drawn with caution, and further molecular analysis is pending.

Treatment on progression

Treatment possibilities on progression should be carefully considered in an interdisciplinary manner and include resurgery, reradiation as well as systemic approaches including temozolomide rechallenge and Nitrosourea's.⁷ A randomised study on recurrent 1p/19q intact grade II

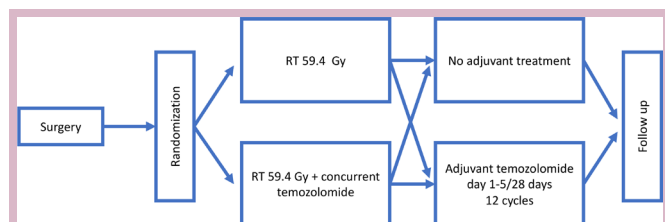


Figure 1 2×2 study design of the CATNON trial.

and grade III glioma did not observe a benefit in progression free survival (PFS) or OS of adding bevacizumab to temozolomide.¹⁸

Further supportive measures

Seizures, cognitive deficits and focal neurological deficits require special attention as they have great impact on quality of survival. It is important to realise that over time cognitive deficits may progress, and this requires ongoing attentiveness for these problems.¹⁹ A referral to specialised rehabilitation centres will not solve this type of problem but may help the patient to better cope with the challenges and issues that patients experience in everyday life and work. It is at present unclear if combining temozolomide with radiotherapy during the radiotherapy phase will increase late-onset cognitive deficits in patients with a relatively good prognosis compared with treatment with radiotherapy alone, but this is a potential concern.

CONCLUSIONS, OR: HOW I TREAT

In all lesions suspected to present a diffuse glioma, surgery should be set up to be as extensive as safely possible. We routinely assess grade II and III tumours with next generation sequencing using a glioma-specific panel including IDH, ATRX, H3-K27, 1p/19q, TERT promoter, EGFR as well as combined loss of heterozygosity of chromosome 1p, 19q, 10q and trisomy of chromosome 7. This panel allows the assessment of both copy number alterations and glioma relevant mutations, and allows the important further classification IDHwt and IDHmt anaplastic astrocytoma.²⁰ We treat grade II and III tumours with 'molecular features of glioblastoma' as glioblastoma with combined chemoradiation including six cycles of adjuvant temozolomide irrespective of the MGMT methylation status (figure 2). For anaplastic astrocytoma IDHmt, the interim results of the CATNON trials strongly suggest treatment with 59.4 Gy radiotherapy in fractions of 1.8 Gy followed by 12 cycles of adjuvant temozolomide chemotherapy (200 mg/m² days 1–5 in a 4-week cycle; figure 2).^{7,14} Even in fully resected patients, we continue with adjuvant radiotherapy and chemotherapy without

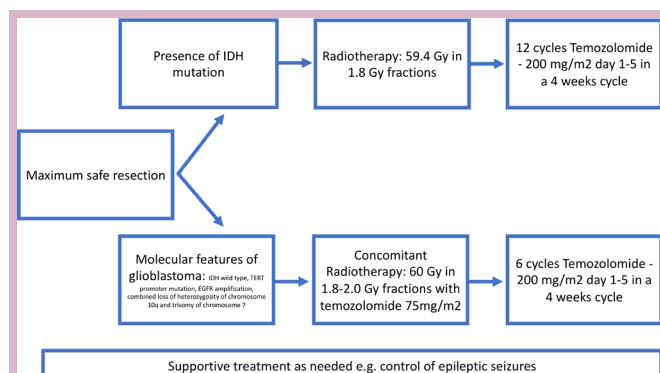


Figure 2 Illustration of the currently proposed treatment schedule in anaplastic astrocytoma without 1p/19q codeletion.

delay. This proposed regime should be applied in all IDHmt patients or in the presence of an MGMT methylation. In IDHwt patients or in absence of MGMT methylation, the additional adjuvant treatment with temozolomide should be discussed with a patient. The clinical benefit of concomitant temozolomide during radiotherapy in IDHmt tumors remains to be established until the final analysis of the CATNON trials also reporting of neuro-cognitive and quality of life based endpoints are available.

Contributors AB and MvdB prepared and reviewed the manuscript.

Funding The authors have not declared a specific grant for this research from any funding agency in the public, commercial or not-for-profit sectors.

Competing interests AB has research support from Daiichi Sankyo and honoraria for lectures, consultation or advisory board participation from Roche Bristol-Myers Squibb, Merck, Daiichi Sankyo as well as travel support from Roche, Amgen and AbbVie. MvdB has received honoraria of Abbvie, BMS, Celgene, Boehringer, and AGIOS and research support from Abbvie.

Patient consent for publication Not required.

Provenance and peer review Not commissioned; externally peer reviewed.

Open access This is an open access article distributed in accordance with the Creative Commons Attribution Non Commercial (CC BY-NC 4.0) license, which permits others to distribute, remix, adapt, build upon this work non-commercially, and license their derivative works on different terms, provided the original work is properly cited, any changes made are indicated, and the use is non-commercial. See: <http://creativecommons.org/licenses/by-nc/4.0/>.

REFERENCES

- Ostrom QT, Gittleman H, Truitt G, *et al*. CBTRUS statistical report: primary brain and other central nervous system tumors diagnosed in the United States in 2011-2015. *Neuro Oncol* 2018;20(suppl_4):iv1-86.
- Louis DN, Perry A, Reifenberger G, *et al*. The 2016 World Health Organization classification of tumors of the central nervous system: a summary. *Acta Neuropathol* 2016;131:803-20.
- Aibaidula A, Chan AK-Y, Shi Z, *et al*. Adult IDH wild-type lower-grade gliomas should be further stratified. *Neuro Oncol* 2017;19:1327-37.
- Wijnenga MMJ, Dubbink HJ, French PJ, *et al*. Molecular and clinical heterogeneity of adult diffuse low-grade IDH wild-type gliomas: assessment of TERT promoter mutation and chromosome 7 and 10 copy number status allows superior prognostic stratification. *Acta Neuropathol* 2017;134:957-9.
- Brat DJ, Aldape K, Colman H, *et al*. cIMPACT-NOW update 3: recommended diagnostic criteria for "Diffuse astrocytic glioma, IDH-wildtype, with molecular features of glioblastoma, WHO grade IV". *Acta Neuropathol* 2018;136:805-10.
- Kros JM, Huizer K, Hernández-Lain A, *et al*. Evidence-Based diagnostic algorithm for glioma: analysis of the results of pathology panel review and molecular parameters of EORTC 26951 and 26882 trials. *J Clin Oncol* 2015;33:1943-50.
- Weller M, van den Bent M, Tonn JC, *et al*. European association for neuro-oncology (EANO) guideline on the diagnosis and treatment of adult astrocytic and oligodendroglial gliomas. *Lancet Oncol* 2017;18:e315-29.
- Wijnenga MMJ, French PJ, Dubbink HJ, *et al*. The impact of surgery in molecularly defined low-grade glioma: an integrated clinical, radiological, and molecular analysis. *Neuro Oncol* 2018;20:103-12.
- Kawaguchi T, Sonoda Y, Shibahara I, *et al*. Impact of gross total resection in patients with who grade III glioma harboring the IDH 1/2 mutation without the 1p/19q co-deletion. *J Neurooncol* 2016;129:505-14.
- Cairncross JG, Wang M, Jenkins RB, *et al*. Benefit from procarbazine, lomustine, and vincristine in oligodendroglial tumors is associated with mutation of IDH. *J Clin Oncol* 2014;32:783-90.
- van den Bent MJ, Brandes AA, Taphoorn MJB, *et al*. Adjuvant procarbazine, lomustine, and vincristine chemotherapy in newly diagnosed anaplastic oligodendroglioma: long-term follow-

- up of EORTC brain tumor group study 26951. *J Clin Oncol* 2013;31:344–50.
12. van den Bent MJ, Carpentier AF, Brandes AA, *et al.* Adjuvant procarbazine, lomustine, and vincristine improves progression-free survival but not overall survival in newly diagnosed anaplastic oligodendrogliomas and oligoastrocytomas: a randomized European organisation for research and treatment of cancer phase III trial. *J Clin Oncol* 2006;24:2715–22.
 13. Wick W, Roth P, Hartmann C, *et al.* Long-Term analysis of the NOA-04 randomized phase III trial of sequential radiochemotherapy of anaplastic glioma with PCV or temozolomide. *Neuro Oncol* 2016;18:1529–37.
 14. van den Bent MJ, Baumert B, Erridge SC, *et al.* Interim results from the CATNON trial (EORTC study 26053-22054) of treatment with concurrent and adjuvant temozolomide for 1p/19q non-co-deleted anaplastic glioma: a phase 3, randomised, open-label intergroup study. *Lancet* 2017;390:1645–53.
 15. Van Den Bent MJ, Erridge S, Vogelbaum MA, *et al.* Second interim and first molecular analysis of the EORTC randomized phase III intergroup CATNON trial on concurrent and adjuvant temozolomide in anaplastic glioma without 1p/19q codeletion. *JCO* 2019;37(15_suppl).
 16. Wick W, Meisner C, Hentschel B, *et al.* Prognostic or predictive value of MGMT promoter methylation in gliomas depends on IDH1 mutation. *Neurology* 2013;81:1515–22.
 17. van den Bent MJ, Erdem-Eraslan L, Idbaih A, *et al.* MGMT-STP27 methylation status as predictive marker for response to PCV in anaplastic oligodendrogliomas and Oligoastrocytomas. A report from EORTC study 26951. *Clin Cancer Res* 2013;19:5513–22.
 18. van den Bent MJ, Klein M, Smits M, *et al.* Bevacizumab and temozolomide in patients with first recurrence of who grade II and III glioma, without 1p/19q co-deletion (TAVAREC): a randomised controlled phase 2 EORTC trial. *Lancet Oncol* 2018;19:1170–9.
 19. Habets EJJ, Taphoorn MJB, Nederend S, *et al.* Health-Related quality of life and cognitive functioning in long-term anaplastic oligodendroglioma and oligoastrocytoma survivors. *J Neurooncol* 2014;116:161–8.
 20. Synhaeve NE, van den Bent MJ, French PJ, *et al.* Clinical evaluation of a dedicated next generation sequencing panel for routine glioma diagnostics. *Acta Neuropathol Commun* 2018;6.