

Intracochlear Schwannoma: Diagnosis and Management

Aline Gomes Bittencourt¹ Ricardo Dourado Alves¹ Liliane Satomi Ikari¹ Patrick Rademaker Burke¹
Eloisa Maria Santiago Gebrim² Ricardo Ferreira Bento¹

¹Department of Otolaryngology, Universidade de São Paulo, São Paulo, São Paulo, Brazil

²Department of Radiology, Universidade de São Paulo, São Paulo, São Paulo, Brazil

Address for correspondence Aline Gomes Bittencourt, MD, Departamento de Otorrinaringologia, Universidade de São Paulo, Rua Teodoro Sampaio N 483, São Paulo, SP 05405000, Brazil (e-mail: bittencourt@iaorl.org).

Int Arch Otorhinolaryngol 2014;18:322–324.

Abstract

Introduction Schwannomas of the eighth cranial nerve are benign tumors that usually occur in the internal auditory canal or the cerebellopontine angle cistern. Rarely, these tumors may originate from the neural elements within the vestibule, cochlea, or semicircular canals and are called *intralabyrinthine schwannomas*. Intracochlear schwannomas (ICs) represent a small percentage of these tumors, and their diagnosis is based on high-resolution magnetic resonance imaging (MRI).

Objectives To report the clinical and radiologic features and audiometric testing results of an ICs in a 48-year-old man after a 22-month follow-up period.

Resumed Report A patient with an 8-year history of persistent tinnitus in his right ear, combined with ipsilateral progressive hearing loss and aural fullness. Audiometry revealed normal hearing in the left ear and a moderate to severe sensorineural hearing loss in the right ear, with decreased speech reception threshold and word recognition score, compared with the exam performed 5 years previously. MRI showed a small intracochlear nodular lesion in the modiolus, isointense on T1 with a high contrast enhancement on T1 postgadolinium images. During the follow-up period, there were no radiologic changes on imaging studies. Thus, a wait-and-scan policy was chosen as the lesion remained stable with no considerable growth and the patient still presents with residual hearing.

Conclusions Once diagnosed, not all ICs patients require surgery. Treatment options for ICs include stereotactic radiotherapy and rescanning policy, depending on the tumor's size, evidence of the tumor's growth, degree of hearing loss, intractable vestibular symptoms, concern about the pathologic diagnosis, and the patient's other medical conditions.

Keywords

- ▶ intracochlear schwannoma
- ▶ sensorineural hearing loss
- ▶ acoustic neuroma
- ▶ temporal bone tumor
- ▶ transotic approach
- ▶ magnetic resonance imaging

Introduction

Schwannomas of the eighth cranial nerve are benign tumors that usually occur in the internal auditory canal (IAC) or the cerebellopontine angle cistern. Rarely, these tumors may originate from the neural elements within the vestibule, cochlea, or semicircular canals and are called *intralabyrinthine*

schwannomas (ILSs).^{1,2} Intracochlear schwannomas (ICs) represent a small percentage of these tumors, and their diagnosis is based on high-resolution magnetic resonance imaging (MRI).

The aim of this article is to report the clinical and radiologic features of an ICs in a 48-year-old man after a 22-month follow-up period.

received
October 21, 2013
accepted
November 4, 2013
published online
January 7, 2014

DOI <http://dx.doi.org/10.1055/s-0033-1364170>.
ISSN 1809-9777.

Copyright © 2014 by Thieme Publicações Ltda, Rio de Janeiro, Brazil

License terms



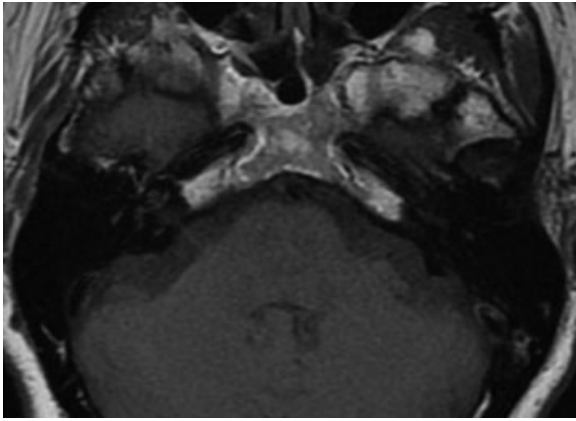


Fig. 1 Axial T1-weighted magnetic resonance image evidencing an isointense mass on T1 limited to the right cochlea.

Case Report

A 48-year-old man presented to our clinic with an 8-year history of persistent tinnitus in his right ear, combined with ipsilateral progressive hearing loss and aural fullness. He did not report vertigo, ototoxic exposure, a history of otitis media or trauma, or a similar familial history.

Upon physical examination, there were no otologic findings, facial palsy, or any other affected cranial nerves. Audiological examination revealed normal hearing in the left ear and moderate to severe sensorineural hearing loss in the right ear, with a speech reception threshold (SRT) of 80 dB and a word recognition score (WRS) of 58%. An audiogram obtained 7 years previously showed mild to moderate hearing loss in the right ear, and the patient had an SRT of 55 dB and a normal WRS of 92%.

MRI demonstrated a small intracochlear nodular lesion (diameter, 3.0 mm) in the modiolus, with a diffuse contrast in the apical turn, isointense on T1 (→ Fig. 1) with a high contrast enhancement on T1 postgadolinium images (→ Fig. 2). The lesion showed sharply delineated edges on enhanced T1-weighted images and sharply delineated signal intensity loss

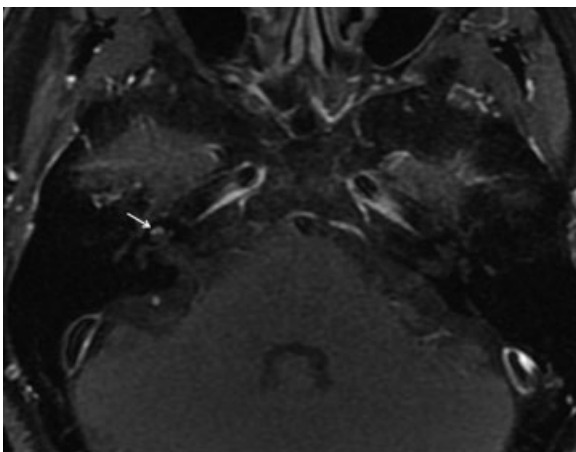


Fig. 2 Axial postcontrast T1-weighted image showing enhancement in the modiolus (arrow) of the right cochlea.

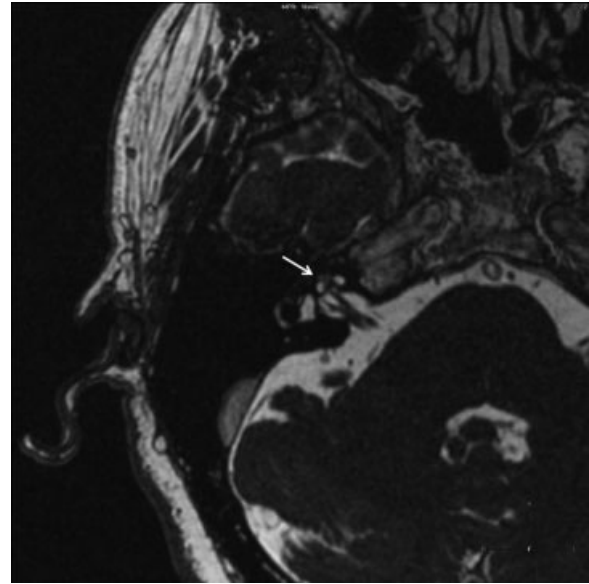


Fig. 3 Axial T2-weighted magnetic resonance image of the inner ear showing an intracochlear schwannoma as a hypointense mass that has replaced the normal fluid of the right cochlea (arrow).

in the high-intensity intralabyrinthine fluid on heavily T2-weighted images (→ Fig. 3). After 22 months, there were no symptomatic or audiological changes and MRI presented the same images.

Discussion

ILSs can be subclassified into seven groups according to the inner ear structures that are affected: intravestibular, intracochlear, intravestibulocochlear, transmodiolar, transmacular, transotic, and tympanolabyrinthine.² Approximately 100 cases of ILSs have been reported.³ The most common type of ILS is the intravestibular, and the least common types are the intravestibulocochlear and the transotic.² Schwannomas that are confined exclusively to the cochlea are extremely rare.

Schwann cells of the cochlear axons in the cochlear nerve are present in the modiolus, proximal to the spiral ganglion.^{1,3} Therefore, an ICS could arise in the modiolus and could then grow from the modiolus, occupy the cochlear basal turn, erode the cribriform area of the IAC, and spread into the vestibule.

In previous reports on patients with ICS, the most prevalent presenting symptoms were unilateral hearing loss, varying from 93 to 100%, followed by tinnitus (50%), vertigo (30 to 51%), imbalance, and aural fullness. The hearing loss is usually sensorineural and progressive, typically along with poor speech recognition ability, although ~15 to 32% of patients can present with sudden hearing loss.^{1,2,4-7} Occasionally, a mixed-type hearing loss can occur, presumably due to increased intracochlear impedance.² These tumors may cause secondary endolymphatic hydrops, resulting in disequilibrium and vertigo.⁴⁻⁷

Before the MRI era, these rare tumors were sporadically identified during surgical procedures of the inner ear or during

postmortem autopsies.³⁻⁷ In 1917, Nager first reported an ICS through the autopsy findings of a deaf and mentally disabled patient.⁸ Recent advances in MRI technology have enabled the detection of small ICS lesions (<2 mm) and the determination of their precise localization.^{2-4,7} Typically, an ICS is enhanced on T1-weighted images with gadolinium with sharply delineated edges and shows a delineated signal loss in the high-intensity intralabyrinthine fluid on T2-weighted images.⁹ High-resolution fast spin-echo T2-weighted images and traditional T1-weighted images with gadolinium are both equally sensitive in detecting schwannomas.^{1,4,5,7}

The most important differential diagnosis is labyrinthitis. The MRI findings of ICS may mimic those of infectious or inflammatory processes. However, acute infectious or inflammatory processes are usually normal on T2-weighted images, and an ICS may present as a filling defect. Labyrinthitis demonstrates an enhancement, which is often pronounced and less sharp and most commonly affects the complete cochlea or the vestibular system. However, this enhancement becomes weaker and may disappear on follow-up.^{9,10}

In rare cases of focal enhancement, labyrinthitis can be distinguished by performing a high-resolution thin-section T2-weighted study.^{5,7} In acute labyrinthitis, no soft tissue mass or filling defect is seen in the labyrinth. Chronic labyrinthitis shows T2 signal intensity loss within labyrinth and often demonstrates T1 postcontrast enhancement during its fibrous stage and no enhancement at ossific stage.^{5,7} Labyrinthitis may enhance on T1 postcontrast during its fibro-osseous phase and show T2 signal intensity loss within the inner ear, despite the intensity loss is usually unsharp. It could be diagnosed by obtaining a full medical history and performing temporal bone computed tomography (CT), although the CT can be normal in the early stages.^{5,7}

Hemorrhage has a variable signal on T2-weighted images but appears as a high signal intensity lesion on T1-weighted images without contrast enhancement.^{5,7} Lipoma, although rare, could also present as hyperintense lesion on T1-weighted images and hypointensity on fat-suppression sequences. Therefore, T1-weighted postcontrast enhanced images are essential to confirm that a lesion is a schwannoma.^{5,7}

Once diagnosed, not all ICS patients require surgery. The treatment of ICS depends on the tumor's size, evidence of the tumor's growth, degree of hearing loss, intractable vestibular symptoms, concern about the pathologic diagnosis, and the patient's other medical conditions.^{1,4-6} Preservation of hearing is not an option in the surgical removal of these tumors. The suggested surgical access is transotic, as it allows a good exposure of the inner ear structures and the IAC.³⁻⁶ Studies

have also reported successful tumor removal with a transcanal labyrinthectomy or a translabyrinthine approach.^{1,2,5,6}

Stereotactic radiotherapy is a treatment option for an ICS patient who has a progressively enlarging tumor but may not be eligible for surgery.⁶ The risks for radiosurgery include sensorineural sequelae, increased tumor growth, and malignant transformation. Radiosurgery is probably not effective in treating the vestibular symptoms. A bone-anchored hearing aid may help to overcome the head shadow effect and improve hearing.⁵

The suggested follow-up examination is rescanning at 12 months after the initial diagnosis. If the ICS has not grown, an MRI scan should be repeated every 2 years. Our patient's main complaint was hearing loss, but he presented with residual hearing, without any vestibular symptoms. Moreover, we decided to pursue a wait-and-scan policy because in the previous 22 months, the lesion had remained stable, showing no considerable growth.

References

- Zhu AF, McKinnon BJ. Transcanal surgical excision of an intracochlear schwannoma. *Am J Otolaryngol* 2012;33(6):779-781
- Kennedy RJ, Shelton C, Salzman KL, Davidson HC, Harnsberger HR. Intralabyrinthine schwannomas: diagnosis, management, and a new classification system. *Otol Neurotol* 2004;25(2):160-167
- Yoshida T, Sone M, Naganawa S, Nakashima T. Accuracy of 3.0. Tesla magnetic resonance imaging in the diagnosis of intracochlear schwannoma. *Auris Nasus Larynx* 2011;38(4):551-554
- Grayeli AB, Fond C, Kalamarides M, et al. Diagnosis and management of intracochlear schwannomas. *Otol Neurotol* 2007;28(7):951-957
- Jiang ZY, Kutz JW Jr, Roland PS, Isaacson B. Intracochlear schwannomas confined to the otic capsule. *Otol Neurotol* 2011;32(7):1175-1179
- Miller ME, Moriarty JM, Linetsky M, Lai C, Ishiyama A. Intracochlear schwannoma presenting as diffuse cochlear enhancement: diagnostic challenges of a rare cause of deafness. *Ir J Med Sci* 2012;181(1):131-134
- Salzman KL, Childs AM, Davidson HC, Kennedy RJ, Shelton C, Harnsberger HR. Intralabyrinthine schwannomas: imaging diagnosis and classification. *AJNR Am J Neuroradiol* 2012;33(1):104-109
- Nager FR. Zur Anatomie der endemischen Taubstummheit (mit einem Neurofibrom der Schneckenwindel). *Z Ohrenhk.* 75. Chap 8, pp.349-364. Wiesbaden; 1917
- Tieleman A, Casselman JW, Somers T, et al. Imaging of intralabyrinthine schwannomas: a retrospective study of 52 cases with emphasis on lesion growth. *AJNR Am J Neuroradiol* 2008;29(5):898-905
- Magliulo G, Colicchio G, Romana AF, Stasolla A. Intracochlear schwannoma. *Skull Base* 2010;20(2):115-118