

Midterm Results of Conversion from Failed Bipolar Hemiarthroplasty to Total Hip Arthroplasty

Abstract

Background: Conversion from failed bipolar hemiarthroplasty (HA) to total hip arthroplasty (THA) presents a great challenge to orthopedic surgeons for bipolar head removal and cup placement with or without change of femoral stem. Conversion THA after failed bipolar arthroplasty is known to offer both symptomatic and functional improvement. This study evaluates the midterm functional outcome and complications, especially dislocation associated with femoral head diameter, after conversion THA. **Materials and Methods:** Forty eight hips with the conversion of bipolar HA to THA were followed up for an average 6.2 years (range 2.0–11.5 years). Twenty one hips had conversion surgery to THA using metal-on-metal articulation (28 or 32 mm head). Nine hips used ceramic-on-ceramic (28–40 mm) and eighteen hips used large head metal-on-metal bearing (>40 mm). Outcome was evaluated using Harris Hip Score (HHS) and Western Ontario McMaster Universities Osteoarthritis Index (WOMAC) score. The radiographs were analyzed for evidence of osteolysis and/or loosening. The complications were evaluated, especially dislocation with different femoral head diameter. **Results:** Average HHS significantly improved from 42 preoperatively to 86 postoperatively and the average WOMAC score also significantly improved from 47 to 22 postoperatively. Radiological evaluation showed all the femoral components were stable. There was one acetabular component loosening, which required revision 9 years after conversion to THA. One dislocation and one recurrent dislocation were recorded in isolated acetabular revision hip; whereas one dislocation, one recurrent dislocation, and one trochanteric nonunion occurred in the hips with revision of both components. All dislocations occurred in hips with a femoral head size of 28 mm ($P = 0.052$). The cup and femoral head interval length was the most significant factor contributing to dislocation ($P = 0.013$). **Conclusions:** Conversion THA after failed bipolar HA offers a reliable pain relief and functional improvement. To prevent dislocation, it is highly recommended to use a larger diameter femoral head, especially where the cup size is big.

Keywords: Bipolar hemiarthroplasty, complication, conversion total hip arthroplasty

MeSH terms: Arthroplasty, replacement, hip, arthritis, acetabulum

**Kyung-Soon Park,
Chee-Ken Chan¹,
Dong-Hyun Lee,
Taek-Rim Yoon**

Center for Joint Disease,
Chonnam National University
Hwasun Hospital, 160 Ilsim-Ri,
Hwasun-Eup, Hwasun-Gun,
Jeonnam 58128, Korea,
¹Department of Orthopaedic
Surgery, Faculty of Medicine,
NOCERAL, University of
Malaya, Kuala Lumpur,
Malaysia

Introduction

Conversion from failed bipolar hemiarthroplasty (HA) to total hip arthroplasty (THA) is not uncommon and presents a great challenge to orthopedic surgeons for bipolar head removal and cup placement with or without change of femoral stem.

Midterm to long term outcome study of subsequent THA after failed HA has been debatable and unclear.^{1,2} Many reports have described the variable outcome and complications of conversion to THA for failed HA.³⁻⁶ However, none of the authors have specifically reported the results of conversion of bipolar arthroplasty to THA in various femoral head sizes with ceramic-on-ceramic or metal-on-metal articulations. This study aims to evaluate the

midterm functional outcome with average followup of 6.2 years and the complications associated with these prostheses, especially the dislocation rate associated with different femoral head diameter.

Materials and Methods

Forty eight patients (48 hips) underwent conversion of bipolar HA to THA between June 1998 and June 2013. They were followed up for more than 2 years. After obtaining Ethical Committee approval, patient's charts were analyzed for details of index operation, symptoms before conversion to THA, date of conversion to THA, and intraoperative and postoperative complications for each of the surgical procedures. Bipolar HA was performed for femoral neck fracture in 32 patients,

This is an open access journal, and articles are distributed under the terms of the Creative Commons Attribution-NonCommercial-ShareAlike 4.0 License, which allows others to remix, tweak, and build upon the work non-commercially, as long as appropriate credit is given and the new creations are licensed under the identical terms.

For reprints contact: reprints@medknow.com

How to cite this article: Park KS, Chan CK, Lee DH, Yoon TR. Midterm results of conversion from failed bipolar hemiarthroplasty to total hip arthroplasty. Indian J Orthop 2018;52:369-73.

Address for correspondence:

Prof. Taek-Rim Yoon,
Center for Joint Disease,
Chonnam National University
Hwasun Hospital, 160 Ilsim-Ri,
Hwasun-Eup, Hwasun-Gun,
Jeonnam 58128, Korea.
E-mail: tryoon@chonnam.ac.kr

Access this article online

Website: www.ijoonline.com

DOI:
10.4103/ortho.IJOrtho_494_16

Quick Response Code:



osteonecrosis of femoral head in 15 patients and septic hip sequelae in one patient.

The average duration of followup was 6.2 years (range 2.0–11.5 years). There were 22 men and 26 women between the ages of 28–80 years (average, 68.9 years) at the time of conversion surgery. Twenty one hips had conversion surgery to THA using Fitmore® acetabular cup (Zimmer, Winterthur, Switzerland) with metal-on-metal articulation (28 mm or 32 mm head). Six hips had surgery using Secur Fit cup (Stryker Osteonics, New Jersey, USA) and three hips, using Delta PF® (Lima-Lto, Udine, Italy) with ceramic-on-ceramic articulation (28–40 mm head). Eighteen hips had surgery using large head metal-on-metal bearing MMC (Zimmer, Warsaw, IN, USA) (seven hips), ACCIS (Implant Cast, Buxtehude, Germany) (six hips), and M2a-Magnum™ (Biomet, Warsaw, IN, USA) (five hips) (40–50 mm head) [Table 1 and Figure 1].

Conversion THA was performed for acetabular erosion without femoral stem loosening in 19 hips, acetabular cartilage erosion with femoral stem loosening in 13 hips, periprosthetic fracture with acetabular erosion in 12 hips, and recurrent dislocation in four hips. For the femoral stem revision, Wagner long stem (Zimmer, Warsaw, IN, USA) were used in 17 hips and cone prosthesis (Zimmer, Warsaw, IN, USA) was used in eight hips. All procedures were performed by two hip surgeons using conventional posterolateral approach.

Clinical results were evaluated using Harris Hip Score (HHS)⁷ and Western Ontario McMaster Universities Osteoarthritis Index (WOMAC) score.⁸ The preoperative HHS and WOMAC score were obtained from hospital

Table 1: Demographical data with implant details

Parameters	Data of 48 hips (48 patients)
Age, years (range)	68.9 (28-80)
Sex (male/female)	22/26
Follow-up duration, years (range)	6.2 (2.0-11.5)
Aetiology (cases)	
Acetabular erosion only	19
Acetabular erosion + femoral stem loosening	13
Periprosthetic fracture + acetabular erosion	12
Recurrent dislocation	4
Acetabular components, cases	
Fitmore (Zimmer, Winterthur, Switzerland)	21
Securfit (Stryker Osteonics, New jersey, USA)	6
Delta PF® (Lima-Lto, Udine, Italy)	3
MMC (Zimmer, Warsaw, USA)	7
ACCIS (Implantcast, Buxtehude, Germany)	6
M2a-magnum™ (Biomet, Warsaw, USA)	5
Bearing surface, cases	
Metal-on-metal (28, 32 mm)	21
Ceramic-on-ceramic (28, 32, 36, 40 mm)	9
Large head metal-on-metal (40-50 mm)	18

records. Postoperative scores were obtained at each followup visit. The radiological evaluation was performed using the following criteria by single-blinded observer: (i) Inclination and anteversion were calculated using Widmer’s method⁹ to determine acetabular cup alignment, (ii) cup positional changes were monitored at each followup, (iii) to evaluate acetabular osteolysis, DeLee and Charnley¹⁰ classification and Gruen¹¹ classification for femoral stem osteolysis were used respectively, and (iv) heterotopic ossification was evaluated according to the classification of Brooker *et al.*¹² The complications were evaluated, especially dislocations. In addition, for the evaluation of risk factor for dislocation, a new measurement method which is the cup and femoral head interval length was calculated using the following formula, i.e. “cup and femoral head interval length = (cup size-head size)/2” [Figure 2]. Furthermore, deviation of cup angles from Lewinnek *et al.* safe zone¹³ (inclination 40° and ante version 20°) was calculated.

Data were analyzed for statistical significance using the Chi-square test for categorical variables and the Student’s *t*-test for continuous variables. For the evaluation of relating risk factor for dislocation, Fisher exact test and the Mann–Whitney U-test were used. *P* ≤ 0.05 was considered statistically significant. Statistical analyses were performed using the SPSS statistical software system version 20.0 (SPSS, Chicago, IL, USA).

Results

The time interval between HA and conversion to THA was 6.7 years on average (range 5–12 years) and mean age of HA performed was 62.2 years old (range 24–75 years). Pain was the leading symptom in all the patients. Average HHS improved from 42 preoperatively (range 34–67) to 86 (range 65–97) postoperatively (*P* = 0.001). The average total WOMAC score improved from 47 (range 32–67) to 22 (range 9–44) postoperatively (*P* = 0.001). All the patients operated for groin pain reported significant improvement in

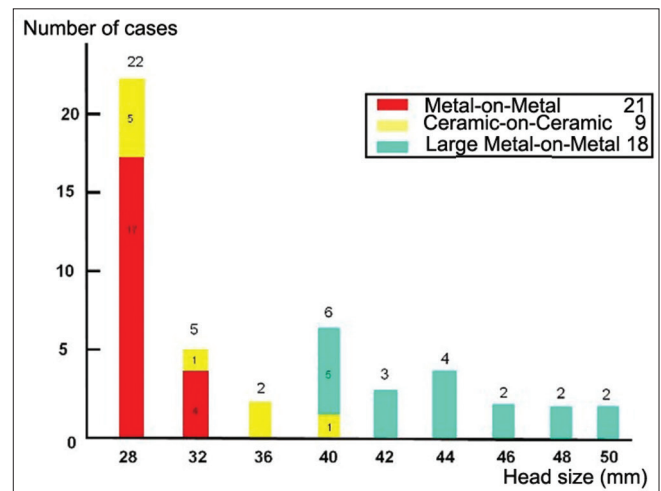


Figure 1: A bar diagram showing distribution of femoral head size and bearing couplings

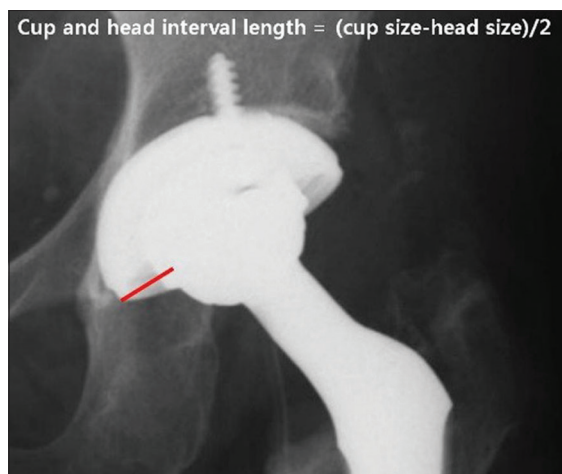


Figure 2: X-ray (L) hip joint anteroposterior view showing cup and femoral head interval length indicated with red line

their symptoms. Radiological evaluation showed good bony in growth and all the femoral components were stable. The average inclination angle of acetabular components was 37.4° (range 33.5°–48.°), and average acetabular anteversion was 22.3° (range 15.6°–32.8°). There was one acetabular component loosening and it required revision 9 years after conversion to THA. There were no cases with acetabular component osteolysis accompanied by radiolucency, location change or a significant change in cup angle with the exception of one case.

Complications occurred in five hips. One dislocation and one recurrent dislocation were recorded in isolated acetabular revision hips, whereas one dislocation, one recurrent dislocation, and one trochanteric nonunion occurred in the hips with revision of both components. All dislocations occurred in hips with a femoral head size of 28 mm ($P = 0.052$). The cup and femoral head interval length was the most significant contributory factor for dislocation ($P = 0.013$) [Table 2]. There was no incidence of infection, deep vein thrombosis, or pulmonary embolism. None of the femoral components required revision.

Discussion

HA is regarded as an easier and simpler surgery than THA. However, as metallic head of prosthesis articulates with articular cartilage, acetabular cartilage erosion can occur, with reported long term followup rates of 5%–24%.^{5,14,15} Moreover, femoral head is not completely hemispherical. Therefore, there can be some mismatch between the acetabular cartilage and the metallic hemispherical head. On the other hand, during the sizing of the HA head, error scan occur. As the size of head is measured in mm, the mismatch of <1 mm is unavoidable. Accordingly, the measurement of size of femoral head with Vernier calipers by the surgeon may be incorrect. The difference of friction coefficient of the cartilage and metal head can also cause acetabular cartilage erosion. As a result, there are some reports of better functional results of THA than HA.^{16,17}

Table 2: The association between risk factors and dislocation

Variable	P
Sex	0.320
Age	0.395
Cup size	0.125
Deviation of cup inclination angle	0.246
Deviation of cup anteversion angle	0.346
Head size	0.052
Cup and femoral head interval length	0.013
Head neck length	0.871

The hip pain in patients with HA may be varied. If there is acetabular erosion, groin pain is predominant.^{4,6} However, stem loosening or polyethylene wear of bipolar HA can cause hip and thigh pain. Therefore, the management of painful HA should be decided according to the exact cause of the hip pain. In the situation of acetabular cartilage erosion, only THA conversion can relieve the inguinal pain. Our result showed that the outcome after conversion to THA was good.

Conversion to THA after failed HA carries risk of postoperative hip dislocations. The incidence of dislocation is 0% to 16%.^{4,18-20} In this study, despite our careful soft tissue dissection and posterior capsular repair, the incidence of dislocation (4/48) is not lower compared to other studies. Advanced age, extensive soft tissue release, and muscular weakness are likely contributing factors. In revision of modular HA, acetabular reconstruction without stem revision can be done with less morbidity compared to with stem revision. A recent meta-analysis of 12,203 THA procedures reported a dislocation rate of the posterior approach as 3.23% as compared with 2.18% for the anterolateral, 1.27% for the transtrochanteric, and 0.55% for the direct lateral approaches. Accordingly, the posterior approach causes maximum concern when evaluating the risk of dislocation.⁴ In conversion surgery from failed HA to THA, additional and more superior anterior capsular release is required together with the posterolateral approach for exposure of acetabulum to insert the hemispherical acetabular cup. The additional extensive capsular release can also increase the risk of prosthetic joint dislocation.

On the other hand, Palan *et al.*²¹ postulated that head size is related to dislocation rate regardless of approaches either anterolateral or posterior. In our study, there was evidence of prevention of dislocation where the femoral head size exceeded 32 mm although it was not statistically significant ($P = 0.052$). The only significant contributing factor to dislocation in this study is the cup and femoral head interval length ($P = 0.013$). We postulate that the bigger the cup and femoral head interval length, there will be more dead space around the prosthetic joint articulation and subsequently fibrous tissue healing may be affected and inadequate to provide protection to joint's stability.

As a result, the prosthetic joint may be unstable and subsequently dislocates.

The incidence of complications in this study is comparable to other studies. Several authors reported the incidence of complications in the range of 7% to 64% of cases after conversion of HA to THA. In our study, with the exception of one cup loosening, there was no case of osteolysis. It is postulated that hard-on-hard bearing can prevent wear and osteolysis even in conversion THA from HA.

In addition, intraoperative femoral or acetabular fractures could be prevented. In cases of acetabular protrusion of HA, it is difficult to dislocate the hip during revision surgery. Attempts of forceful dislocation may cause femoral periprosthetic fracture or acetabular posterior wall fracture. In such cases, trunnion of the stem was disengaged from the head of HA before dislocation, followed by superior and anterior capsular release, before exposure of the entire acetabulum. After this procedure, the removal of the head of HA could be easily done.

Concerns about the large diameter metal-on-metal THAs include pseudotumor and hypersensitivity reactions. However, in cases studied, even though pseudotumor was not checked using magnetic resonance imaging or ultrasonography, there were no cases with inguinal pain or rapid progression of osteolysis. It is likely that the reason for the low incidence of inguinal area pain is that ASR device (Depuy, Warsaw, IN, USA) was not used. The large diameter head of THA may be beneficial in preventing hip dislocations, and it is necessary, especially for patients at high risk of dislocation, such as conversion of failed bipolar HA to THA.

The limitations of this study are that there was no control group and the degree of femoral stem anteversion was not checked. The combined anteversion deviation could be a related risk factor for dislocation. Furthermore, the dislocation rate in this study was not sufficiently high as to show the significance of head size for dislocation. Nevertheless, this study showed that the cup and head interval length is more important than head size itself for dislocation after conversion to THA from bipolar HA.

Conclusions

Conversion THA after symptomatic bipolar arthroplasty can offer a reliable pain relief and functional improvement. The perioperative complications approximate to those of a revision THA in this study. For the prevention of dislocation, it is better to use a larger diameter femoral head, especially if the cup size is big. Proportional increase of head size to cup size is necessary.

Declaration of patient consent

The authors certify that they have obtained all appropriate patient consent forms. In the form the patient(s) has/have given his/her/their consent for his/her/their images and other clinical information to be reported in the journal. The

patients understand that their names and initials will not be published and due efforts will be made to conceal their identity, but anonymity cannot be guaranteed.

Financial support and sponsorship

This study was supported by a grant (CRI13905-21) Chonnam National University Hospital Biomedical Research Institute.

Conflicts of interest

There are no conflicts of interest.

References

- Gjertsen JE, Lie SA, Vinje T, Engesaeter LB, Hallan G, Matre K, *et al.* More re-operations after uncemented than cemented hemiarthroplasty used in the treatment of displaced fractures of the femoral neck: An observational study of 11,116 hemiarthroplasties from a national register. *J Bone Joint Surg Br* 2012;94:1113-9.
- Kannan A, Kancherla R, McMahon S, Hawdon G, Soral A, Malhotra R. Arthroplasty options in femoral-neck fracture: Answers from the national registries. *Int Orthop* 2012;36:1-8.
- Sierra RJ, Cabanela ME. Conversion of failed hip hemiarthroplasties after femoral neck fractures. *Clin Orthop Relat Res* 2002;399:129-39.
- Sharkey PF, Rao R, Hozack WJ, Rothman RH, Carey C. Conversion of hemiarthroplasty to total hip arthroplasty: Can groin pain be eliminated? *J Arthroplasty* 1998;13:627-30.
- Coleman SH, Bansal M, Cornell CN, Sculco TP. Failure of bipolar hemiarthroplasty: A retrospective review of 31 consecutive bipolar prostheses converted to total hip arthroplasty. *Am J Orthop (Belle Mead NJ)* 2001;30:313-9.
- Diwanji SR, Kim SK, Seon JK, Park SJ, Yoon TR. Clinical results of conversion total hip arthroplasty after failed bipolar hemiarthroplasty. *J Arthroplasty* 2008;23:1009-15.
- Harris WH. Traumatic arthritis of the hip after dislocation and acetabular fractures: Treatment by mold arthroplasty. An end-result study using a new method of result evaluation. *J Bone Joint Surg Am* 1969;51:737-55.
- Boardman DL, Dorey F, Thomas BJ, Lieberman JR. The accuracy of assessing total hip arthroplasty outcomes: A prospective correlation study of walking ability and 2 validated measurement devices. *J Arthroplasty* 2000;15:200-4.
- Widmer KH. A simplified method to determine acetabular cup anteversion from plain radiographs. *J Arthroplasty* 2004;19:387-90.
- DeLee JG, Charnley J. Radiological demarcation of cemented sockets in total hip replacement. *Clin Orthop Relat Res* 1976;121 20-32.
- Gruen TA, McNeice GM, Amstutz HC. "Modes of failure" of cemented stem-type femoral components: A radiographic analysis of loosening. *Clin Orthop Relat Res* 1979;141:17-27.
- Brooker AF, Bowerman JW, Robinson RA, Riley LH Jr. Ectopic ossification following total hip replacement. Incidence and a method of classification. *J Bone Joint Surg Am* 1973;55:1629-32.
- Lewinnek GE, Lewis JL, Tarr R, Compere CL, Zimmerman JR. Dislocations after total hip-replacement arthroplasties. *J Bone Joint Surg Am* 1978;60:217-20.
- Nakata K, Ohzono K, Masuhara K, Matsui M, Hiroshima K, Ochi T. Acetabular osteolysis and migration in bipolar

- arthroplasty of the hip: Five- to 13-year follow-up study. *J Bone Joint Surg Br* 1997;79:258-64.
15. Yamagata M, Chao EY, Ilstrup DM, Melton LJ 3rd, Coventry MB, Stauffer RN. Fixed-head and bipolar hip endoprostheses. A retrospective clinical and roentgenographic study. *J Arthroplasty* 1987;2:327-41.
 16. Baker RP, Squires B, Gargan MF, Bannister GC. Total hip arthroplasty and hemiarthroplasty in mobile, independent patients with a displaced intracapsular fracture of the femoral neck. A randomized, controlled trial. *J Bone Joint Surg Am* 2006;88:2583-9.
 17. Blomfeldt R, Törnkvist H, Eriksson K, Söderqvist A, Ponzer S, Tidermark J. A randomised controlled trial comparing bipolar hemiarthroplasty with total hip replacement for displaced intracapsular fractures of the femoral neck in elderly patients. *J Bone Joint Surg Br* 2007;89:160-5.
 18. Sarmiento A, Gerard FM. Total hip arthroplasty for failed endoprostheses. *Clin Orthop Relat Res* 1978;137:112-7.
 19. Paprosky WG, Woeden SH. Acetabular Revision without Femoral Exchange - Is there a Correlation with Instability? Read at the Annual Meeting of the American Academy of Orthopaedic Surgeons, Dallas, TX: 13-17 February, 2002.
 20. Llinas A, Sarmiento A, Ebramzadeh E, Gogan WJ, McKellop HA. Total hip replacement after failed hemiarthroplasty or mould arthroplasty. Comparison of results with those of primary replacements. *J Bone Joint Surg Br* 1991;73:902-7.
 21. Palan J, Beard DJ, Murray DW, Andrew JG, Nolan J. Which approach for total hip arthroplasty: Anterolateral or posterior? *Clin Orthop Relat Res* 2009;467:473-7.