



Osteonecrosis of the Femoral Head in the Setting of a Complex Acetabulum Fracture without Hip Dislocation Treated Surgically Using Ilio-inguinal Approach: A Case Report

Anshul Shyam Sobti, DNB, D.Ortho, MBBS, Kwang-Jun Oh, MD, PhD

Department of Orthopedic Surgery, Konkuk University School of Medicine, Seoul, Korea

Osteonecrosis in isolated fractures of the acetabulum without dislocation of hip seems to be a known complication, but to our knowledge it has not been reported adequately. The causative nature of post-traumatic femoral head osteonecrosis has not been studied critically. The pathophysiology of osteonecrosis in this case also eludes us. Striking evidence points towards the intra-operative blood loss and low mean arterial pressure possibly leading to hypo-perfusion of femoral head leading to osteonecrosis. Fractures of the acetabulum pose a difficult problem for the patient and the surgeon because of possible complications. Thus any surgeon involved in surgery for fractures of the acetabulum should be aware of the possibility of this potential complication. Here is a 61-year male, who sustained a complex fracture of the acetabulum without hip dislocation, subsequently was treated surgically with internal fixation using an anterior approach, 10 months after surgery patient developed osteonecrosis of the femoral head.

Key Words: Acetabular fracture, Osteonecrosis of the femoral head, Acetabulum fracture complication

Fractures of the acetabulum pose a difficult problem for the patient and the surgeon because of the commonly

experienced late complications of posttraumatic osteoarthritis, osteonecrosis (ON) of the femoral head, and heterotopic ossification. Acetabular fractures associated with hip dislocations have been well documented in literature. They are usually associated with osteonecrosis of the femoral head (ONFH) and have a high rate of morbidity and mortality. ON associated with isolated acetabulum fracture without dislocation of the hip is known to occur, but as per knowledge of the authors its occurrence has rarely been reported to present after using an anterior surgical approach. The purpose of this article is to bring to notice the occurrence of this rarely reported event. The exact cause of ON here eludes us, with possible mechanisms being hypo-volemia intra-operatively with a low mean

Submitted: June 17, 2014 **1st revision:** July 22, 2014
2nd revision: August 18, 2014 **Final acceptance:** August 20, 2014
Address reprint request to
Kwang-Jun Oh, MD, PhD
Department of Orthopedic Surgery, Konkuk University School of Medicine, 120 Neungdong-ro, Gwangjin-gu, Seoul 143-729, Korea
TEL: +82-2-2030-7615 **FAX:** +82-2-2030-7369
E-mail: damioh@gmail.com

This is an Open Access article distributed under the terms of the Creative Commons Attribution Non-Commercial License (<http://creativecommons.org/licenses/by-nc/3.0>) which permits unrestricted non-commercial use, distribution, and reproduction in any medium, provided the original work is properly cited.

arterial pressure, leading to decreased blood flow to the femoral head; nature and complexity of the injury and predisposition of the patient.

CASE REPORT

A 61-year male presented to the emergency department with a history of road traffic accident. He arrived hemodynamically stable with a blood pressure of 126/76 mmHg and a heart rate of 78 beats per minute. On plain radiograph (Fig. 1A) anteroposterior and two Judet 45° oblique view¹⁾ and computed tomography (CT) scan of pelvis (Fig. 1B), the findings revealed both column fracture of acetabulum without hip dislocation, but no presence of femoral head fracture or ONFH.

After patient's vitals were stabilized, we performed the surgical procedure. Buttress plating through ilio-inguinal approach was performed using a reconstruction plate, which was supplemented by a compact hand plate. The surgical procedure lasted for 3 hours 44 minutes. The total blood loss intra-operatively was 3,000 mL. The preoperative hemoglobin (Hb) was 9.7 gm%. The patient was transfused 8 units of whole blood, 3 units of fresh frozen plasma and 8 units of packed red blood cells. Intra-operative Hb was 9.7 gm%; the average mean arterial pressure was 91.82 mmHg during the operative procedure. Post-operative blood loss via suction drain was 380 mL. Post-operatively the patient was transfused 2 units of whole blood and 1 unit of fresh frozen plasma. The Hb postoperatively was 10.3 gm%,

the patient was shifted to intensive care unit for a day, later was transferred to the ward.

The post-operative X-ray (Fig. 2A) and CT scan revealed an acceptable reduction of the fracture fragments and a concentric hip. Sitting up was performed on the first postoperative day; the patient subsequently began formal physical therapy and active range of motion exercises. Partial toe touch weight bearing (20 to 30 lb; 9 to 13.6 kg) with a walker was maintained for 6-8 weeks. Progression to full weight bearing was started on the basis of the follow-up radiographs. Physical therapy was continued until muscle strength and range of motion were regained. The patient was then followed up on a regular basis, every monthly. His progress was monitored. On subsequent follow-up, the patient had complains of pain in the hip joint. The patient's 4-month postoperative X-ray revealed a radiolucent lesion in the superolateral part of femoral head, crescent sign, and sclerosis. The 10-month follow up X-ray (Fig. 2B) showed collapse and sclerosis, findings consistent with ONFH. A CT scan (Fig. 3A) confirmed this. ON was diagnosed only when the radiographic findings provided a clear differentiation from wear of the femoral head²⁾. The joint pain increased due to the ONFH, we performed a total hip replacement (Fig. 3B) 12 months after the index surgery. Histopathology report of the femoral head confirmed ON.

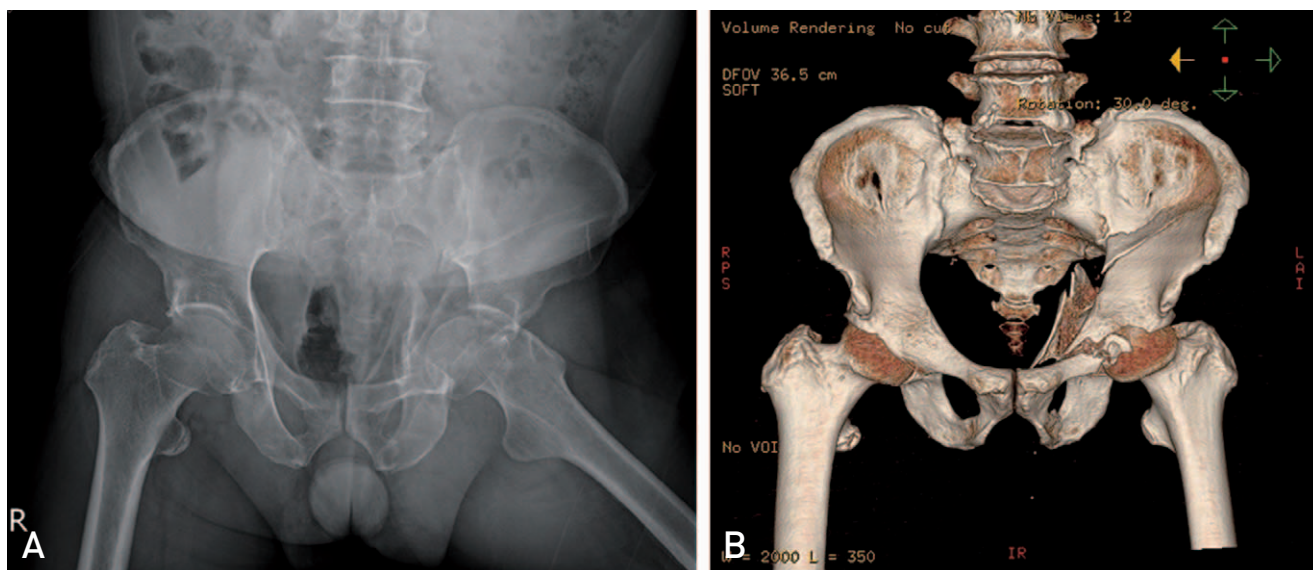


Fig. 1. Preoperative images. (A) X-ray image. (B) Computed tomography scan.

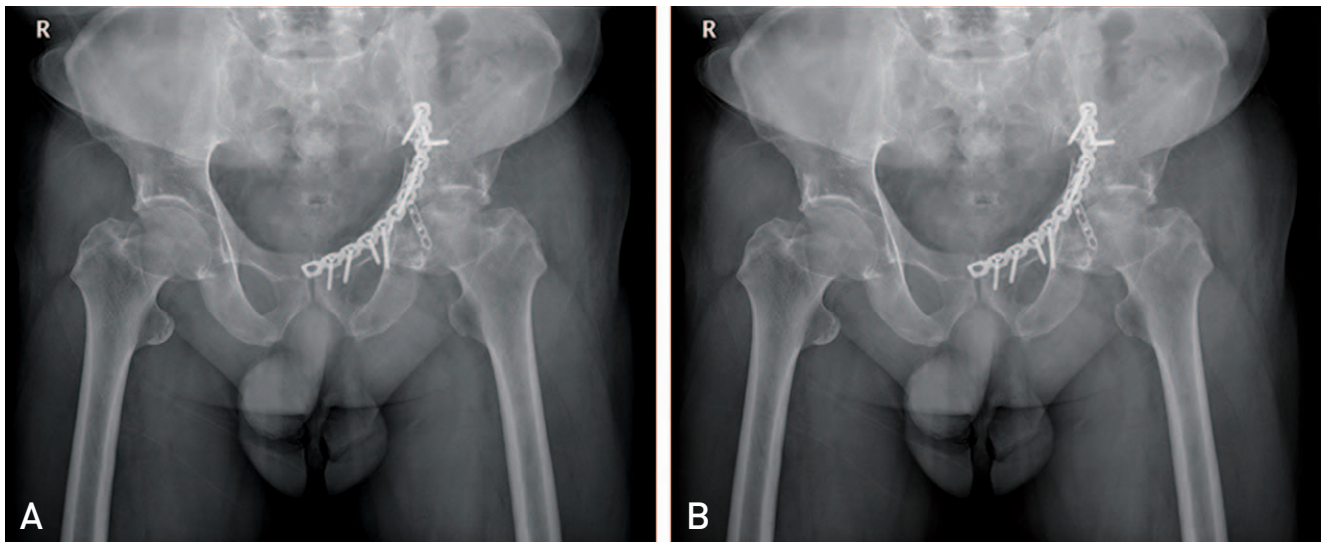


Fig. 2. Postoperative images. (A) X-ray image of immediately after surgery. (B) X-ray image after 10 months.

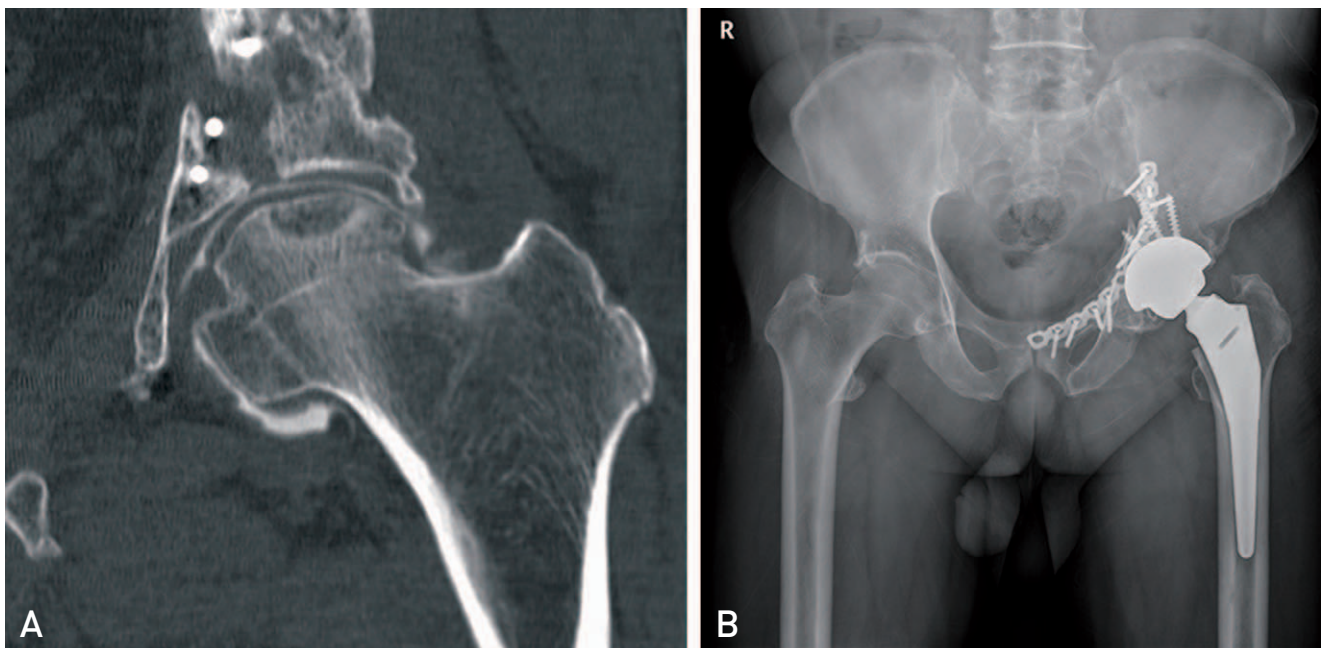


Fig. 3. (A) Computed tomography scan showing osteonecrosis of the femoral head. (B) Postoperative x-ray image after total hip replacement.

DISCUSSION

Late complications of acetabulum fractures include heterotopic ossification and ONFH, which are present in less than 10% of the population³. The exact cause of these complications are not entirely understood. The incidence of ON described in literature varies from 3% to 53%³⁻⁵. The incidence of ONFH is known to be high in transverse and posterior wall fractures associated with

posterior dislocation⁶. ON also occurs in conjunction with approximately 3% of anterior hip dislocations and in more than 13% of posterior hip dislocations. In a recent meta analysis of 3,670 surgically treated displaced acetabular fractures the incidence of ONFH showed an overall incidence of 5.6%³, suggesting that it is grossly overestimated and that most of the observed changes in the head of the femur are probably due to osteoarthritis⁵.

ONFH is caused by inadequate blood supply to the affected segment of the subchondral bone. When posterior surgical approaches have been used, ON rates as high as 42% within the first year after surgery have been reported⁷⁾. The anterior surgical approach to the acetabulum theoretically leads to the least devascularization⁸⁾. Many systemic conditions are associated with ON, but 25% of all cases are described as idiopathic and can contribute as a cause⁹⁾. Trauma is one of the most common causes of ON, interruption of the blood supply to the affected segment of the bone being the cause of ischemia.

In this case the exact cause of ONFH eludes us, especially in the absence of any patient related predisposing risk factors, except presence of fracture without hip dislocation and subsequent intervention by an ilio-inguinal approach. A probable theory of etiology could be the intra-operative hypovolaemia, low mean arterial pressure, causing compromised flow to the femoral head being so as to act as the final blow. Alteration of the blood supply to vital organs during hypovolaemia is well established. With mean arterial pressure usually in the range of 50 to 60 mmHg, the flow to the femoral head is potentially compromised¹⁰⁾ so as to act in an accumulative stress theory, as suggested by Kenzora and Glimcher⁹⁾. It is questionable as to whether this alone would be enough to explain the development of ON. Patient also could have had other unknown risk factors for non-traumatic ON.

REFERENCES

1. Judet R, Judet J, Letournel E. *Fractures of the acetabulum: classification and surgical approaches for open reduction. Preliminary report. J Bone Joint Surg Am.* 1964;46:1615-46.
2. Matta JM. *Fractures of the acetabulum: accuracy of reduction and clinical results in patients managed operatively within three weeks after the injury. J Bone Joint Surg Am.* 1996;78:1632-45.
3. Giannoudis PV, Grotz MR, Papakostidis C, Dinopoulos H. *Operative treatment of displaced fractures of the acetabulum. A meta-analysis. J Bone Joint Surg Br.* 2005; 87:2-9.
4. Matta JM, Anderson LM, Epstein HC, Hendricks P. *Fractures of the acetabulum. A retrospective analysis. Clin Orthop Relat Res.* 1986;205:230-40.
5. Liebergall M, Mosheiff R, Low J, Goldvirt M, Matan Y, Segal D. *Acetabular fractures. Clinical outcome of surgical treatment. Clin Orthop Relat Res.* 1999;366:205-16.
6. Letournel E, Judet R, Elson R. *Fractures of the acetabulum. Berlin, Germany: Springer-Verlag; 1981.*
7. Baumgaertner MR. *Fractures of the posterior wall of the acetabulum. J Am Acad Orthop Surg.* 1999;7:54-65.
8. Trueta J, Harrison MH. *The normal vascular anatomy of the femoral head in adult man. J Bone Joint Surg Br.* 1953; 35-B:442-61.
9. Kenzora JE, Glimcher MJ. *Accumulative cell stress: the multifactorial etiology of idiopathic osteonecrosis. Orthop Clin North Am.* 1985;16:669-79.
10. Orpen N, Walker G, Fairlie N, Coghill S, Birch N. *Avascular necrosis of the femoral head after surgery for lumbar spinal stenosis. Spine (Phila Pa 1976).* 2003;28:E364-7.