

# Role of the Infectious Disease Consultant in Management of Patients With Tuberculosis-Associated Ocular Inflammation

Marjorie M. Conant,<sup>1,2</sup> Chuck R. Vrasich,<sup>3</sup> Jeff V. Wongsakhaluang,<sup>4</sup> Kevin Ferenchak,<sup>4</sup> Matthew K. Asano,<sup>4</sup> Norbert Becker,<sup>4</sup> and Patricia DeMarais<sup>2</sup>

<sup>1</sup>Division of Infectious Diseases, Rush University, <sup>2</sup>Division of Infectious Diseases, John Stroger Hospital of Cook County and Ruth Rothstein CORE Center, <sup>3</sup>Department of Internal Medicine, and <sup>4</sup>Division of Ophthalmology, John Stroger Hospital of Cook County, Chicago, Illinois

**Background.** Tuberculosis is a disease with continued worldwide prevalence, morbidity, and mortality. Tuberculosis-associated ocular inflammation (TB-AOI) is a manifestation that can occur with pulmonary or extrapulmonary TB. Evaluation of these ocular presentations and treatment in the United States are limited. Our objective was to describe cases in an urban area and assess the role of the infectious diseases specialist in managing these complex patients.

**Methods.** We performed a retrospective case series of all patients referred to our infectious disease clinic for presumed TB-AOI from 2005 through 2013. Patients with ocular inflammation were determined to have presumed TB-AOI based on clinical presentation with correlative positive tuberculin skin test and/or QuantiFERON-TB Gold. Attempts were made to exclude other diagnoses. Data were collected and analyzed with respect to demographics, ocular manifestations, and treatment.

**Results.** Sixty eyes of 42 patients were included in the study; anterior uveitis was the most common site of involvement. The median age was 46 years, and 33 patients (79%) were foreign born. Forty patients (95%) received a course of antituberculous therapy with 38% experiencing treatment-related side effects. A 6-month duration was recommended in 78% cases. There was improvement or stability of the vision in 42 eyes (74%) of those treated.

**Conclusions.** Ocular involvement is an uncommon but important manifestation of TB. Our data further characterize TB-AOI cases in the United States. Treatment provides significant benefit to properly selected patients. A multidisciplinary approach, with care provided by ophthalmology and infectious disease providers, should be used to allow for the most efficacious treatment.

**Keywords.** *Mycobacterium*; ocular infections; tuberculosis; uveitis.

Tuberculosis (TB), the second leading cause of death from an infectious disease, poses serious complications for those infected. In 2013 alone, an estimated 9 million people were diagnosed and 1.5 million died as a result of TB [1]. Approximately one third of the world's population is suspected to be infected with *Mycobacterium tuberculosis* (MTB), with approximately 10% expected to develop tuberculous disease during their lifetime [2]. Within the United States, the Centers for Disease Control and Prevention (CDC) reported the disease prevalence as 3 cases per 100 000 persons in 2013 with foreign-born persons having nearly 13 times higher rates of disease [3]. Additional risk factors include homelessness, low socioeconomic status, detainment in correctional facilities, and human immunodeficiency virus (HIV) infection [4].

The true prevalence may be underreported, because there remains difficulty in confirming the diagnosis in many patients.

Tuberculosis is typically associated with pulmonary infection, but in up to 20% of cases pulmonary involvement is absent [5]. Extrapulmonary TB can involve almost any site of the body, including the eye. Tuberculosis-associated ocular inflammation (TB-AOI) is the presence of infection and/or inflammation involving the eye as a result of direct infection of the eye or in association with extraocular TB. Tuberculosis-AOI may present with a variety of ophthalmic clinical findings involving almost any structure of the eye, often mimicking other inflammatory conditions. Pathology evaluation typically reveals granulomatous inflammation [6].

Eye manifestations of TB are categorized based on the primary anatomical location of the inflammation in accordance with the Standardization of Uveitis Nomenclature Working Group [7]. Anterior uveitis describes inflammation involving the iris and ciliary body. Other anterior structures that may be involved are the cornea and sclera. Symptoms suggestive of an anterior process are a red, painful eye with or without decreased vision. Inflammation involving primarily the vitreous is called intermediate uveitis. Posterior uveitis describes inflammation of the choroid and/or retina. Symptoms suggestive of a posterior process are blurry vision, mild or absent pain, and floaters.

Received 10 June 2015; accepted 8 December 2015.

Correspondence: P. DeMarais, Division of Infectious Diseases, John Stroger Hospital of Cook County and Ruth Rothstein CORE Center, 2020 W. Harrison, Chicago, IL 60612 (pdemarais@coockcountyhhs.org).

Open Forum Infectious Diseases®

© The Author 2015. Published by Oxford University Press on behalf of the Infectious Diseases Society of America. This is an Open Access article distributed under the terms of the Creative Commons Attribution-NonCommercial-NoDerivs licence (<http://creativecommons.org/licenses/by-nc-nd/4.0/>), which permits non-commercial reproduction and distribution of the work, in any medium, provided the original work is not altered or transformed in any way, and that the work is properly cited. For commercial re-use, please contact [journals.permissions@oup.com](mailto:journals.permissions@oup.com). DOI: 10.1093/ofid/ofv195

Panuveitis involves both anterior and posterior segments. Optic neuropathy is primary involvement of the optic nerve. Posterior uveitis is traditionally regarded as the most common site of ocular involvement and predominantly involves the choroid [8]. Gupta et al [2] described 158 patients in India with TB-AOI, which were classified as posterior uveitis (42%), anterior uveitis (36%), intermediate uveitis (11%), and panuveitis (11%). Recent data suggest bilateral disease occurs in 53% to 73% of cases of isolated TB-AOI [6, 9].

Diagnosis of TB-AOI poses a significant challenge to clinicians due to limited diagnostic capabilities. There remains lack of uniform diagnostic criteria agreed upon by infectious disease (ID) specialists and ophthalmologists. Guidelines for the diagnosis of TB-AOI have been proposed to categorize patients as definitive or presumed infection using supportive clinical ocular findings, ocular microbiologic specimens, corroborative evidence (positive tuberculin skin test, interferon gamma release assay, and chest radiography), and exclusion of other causes [2, 10]. In one study of presumed TB-AOI in India, they identified 3 clinical findings specific for TB: broad-based posterior synechiae, retinal vasculitis with or without choroiditis, and serpiginous-like choroiditis [11]. However, these criteria are yet to be evaluated and validated in lower prevalence regions. Pathology and microbiologic testing (acid-fast smear [AFB], tissue culture, polymerase chain reaction [PCR] for MTB DNA) to confirm the presence of TB infection provides a more conclusive diagnosis, but the yield from such studies has been relatively low [6]. In one study, the sensitivity for PCR in vitreous samples ranged from 33.3% to 46.9% [12], and in another study only 3.8% of suspected cases were positive [13]. Moreover, positive tissue-based PCR results have been obtained in up to 11% of controlled patient groups that had been assumed not to have TB-AOI [14]. The added risk of ocular morbidity while obtaining a specimen must be weighed against what has seemed low benefit. In addition to inadequate diagnostic capabilities, there is also speculation that many ocular manifestations are immune-mediated hypersensitivity reactions secondary to TB infection in other sites of the body, as opposed to active ocular infection [15, 16]. Without direct evaluation for TB from ocular specimens, differentiating infection from inflammation may be impossible [8].

The role for early evaluation and management by an ID specialist has been well described [2, 14, 17–19]. There are limited data in the literature regarding clinical approach taken by the ID specialist with these complicated cases. We present a large series of patients referred to an academic ID clinic for evaluation of presumed TB-AOI.

## METHODS

We conducted a retrospective review of all patients who were referred to the ID clinic at Ruth M. Rothstein CORE Center during the 9 years from 2005 through 2013 for suspected TB-AOI. The CORE Center is a part of the safety net Cook County

Health and Hospitals System (CCHHS) serving the greater Chicago area. All referrals originated from the Ophthalmology Department at CCHHS. Patients were included in this review if they met the following criteria: (1) active uveitis on ophthalmologic exam and (2) evidence of TB infection with either a positive purified protein derivative (PPD) and/or QuantiFERON-TB Gold In-Tube Test. The PPD was interpreted based on the CDC classification [20], and a positive QuantiFERON-TB Gold In-Tube Test was defined as per the manufacturer guidelines [21]. Other possible causes of uveitis, such as syphilis, lupus, rheumatoid arthritis, and sarcoidosis, were screened for by laboratory tests (syphilis serology, antinuclear antibody [ANA], rheumatoid factor [RF], angiotensin-converting enzyme [ACE], and lysosome) and a self-administered uveitis questionnaire (reviewed by the ophthalmologist seeing the patient) addressing symptomatology related to these diseases.

All patients underwent complete evaluation in the ID clinic, including history and physical exam. Data were collected on demographics (age, sex, race, country of birth, duration of time in the United States), Bacillus Calmette-Guérin status, TB risk factors (prior imprisonment, period of homelessness, or exposure to TB contact), HIV status, TB diagnostic studies (chest x-ray, AFB smear and culture, MTB PCR), use of topical or systemic corticosteroids, type and duration of antituberculous therapy (ATT), adverse drug effects, and length of follow up when available for each patient.

Patients' ophthalmologic records were also reviewed for ocular history, type and duration of symptoms, site of involvement, visual acuity, topical medications, response to therapy, and duration of follow up. Primary site of involvement was categorized as anterior uveitis, intermediate uveitis, posterior uveitis, panuveitis, or optic neuropathy. Anterior uveitis included keratitis, scleritis, iritis, and iridocyclitis. Intermediate uveitis included vitritis. Posterior uveitis included choroiditis and retinitis. Optic neuropathy included papillitis, optic neuritis, or neuroretinitis.

Both the ID and Ophthalmology departments performed independent clinical evaluations, and all included patients who were thought to have presumed TB-AOI. The ID physician determined whether ATT was indicated, as well as drug regimen and duration, based on the opinion of the referring ophthalmologist and a review of the clinical and laboratory data. The ophthalmologist determined whether the patient required topical or systemic steroids. Dose of systemic steroid was typically 1 mg/kg prednisone daily. All patients were reported to the Illinois Department of Health for suspected diagnosis of TB.

Statistical analysis included descriptive statistics. The study was reviewed and approved by the CCHHS Institutional Review Board.

## RESULTS

Over the 8-year study period, 42 patients including 60 eyes were referred to the ID clinic for ATT. The most common symptoms

at presentation were blurry vision (n = 29, 69%), eye pain (n = 19, 45%), and red eye (n = 12, 29%).

Table 1 describes demographics. Twenty-three patients (55%) were female, and the median age was 46 years (range, 16–69 years). Thirty-three patients (79%) were born outside the United States. Chest imaging (x-ray and/or computed tomography scan) was available for all patients and was abnormal in 8 cases (19%). No patients were suspected of having active pulmonary TB based on clinical symptoms. Nine patients (21%) received systemic corticosteroids. One patient (2%) was infected with HIV. All patients in the study had positive TB screening tests. Forty-one patients (98%) had a positive PPD; the 1 patient with a negative PPD had a positive QuantiFERON assay. Purified protein derivative size was reported for 30 patients (75%) with a median of 20 mm (range, 7–40 mm). Patients were observed for an average of 16.3 months (range, 0–96 months).

Ocular involvement included anterior uveitis (n = 20, 33%), intermediate uveitis (n = 6, 10%), posterior uveitis (n = 15, 25%), panuveitis (n = 14, 23%), and optic neuropathy (n = 5, 8%). Twenty-four patients (57%) had unilateral disease (Table 2).

Forty-one of 42 patients had negative syphilis screening. The remaining patient was not tested. Six of 31 patients (19%) that were tested for RF had positive results. Three of 37 patients (8%) tested for ANAs had positive results. Seven of 36 patients (19%) tested for ACE level had elevated results. None of these patients with positive ancillary testing screened positive on their ophthalmology uveitis questionnaire gave clinical history or had physical findings diagnostic for rheumatoid arthritis, lupus, or sarcoidosis.

An ophthalmologic diagnostic procedure was performed in 3 patients (7%). Vitreous aspiration was performed for 2 of the patients. One patient had clinical findings suggestive of endophthalmitis, so a routine bacterial culture was obtained and was negative. For the other patient, ID requested a specimen be obtained for MTB PCR, which was negative. The third patient underwent drainage of a choroidal effusion with fluid sent for AFB smear and culture, which were negative.

Forty patients (95%) received a course of ATT. The 2 patients who did not receive ATT declined the recommended treatment. Of the patients who were treated, 31 (78%) received a 6-month duration of therapy. The most common regimen was 2 months

**Table 2. Site of Ocular Involvement**

Ocular Manifestation	n/N (%)
Anterior uveitis	20/60 (33)
Posterior uveitis	15/60 (25)
Intermediate uveitis	6/60 (10)
Panuveitis	14/60 (23)
Optic neuropathy	5/60 (8)
Unilateral involvement	24/42 (57)

of rifampin, isoniazid, pyrazinamide, and ethambutol followed by 4 months of rifampin and isoniazid in 23 patients (58%).

Fifteen patients (38%) developed adverse effects from therapy with the most common being nausea in 8 patients (20%). Three patients (7.5%) developed a transient elevation of liver enzymes with 2 of them (5%) requiring interruption of therapy until abnormalities and associated symptoms improved. One patient (2.5%) stopped therapy altogether due to burning leg pain in the first month. Another 2 patients (5%) had treatment courses extended to 8 and 9 months as a consequence of intolerance limiting compliance. Worsening visual complaints and nausea prompted discontinuation of ethambutol in 2 patients (5%). Neuropathy in 1 patient (2.5%) necessitated exchange of isoniazid for levofloxacin.

Outcome data were collected for 57 eyes of 39 patients. Although there were a total of 42 patients, 2 patients declined therapy and were lost to follow up; and a third patient never returned to the ophthalmology clinic. However, this third patient did follow up regularly with ID and completed a course of ATT. Improvement or stability of vision was documented in 42 eyes (74%), whereas 15 eyes (26%) had worsening vision (Figure 1). Of the 15 eyes with worsening vision, 8 (53%) had improvement or resolution of inflammation, 3 (20%) had unchanged inflammation, and 4 (27%) had worsening inflammation. Overall, 40 eyes (73%) of patients treated with ATT had improvement in the level of inflammation (Figure 1). There were 2 eyes in which inflammation could not be quantified during follow up visits due to dense cataracts obstructing the examiner's view.

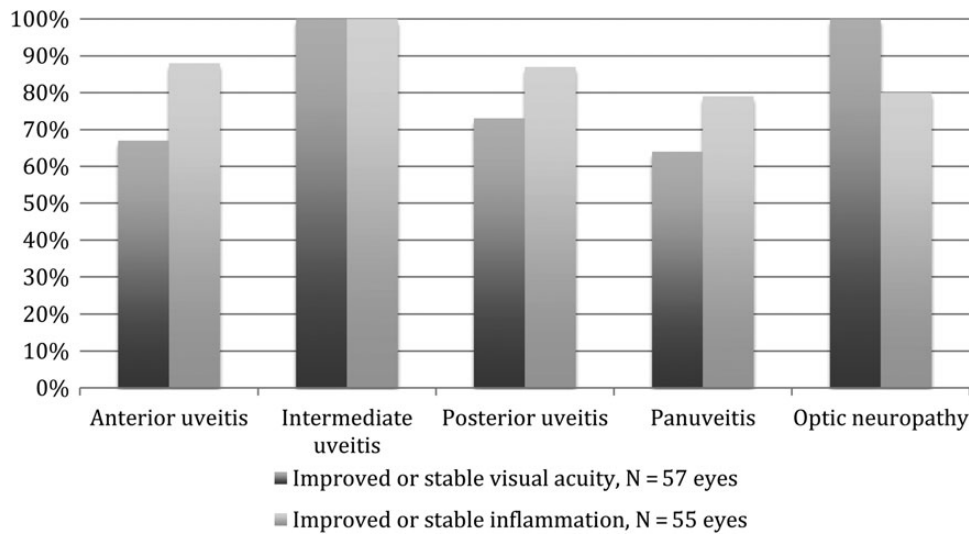
## DISCUSSION

The diagnosis of TB-AOI is difficult and in almost all cases relies on a suggestive clinical presentation, a correlative positive TB screening test, and screening to rule out other common treatable etiologies, such as syphilis, lupus, rheumatoid arthritis, or sarcoidosis. Because biopsy and/or aspiration of inflamed areas produce low yield in the setting of significant risk, the diagnosis of active infection in the eye has proved to be very difficult. Many cases may be a consequence of antigenic mimicry associated with live bacterium elsewhere in the body, but due to lack of adequate diagnostic capabilities this is difficult to differentiate. Whether ocular inflammation is a consequence of TB in the eye versus elsewhere in the body, management should still

**Table 1. Demographic and Clinical Characteristics of Patients with TB-Associated Ocular Inflammation**

Baseline Characteristics	
Median age (range), years	46 (16–69)
Female sex, n/N (%)	23/42 (55)
Foreign born, n/N (%)	33/42 (79)
Positive PPD, n/N (%)	41/42 (98)
Positive QuantiFERON, n/N (%)	7/8 (88)
Known TB exposure, n/N (%)	5/42 (12)
Abnormal chest imaging, n/N (%)	8/42 (19)

Abbreviations: PPD, purified protein derivative; TB, tuberculosis.



**Figure 1.** Percentage of eyes with improved visual acuity (dark gray bar) and inflammation (light gray bar) after anti-tuberculous therapy.

include a course of ATT. The prudent decision that must be made is whether to initiate treatment for active or latent disease. This is where discussion between ID and ophthalmology providers is crucial. Description of ocular abnormalities can help differentiate active inflammation from an ocular scar, for which treatment of latent disease may be more appropriate. This difference in presentation should be clearly communicated between providers. In addition, any changes noted during the course of treatment indicating a potential change in presumed etiology need to be communicated, because treatment may need to be altered.

Risk factors for TB in our study were similar to reported cases in the literature. Foreign-born patients comprised the majority (n = 33, 79%). Of the 9 patients (21%) who were US born, 2 patients had no known TB risk factor. Of these 2 patients, 1 patient had a positive PPD (size not recorded) and QuantiFERON assay but declined ATT with subsequent gradual resolution of uveitis. The second patient had a positive PPD of 24 mm and took ATT for 6 months with improvement of uveitis.

Treatment of TB carries significant morbidity and associated cost [22]. Patients require close follow up with ophthalmology and ID specialists for a multidisciplinary approach to management. Sometimes a change in the clinical picture or evolution of ocular lesions during the treatment course may suggest an alternative diagnosis. For example, there was one patient with anterior uveitis who was treated for presumed TB-AOI. A few months into treatment, her exam became more consistent with a viral etiology of her uveitis. This new information was not communicated to the ID provider, thus no change to her ATT resulted. The decision to initiate treatment is not without risk. Adverse effects were relatively common in our patient population, with nausea being the most prevalent in 20% of patients

who took ATT. These adverse effects significantly altered treatment courses in 6 patients (15%).

Patients were screened for other etiologies that can cause ocular inflammation. There were some patients that tested positive for ANA, RF, or ACE level. No patient included in the study was believed to have a true positive ancillary test secondary to absent clinical correlation. These tests are known to be false positive at times, and they are often difficult to interpret without a suggestive history and clinical findings.

Of the patients who underwent ATT, 42 eyes (74%) demonstrated stable or improved vision, whereas 15 eyes (26%) had worsening vision (Figure 1). Overall, 73% of patients had improvement in inflammation with ATT, which is consistent with previous reports of disease control rates ranging from 40% to 81% [6]. No patients with intermediate uveitis had documented progression of disease, perhaps suggesting a better prognosis for this location. There was discrepancy in some cases that had improvement of inflammation yet worsening visual acuity. This may be explained by sequelae of inflammatory conditions of the eye, including cataracts and glaucoma, which can cause significant vision loss on their own.

Corticosteroid use in TB-AOI is an area of much speculation. From our experience and literature review, there is a lack of data to provide guidance. In our cohort, 49 of 60 eyes received topical steroids. Because topical steroids have limited penetration into the posterior segment of the eye, it is generally accepted among ophthalmologists that topical steroids are best used when inflammation is seen in the anterior segment. The topical route is inefficient in delivering therapeutic concentrations of a drug to the posterior segment, owing to rapid drainage through the nasolacrimal ducts, low permeability of the corneal epithelium, systemic absorption, and the blood-aqueous barrier

[23, 24]. When posterior segment involvement is seen, topical steroids are less likely to be useful, although this varies between experiences among ophthalmologists. Of the 49 eyes that received topical steroids, only 3 eyes had worsening inflammation. Of those 3, 1 eye was primarily posterior involvement.

Fourteen of 60 eyes received systemic steroids. They were started most commonly because of posterior segment involvement, in particular optic nerve disease. Of the patients who received systemic steroids, none of them had worsening ocular inflammation, but there was 1 episode of relapse. Thirteen of 14 patients had posterior uveitis, intermediate uveitis, or optic neuropathy. Only 1 patient who received systemic steroids had anterior uveitis, and this patient was the only one who had worsening inflammation. Given the low number of eyes in this subset of data, a definitive conclusion as to whether systemic steroids are useful could not be made. Risk of recurrence of TB-AOI in patients treated with systemic steroids has been suggested [6], but further research is necessary.

Patients with pulmonary or extrapulmonary TB are not routinely screened for ocular involvement. Tognon et al [9] reported 8.3% of patients with pulmonary or extrapulmonary TB who underwent ophthalmologic screening were found to have ocular involvement despite only 1 of 17 patients having symptomatic visual impairment. The authors raised the question of whether all patients with a known or presumed diagnosis of TB should undergo ophthalmologic screening examinations.

## CONCLUSIONS

There were a number of limitations to our study. It was retrospective and included a time period before and after implementation of an electronic medical record, so ascertainment was not uniform. Our inclusion criteria included positive TB screening tests along with active eye inflammation. This may have allowed patients to be included who had inflammation secondary to other etiologies. Despite our best efforts to exclude these patients, data were lacking in some patients regarding other possible etiologies of ocular inflammation. Moreover, no study has validated the role of evaluation for alternative diagnosis before treatment. As a result, management relies heavily on the ophthalmologic assessment. Despite being one of the larger recent studies in a low disease prevalent area, it was still limited by sample size. In addition, our study may not be generalizable for other areas of the country, because we serve a mostly lower socioeconomic population. Further studies are needed to determine the most effective and safe management of these complicated cases.

## Acknowledgments

**Potential conflicts of interest.** All authors: No reported conflicts. All authors have submitted the ICMJE Form for Disclosure of Potential Conflicts of Interest.

## References

1. World Health Organization. Global tuberculosis report 2013. Available at: [http://apps.who.int/iris/bitstream/10665/91355/1/9789241564656\\_eng.pdf](http://apps.who.int/iris/bitstream/10665/91355/1/9789241564656_eng.pdf). Accessed 3 January 2014.
2. Gupta V, Gupta A, Rao NA. Intraocular tuberculosis—an update. *Surv Ophthalmol* **2007**; 52:561–87.
3. Centers for Disease Control and Prevention. Reported tuberculosis in the United States 2013. Available at: <http://www.cdc.gov/tb/statistics/reports/2013/pdf/report2013.pdf>. Accessed 7 October 2014.
4. Taylor Z, Nolan CM, Blumberg HM, et al. Controlling tuberculosis in the United States. Recommendations from the American Thoracic Society, CDC, and the Infectious Diseases Society of America. *MMWR Mortal Wkly Rep* **2005**; 54:1–81.
5. Demirci H, Shields CL, Shields JA, Eagle RC Jr. Ocular tuberculosis masquerading as ocular tumors. *Surv Ophthalmol* **2004**; 49:78–89.
6. Patel SS, Saraiya NV, Tessler HH, Goldstein DA. Mycobacterial ocular inflammation: delay in diagnosis and other factors impacting morbidity. *JAMA Ophthalmol* **2013**; 131:752–8.
7. Jabs DA, Nussenblatt RB, Rosenbaum JT; Standardization of Uveitis Nomenclature (SUN) Working Group. Standardization of uveitis nomenclature for reporting clinical data. Results of the First International Workshop. *Am J Ophthalmol* **2005**; 140:509–16.
8. Cutrufello NJ, Karakousis PC, Fishler J, Albin TA. Intraocular tuberculosis. *Ocul Immunol Inflamm* **2010**; 18:281–91.
9. Tognon MS, Fiscoon M, Mirabelli P, et al. Tuberculosis of the eye in Italy: a forgotten extrapulmonary localization. *Infection* **2014**; 42:335–42.
10. Vasconcelos-Santos DV, Zierhut M, Rao NA. Strengths and weaknesses of diagnostic tools for tuberculous uveitis. *Ocul Immunol Inflamm* **2009**; 17:351–5.
11. Gupta A, Bansal R, Gupta V, et al. Ocular signs predictive of tubercular uveitis. *Am J Ophthalmol* **2010**; 149:562–70.
12. Arora SK, Gupta V, Gupta A, et al. Diagnostic efficacy of polymerase chain reaction in granulomatous uveitis. *Tuber Lung Dis* **1999**; 79:229–33.
13. Ang M, Htoon HM, Chee SP. Diagnosis of tuberculous uveitis: clinical application of an interferon-gamma release assay. *Ophthalmology* **2009**; 116:1391–6.
14. Bramante CT, Talbot EA, Rathinam SR, et al. Diagnosis of ocular tuberculosis: a role for new testing modalities? *Int Ophthalmol Clin* **2007**; 47:45–62.
15. Morimura Y, Okada AA, Kawahara S, et al. Tuberculin skin testing in uveitis patients and treatment of presumed intraocular tuberculosis in Japan. *Ophthalmology* **2002**; 109:851–7.
16. Lorenc V, González-Martin J, Keller J, et al. Indirect supportive evidence for diagnosis of tuberculosis-related uveitis: from the tuberculin skin test to the new interferon gamma release assays. *Acta Ophthalmol (Copenh)* **2013**; 91:e99–107.
17. Kurup SK, Chan CC. *Mycobacterium*-related ocular inflammatory disease: diagnosis and management. *Ann Acad Med Singapore* **2006**; 35:203–9.
18. Oluleye TS. Tuberculous uveitis. *J Multidiscip Healthc* **2013**; 6:41–3.
19. Yeh S, Sen HN, Colyer M, et al. Update on ocular tuberculosis. *Curr Opin Ophthalmol* **2012**; 23:551–6.
20. Centers for Disease Control and Prevention. Tuberculin skin testing. Available at: <http://www.cdc.gov/tb/publications/factsheets/testing/skintesting.htm>. Accessed 7 October 2014.
21. Cellestis. QuantiFERON-TB Gold [package insert]. Available at: <http://www.fda.gov/downloads/AdvisoryCommittees/CommitteesMeetingMaterials/MedicalDevices/MedicalDevicesAdvisoryCommittee/MicrobiologyDevicesPanel/UCM260551.pdf>. Accessed 7 October 2014.
22. Burman WJ, Dalton CB, Cohn DL, et al. A cost-effectiveness analysis of directly observed therapy vs self-administered therapy for treatment of tuberculosis. *Chest* **1997**; 112:63–70.
23. Gaudana R, Ananthula HK, Parenky A, Mitra AK. Ocular drug delivery. *AAPS J* **2010**; 12:348–60.
24. Thrimawithana TR, Young S, Bunt CR, et al. Drug delivery to the posterior segment of the eye. *Drug Discov Today* **2011**; 16:270–7.