

# Evaluation of effect of submucosal administration of depomedrol in management of postoperative sequelae in mandibular fractures: A randomized clinical trial study

## ABSTRACT

**Introduction:** The mandible is a commonly fractured bone in the face, a fact related to its prominent and exposed position. Open reduction and internal fixation (ORIF) of mandibular fractures has been associated with trauma to the surgical site and the surrounding tissues.

**Purpose:** The purpose of this study is to evaluate the effects of immediate postoperative submucosal depomedrol administration on postoperative pain, edema, and trismus after ORIF for mandibular fractures.

**Materials and Methods:** We conducted a prospective, randomized, controlled, double-blind study of forty patients who required ORIF for mandibular fractures under general anesthesia. The patients were divided into two groups, an experimental group who received immediate postoperative submucosal 40 mg of depomedrol injection through the surgical incision site, and a control group who did not receive any drug. Pain was assessed using a Visual Analog Scale score and the frequency of analgesic consumption at various postoperative intervals. The maximum interincisal distance and facial measurements were compared before surgery and at 24, 48, 72 h, and 7 days after surgery.

**Results:** Statistical analysis of the data indicated a significant decrease in edema, trismus, and pain in the depomedrol group. No clinically apparent infection, disturbance of wound healing, or other corticosteroid-related complications were noted.

**Conclusion:** The results of our study suggest that submucosal administration of depomedrol injection after ORIF for mandibular fractures is effective in reducing postoperative pain, edema, and trismus.

**Keywords:** Depomedrol, mandibular fracture, pain, submucosal, swelling, trismus

## INTRODUCTION

Mandibular fractures are a commonly experienced issue in oral and maxillofacial surgery, that typically requires open reduction and internal fixation (ORIF), and this tissue injury prompts expanded inflammatory response in the perioperative area.<sup>[1-2]</sup> Patients usually experience some amount of functional discomfort at the surgical site.<sup>[3]</sup> This discomfort is due to the common signs and symptoms of ORIF of fractured mandible which includes swelling, pain, and trismus.<sup>[4]</sup> These postoperative sequelae manifests generally as facial edema and muscular spasm.<sup>[5]</sup>

Different techniques have been proposed in the literature to control the postoperative swelling, of which corticosteroids have been broadly utilized in oral and maxillofacial medical

**JANANI KANDAMANI, SUDARSSAN SUBRAMANIAM GOUTHAMAN, DIVYA SANJEEVI RAMAKRISHNAN, M. P. SANTHOSH KUMAR, M. R. MUTHUSEKAR**

Department of Oral and Maxillofacial Surgery, Saveetha Dental College and Hospitals, Saveetha Institute of Medical and Technical Sciences, Saveetha University, Chennai, Tamil Nadu, India

**Address for correspondence:** Dr. Janani Kandamani, Department of Oral and Maxillofacial Surgery, Saveetha Dental College, Saveetha University, Chennai, Tamil Nadu, India. E-mail: jananikandamani@gmail.com


**Received:** 18 June 2020, **Revised:** 21 July 2020, **Accepted:** 31 October 2020, **Published:** 20 April 2022

This is an open access journal, and articles are distributed under the terms of the Creative Commons Attribution-NonCommercial-ShareAlike 4.0 License, which allows others to remix, tweak, and build upon the work non-commercially, as long as appropriate credit is given and the new creations are licensed under the identical terms.

**For reprints contact:** WKHLRPMedknow\_reprints@wolterskluwer.com

**How to cite this article:** Kandamani J, Gouthaman SS, Ramakrishnan DS, Kumar MP, Muthusekar MR. Evaluation of effect of submucosal administration of depomedrol in management of postoperative sequelae in mandibular fractures: A randomized clinical trial study. *Natl J Maxillofac Surg* 2022;13:84-9.

### Access this article online

<b>Website:</b> www.njms.in	<b>Quick Response Code</b> 
<b>DOI:</b> 10.4103/njms.NJMS_118_20	

procedure to control inflammation and the associated symptoms of any maxillofacial procedure for several decades, since corticosteroids are one of the most utilized classes of medications because of their strong anti-inflammatory activity and are relatively safe in healthy patients.<sup>[6]</sup> The anti-inflammatory action of corticosteroids has been used to lessen the edema instigated by the surgery; however, their immediate effects on control of pain and trismus are still controversial.<sup>[7,8]</sup>

Literature is rich with the reports of the parenteral corticosteroid use in oral surgery, but data on the intraoral and submucosal administration route is scarce. There have been many studies that have evaluated the effectiveness of dexamethasone and methylprednisolone in third molar surgery using different routes with variable results. To our knowledge, this is the first article that evaluated the effects of submucosal administration of a single dose of 40 mg of depomedrol on postoperative pain, edema, and trismus after ORIF for mandibular fractures.

## MATERIALS AND METHODS

Participants in this double-blinded randomized clinical trial were selected from the outpatients who require ORIF after mandibular fractures simple randomization method. Randomization allocation concealment by sequentially numbered, opaque, sealed envelopes. Approval for the project was obtained from the Institutional Review Board of Saveetha Institute of Medical and Technical Sciences, Chennai, India (SRB Ref No: SRB/SDMDS03/18/OMFS/05). Patient and the assessor were blinded in the study. The patients were divided into two groups of 20 patients each as shown in Flow Diagram 1. The experimental group received immediate postoperative submucosal infiltration of 40 mg Depomedrol in the vicinity of the surgical site, and the control group did not. All the patients in the present study underwent surgery using a standard technique under general anesthesia by the same operator who was kept unaware of the study details. After surgical exposure, reduction, fixation and closure of the incision site of the mandibular fracture, the experimental group received 40 mg of depomedrol as a submucosal infiltration in the surgical incision site and the control group did not. In case of multiple fractures, 40 mg of depomedrol was administered at each fracture site. The duration of surgery was recorded.

### Inclusion criteria

- Patients aged 15–60 years who required ORIF for mandibular fractures under general anesthesia were included in the study.

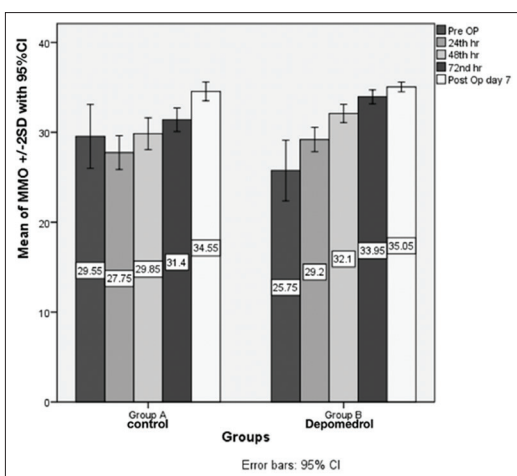
### Exclusion criteria

- Patients with existing systemic illness and comorbidities, pregnancy, history of systemic steroid administration, allergy to any of the components of the trial drug preparation, other associated injuries, or an inability to comprehend pain were excluded from the study.

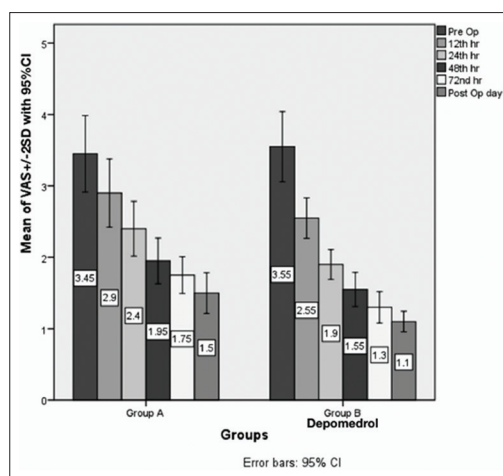
All measurements were performed by a single observer who was unaware of the administration of the medication. Edema and mouth opening were measured preoperatively and 24, 48, and 72 h and 7 days after surgery. Edema was assessed on each side of the fracture as a mean of a 5-line measurement<sup>[9]</sup> using a plastic measuring tape (line 1, gonion to lateral canthus of eye; line 2, tragus to commissure of lip; line; line 3, tragus to midline in chin; line 4, tragus to ala; and line 5, right gonion to left gonion). The mouth opening was measured as the maximum inter incisal distance using a Vernier caliper. Pain was measured using a 10-cm Visual Analog Scale (VAS), experienced after 2, 4, 8, 12, 24, 48, 72 h, and 7 days of ORIF. If the pain intensity (VAS score) exceeded more than 5 (of 10), the patient received an injection of Ketorolac 30 mg intramuscularly during the nothing by mouth period or tablet Diclofenac 50 mg when oral consumption was allowed. If the pain intensity (VAS score) exceeded more than 5 (of 10) even after oral analgesic consumption, an injection of Ketorolac 30 mg intramuscularly was given as a rescue analgesic. Similarly, analgesic usage required 2, 4, 8, 12, 24, 48, 72 h, and 7 days after ORIF was recorded. The collected data were analyzed.

## RESULTS

A total of 40 patients were recruited in this study, 37 were male patients and 3 were female patients. The mean age ( $\pm$  standard deviation) of subjects was 28.3 (8.73) years and 34.80 (10.28) years, Groups A and B, respectively. An isolated angle fracture was present in 11 patients and was the most frequent; symphysis with condyle fracture occurred in 5 patients and was also more frequent than that of other types, as shown in Table 1. The fracture sites were almost equally distributed in two groups. The cause of the mandible fracture was a road traffic accident for 21 patients, an injury from a fall for 5, physical assault for 9, sports-related injury for 3 patient, domestic violence for 1 patient, and an industrial injury for 1 patient. Both groups were comparable with respect to the interval between the trauma and surgery ( $P > 0.05$ ) and duration of surgery, as shown in Table 2. Statistically significant differences were found between the groups in the limitation of mouth opening, as shown in Graph 1, 48, and 72 h postoperatively ( $P = 0.028^*$ , 0.001) by the unpaired *t*-test and statistical significance difference at  $P < 0.05$



Graph 1: Measurement of Trismus at different intervals. Graph 1 shows at the seventh post-operative day patient in both the groups have improvement in maximum mouth opening clinically.



Graph 2: Measurement Of VAS Score At different intervals The results of VAS score on 1st, 2nd, and 7th POD are significant at P < 0.05 level and highly sig-nificant at P < 0.01 level, as shown in Graph 2.

level, respectively. Pain was calculated in terms of a Visual Analog Scale from subjective analysis ranging from 0 to 10. A significant increase of pain as seen in graph 2 was reported in the control group compared to depomedrol group during the 1<sup>st</sup>, 2<sup>nd</sup>, 3<sup>rd</sup>, and 7<sup>th</sup> postoperative days ( $P = 0.023^*$ ,  $0.043^*$ ,  $0.008^*$ ,  $0.014^*$ ) by unpaired *t*-test and statistical significance difference At  $P < 0.05$  level was evident. Comparison of edema at different postoperative intervals 48 and 72 h ( $P = 0.043^*$ ,  $0.0232^*$ ) between control and experimental groups by unpaired *t*-test shows statistical significance difference at  $P < 0.05$  level, as shown in Table 3.

DISCUSSION

The usage of corticosteroids is vast but crucial.<sup>[10]</sup> No wonder, Cortisol (hydrocortisone) is called the “life-protecting hormone” and Aldosterone, the “life-saving hormone.”<sup>[11,12]</sup> Corticosteroids are used for the treatment of various diseases relating to the oral and maxillofacial region. They are also widely used to minimise the postoperative morbidities after oral and maxillofacial surgeries.<sup>[13,14]</sup>

The surgical extraction of impacted mandibular third molars is one of the most commonly performed procedures in oral surgery.<sup>[15,16]</sup> Different doses of dexamethasone, (4 or 8 mg) as submucosal injection, when evaluated the effect on postoperative sequelae and quality of life (QOL) after third molar surgery, found no statistically significant differences were observed between the 2 dosage regimens of dexamethasone but was an effective therapeutic strategy for improving the QOL after surgical removal of impacted lower third molars with a comparable effect on postoperative sequelae to intramuscular injection.<sup>[17,18]</sup> These results were similar to few other studies.<sup>[19,20]</sup>

Table 1: Frequency of site of mandibular fractures

Fracture type	No of patients
Isolated fractures	
Parasymphysis	6
Angle	11
Body	1
Condyle	2
Symphysis	1
Multiple fractures	
Symphysis and condyle	5
Parasymphysis and condyle	2
Parasymphysis and bilateral condyle	2
Bilateral parasymphysis and condyle	1
Bilateral condyle and symphysis	1
Angle and symphysis	1
Parasymphysis and angle	4
Bilateral parasymphysis	1
Condyle and body	1
Ramus and parasymphysis	1

Table 2: Comparison of interval between trauma and surgery and duration of surgery between depomedrol and control group by independent sample t-test and unpaired t-test – no statistical significance at P>0.05 level

Comparison of interval between trauma and surgery				
Groups	n	Mean ± SD	t	P
Interval between trauma and surgery				
Group A	20	8.85 ± 8.32	0.233	0.817#
Group B	20	8.25 ± 7.95		
Duration of surgery				
Group A	20	124.75 ± 52.00	0.097	0.923#
Group B	20	126.50 ± 61.56		

#No Statistical significance at P>0.05 level. Both groups were comparable with respect to the interval between the trauma and surgery and duration of surgery (P>0.05). SD: Standard deviation

ORIF is a surgical treatment modality for mandibular fractures that has been associated with pain, trismus, swelling, and

postoperative morbidity that negatively affects a patient's QOL.<sup>[21,22]</sup> In the present study, all the patients underwent ORIF by a single surgeon who was unaware of the study details. No significant variation was found in patient gender ratio, use of antibiotics, interval between the trauma and surgery, or operative time except for patient age distribution, which was statistically significant ( $P < 0.05$ ) between the 2 groups in the study; thus, all these variables were equally distributed in the 2 groups. Because fracture severity can affect the outcomes of the study, patients with comminuted, infected fractures were excluded from the present study. However, multiple fractures of the mandible were included in the study owing to the limited duration of the thesis study period.

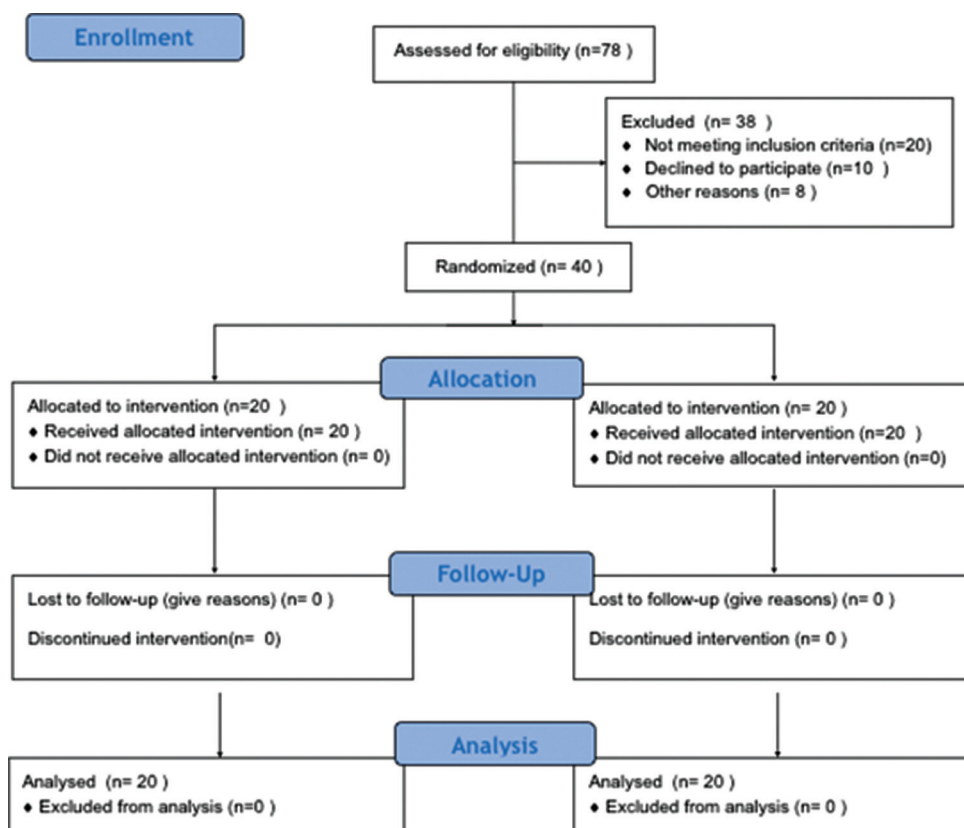
**Table 3: Comparison of edema at different postoperative intervals between control and experimental groups by unpaired t-test statistical significance difference at  $P < 0.05$  level**

Groups	Mean±SD	P
48 h		
Group A	149.21±8.046	0.043*
Group B	144.57±5.7886	
72 h		
Group A	146.87±8.007	0.0232*
Group B	141.38±6.604	

A comparison of the edema from preoperatively to 72 h postoperatively showed significant differences (\* $P=0.043$  at 48 hr and  $P=0.0232$  at 72 hr) where  $P < 0.05$  between the experimental and control group. SD: Standard deviation

The occurrence of multiple fractures was almost equally distributed between the 2 groups with no statistically significant influence on the results. Submucosal administration of Depomedrol immediately in the postoperative period significantly reduced the incidence of swelling at the point of maximum edema in our study, which is Consistent with the findings from other studies of submucosal dexamethasone in third molar extraction<sup>[23,24]</sup> and mandibular fractures.<sup>[25]</sup> Submucosal depomedrol significantly reduced the severity of edema in our study.

The reasons for postoperative infection after mandibular fracture could have been poor oral hygiene, a poor condition of the teeth in the fracture line, unsatisfactory patient compliance, fracture severity, aging, substance abuse, preexisting systemic diseases, and so forth. The adverse effects associated with corticosteroid use include Cushing syndrome, hypothalamic-pituitary adrenal suppression, posterior sub capsular cataracts, glaucoma, hypertension, myopathy, osteoporosis, alterations in mood or personality, psychosis, thin fragile skin, and impaired wound healing. Systemic or topical corticosteroids are absolutely contraindicated for patients with active, healed or incompletely healed tuberculosis, ocular herpes simplex, primary glaucoma or acute psychosis. Short-term use has not been associated with the known systemic



Flow Diagram 1: CONSORT flow diagram

side-effects of steroids such as poor wound healing, infection or adrenal suppression. No such postoperative infections were noted in patients included in the present study as only a single dose of corticosteroid drug was administered.<sup>[25,26]</sup>

A prospective study with a greater sample size is required to definitely comment on that stated trend in the reduction of postoperative edema. In addition, including anthropometric points of measurements in the face that do not swell after ORIF for a fracture of a specific site might have masked the overall measurement of edema in our study. Additionally, edema is difficult to quantify accurately. Various methods such as the 3-dimensional optical scanner, facial plethysmography, photography, Holland's facial bow technique, computed tomography,<sup>[25-27]</sup> magnetic resonance imaging<sup>[28]</sup> might have been better than the economic use of a measuring tape and the facial anatomic landmarks. Considering the studies<sup>[29,30]</sup> with the safe use of higher doses of steroids, additional studies should be performed after controlling for other variables, such as oral hygiene, to determine the effective and safe dose. The risk of systemic toxicity will also be reduced with submucosal administration.

## CONCLUSION

Within the limitation of the study:

- This study has shown that the administration of depomedrol has a significant impact in reducing postoperative pain, edema, and trismus following ORIF after mandibular fractures
- The submucosal route of methyl prednisolone acetate administration is a viable alternative to the other routes. Indeed, it exhibited significant comparative advantages over other route of administration. In addition, it offers a safe, simple, cost-effective method, which produces a high concentration of the drug at the operative site, thereby lessening the systemic effects
- It appears that the potential analgesic effect of corticosteroids, if proved with proper randomised controlled trials with higher sample size, possess guarantee to enhance their future compliance of the drug into routine dental practice, despite the fact of remaining controversial and debatable.

## Financial support and sponsorship

Nil.

## Conflicts of interest

There are no conflicts of interest.

## REFERENCES

1. Al-Bishri A, Rosenquist J, Sunzel B. On neurosensory disturbance after sagittal split osteotomy. *J Oral Maxillofac Surg* 2004;62:1472-6.
2. Antunes AA, Avelar RL, Martins Neto EC, Frota R, Dias E. Effect of two routes of administration of dexamethasone on pain, edema, and trismus in impacted lower third molar surgery. *Oral Maxillofac Surg* 2011;15:217-23.
3. Arora SS, Phull T, Kumar I, Kumar A, Kumar N, Singh H. A comparative study of the effect of two dosages of submucosal injection of dexamethasone on postoperative discomfort after third molar surgery: A prospective randomized study. *Oral Maxillofac Surg* 2018;22:225-30.
4. Bangbose BO, Akinwande JA, Adeyemo WL, Ladeinde AL, Arotiba GT, Ogunlewe MO. Effects of co-administered dexamethasone and diclofenac potassium on pain, swelling and trismus following third molar surgery. *Head Face Med* 2005;1:11.
5. Chugh A, Singh S, Mittal Y, Chugh V. Submucosal injection of dexamethasone and methylprednisolone for the control of postoperative sequelae after third molar surgery: Randomized controlled trial. *Int J Oral Maxillofac Surg* 2018;47:228-33.
6. Deo SP. Single-dose of submucosal injection of dexamethasone affects the post operative quality of life after third molar surgery. *J Maxillofac Oral Surg* 2016;15:367-75.
7. Deo SP. Effect of submucosal injection of dexamethasone on post-operative sequelae of third molar surgery. *JNMA J Nepal Med Assoc* 2011;51:72-8.
8. Dionne RA, Gordon SM, Rowan J, Kent A, Brahim JS. Dexamethasone suppresses peripheral prostanoid levels without analgesia in a clinical model of acute inflammation. *J Oral Maxillofac Surg* 2003;61:997-1003.
9. Dongol A, Jaisani MR, Pradhan L, Dulal S, Sagtani A. A randomized clinical trial of the effects of submucosal dexamethasone after surgery for mandibular fractures. *J Oral Maxillofac Surg* 2015;73:1124-32.
10. Graziani F, D' Aiuto F, Arduino PG, Tonelli M, Gabriele M. Perioperative dexamethasone reduces post-surgical sequelae of wisdom tooth removal. A split-mouth randomized double-masked clinical trial. *Int J Oral Maxillofac Surg* 2006;35:241-6.
11. Ibikunle AA, Adeyemo WL, Ladeinde AL. Effect of submucosal or oral administration of prednisolone on postoperative sequelae following surgical extraction of impacted mandibular third molar: A randomized controlled study. *Niger Med J* 2016;57:272.
12. Kanatas AN, Rogers SN. A systematic review of patient self-completed questionnaires suitable for oral and maxillofacial surgery. *Br J Oral Maxillofac Surg* 2010;48:579-90.
13. Kwon PH, Laskin DM, editors. *Clinician's Manual of Oral and Maxillofacial Surgery*. Quintessence Publishing Company; 2001.
14. Kyzas PA. Use of antibiotics in the treatment of mandible fractures: A systematic review. *J Oral Maxillofac Surg* 2011;69:1129-45.
15. Lim D, Ngeow WC. A comparative study on the efficacy of submucosal injection of dexamethasone versus methylprednisolone in reducing postoperative sequelae after third molar surgery. *J Oral Maxillofac Surg* 2017;75:2278-86.
16. Lim D, Ngeow WC. Analgesic effect of submucosal dexamethasone and methylprednisolone in third molar surgery. *Int J Oral Maxillofac Surg* 2017;46:278.
17. Majid OW. Submucosal dexamethasone injection improves quality of life measures after third molar surgery: A comparative study. *J Oral Maxillofac Surg* 2011;69:2289-97.
18. Majid OW, Mahmood WK. Effect of submucosal and intramuscular dexamethasone on postoperative sequelae after third molar surgery: Comparative study. *Br J Oral Maxillofac Surg* 2011;49:647-52.
19. Gordon PE, Lawler ME, Kaban LB, Dodson TB. Mandibular fracture severity and patient health status are associated with postoperative inflammatory complications. *J Oral Maxillofac Surg* 2011;69:2191-7.

20. Meisami T, Musa M, Keller MA, Cooper R, Clokie CM, Sándor GK. Magnetic resonance imaging assessment of airway status after orthognathic surgery. *Oral Surg Oral Med Oral Pathol Oral Radiol Endod* 2007;103:458-63.
21. Rana M, Gellrich NC, von See C, Weiskopf C, Gerressen M, Ghassemi A, *et al.* 3D evaluation of postoperative swelling in treatment of bilateral mandibular fractures using 2 different cooling therapy methods: A randomized observer blind prospective study. *J Craniomaxillofac Surg* 2013;41:e17-23.
22. Richards RN. Side effects of short-term oral corticosteroids. *J Cutan Med Surg* 2008;12:77-81.
23. Ristow O, Hohlweg-Majert B, Kehl V, Koerdt S, Hahnefeld L, Pautke C. Does elastic therapeutic tape reduce postoperative swelling, pain, and trismus after open reduction and internal fixation of mandibular fractures? *J Oral Maxillofac Surg* 2013;71:1387-96.
24. Saravanan K, Kannan R, John RR, Nantha Kumar C. A single pre operative dose of sub mucosal dexamethasone is effective in improving post operative quality of life in the surgical management of impacted third molars: A comparative randomised prospective study. *J Maxillofac Oral Surg* 2016;15:67-71.
25. Seo K, Tanaka Y, Terumitsu M, Someya G. Efficacy of steroid treatment for sensory impairment after orthognathic surgery. *J Oral Maxillofac Surg* 2004;62:1193-7.
26. Thorén H, Snäll J, Kormi E, Numminen L, Fåh R, Iizuka T, *et al.* Does perioperative glucocorticosteroid treatment correlate with disturbance in surgical wound healing after treatment of facial fractures? A retrospective study. *J Oral Maxillofac Surg* 2009;67:1884-8.
27. Tiwana PS, Foy SP, Shugars DA, Marciani RD, Conrad SM, Phillips C, *et al.* The impact of intravenous corticosteroids with third molar surgery in patients at high risk for delayed health-related quality of life and clinical recovery. *J Oral Maxillofac Surg* 2005;63:55-62.
28. Lamey PJ. Drug information handbook for dentistry: Oral medicine for medically-compromised patients and specific conditions. *Br Dent J* 2005;198:248-9.
29. Warraich R, Faisal M, Rana M, Shaheen A, Gellrich NC, Rana M. Evaluation of postoperative discomfort following third molar surgery using submucosal dexamethasone – A randomized observer blind prospective study. *Oral Surg Oral Med Oral Pathol Oral Radiol* 2013;116:16-22.
30. Weber CR, Griffin JM. Evaluation of dexamethasone for reducing postoperative edema and inflammatory response after orthognathic surgery. *J Oral Maxillofac Surg* 1994;52:35-9.