




The Diagnostic Value of p16/Ki67 Dual Immunostaining for Anal Intraepithelial Neoplasia: A Meta-Analysis

American Journal of Men's Health
November–December 1–10
© The Author(s) 2020
Article reuse guidelines:
sagepub.com/journals-permissions
DOI: 10.1177/1557988320977630
journals.sagepub.com/home/jmh


Cheng-Chieh Chen^{1,2*}, Kuan-Chun Hsueh^{3*}, Cheng-Huang Shen^{4*},
Chyi-Huey Bai⁵, Chia-Chang Wu^{6,7,8}, and Yuan-Hung Wang^{1,9}

Abstract

The p16/Ki67 dual immunostaining was performed on anal cytology specimens; this is an anal cancer screening method. A literature search was performed in the BioMed Central, Cochrane Library, Embase, Google Scholar, and PubMed electronic databases for relevant articles. We included studies that discussed the efficacy of p16/Ki67 dual immunostaining for detecting anal intraepithelial neoplasia (AIN). Studies that calculated the diagnostic efficacy on a per-patient basis were included. We excluded review articles, case series, and studies that did not provide sufficient information. We extracted data on true positive, true negative, false positive, and false negative from the included studies to generate pooled sensitivity, specificity, and diagnostic odds ratio (DOR). All analyses were performed with a random-effects model using MetaDiSc 1.4 and MetaDTA. The meta-analysis produced a pooled sensitivity of 0.63 (95% CI: 0.34, 0.86) and specificity of 0.65 (95% CI: 0.46, 0.81) for p16/Ki67 dual immunostaining in detecting AIN. The pooled DOR was 3.26 (95% CI: -0.29, 6.82). A subgroup analysis of HIV-infected men who have sex with men (MSM) demonstrated a pooled sensitivity of 0.75 (95% CI: 0.28, 0.96). p16/Ki67 dual immunostaining might have a higher sensitivity for detecting AIN in HIV-infected MSM. p16/Ki67 dual immunostaining might be more sensitive in HIV-infected MSM and has higher specificity compared to human papillomavirus testing among this high-risk group. p16/Ki67 dual immunostaining might be an adjuvant and potential triage test for anal cytology in anal cancer screening.

Keywords

Anal cytology, anus neoplasms, early detection of cancer, predictive value of tests, p16/Ki67 dual immunostaining

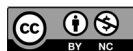Received July 27, 2020; revised October 21, 2020; accepted November 9, 2020

Anal cancer is a rare malignancy with an incidence of 1/100,000 in the general population. The incidence of anal cancer among HIV-infected men who have sex with men (MSM) is higher than that of the general population (Salit et al., 2010). Histologic types of anal cancer include squamous cell carcinoma (SCC), adenocarcinoma, melanoma, and sarcoma (Klas et al., 1999). SCC accounts for approximately 80%–85% of anal cancers (Wisniewski et al., 2017).

High-risk human papillomavirus (HR-HPV) infection in anal canal might lead to anal intraepithelial neoplasia (AIN). HR-HPV types 16 and 18 are identified in 78% of all anal cancers (Morency et al., 2019). AIN refers to precancerous lesions of anal SCC and is graded as AIN 1–3. AIN 1 is defined as low-grade squamous intraepithelial lesion (LSIL); AIN 2 and AIN 3 are considered to be high-grade squamous intraepithelial lesions (HSILs) (do

Socorro Nobre et al., 2016; Donà et al., 2012; Weis, 2013; Williams et al., 2010).

The prevalence of anal HPV type 16 and HSIL were 35.4% and 29.1% in HIV-positive men (Machalek et al., 2012). No high-grade AIN regression was recorded based on a systematic review (Machalek et al., 2012). Anal cytology is the most common screening method for AIN. High-resolution anoscopy combined with a histological examination could be useful as initial diagnostic tools for suspected anal lesions (Gonçalves et al., 2019). The reporting terminology of cytological screening for anal cancer is based on the Bethesda system (Nayar & Wilbur, 2015). Cervical cancer and anal cancer share similarities, including the etiology, tumor biology, and screening modality (Leeds & Fang, 2016). The p16 protein regulates the cell cycle and induces cell-cycle arrest under normal physiological conditions.



Ki67 is a mitotic index and cell proliferation marker. p16/Ki67 dual immunostaining for cervical cancer screening is used on Pap (cervicovaginal) smears in cervical cancer screening. Simultaneous expressions of p16 and Ki67 in a single cervical epithelial cell indicate a positive result and cell-cycle dysregulation (Ebisch et al., 2017). p16 immunostaining showed positive reactivity in 89% of patients diagnosed with high-grade cervical dysplasia (Tsoumpou et al., 2009). Two meta-analyses provided evidence that anal cytology for anal cancer screening had areas of under the receiver operating characteristic curve (AUC) ranging from 0.72 to 0.75 (Chen & Chou, 2019; Gonçalves et al., 2019). p16/Ki67 dual immunostaining performed for cervical cytology is an adjuvant method to improve the diagnostic effectiveness (Chen et al., 2016). A meta-analysis reported a pooled sensitivity of 0.91 for p16/Ki67 dual immunostaining, thus demonstrating its superiority for cervical cancer screening (Chen et al., 2016). The effectiveness of p16/Ki67 dual immunostaining as an adjuvant test for anal cancer screening has not been systematically discussed. Therefore, this research gap is needed to be further investigated. The increased anal cancer risk in HIV-infected populations highlights the needs for evidence on anal dysplasia screening (Silverberg et al., 2015). The increased need for improved screening modalities for anal cancer in high-risk population is required. Anal cytology is one of the screening tools for anal cancer. p16/Ki67 dual immunostaining is an adjuvant method performed on anal cytology samples. To our knowledge, there is no consensus about p16/Ki67 dual immunostaining to improve the accuracy of anal cytology for anal cancer screening. The purpose of the study was to exam the summary performance of p16/Ki67 dual immunostaining for anal cancer screening.

Materials and Methods

Literature Search Strategy

We applied Preferred Reporting Items for a Systematic Review and Meta-analysis of Diagnostic Test Accuracy Studies as the framework for the study and followed the protocol of diagnostic test accuracy for the review (Leeftang, 2014; McInnes et al., 2018). We systematically searched the BioMed Central, Cochrane Library, Embase, Google Scholar, and PubMed electronic databases for relevant studies. We used search terms of (anal cancer or anus neoplasm or anal intraepithelial neoplasia or anal squamous cell carcinoma or AIN or anal precancerous lesions or anal dysplasia) and (p16 or p16 immunocytochemistry or immunostain or Ki67) and (anal cytology or anal Pap test or cytological examination or cytology) and (sensitivity or specificity or accuracy). We applied no time restriction in order to obtain more potentially relevant articles.

Inclusion and Exclusion Criteria

We included articles that discussed the efficacy of p16/Ki67 dual immunostaining performed on anal cytology specimens for detecting AIN. Studies that calculated the diagnostic efficacy on a per-patient basis were included. We excluded review articles, case series, and studies that did not provide sufficient information. There was no study design limit for our study selection. One author screened titles and abstracts for potential studies. After the elimination of irrelevant studies, two reviewers independently examined full-text articles that met the inclusion criteria. Disagreements between the reviewers were resolved through discussions. The last search was performed on July 25, 2020.

¹Graduate Institute of Clinical Medicine, College of Medicine, Taipei Medical University, Taipei, Taiwan

²Department of Pathology and Laboratory Medicine, Shin Kong Wu Ho-Su Memorial Hospital, Taipei, Taiwan

³Department of Surgery, Division of General Surgery, Tungs' Taichung MetroHarbor Hospital, Taichung, Taiwan

⁴Department of Urology, Ditmanson Medical Foundation Chiayi Christian Hospital, Chiayi, Taiwan

⁵Department of Public Health, College of Medicine, Taipei Medical University, Taipei, Taiwan

⁶Department of Urology, Shuang Ho Hospital, Taipei Medical University, New Taipei City, Taiwan

⁷Department of Urology, School of Medicine, College of Medicine, Taipei Medical University, Taipei, Taiwan

⁸TMU Research Center of Urology and Kidney, Taipei Medical University, Taipei, Taiwan

⁹Department of Medical Research, Shuang Ho Hospital, Taipei Medical University, New Taipei City, Taiwan

*These authors contributed equally to this work.

Corresponding Authors:

Yuan-Hung Wang, PhD, Graduate Institute of Clinical Medicine, College of Medicine, Taipei Medical University, 250 Wu-Hsing Street, Taipei 11031, Taiwan.

Email: d508091002@tmu.edu.tw

Chia-Chang Wu, MD, PhD, Department of Urology, Shuang Ho Hospital, Taipei Medical University, 291 Jhongjheng Road, Jhonghe Dist., New Taipei City 23561, Taiwan.

Email: d508094004@tmu.edu.tw

Quality Assessment

We used a tool known as Quality Assessment of Diagnostic Accuracy Studies-2 (QUADAS-2) to assess the quality of included studies (Whiting et al., 2011). Based on QUADAS-2, p16/Ki67 dual immunostaining was the index test, and a histological diagnosis for AIN or SCC was the reference standard. QUADAS-2 has four domains including patient selection, index test, reference standard, and flow and timing. Every domain has questions that help judge the risk of bias of the included studies. Based on QUADAS-2, risk of bias is judged as “low,” “high,” or “unclear.” If the answers to all signaling questions for a domain are “yes,” then risk of bias can be judged low. If any signaling question is answered “no,” potential for bias exists. A study was thought to be of high quality if each domain for the study was judged as having a low risk of bias.

Statistical Analysis

We extracted data of true positive, true negative, false positive, and false negative from the included studies to generate pooled sensitivity, specificity, and diagnostic odds ratio (DOR). Sensitivity was defined as the proportion of people with a illness (target condition) who showed a positive result, whereas specificity was the proportion of people without the illness (target condition) who showed a negative result (Akobeng, 2007). The DOR was defined as sensitivity/(1 – sensitivity) over (1 – specificity)/specificity (Glas et al., 2003). A diagnostic test is discriminative if the DOR of the test is >1 . We graphed the summary receiver operating characteristic (SROC) curve to present the overall diagnostic efficacy of p16/Ki67 dual immunostaining. A perfect diagnostic test shows an area under the SROC curve (AUC) of 1. The AUC of an excellent diagnostic test should be in the region of ≥ 0.97 . An AUC of 0.93–0.96 indicates a very good test, and an AUC of 0.75–0.92 is considered good (Jones & Athanasiou, 2005). All summary estimates were generated with the associated 95% CI. All analyses were performed with a random-effects model using MetaDiSc 1.4 and MetaDTA (Freeman et al., 2019; Zamora et al., 2006). A p value of $<.05$ is considered statistically significant.

Results

Four studies with 687 AIN patients were included (Dupin et al., 2015; Pichon et al., 2019; Serrano-Villar et al., 2017; Wentzensen et al., 2012). Figure 1 is the process of the literature search, and Table 1 lists the characteristics of the studies. Table 2 presents statistical data. The meta-analysis generated a pooled sensitivity of 0.63 (95% CI:

0.34, 0.86) (Figure 2) and specificity of 0.65 (95% CI: 0.46, 0.81) (Figure 3). The pooled DOR was 3.26 (95% CI: -0.29 , 6.82), which indicates that p16/Ki67 dual immunostaining is a discriminative diagnostic test. Figure 4 presents the pooled estimate of p16/Ki67 dual immunostaining in SROC curve. The meta-analysis generated an AUC of 0.69 for p16/Ki67 dual immunostaining (Figure 5).

Subgroup Analysis

A subgroup analysis of p16/Ki67 dual immunostaining for HIV-infected MSM displayed a pooled sensitivity of 0.75 (95% CI: 0.28, 0.96) and specificity of 0.59 (95% CI: 0.41, 0.75). The pooled DOR of p16/Ki67 dual immunostaining for HIV-infected MSM was 4.24 (95% CI: -1.49 , 9.96). p16/Ki67 dual immunostaining might have higher sensitivity in detecting AIN in HIV-infected MSM.

Estimation of Heterogeneity

We performed Cochran’s Q test for the DOR to investigate the heterogeneity across studies. Cochran’s Q test for the DOR presented heterogeneity across the studies ($p = .0001$). The I^2 index for pooled sensitivity (95.4%) was higher than that for pooled specificity (93.2%), which indicated high heterogeneity in both pooled estimates. The I^2 index represents heterogeneity across studies. Values of 25%, 50%, and 75%, respectively, indicate low, moderate, and high levels of heterogeneity (Higgins et al., 2003). Because patient selection might have impact on heterogeneity, we conducted subgroup analyses to evaluate the possible effects. A subgroup analysis of studies that solely enrolled HIV-infected MSM produced I^2 index of 98.2% for the pooled sensitivity. Another subgroup analysis of studies that enrolled patients with pathologically proved LSIL or HSIL produced I^2 index of 0% for the pooled sensitivity.

The strength of evidence of this study is based on a quality assessment. Table 3 presents the quality of the studies. Studies in the meta-analysis had a cross-sectional study design, which is usual for diagnostic accuracy studies (Takwoingi & Quinn, 2018). Two studies reported that patient enrollment was consecutive (Dupin et al., 2015; Pichon et al., 2019). No study demonstrated that the index test was interpreted without knowledge of the reference standard. One article presented that the reference standard was interpreted without knowledge of the index test (Dupin et al., 2015). No study in the meta-analysis recorded that all patients received a reference standard. Patients of the studies in our meta-analysis matched the review question.

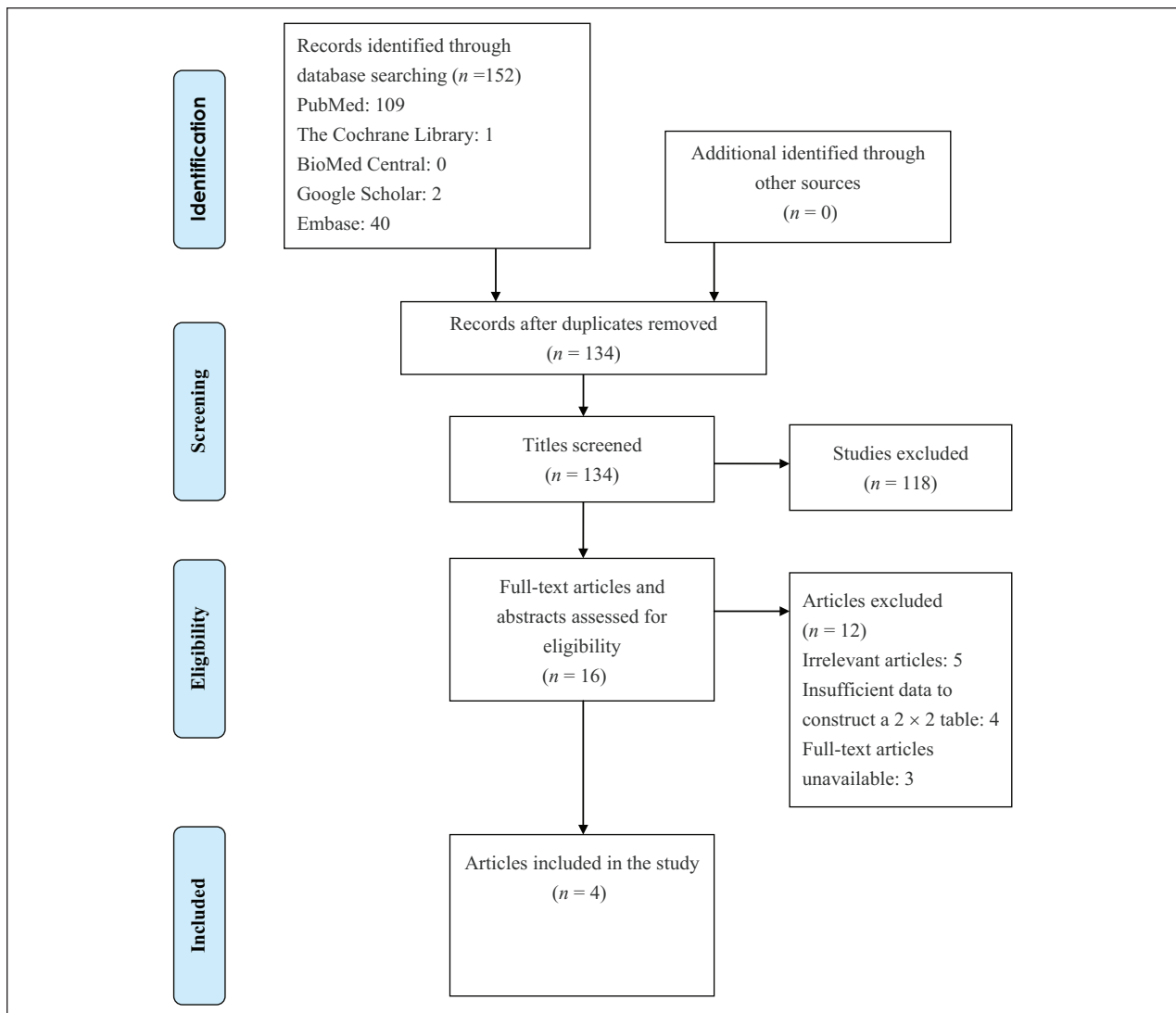


Figure 1. Flow Diagram of Literature Search.

Discussion

The main finding of our study identified that p16/Ki67 dual immunostaining had moderate sensitivity and specificity for detecting AIN. Our study generated a pooled DOR of 3.26 (95% CI: -0.29, 6.82), indicating that p16/Ki67 dual immunostaining might be capable of predicting AIN in the anal cytological specimens. A previous meta-analysis reported that p16/Ki67 dual immunostaining might be more accurate than p16 alone in anal cytology in detecting anal precancer and cancer (Clarke & Wentzensen, 2018).

Burgos et al. (2017) demonstrated that HPV testing had sensitivity of 0.90 and specificity of 0.24 in detecting AIN and suggested that HPV testing should not replace anal cytology in anal cancer screening (Burgos et al.,

2017). HPV testing is not recommended as an initial screening method for anal cancer in HIV-infected MSM owing to the high prevalence of HPV infection in this population. False-positive tests might lead to additional clinical workup (Clarke & Wentzensen, 2018). According to the subgroup analysis of our study, the pooled specificity of p16/Ki67 dual immunostaining for detecting AIN in HIV-infected MSM was 0.59 (95% CI: 0.41, 0.75), which was higher than that (0.24) of HPV testing (Burgos et al., 2017). Cytology combined with HPV testing (co-testing) is recommended every 5 years in women aged 30–65 years in cervical cancer screening (Kim et al., 2018). However, this co-testing for anal cancer was not considered for a screening tool in HIV-infected MSM due to a lower specificity (Burgos et al., 2017).

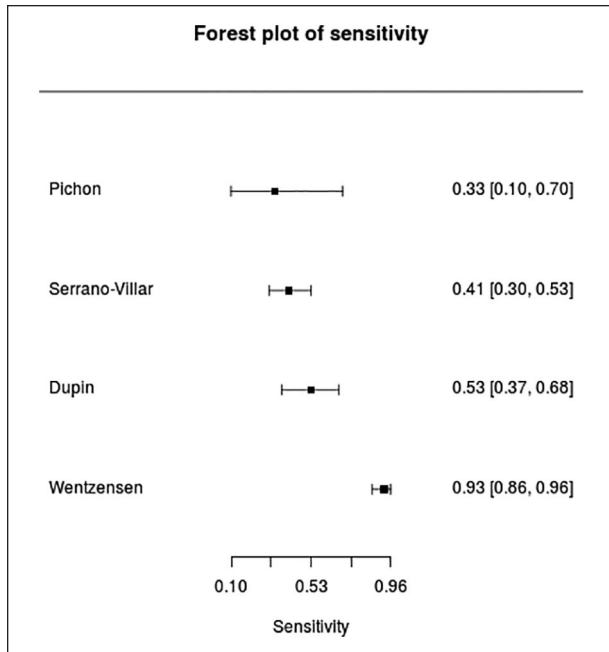
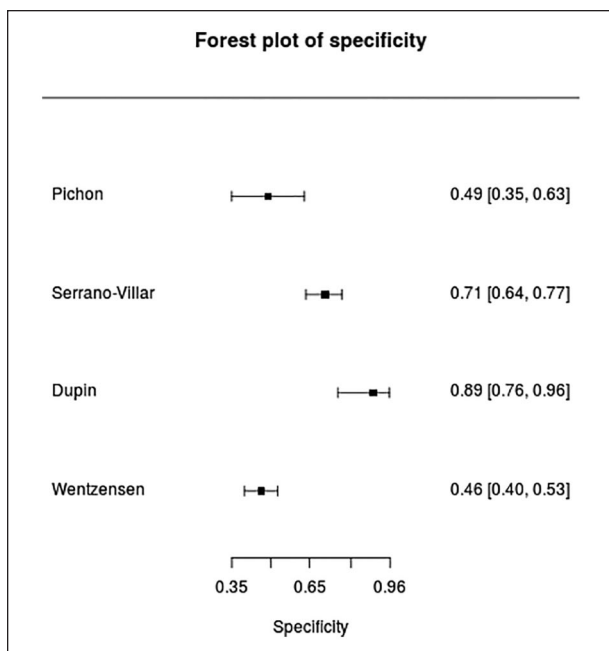
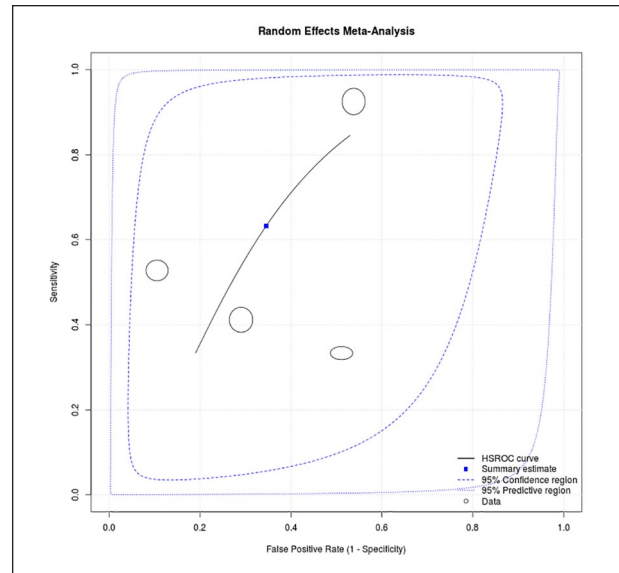
Table 1. Characteristics of Studies in the Meta-analysis.

Study	Study Design	Gender	No. of Specimen (Total / Data Extraction)	Mean Age (Range)	Specimen Type	Triage	Index Test	Detection	Comparator	Reference Standard	Histologic Type
Pichon et al. (2019)	Prospective, consecutive	HIV-positive and HIV-negative patients	(82/51)	46.5 (median) 19-70	LBC (ThinPrep)	ASCUS	p16/Ki67 dual stain (CINtec PLUS Kit)	HSIL	HPV genotyping	Biopsy, cytology	LSIL, HSIL
Serrano-Villar et al. (2017)	Prospective, cross-sectional	HIV- infected MSM	(328/230)	39 ± 10	LBC (ThinPrep)	NA	p16/Ki67 dual stain (CINtec PLUS Kit)	HSIL	Cytology	Biopsy	LSIL, HSIL
Dupin et al. (2015)	Cross-sectional	HIV-infected patients including MSM and women with HPV-related genital lesions	(120/74)	47 (21-79)	LBC (ThinPrep)	HPV E6/E7 mRNA positive	p16/Ki67 dual stain (CINtec PLUS Kit)	HSIL	NA	Histologically confirmed cytological diagnosis of HSIL	LSIL, HSIL
Wentzensen et al. (2012)	Prospective, cross-sectional	HIV- infected MSM	(363/332)	53 (median) 26-79	LBC (ThinPrep)	NA	p16/Ki68 dual stain (CINtec PLUS Kit)	AIN 2 or worse	Cytology	Histology	AIN2, AIN3

AIN = anal intraepithelial neoplasia; ASCUS = atypical squamous cell of undetermined significance; HIV = human immunodeficiency virus; HPV = high-grade squamous intraepithelial lesion; HR-HPV = high-risk human papillomavirus; LBC = liquid-based cytology; LISL = low-grade squamous intraepithelial lesion; MSM = men who have sex with men; NA = not available. Manufacturer: CINtec PLUS Kit (Roche Diagnostics); ThinPrep (Hologic Inc.).

Table 2. Statistical Data for the Meta-analysis.

Study	True Positive	False Positive	False Negative	True Negative
Pichon et al. (2019)	2	23	4	22
Serrano-Villar et al. (2017)	28	47	40	115
Dupin et al. (2015)	19	4	17	34
Wentzensen et al. (2012)	99	121	8	104

**Figure 2.** Forest Plot Showing the Pooled Sensitivity.**Figure 3.** Forest Plot Showing the Pooled Specificity.**Figure 4.** The Summary Receiver Operating Characteristic Curve.

Anal cytology has higher sensitivity in detecting AIN among HIV-infected MSM (Clarke & Wentzensen, 2018). Based on the subgroup analysis, our investigation presented higher sensitivity of p16/Ki67 dual immunostaining in detecting AIN in HIV-infected MSM. Despite the higher incidence of AIN among HIV-infected MSM, no routine screening method for anal cancer has been implemented. The excision of anal HSIL lesions has not been proven to reduce the incidence of anal cancer (Palefsky, 2015). The ANCHOR (Anal Cancer/HSIL Outcomes Research) study is an ongoing clinical trial to demonstrate the efficacy of HISL treatment for reducing the risk of anal cancer. If the ANCHOR study revealed that excision of HSIL lesions leads to significant reduction of anal cancer, anal cytology might be one of the main components in anal cancer screening (Palefsky, 2015). Further anoscopy was recommended for patients with positive anal cytology (Palefsky, 2015). Over 50% of anal cancer patients might be misdiagnosed, and 25% had symptoms before the diagnosis was established (Bingmer et al., 2020).

Current evidence suggests that anal cytology is more appropriate for anal cancer screening owing to low false positives, compared with high-risk HPV testing (Clarke & Wentzensen, 2018). A systematic review involving eight

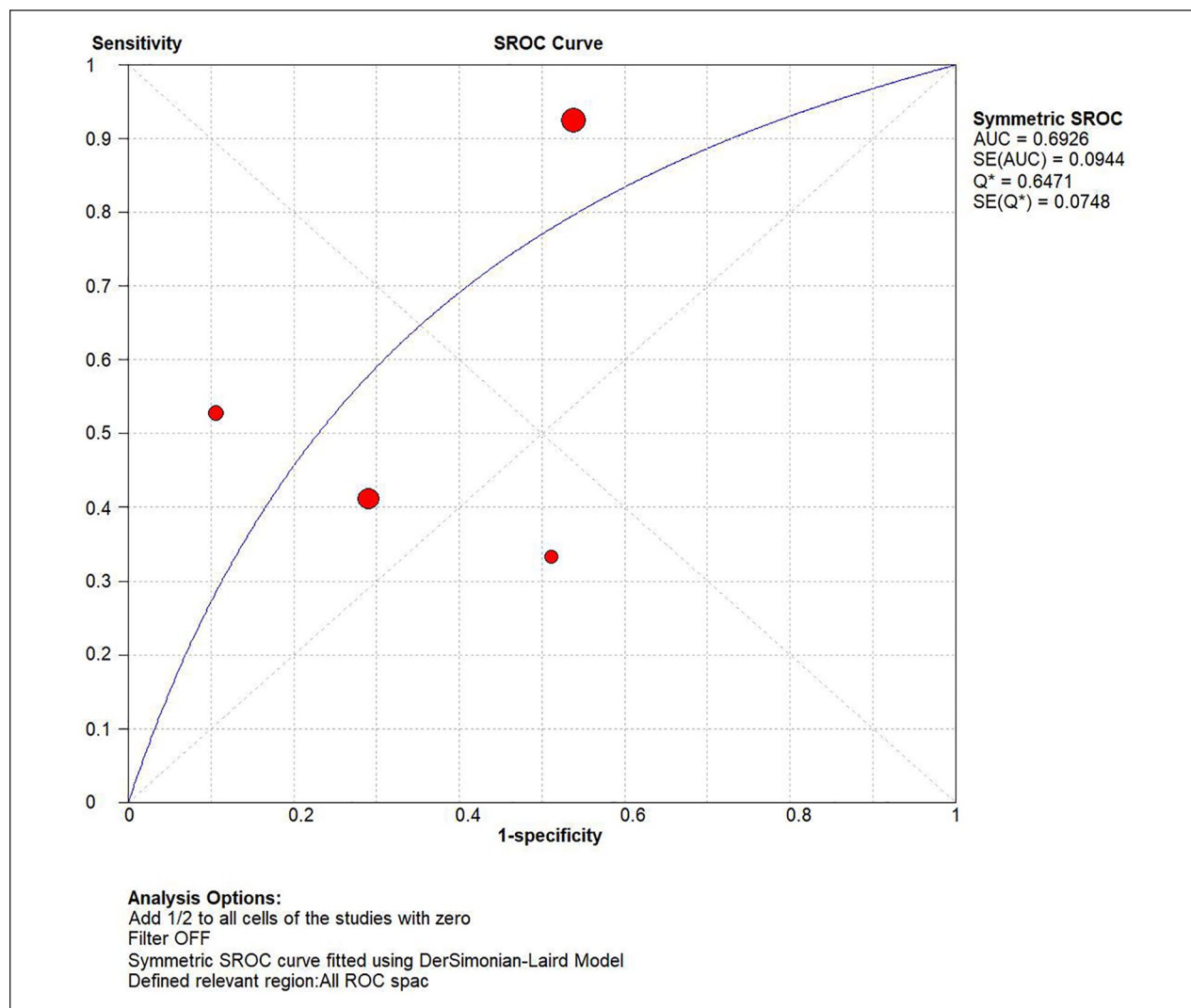


Figure 5. The SROC Curve Showing an AUC of 0.69 for p16/Ki67 Dual Immunostaining. AUC: area under the receiver operating characteristic curve; SROC = summary receiver operating characteristic.

society or institutional recommendations suggests that anal cytology is a method for anal cancer screening in high-risk population, including MSM (Albuquerque et al., 2019). Our findings suggest that p16/Ki67 dual immunostaining might be an adjuvant and potential triage test for anal cytology in anal cancer screening (Bossuyt et al., 2006).

Patient selection, study design, the role of index test, and grade of AIN might be sources of heterogeneity across study. A subgroup analysis of three studies using prospective study design produced lower I^2 index (92.0%) for pooled specificity. Two studies did not report that patient enrollment was random. Patient populations of studies in the meta-analysis consist of HIV-infected MSM, women with HPV-related genital lesions, and HIV-positive and HIV-negative patients. Two studies in the meta-analysis discussed the efficacy of p16/Ki67 dual immunostaining as a triage test for detecting AIN. A

subgroup analysis of two studies assessing the value of p16/Ki67 dual immunostaining as a triage method produced I^2 index of 0% for the pooled sensitivity. One study only enrolled pathologically proven HSIL patients. A subgroup analysis of studies that enrolled patients with pathologically proved LSIL or HSIL produced I^2 index of 0% for the pooled sensitivity and lower I^2 index of 88.3% for the pooled specificity.

Although we found a potential diagnostic value of p16/Ki67 dual immunostaining for AIN, these findings should be interpreted with caution because this meta-analysis still had some limitations. First, no article recorded that the index test was interpreted without knowledge of the result of a reference standard. Second, no study in the meta-analysis recorded that all patients were included in the analysis. Therefore, large-scale trials of p16/Ki67 dual immunostaining for anal cytology specimens are required and future

Table 3. Methodological Quality of Studies.

Study	Risk of Bias				Applicability Concerns		
	Patient Selection	Index Test	Reference Standard	Flow and Timing	Patient Selection	Index Test	Reference Standard
Pichon et al. (2019)	L	U	H	H	L	L	H
Serrano-Villar et al. (2017)	U	U	U	H	L	L	L
Dupin et al. (2015)	L	U	L	H	L	H	L
Wentzensen et al. (2012)	U	U	U	H	L	L	L

H = high risk of bias; L = low risk of bias; U = unclear risk of bias.

studies emphasizing blind interpretation of the index test are needed to improve the quality of studies discussing the performance of p16/Ki67 dual immunostaining in anal cancer screening.

In conclusion, our investigation indicated that p16/Ki67 dual immunostaining might be effective in detecting AIN in anal cytology. We recommend that p16/Ki67 dual immunostaining might be useful and feasible if anal cytology is used as an initial screening modality in anal cancer screening.

Author contributions

CCC, CHB, and YHW were responsible for the conception, design, and acquisition of data, CCC and CCW drafting the initial manuscript and revising it critically for important intellectual content. CHB, CHS, and KCH analyzed and interpreted the data. YHW wrote the final draft. All authors read and approved the final manuscript.



Declaration of Conflicting Interests

The author(s) declared no potential conflicts of interest with respect to the research, authorship, and/or publication of this article.

Funding

The author(s) disclosed receipt of the following financial support for the research, authorship, and/or publication of this article: This study was supported by grants from Tung's Taichung Metroharbor Hospital (Grant no.: TTM-TMU-104-01) and Shuang Ho Hospital, Taipei Medical University (Grant no.: 106TMU-SHH-25).

ORCID iDs

Cheng-Chieh Chen  <https://orcid.org/0000-0002-3748-856X>
Yuan-Hung Wang  <https://orcid.org/0000-0001-5570-2622>

References

- Akobeng, A. K. (2007). Understanding diagnostic tests 1: Sensitivity, specificity and predictive values. *Acta Paediatrica*, *96*(3), 338–341. <https://doi:10.1111/j.1651-2227.2006.00180.x>
- Albuquerque, A., Rios, E., & Schmitt, F. (2019). Recommendations favoring anal cytology as a method for anal cancer screening: A systematic review. *Cancers (Basel)*, *11*(12), 1942. <https://doi:10.3390/cancers11121942>
- Bingmer, K., Ofshteyn, A., Stein, S. L., & Steinhagen, E. (2020). Delayed diagnosis of anal cancer. *Journal of Gastrointestinal Surgery*, *24*(1), 212–217. <https://doi:10.1007/s11605-019-04364-0>
- Bossuyt, P. M., Irwig, L., Craig, J., & Glasziou, P. (2006). Comparative accuracy: Assessing new tests against existing diagnostic pathways. *BMJ*, *332*(7549), 1089–1092. <https://doi:10.1136/bmj.332.7549.1089>
- Burgos, J., Hernández-Losa, J., Landolfi, S., Guelar, A., Dinares, M., Villar, J., Navarro, J., Ribera, E., Falcó, V., & Curran, A. (2017). The role of oncogenic human papillomavirus determination for diagnosis of high-grade anal intraepithelial neoplasia in HIV-infected MSM. *AIDS*, *31*(16), 2227–2233. <https://doi:10.1097/QAD.0000000000001605>
- Chen, C. C., Huang, L. W., Bai, C. H., & Lee, C. C. (2016). Predictive value of p16/Ki-67 immunocytochemistry for triage of women with abnormal Papanicolaou test in cervical cancer screening: A systematic review and meta-analysis. *Annals of Saudi Medicine*, *36*(4), 245–251. <https://doi:10.5144/0256-4947.2016.245>
- Chen, C. C., & Chou, Y. Y. (2019). Predictive value of the anal cytology for detecting anal intraepithelial neoplasia or worse: A systematic review and meta-analysis. *Diagnostic Cytopathology*, *47*(4), 307–314. <https://doi:10.1002/dc.24078>
- Clarke, M. A., & Wentzensen, N. (2018). Strategies for screening and early detection of anal cancers: A narrative and systematic review and meta-analysis of cytology, HPV testing, and other biomarkers. *Cancer Cytopathology*, *126*(7), 447–460. <https://doi:10.1002/cncy.22018>
- do Socorro Nobre, M., Jacyntho, C. M., Eleutério, J., Jr., Giraldo, P. C., & Gonçalves, A. K. (2016). Abnormal anal cytology risk in women with known genital squamous intraepithelial lesion. *The Brazilian Journal of Infectious Diseases*, *20*(3), 294–297. <https://doi:10.1016/j.bjid.2016.01.008>
- Donà, M. G., Benevolo, M., Vocaturo, A., Palamara, G., Latini, A., Giglio, A., Moretto, D., Rollo, F., Impara, G., Ensoli, F., Pimpinelli, F., Di Carlo, A., & Giuliani, M. (2012). Anal cytological abnormalities and epidemiological correlates among men who have sex with men at risk for HIV-1 infection. *BMC Cancer*, *12*, 476. <https://doi:10.1186/1471-2407-12-476>
- Dupin, C., Siproudhis, L., Henno, S., Minjolle, S., Arvieux, C., & Tattevin, P. (2015). Use of human papillomavirus genotyping and biomarkers for targeted screening of anal

- dysplasia in human immunodeficiency virus-infected patients. *Digestive and Liver Disease*, 47(5), 423–428. <https://doi.org/10.1016/j.dld.2015.01.150>
- Ebisch, R. M., van der Horst, J., Hermsen, M., Rijstenberg, L. L., Vedder, J. E., Bulten, J., Bosgraaf, R. P., Verhoef, V. M., Heideman, D. A., Snijders, P. J., Meijer, C. J., van Kemenade, F. J., Massuger, L. F., Melchers, W. J., Bekkers, R. L., & Siebers, A. G. (2017). Evaluation of p16/Ki-67 dual-stained cytology as triage test for high-risk human papillomavirus-positive women. *Modern Pathology*, 30(7), 1021–1031. <https://doi.org/10.1038/modpathol.2017.16>
- Freeman, S. C., Kerby, C. R., Patel, A., Cooper, N. J., Quinn, T., & Sutton, A. J. (2019). Development of an interactive web-based tool to conduct and interrogate meta-analysis of diagnostic test accuracy studies: MetaDTA. *BMC Medical Research Methodology*, 19(1), 81. <https://doi.org/10.1186/s12874-019-0724-x>
- Glas, A. S., Lijmer, J. G., Prins, M. H., Bonsel, G. J., & Bossuyt, P. M. (2003). The diagnostic odds ratio: A single indicator of test performance. *Journal of Clinical Epidemiology*, 56(11), 1129–1135. [https://doi.org/10.1016/s0895-4356\(03\)00177-x](https://doi.org/10.1016/s0895-4356(03)00177-x)
- Gonçalves, J. C. N., Macedo, A. C. L., Madeira, K., Bavaresco, D. V., Dondossola, E. R., Grande, A. J., & da Rosa, M. I. (2019). Accuracy of anal cytology for diagnostic of precursor lesions of anal cancer: Systematic review and meta-analysis. *Diseases of the Colon and Rectum*, 62(1), 112–120. <https://doi.org/10.1097/DCR.0000000000001231>
- Higgins, J. P., Thompson, S. G., Deeks, J. J., & Altman, D. G. (2003). Measuring inconsistency in meta-analyses. *BMJ*, 327(7414), 557–560. <https://doi.org/10.1136/bmj.327.7414.557>
- Jones, C. M., & Athanasiou, T. (2005). Summary receiver operating characteristic curve analysis techniques in the evaluation of diagnostic tests. *The Annals of Thoracic Surgery*, 79(1), 16–20. <https://doi.org/10.1016/j.athoracsur.2004.09.040>
- Kim, J. J., Burger, E. A., Regan, C., & Sy, S. (2018). Screening for cervical cancer in primary care: A decision analysis for the US Preventive Services Task Force. *JAMA*, 320(7), 706–714. <https://doi.org/10.1001/jama.2017.19872>
- Klas, J. V., Rothenberger, D. A., Wong, W. D., & Madoff, R. D. (1999). Malignant tumors of the anal canal: The spectrum of disease, treatment, and outcomes. *Cancer*, 85(8), 1686–1693. [https://doi.org/10.1002/\(sici\)1097-0142\(19990415\)85:8<1686::aid-cnrc7>3.0.co;2-7](https://doi.org/10.1002/(sici)1097-0142(19990415)85:8<1686::aid-cnrc7>3.0.co;2-7)
- Leeds, I. L., & Fang, S. H. (2016). Anal cancer and intraepithelial neoplasia screening: A review. *World Journal of Gastrointestinal Surgery*, 8(1), 41–51. <https://doi.org/10.4240/wjgs.v8.i1.41>
- Leeflang, M. M. (2014). Systematic reviews and meta-analyses of diagnostic test accuracy. *Clinical Microbiology and Infection*, 20(2), 105–113. <https://doi.org/10.1111/1469-0691.12474>
- Machalek, D. A., Poynten, M., Jin, F., Fairley, C. K., Farnsworth, A., Garland, S. M., Hillman, R. J., Petoumenos, K., Roberts, J., Tabrizi, S. N., Templeton, D. J., & Grulich, A. E. (2012). Anal human papillomavirus infection and associated neoplastic lesions in men who have sex with men: A systematic review and meta-analysis. *The Lancet. Oncology*, 13(5), 487–500. [https://doi.org/10.1016/S1470-2045\(12\)70080-3](https://doi.org/10.1016/S1470-2045(12)70080-3)
- McInnes, M. D. F., Moher, D., Thombs, B. D., McGrath, T. A., & Bossuyt, P. M.; and the PRISMA-DTA Group, Clifford, T., Cohen, J. F., Deeks, J. J., Gatsonis, C., Hooff, L., Hunt, H. A., Hyde, C. J., Korevaar, D. A., Leeflang, M. M. G., Macaskill, P., Reitsma, J. B., Rodin, R., Rutjes, A. W. S., Salameh, J. P., . . . Willis, B. H. (2018). Preferred reporting items for a systematic review and meta-analysis of diagnostic test accuracy studies: The PRISMA-DTA statement. *JAMA*, 319(4), 388–396. <https://doi.org/10.1001/jama.2017.19163>
- Morency, E. G., Harbert, T., Fatima, N., Samolczyk, J., Maniar, K. P., & Nayar, R. (2019). Anal cytology: institutional statistics, correlation with histology, and development of multidisciplinary screening program with review of the current literature. *Archives of Pathology & Laboratory Medicine*, 143(1), 23–29. <https://doi.org/10.5858/arpa.2017-0242-RA>
- Nayar, R., & Wilbur, D. C. (2015). The pap test and Bethesda 2014. “The reports of my demise have been greatly exaggerated.” (after a quotation from Mark Twain). *Acta Cytologica*, 59(2), 121–132. <https://doi.org/10.1159/000381842>
- Palefsky, J. M. (2015). Screening to prevent anal cancer: Current thinking and future directions. *Cancer Cytopathology*, 123(9), 509–510. <https://doi.org/10.1002/cncy.21571>
- Pichon, M., Joly, M., Lebreton, F., Benchaïb, M., Mekki, Y., & Devouassoux-Shisheboran, M. (2019). Evaluation of p16/Ki-67 dual staining compared with HPV genotyping in anal cytology with diagnosis of ASC-US for detection of high-grade anal intraepithelial lesions. *Journal of Cytology*, 36(3), 152–156. https://doi.org/10.4103/JOC.JOC_131_18
- Salit, I. E., Lytwyn, A., Raboud, J., Sano, M., Chong, S., Diong, C., Chapman, W., Mahony, J. B., & Timmouth, J. (2010). The role of cytology (pap tests) and human papillomavirus testing in anal cancer screening. *AIDS*, 24(9), 1307–1313. <https://doi.org/10.1097/QAD.0b013e328339e592>
- Serrano-Villar, S., Hernández-Novoa, B., de Benito, A., Del Romero, J., Ocampo, A., Blanco, J. R., Masiá, M., Sendagorta, E., Sanz, G., Moreno, S., & Pérez-Molina, J. A. (2017). Screening for precancerous anal lesions with P16/Ki67 immunostaining in HIV-infected MSM. *PLoS One*, 12(11), e0188851. <https://doi.org/10.1371/journal.pone.0188851>
- Silverberg, M. J., Lau, B., Achenbach, C. J., Jing, Y., Althoff, K. N., D’Souza, G., Engels, E. A., Hessel, N. A., Brooks, J. T., Burchell, A. N., Gill, M. J., Goedert, J. J., Hogg, R., Horberg, M. A., Kirk, G. D., Kitahata, M. M., Korthuis, P. T., Mathews, W. C., Mayor, A., . . . Dubrow, R.; North American AIDS Cohort Collaboration on Research and Design of the International Epidemiologic Databases to Evaluate AIDS. (2015). Cumulative incidence of cancer among persons with HIV in North America: A cohort study. *Annals of Internal Medicine*, 163(7), 507–518. <https://doi.org/10.7326/M14-2768>
- Takwoingi, Y., & Quinn, T. J. (2018). Review of Diagnostic Test Accuracy (DTA) studies in older people. *Age Ageing*, 47(3), 349–355. <https://doi.org/10.1093/ageing/afy023>
- Tsompou, I., Arbyn, M., Kyrgiou, M., Wentzensen, N., Koliopoulos, G., Martin-Hirsch, P., Malamou-Mitsi, V.,

- & Paraskevaïdis, E. (2009). p16INK4a immunostaining in cytological and histological specimens from the uterine cervix: A systematic review and meta-analysis. *Cancer Treatment Reviews*, 35(3), 210–220. <https://doi:10.1016/j.ctrv.2008.10.005>
- Weis, S. E. (2013). Current treatment options for management of anal intraepithelial neoplasia. *OncoTargets and Therapy*, 6, 651–665. <https://doi:10.2147/OTT.S38217>
- Wentzensen, N., Follansbee, S., Borgonovo, S., Tokugawa, D., Schwartz, L., Lorey, T. S., Sahasrabudde, V. V., Lamere, B., Gage, J. C., Fetterman, B., Darragh, T. M., & Castle, P. E. (2012). Human papillomavirus genotyping, human papillomavirus mRNA expression, and p16/Ki-67 cytology to detect anal cancer precursors in HIV-infected MSM. *AIDS*, 26(17), 2185–2192. <https://doi:10.1097/QAD.0b013e328359f255>
- Whiting, P. F., Rutjes, A. W., Westwood, M. E., Mallett, S., Deeks, J. J., Reitsma, J. B., Leeflang, M. M., Sterne, J. A., & Bossuyt, P. M., & QUADAS-2 Group. (2011). QUADAS-2: A revised tool for the quality assessment of diagnostic accuracy studies. *Annals of Internal Medicine*, 155(8), 529–536. <https://doi:10.7326/0003-4819-155-8-201110180-00009>
- Williams, V. M., Metcalf, C., French, M. A., & McCloskey, J. C. (2010). Audit of paired anal cytology and histopathology outcomes in patients referred to a public sexual health clinic. *Sexual Health*, 7(3), 346–351. <https://doi:10.1071/SH09118>
- Wisniewski, A., Fléjou, J. F., Siproudhis, L., Abramowitz, L., Svrcek, M., & Beaugerie, L. (2017). Anal neoplasia in inflammatory Bowel disease: Classification proposal, epidemiology, carcinogenesis, and risk management perspectives. *Journal of Crohn's & Colitis*, 11(8), 1011–1018. <https://doi:10.1093/ecco-jcc/jjx035>
- Zamora, J., Abaira, V., Muriel, A., Khan, K., & Coomarasamy, A. (2006). Meta-DiSc: A software for meta-analysis of test accuracy data. *BMC Medical Research Methodology*, 6, 31. <https://doi:10.1186/1471-2288-6-31>