

Finger and Nail Lesion, Formaldehyde Exposure, and Vegetable for Sale

Dear Editor,

Formaldehyde or formalin is a toxic substance that can induce cancer if one chronically exposed to it. The formaldehyde contamination becomes an interesting health problem.^[1] In developing countries, where there is poor legal control, the contamination of formaldehyde in food is a common problem, and this is a big public health hazard to the local people.^[2] Here, the authors report an interesting case of a patient presenting with abnormal finger and nail lesion. This patient noted that she got the problem for many months. She gave the history that she had practiced as a worker in vegetable preparation for wholesale to markets for 1 year and had to use her hands for dipping of the vegetables in the formaldehyde solution every day before the vegetables are delivered to the markets. She noted that the lesion occurred 1 month after she started her work. The skin lesion is shown in Figure 1. The lesion was provoked when she performed daily work, dipping the vegetable into formaldehyde, and if she sipped for work, the lesion seemed improved. In this case, the patient performed repetitive self-test provocation by testing contact at other parts of her body to formaldehyde and observed the relationship between formaldehyde and dermatological problem.

This is a good case study on the finger and nail lesion according to chemical irritant. Here, formaldehyde is the causative agent. The formaldehyde included dermatitis is sporadically mentioned and is usually relating to cosmetic contamination.^[3] With a clear history of exposure, provocation, and appearance of dermatological problem, the diagnosis of formaldehyde-induced health problem in this patient can be made. Nevertheless, the present case is a good example of occupational health case, and it also

reflects the public health problem. The patient is a worker and has to follow her tricky and bad boss who is the owner of the vegetable wholesale business. It can expect that there will be many formaldehyde-contaminated vegetables in the local markets, and this can be further hidden hazard to general population. The survey of the contamination in vegetable sample collected from the market is needed, and the strict legal control and punishment of the greedy bad businessman are recommended.

Financial support and sponsorship

Nil.

Conflicts of interest

There are no conflicts of interest.

Sora Yasri, Viroj Wiwanitkit¹

KMT Primary Care Center, Bangkok Thailand, ¹Department of Tropical Medicine, Hainan Medical University, Haikou, China

*Address for correspondence: Dr. Sora Yasri,
KMT Primary Care Center, Bangkok, Thailand.
E-mail: sorayasri@outlook.co.th*

Received: 15 Aug 17 **Accepted:** 29 Jan 18

Published: 17 May 19

References

1. Tang X, Bai Y, Duong A, Smith MT, Li L, Zhang L, *et al*. Formaldehyde in China: Production, consumption, exposure levels, and health effects. *Environ Int* 2009;35:1210-24.
2. Restani P, Restelli AR, Galli CL. Formaldehyde and hexamethylenetetramine as food additives: Chemical interactions and toxicology. *Food Addit Contam* 1992;9:597-605.
3. Lundov MD, Johansen JD, Carlsen BC, Engkilde K, Menné T, Thyssen JP, *et al*. Formaldehyde exposure and patterns of concomitant contact allergy to formaldehyde and formaldehyde-releasers. *Contact Dermatitis* 2010;63:31-6.

This is an open access journal, and articles are distributed under the terms of the Creative Commons Attribution-NonCommercial-ShareAlike 4.0 License, which allows others to remix, tweak, and build upon the work non-commercially, as long as appropriate credit is given and the new creations are licensed under the identical terms.

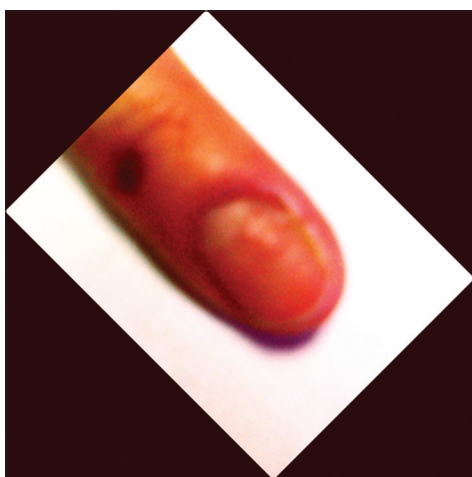


Figure 1: Lesion at finger and nail. The lesion is described as erythematous scaly itching rash with blistering at skin and exfoliative pitting nail. The nail lesion is more predominant at the tip of finger (which can reflect long-term exposure since nail regularly grows)

Access this article online

Quick Response Code:



Website:

www.ijpvmjournal.net/www.ijpvm.ir

DOI:

10.4103/ijpvm.IJPVM_352_17

How to cite this article: Yasri S, Wiwanitkit V. Finger and nail lesion, formaldehyde exposure, and vegetable for sale. *Int J Prev Med* 2019;10:76.

© 2019 International Journal of Preventive Medicine | Published by Wolters Kluwer - Medknow