



Case report

Cranial and intra-axial metastasis originating from a primary ovarian Dysgerminoma[☆]

Tiffany L. Beck^a, Hitomi Momose^b, Jeffrey M. Dym^c, Vikas Y. Rao^d, Randy Bohart^e,
Bram H. Goldstein^{e,*,1}

^a Gynecologic Oncology Associates, Newport Beach, CA, United States of America

^b St. Joseph Health, Department of Pathology, Mission Viejo, CA, United States of America

^c St. Joseph Health, Department of Radiology, Mission Viejo, CA, United States of America

^d St. Joseph Health, Department of Neurosurgery, Mission Viejo, CA, United States of America

^e Oso Home Care, 17175 Gillette Avenue, Irvine, CA 92614, United States of America



ARTICLE INFO

Keywords:

Ovarian dysgerminoma

Cranial metastasis

Treatment

ABSTRACT

Dysgerminomas are aggressive germ cell tumors that typically have a favorable prognosis, especially in patients diagnosed with early stage disease. We recount the history of a 23-year-old woman who was treated for a stage IA ovarian dysgerminoma in November 2017. Postoperatively, the patient was noncompliant insofar as obtaining routine lab evaluations; ten months later, she was diagnosed with a cranial metastasis that extended into the meninges. The patient subsequently underwent a craniotomy and adjuvant etoposide, bleomycin and cisplatin chemotherapy to which she initially responded; however, during cycle 4, she developed pancytopenia whereupon the chemotherapy was summarily discontinued. Thereafter, the patient was surveilled and currently, she remains in clinical remission. Early stage ovarian dysgerminoma, albeit rarely, has the capacity to metastasize to the cranium or brain, further underscoring the significance of employing active follow-up with these patients.

1. Introduction

Dysgerminomas comprise approximately 2% of all ovarian malignancies and nearly 33% of malignant ovarian germ cell neoplasms (Zogbi et al., 2018). They frequently manifest themselves in young adults or adolescents and have a proclivity for rapid growth (Mangili et al., 2011). When they manifest themselves, ovarian dysgerminomas routinely coincide with abdominal distention, pain and menstrual abnormalities (Zogbi et al., 2018).

Dysgerminoma, the ovarian counterpart of testicular seminoma, is composed of undifferentiated germ and large vesicular cells with interspersed, scant fibrous stroma (Zaloudek et al., 1981). They are characteristically unilateral and grossly, resemble a tan-colored, lobulated, firm mass (Gordon et al., 1981). On ultrasound, dysgerminomas are depicted as a highly vascularized, large, solid, lobulated adnexal mass with irregular, internal echogenicity (Guerriero et al., 2011).

Despite their malignant propensity, stage I dysgerminoma patient 5-year survival rates are approximately 90% (Gallion et al., 1988).

Conversely, relapse rates for stage IA disease are nearly 20%, (Patterson et al., 2008) wherein the disease is often identified within the contralateral ovary, pelvis and abdomen (Mangili et al., 2011; A L Husaini et al., 2012).

When dysgerminomas metastasize, the disease is typically encountered in the para-aortic or supraclavicular lymph nodes (Mangili et al., 2011; A L Husaini et al., 2012), whereas the breast is very uncommon (Kattan et al., 1992) and neurologic involvement is exceedingly rare (Afridi et al., 1976; Jolles et al., 1989). In the current study, we recount the extraordinary occurrence of an ovarian dysgerminoma patient who developed metastatic disease that infiltrated her cranium and dura mater.

2. Case report

A 23-year-old, nulligravid woman with a history of polycystic ovary syndrome, migraines and bipolar disorder originally presented to an outside medical facility in November 2017 with pelvic pain and a 11 cm

[☆] This study was supported by the Women's Cancer Research Foundation.

* Corresponding author at: Women's Cancer Research Foundation, 351 Hospital Road, Suite #506, Newport Beach, CA 92663, United States of America.
E-mail address: bram@gynoncology.com (B.H. Goldstein).

¹ Request for reprints: Bram Goldstein, Ph.D., Women's Cancer Research Foundation, 351 Hospital Road, Suite #506, Newport Beach, CA 92663.

pelvic mass depicted on ultrasound. She had a CA-125 of 55.7 U/mL, a negative beta human chorionic gonadotropin (HCG) test, a carcinoembryonic antigen (CEA) of 0.8 ng/mL and alpha-fetoprotein (AFP) < 0.7 ng/mL; her lactate dehydrogenase (LDH) was not measured.

The patient underwent a diagnostic laparoscopy, exploratory laparotomy and right salpingo-oophorectomy for a presumed stage IA dysgerminoma. Postoperatively, a CT scan of the chest, abdomen and pelvis in November 2017 precluded tumor deposits, ascites or adenopathy; notably, the resected right ovary contained a 5 cm cyst. Final pathology revealed a stage IA ovarian dysgerminoma. The patient was subsequently referred to our gynecologic oncology service for surveillance.

In January 2018, the patient's LDH was 361 U/L, her CA-125 was 9 U/mL and a CT scan of the abdomen and pelvis was negative for recurrent disease. She was prescribed bi-monthly evaluations although the patient was non-compliant and only returned in May 2018; nevertheless, she was asymptomatic and her LDH and CA-125 levels were 147 U/L and 3 U/mL, respectively.

In July 2018, the patient complained of neck swelling, malaise, anorexia, abdominal bloating, diarrhea and migratory pain; her CA-125 was 133 U/mL but she neglected to have her LDH levels measured. Additionally, the patient developed a persistent cough and scalp cellulitis for which she was prescribed Bactrim at an urgent care facility.

In September 2018, the patient was admitted to the emergency room for a painful, enlarging right parietal scalp mass; her LDH was > 4000 U/L. Preoperative cranial CT imaging revealed a 6.4 cm × 5.2 cm right posterior lesion infiltrating the right parietal bone with superficial extension into the skull and intra-axial involvement (Fig. 1). The patient subsequently underwent a right parietal craniotomy with resection of the skull mass and attendant dura mater (Fig. 2); a postoperative PET scan was negative for residual disease. The frozen section was consistent with her primary ovarian dysgerminoma (Fig. 3a & b).

In October 2018, the patient's LDH was 271 U/L and her CA-125 was 19 U/mL. She commenced with four cycles of intravenous bleomycin (15 units/wk. on days 1, 8, and 15), intravenous etoposide 120 (mg/m²), and intravenous cisplatin (40 mg/m² on days 1–5); her November 2018 lab values remained stable. Inauspiciously, at cycle 3, the patient's LDH was elevated at 380 U/L but during cycle four, her

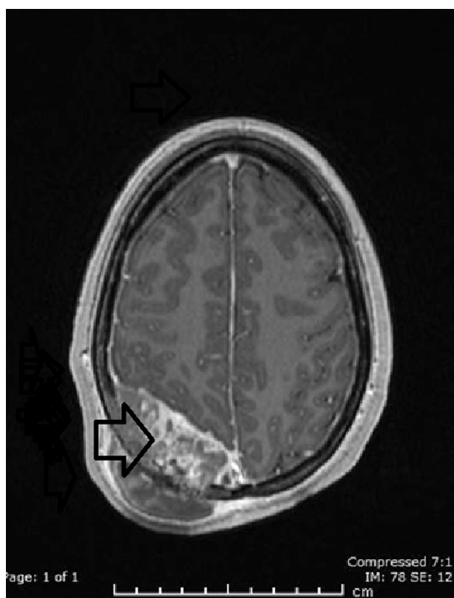


Fig. 1. Axial post contrast MRI demonstrates the aggressive enhancing mass (arrow) involving the right parietal bone with both extra- and intracranial involvement.

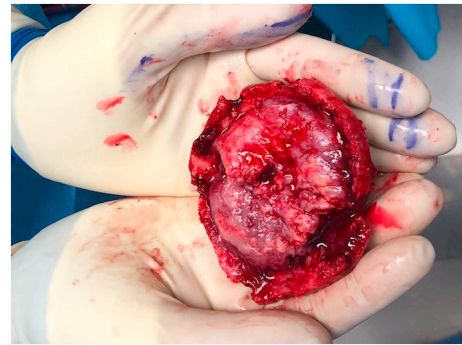


Fig. 2. Gross photograph of the skull through which the metastatic dysgerminoma has invaded.

LDH (254 U/L) and CA-125 (15 U/mL) levels decreased; unfortunately, the patient thereupon developed pancytopenia whereupon the chemotherapy was discontinued. Currently, she is doing well and undergoing routine surveillance by her gynecologic oncologist.

3. Conclusions

Dysgerminomas are aggressive lesions that predominantly infiltrate via direct extension, the lymphatic system or in advanced cases, hematogenously (Mangili et al., 2011; Patterson et al., 2008). Characteristically, they respond favorably to treatment and are associated with an overall 5-year survival rate approximating 90% (Mangili et al., 2011; Gallion et al., 1988). Similarly, relapse rates for dysgerminoma patients with early stage disease are approximately 20% and often attributed to postoperative residual disease (Patterson et al., 2008). In one dysgerminoma study, the 5-year survival rate was 61% for the optimally cytoreduced group (≤ 1 cm), compared with 14% in the sub-optimal surgery cohort (Li and Xiaohua, 2016).

We describe herein, a patient who underwent surgical treatment for a stage IA ovarian dysgerminoma. Postoperatively, she was relatively noncompliant and did not adhere to her prescribed surveillance; within ten months of the patient's initial diagnosis, she developed an ovarian dysgerminoma that was metastatic to the cranium and meninges.

There have been reported studies documenting ovarian dysgerminomas that metastasize to the lymph nodes (A L Husaini et al., 2012) and albeit rarely, the breast (Kattan et al., 1992). However, the identification of an ovarian dysgerminoma metastatic to the brain (Afridi et al., 1976; Jolles et al., 1989), let alone the cranium, is exceptionally uncommon. Jolles et al. reported on an advanced ovarian dysgerminoma patient who developed carcinomatous meningitis while undergoing vinblastine, cisplatin and bleomycin chemotherapy (Jolles et al., 1989). In another study, a 21-year-old woman was treated with a total abdominal hysterectomy, bilateral salpingo-oophorectomy and pelvic radiotherapy (30 Gy) for a stage IB, 25 cm ovarian dysgerminoma (Afridi et al., 1976). However, she recurred in the pelvic lymph nodes within 6 months and afterward developed pulmonary metastases; in both instances, she was treated with radiotherapy. Five months later, the patient complained of a headache and weakness, which was ascribed to a right parietal lobe metastasis originating from her primary disease.

Despite the similarities, our patient had a stage IA dysgerminoma, whereas the aforesaid subjects were afflicted with advanced stage disease. However, we recognize that our patient was initially not surgically staged, which might have eventuated upstaging; accordingly, the potential inclusion of adjuvant chemotherapy may have attenuated the patient's risk for recurrence. Moreover, the two case studies reported on disease involving either the brain parenchyma or extra-parenchymal tissue (Afridi et al., 1976; Jolles et al., 1989); in contradistinction, our patient was afflicted with metastatic cancer that infiltrated the cranium and meninges. While there have been reports depicting cranial

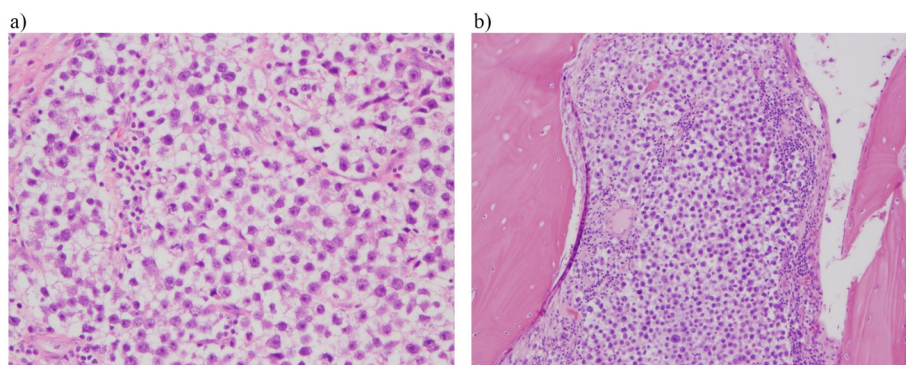


Fig. 3. a. Dysgerminoma in the right ovary. b. Dysgerminoma involving the skull bone, with the morphology identical to that of the right ovarian tumor.

metastases originating from a testicular germ cell tumor (Uygun et al., 2006), we were only able to identify one gynecologic case study involving a mature ovarian teratoma patient whose disease metastasized to the cranial vault (Tokuda et al., 1993).

When managing a dysgerminoma, surgery is not only beneficial but the sine qua non for diagnosis and staging (Mangili et al., 2011). Young patients diagnosed with a dysgerminoma who desire fertility and are at risk for recurrence should be counseled regarding the potential for oocyte/embryo cryopreservation before and/or after the completion of chemotherapy. Bleomycin, etoposide, and cisplatin is an established regimen for advanced disease and an independent prognostic indicator for improved patient outcomes (Mangili et al., 2011). Regrettably, persistent disease may be ultimately discerned in the brain due to the blood-brain barrier's ability to preclude chemotherapy delivery (Weidle et al., 2015); in select cases with CNS disease involvement, radiation therapy may also confer a limited benefit (Fosså et al., 1999). Vigilant surveillance of patients, comprising frequent clinic evaluations, serial tumor marker (e.g., LDH, beta-hCG, CA-125) and routine imaging (Zogbi et al., 2018; Gordon et al., 1981), is strongly recommended.

Declaration of Competing Interests

All authors deny any conflict of interest associated with this manuscript.

Author contributions

TB contributed significantly to the study's initiation, development and manuscript revision.

BG substantially contributed to the study's development and manuscript revision.

HM conducted the review of the patient's pathologic diagnosis and treatment history and also substantially contributed to the study's development and manuscript revision.

JD was instrumental in reviewing the patient's charge and conducting the radiologic evaluation.

RB reviewed the patient's chart, analyzed the chemotherapy treatment lines and corresponding outcomes, and significantly assisted with the manuscript development and revision.

VR commented on the surgical evaluation, reviewed the patient's

postop data and significantly assisted with the manuscript development and revision.

References

- A I Husaini, H., Soudy, H., El Din Darwish, A., Ahmed, M., Eltigani, A., A I Mubarak, M., et al., 2012. Pure dysgerminoma of the ovary: a single institutional experience of 65 patients. *Med. Oncol.* 29, 2944–2948.
- Afridi, M.A., Vongtama, V., Tsukada, Y., Piver, M.S., 1976. Dysgerminoma of the ovary: radiation therapy for recurrence and metastases. *Am. J. Obstet. Gynecol.* 126, 190–194.
- Fosså, S.D., Bokemeyer, C., Gerl, A., Culine, S., Jones, W.G., Mead, G.M., et al., 1999. Treatment outcome of patients with brain metastases from malignant germ cell tumors. *Cancer* 85, 988–997.
- Gallion, H.H., van Nagell Jr., J.R., Donaldson, E.S., Powell, D.E., 1988. Ovarian dysgerminoma: report of seven cases and review of the literature. *Am. J. Obstet. Gynecol.* 158, 591–595.
- Gordon, A., Lipton, D., Woodruff, J.D., 1981. Dysgerminoma: a review of 158 cases from the Emil Novak Ovarian Tumor Registry. *Obstet. Gynecol.* 58, 497–504.
- Guerriero, S., Testa, A.C., Timmerman, D., Van Holsbeke, C., Ajossa, S., Fischerova, D., et al., 2011. Imaging of gynecological disease (6): clinical and ultrasound characteristics of ovarian dysgerminoma. *Ultrasound Obstet. Gynecol.* 37, 596–602.
- Jolles, C.J., Karayianis, S., Smotkin, D., DeLia, J.E., 1989. Advanced ovarian dysgerminoma with cure of tumor persistent in meninges. *Gynecol. Oncol.* 33, 389–391.
- Kattan, J., Droz, J.P., Charpentier, P., Michel, G., Lhommé, C., Boutan-Laroze, A., Prade, M., 1992. Ovarian dysgerminoma metastatic to the breast. *Gynecol. Oncol.* 46, 104–106.
- Li, J., Xiaohua, W., 2016. Current strategy for the treatment of ovarian germ cell tumors: role of extensive surgery. *Curr. Treat. Options in Oncol.* 17, 44.
- Mangili, G., Sigismondi, C., Lorusso, D., Cormio, G., Scollo, P., Viganò, R., et al., 2011. Is surgical restaging indicated in apparent stage IA pure ovarian dysgerminoma? The MITO group retrospective experience. *Gynecol. Oncol.* 121, 280–284.
- Patterson, D.M., Murugaesu, N., Holden, L., Seckl, M.J., Rustin, G.J., 2008. A review of the close surveillance policy for stage I female germ cell tumors of the ovary and other sites. *Int. J. Gynecol. Cancer* 18, 43–50.
- Tokuda, Y., Hatayama, T., Sakoda, K., 1993. Metastasis of malignant struma ovarii to the cranial vault during pregnancy. *Neurosurgery* 33, 515–518.
- Uygun, K., Karagol, H., Kocak, Z., Cicin, I., Yalcin, O., Caloglu, M., et al., 2006. Isolated bone metastasis in testicular germ cell tumors: a case report and review of the literature. *Onkologie* 29, 93–95.
- Weidle, U.H., Niewöhner, J., Tiefenthaler, G., 2015. The blood-brain barrier challenge for the treatment of brain cancer, secondary brain metastases, and neurological diseases. *Cancer Genomics Proteomics* 12, 167–177.
- Zaloudek, C.J., Tavassoli, F.A., Norris, H.J., 1981. Dysgerminoma with syncytiotrophoblastic giant cells. A histologically and clinically distinctive subtype of dysgerminoma. *Am. J. Surg. Pathol.* 5, 361–367.
- Zogbi, L., Gonçalves, C.V., Tejada, V.F., Martins, D., Karam, F., Machado Dos Santos, S., et al., 2018. Treatment of bilateral ovarian dysgerminoma with 11-year follow-up: A case report. *Ann. Med. Surg.* 33, 50–52.