



Night Watch on the Titanic: Detecting Early Signs of Epileptogenesis in Alzheimer Disease

Epilepsy Currents
2020, Vol. 20(6) 369-374

© The Author(s) 2020

Article reuse guidelines:

sagepub.com/journals-permissions

DOI: 10.1177/1535759720964775

journals.sagepub.com/home/epi



Alice D. Lam, MD, PhD¹  and Jeffrey Noebels, MD, PhD^{2*} 

¹ Department of Neurology, Massachusetts General Hospital, Boston, MA, USA

² Department of Neurology, Baylor College of Medicine, Houston, TX, USA

*Corresponding Authors: Alice D. Lam, Department of Neurology, Massachusetts General Hospital, Boston, MA 02114, USA;

e-mail: Lam.Alice@mgh.harvard.edu

Jeffrey Noebels, Department of Neurology, Baylor College of Medicine, One Baylor Plaza, Houston, TX 77030, USA;

e-mail: jnoebels@bcm.edu

Abstract

Aberrant cortical network excitability is an inextricable feature of Alzheimer disease (AD) that can negatively impact memory and accelerate cognitive decline. Surface electroencephalogram spikes and intracranial recordings of nocturnal silent seizures in human AD, coupled with the abnormal neural synchrony that precedes development of behavioral seizures in mouse AD models, build the case for epileptogenesis as an early therapeutic target for AD. Since most individuals with AD do not develop overt seizures, leveraging functional biomarkers of epilepsy risk to stratify a heterogeneous AD patient population for treatment is research priority for successful clinical trial design. Who will benefit from antiseizure interventions, which one, and when should it begin?

Keywords

Alzheimer disease, epileptogenesis, biomarkers, hyperexcitability, temporal lobe, hippocampus, epilepsy

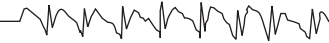Introduction

The earliest symptoms of Alzheimer disease (AD), including short-term memory loss and a decline in cognition that impairs daily function, reflect a burden of neuropathology that has slowly accumulated over decades. Prior to the onset of cognitive decline, there is a 15- to 20-year preclinical stage of AD in which high levels of amyloid and hyperphosphorylated tau protein aggregate as extracellular plaques and intracellular neurofibrillary tangles, respectively.¹ This is accompanied by progressive synaptic loss,² aberrant patterns of excitability gene transcription,^{3,4} and neuronal circuit degradation.⁵ By the time the signs of cognitive dysfunction appear, like the tip of an iceberg, significant unseen damage has already occurred; hence, the recent strategic shift of AD clinical trials toward earlier, even preclinical stages,⁶ and the pressing need to identify proven treatments that can slow disease progression.

Stabilizing network hyperexcitability is one such target. Preserving the health of temporal lobe networks is imperative for maintaining memory function, as the entorhinal cortex–hippocampal circuitry is hard hit early in AD. Early AD pathology drives synaptic dysfunction in this highly vulnerable pathway, initiating an excitotoxic cascade entailing circuit reorganization and impaired neurogenesis.^{2,7} This attenuates memory storage, by figuratively rearranging the deck chairs and burning the lifeboats, triggering inflammation, and epileptiform activity that may contribute to the ongoing amnesic syndrome and drive further decline. Although epileptologists are no strangers to short-term memory loss caused by mesial temporal lobe epilepsy (MTLE), the repercussions of MTLE in AD significantly worsen this blow. Evidence in mouse models of MTLE and AD has established a feedforward cycle directly linking neuronal hyperactivity with excess release of soluble amyloid and tau, suggesting that epileptiform activity in AD



Creative Commons Non Commercial No Deriv CC BY-NC-ND: This article is distributed under the terms of the Creative Commons Attribution-NonCommercial-NoDeriv 4.0 License (<https://creativecommons.org/licenses/by-nc-nd/4.0/>) which permits non-commercial use, reproduction and distribution of the work as published without adaptation or alteration, without further permission provided the original work is attributed as specified on the SAGE and Open Access pages (<https://us.sagepub.com/en-us/nam/open-access-at-sage>).



drives further deposition of amyloid and tau pathology.⁸ Treatment of hAPP J20 mice with levetiracetam not only reduced seizures and spiking but also ameliorated cognitive deficits, demonstrating that epileptiform activity can reversibly impact cognitive function in AD.⁹ Moreover, hyperexcitability in mouse AD models can be rescued even while leaving amyloid plaques intact,¹⁰ suggesting that stabilizing network excitability is possible even at later stages of AD and may still offer an important opportunity to protect cognitive function.

Seizures are common in AD, affecting 2.8% to 47.7% of individuals with autosomal dominant AD (ADAD),¹¹⁻¹³ and 0.5% to 22% with sporadic AD.^{14,15} Among patients with AD who develop epilepsy, 11% to 32% experience their first seizure in the 5 years preceding the onset of cognitive decline.^{16,17} Moreover, patients with epilepsy develop cognitive decline, on average, 5 years earlier than those without epilepsy,¹⁶ supporting a role for epileptogenesis in accelerating preclinical and early clinical stages of AD. In AD, as in MTLE, the precise onset of epileptogenesis is rarely known. Recent studies in humans and mouse AD models have shown that seizures in AD may remain electrographically hidden, deep below the neocortical surface, and beyond the range of scalp electrodes.¹⁸⁻²¹ Mesial temporal lobe (MTL) seizures frequently evade diagnosis, as 58% of patients with MTLE have subclinical seizures, and 63% experience clinical auras that have no ictal correlate on scalp electrodes.²²

Seizures are not a universal feature of AD, however, and if only some patients with AD stand to benefit from an antiepileptogenesis strategy, early biomarkers of MTLE are needed to avoid underpowered clinical trials and to assess whether the medication actually works by suppressing MTL hyperexcitability. Stratifying patients and assessing efficacy in an AD-related antiepileptogenesis drug trial would be straightforward if MTLE could be reliably detected with scalp electroencephalogram (EEG). However, MTL spikes and seizures transmit poorly to the cortical surface, since 70% to 95% of these spikes lack an epileptiform correlate on scalp EEG.^{18,23} More sensitive biomarkers for early detection of MTLE are needed.

Here, we draw attention to the development of MTL hyperexcitability biomarkers needed to enrich drug trial design and develop network modulating therapies to alter AD progression. Combining electrophysiologic biomarkers of hyperexcitability with complementary biological evidence will help define tractable MTL dysfunction and stratify trial subgroups. A multiplex protocol that quantifies network excitability during the AD trajectory, demonstrates target engagement, and correlates with treatment outcome, is essential for assessing novel neuroprotection strategies.

Electrophysiology

Foramen ovale electrodes. Foramen ovale (FO) electrodes positioned adjacent to the MTL are a minimally invasive alternative to stereo-EEG electrodes and represent the gold standard for

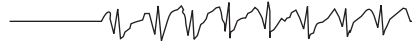assessing deep temporal epileptiform activity in AD. In a pilot study, individuals with AD displayed sleep-activated spikes and electrographic MTL seizures that were invisible on scalp EEG electrodes.¹⁸ MTL epileptiform abnormalities are most prevalent during non-REM sleep in humans,^{18,24} but interestingly, occur primarily during REM sleep in mouse AD models.^{21,24} Although FO electrodes offer high fidelity recordings of MTL activity, the costs and potential risks of electrode placement limit their utility as a screening tool for MTLE in AD.

Scalp EEG. Subclinical epileptiform discharges visible on scalp EEG occur in 9% to 21% of AD with no prior history of epilepsy, compared to 0% to 5% of healthy controls.²⁵⁻²⁷ Most spikes occur during sleep, requiring overnight EEGs for detection. Scalp EEG spikes in AD typically arise locally from the lateral temporal cortex or propagate to the surface from deep MTL foci. In early-onset AD, subclinical epileptiform discharges were associated with a faster decline in global cognition and executive function.²⁵ However, scalp EEG spikes alone are unreliable biomarkers for MTLE in AD, since they are infrequent (<10 per 24 hours) and have variable association with seizures.^{25,27} This complexity is recapitulated in mouse AD models, where multiple spike morphologies exist,²⁰ with distinct responses to antiseizure medications.

On scalp EEG, some MTL spikes resemble small sharp spikes (SSSs),^{18,28} a benign variant not linked to epilepsy.²⁹ Frequent (>100 per 24 hours), unilateral SSS-like waveforms are associated with epilepsy in AD, but occur in only 13% of those with AD-related epilepsy.²⁷ Their use as a MTLE biomarker requires further validation using methods that distinguish pathologic (due to MTLE) from benign SSS. Temporal intermittent rhythmic delta activity (TIRDA) is a well-described biomarker of MTLE³⁰ that occurs in 26% of patients with AD-related epilepsy.²⁷ Similar to spikes, TIRDA occurs infrequently (<10 per 24 hours) in AD, reducing its utility as a quantitative biomarker.²⁷

Magnetoencephalography. Magnetoencephalography (MEG) offers a complementary but largely unexplored approach to detecting MTL network dysfunction in AD. A small study using 1-hour MEG recordings and overnight scalp EEG in early-onset AD found that 21% of participants had epileptiform discharges visible on MEG but not on scalp EEG, compared to 11% of healthy controls.²⁵

Computational approaches. MTL spikes and seizures may be associated with quantitative EEG or MEG signatures that permit their detection even in the absence of a visible correlate.^{31,32} Development of machine learning approaches that reliably extract MTL spike or seizure information from surface EEG or MEG is under way³³⁻³⁶ but will require validation with larger clinical data sets of combined scalp EEG/MEG and intracranial recordings from patients with MTLE.



Genotyping

Genomic profiling can enrich a trial study population for those at higher risk for epilepsy, though individual genotypes remain an imperfect predictor of ongoing or future hyperexcitability.

Alzheimer disease genes. Autosomal dominant AD is caused by mutations in amyloid precursor protein, presenilin1, or presenilin2, with each linked to elevated seizure risk in humans and mouse models.³⁷ Despite the monogenic etiology of ADAD, there is considerable variability in which individuals will develop epilepsy and when, even in single large pedigrees.³⁸ Mouse AD models also demonstrate interindividual variability in epilepsy risk, as even littermates carrying the same AD mutation on an isogenic background show incomplete penetrance.^{19,21,39} Genetic background plays an important role in excitotoxicity in both epilepsy and ADAD.⁴⁰ For example, mutations in MAPT (tau) do not cause AD, but tau deletion prevents epileptogenesis in mouse models.⁴¹ APOE ϵ 4, the most significant genetic risk factor for sporadic AD, confers an age and dose-dependent risk of late-onset epilepsy.⁴² Overexpression of BIN1, the second most significant genetic risk factor for sporadic AD, induces network hyperexcitability in rat hippocampal neurons.⁴³

Epilepsy genes. This rapidly expanding list defines a source of inherited risk for altered cortical excitability in AD. Pro-epileptic modifier genes in AD could either enhance or mask network excitability⁴⁴ depending on their combinatorial pattern⁴⁵ and may guide treatment choice. Building an oligogenic profile of epilepsy risk in AD may explain different onset ages or cognitive features, and incorporating clinical exome studies into AD-related epilepsy drug trials may help predict treatment response. As the genomic landscapes of sporadic AD and epilepsy grow, merging these gene lists will refine translational studies.

Imaging

Imaging studies provide complementary information for staging MTL network dysfunction in AD. Although AD is typically assumed to be a symmetric brain disease, epileptiform abnormalities in AD often involve the temporal lobes asymmetrically.^{25,27} This asymmetry could be leveraged to develop imaging biomarkers for AD patients with MTLE.

Magnetic resonance imaging. Volume-based morphometric analysis of brain atrophy in patients with AD with epileptiform abnormalities has been limited to small studies that analyzed group-based averages of atrophy, without considering the location of each individual's epilepsy.²⁵ Seeking a correlation between epileptiform abnormalities and focal cortical atrophy at a higher resolution may help identify biomarkers specific to MTL network dysfunction. T2 white matter hyperintensities, which are associated with higher risk of late-onset epilepsy, may also be an informative biomarker.⁴⁶

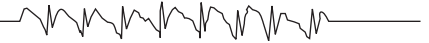Functional magnetic resonance imaging. Functional magnetic resonance imaging (fMRI) tasks that activate episodic memory circuitry reveal increased hippocampal activation that predicts impending MTL failure and cognitive decline in patients in the mild cognitive impairment (MCI) stage of AD.⁴⁷ In individuals with MCI, chronic administration of low-dose levetiracetam reduced hippocampal hyperactivity and improved memory performance.⁴⁸ Whether and how task-evoked hyperactivity on fMRI is related to MTL epileptogenesis remains unclear. Resting state fMRI is more easily performed than task-based fMRI and may provide a more scalable approach to evaluate underlying MTL network connectivity in AD-related epilepsy.⁴⁹

Positron emission tomography. Several positron emission tomography (PET) tracers offer opportunities to evaluate MTLE and synaptic dysfunction in AD. PET tracers that bind amyloid plaques and neurofibrillary tangles have transformed our ability to study AD pathology in vivo and correlate longitudinal changes in AD pathology with clinical features.⁵⁰ Since amyloid and tau deposition can both be driven by hyperactivity,⁸ regional or lateralized tracer uptake could potentially indicate MTL network irritability. 18F-fluorodeoxyglucose (FDG) PET has clinical utility in both dementia and epilepsy but has not yet been evaluated in AD-related epilepsy. In TLE, reduced uptake of FDG in the temporal lobe can be seen even in the absence of an MRI lesion and can predict surgical outcomes.⁵¹ 11C-flumazenil PET also demonstrates focally reduced uptake in TLE.⁵² 11C-UCB-J PET imaging provides a measure of synaptic density⁵³ and reveals widespread reduction of tracer uptake in the MTL and neocortex in AD,⁵⁴ while showing asymmetric focal reduction in the temporal lobe harboring mesial temporal sclerosis in TLE.⁵³ Other PET ligands that assess specific metabolic pathways or neurotransmitter receptors relevant to MTLE in AD are under development.

Fluid Biomarkers

Fluid biomarkers that reflect recent brain hyperexcitability over a period of hours to weeks are needed. Hyperexcitability could be reflected in biofluid markers specific to AD pathology. Cerebrospinal fluid (CSF) A β 42, total tau, and phosphorylated tau constitute core AD diagnostic biomarkers in widespread use. More recently, plasma phospho-tau217 was shown to discriminate AD from other neurodegenerative diseases with performance comparable to CSF and PET measures.⁵⁵ It remains unclear whether focal seizures generate detectable changes in biofluid amyloid or tau that could help recognize MTLE.

Additional biofluid markers of neuronal injury, synaptic loss, and inflammation, while not specific to AD, could still help identify MTLE in AD. Cerebrospinal fluid and plasma levels of neurofilament light, a marker of active neurodegeneration, are elevated in many neurodegenerative diseases, including AD.⁵⁶ Neurogranin (Ng) is a postsynaptic protein expressed in hippocampus and cortex. Increased CSF levels of Ng are seen in MCI patients and predict cognitive decline,



hippocampal atrophy, and glucose hypometabolism.⁵⁷ Cerebrospinal fluid levels of presynaptic proteins SNAP25, synaptotagmin, and GAP-43, and the inflammatory protein TREM2, are also elevated in AD.⁵⁸ Examining biofluid profiles of these and other molecules, including microRNAs, exosomes, and epileptogenesis biomarkers identified from epilepsy studies may provide additional insights.

Conclusion

Although robust preclinical data support a role for MTL hyperexcitability in AD, clinical recognition of this phenomenon in patients has been slow, due to limited visibility and variable expression, and further clinical evidence is essential. Whether MTL hyperexcitability and seizures accelerate AD pathology, and antiepileptic treatment can lessen cognitive decline remains to be determined. Recognizing that no ship is unsinkable, however, we must arm the crew with the appropriate surveillance tools to safely navigate the ice fields. Raising warning flares early, bolstering the lifevest supply, and slowing the velocity before impact are strategies that save lives. If stabilizing MTL hyperexcitability can minimize network damage and decelerate the progression of AD, antiepileptogenic interventions may keep cognition afloat until help arrives. Which ones to use, in whom, and when can only be determined by controlled clinical trials.

Acknowledgments

The authors thank Jasmeer Chhatwal for thoughtful discussion.


Declaration of Conflicting Interests


The author(s) declared no potential conflicts of interest with respect to the research, authorship, and/or publication of this article.

Funding

The author(s) received no financial support for the research, authorship, and/or publication of this article.

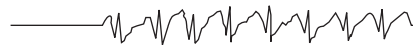ORCID iDs

Alice D. Lam  <https://orcid.org/0000-0001-7754-4637>

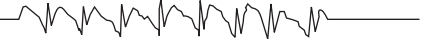Jeffrey Noebels  <https://orcid.org/0000-0002-2887-0839>

References

- Jack CR, Knopman DS, Jagust WJ, et al. Tracking pathophysiological processes in Alzheimer's disease: an updated hypothetical model of dynamic biomarkers. *Lancet Neurol.* 2013;12(2):207-216.
- Barthet G, Mulle C. Presynaptic failure in Alzheimer's disease. *Prog Neurobiol.* 2020. doi:10.1016/j.pneurobio.2020.101801
- Corbett BF, You JC, Zhang X, et al. DFosB regulates gene expression and cognitive dysfunction in a mouse model of Alzheimer's disease. *Cell Rep.* 2017;20(2):344-355.
- Hwang JY, Zukin RS. REST, a master transcriptional regulator in neurodegenerative disease. *Curr Opin Neurobiol.* 2018;48:193-200.
- Yan XX, Cai Y, Shelton J, et al. Chronic temporal lobe epilepsy is associated with enhanced alzheimer-like neuropathology in 3×Tg-AD mice. *PLoS One.* 2012;7(11):e48782.
- Sperling R, Mormino E, Johnson K. The evolution of preclinical Alzheimer's disease: implications for prevention trials. *Neuron.* 2014;84(3):608-622.
- Arendt T, Brückner MK, Gertz HJ, Marcova L. Cortical distribution of neurofibrillary tangles in Alzheimer's disease matches the pattern of neurons that retain their capacity of plastic remodelling in the adult brain. *Neuroscience.* 1998;83(4):991-1002.
- Harris SS, Wolf F, De Strooper B, Busche MA. Tipping the scales: peptide-dependent dysregulation of neural circuit dynamics in Alzheimer's disease. *Neuron.* 2020;107(3):417-435. doi:10.1016/j.neuron.2020.06.005
- Sanchez PE, Zhu L, Verret L, et al. Levetiracetam suppresses neuronal network dysfunction and reverses synaptic and cognitive deficits in an Alzheimer's disease model. *Proc Natl Acad Sci U S A.* 2012;109(42):E2895-E2903.
- Born HA, Kim JY, Savjani RR, et al. Genetic suppression of transgenic APP rescues hypersynchronous network activity in a mouse model of Alzheimer's disease. *J. Neurosci.* 2014;34(11):3826-3840.
- Zarea A, Charbonnier C, Rovelet-Lecrux A, et al. Seizures in dominantly inherited Alzheimer disease. *Neurology.* 2016;87(9):912-919.
- Tang M, Ryman DC, McDade E, et al. Neurological manifestations of autosomal dominant familial Alzheimer's disease: a comparison of the published literature with the dominantly inherited Alzheimer network observational study (DIAN-OBS). *Lancet Neurol.* 2016;15(3):1317-1325.
- Ryan NS, Nicholas JM, Weston PS, et al. Clinical phenotype and genetic associations in autosomal dominant familial Alzheimer's disease: a case series. *Lancet Neurol.* 2016;15(13):1326-1335.
- Vossel KA, Tartaglia MC, Nygaard HB, Zeman AZ, Miller BL. Epileptic activity in Alzheimer's disease: causes and clinical relevance. *Lancet Neurol.* 2017;16(4):311-322.
- Irizarry MC, Jin S, He F, et al. Incidence of new-onset seizures in mild to moderate Alzheimer disease. *Arch Neurol.* 2012;69(3):368-372.
- Vossel KA, Beagle AJ, Rabinovici GD, et al. Seizures and epileptiform activity in the early stages of Alzheimer disease. *JAMA Neurol.* 2013;70(9):1158-1166.
- Sarkis RA, Dickerson BC, Cole AJ, Chemali ZN. Clinical and neurophysiologic characteristics of unprovoked seizures in patients diagnosed with dementia. *J. Neuropsychiatry Clin Neurosci.* 2016;28(1):56-61.
- Lam AD, Deck G, Goldman A, Eskandar EN, Noebels J, Cole AJ. Silent hippocampal seizures and spikes identified by foramen ovale electrodes in Alzheimer's disease. *Nat Med.* 2017;23(6):678-680.
- Palop JJ, Chin J, Roberson ED, et al. Aberrant excitatory neuronal activity and compensatory remodeling of inhibitory hippocampal circuits in mouse models of Alzheimer's disease. *Neuron.* 2007;55(5):697-711.



20. Gureviciene I, Gureviciene I, Ishchenko I, et al. Characterization of epileptic spiking associated with brain amyloidosis in APP/PS1 Mice. *Front Neurol.* 2019;10:1151.
21. Kam K, Duffy ÁM, Moretto J, LaFrancois JJ, Scharfman HE. Interictal spikes during sleep are an early defect in the Tg2576 mouse model of β -amyloid neuropathology. *Sci Rep.* 2016;6:20119.
22. Sperling MR, O'Connor MJ. Auras and subclinical seizures: characteristics and prognostic significance. *Ann Neurol.* 1990;28(3):320-328.
23. Torre JF, Alarcon G, Binnie CD, Polkey CE. Comparison of sphenoidal, foramen ovale and anterior temporal placements for detecting interictal epileptiform discharges in presurgical assessment for temporal lobe epilepsy. *Clin Neurophysiol.* 1999;110(5):895-904.
24. Brown R, Lam AD, Gonzalez-Sulser A, et al. Circadian and brain state modulation of network hyperexcitability in Alzheimer's Disease. *eNeuro.* 2018;5:ENEURO.0426-17. 2018.
25. Vossel KA, Ranasinghe KG, Beagle AJ, et al. Incidence and impact of subclinical epileptiform activity in Alzheimer's disease. *Ann Neurol.* 2016;80(6):858-870.
26. Brunetti V, D'Atri A, Della Marca G, et al. Subclinical epileptiform activity during sleep in Alzheimer's disease and mild cognitive impairment. *Clin Neurophysiol.* 2020;131(5):1011-1018.
27. Lam AD, Sarkis RA, Pellerin KR, et al. Association of epileptiform abnormalities and seizures in Alzheimer disease. *Neurology.* 2020. doi:10.1212/wnl.0000000000010612
28. Issa NP, Wu S, Rose S, et al. Small sharp spikes as EEG markers of mesiotemporal lobe epilepsy. *Clin Neurophysiol.* 2018;129(9):1796-1803.
29. White JC, Langston JW, Pedley TA. Benign epileptiform transients of sleep. Clarification of the small sharp spike controversy. *Neurology.* 1977;27(11):1061-1068.
30. Gambardella A, Gotman J, Cendes F, Andermann F. Focal Intermittent delta activity in patients with mesiotemporal atrophy: a reliable marker of the epileptogenic focus. *Epilepsia.* 1995;36:122-129.
31. Nayak D, Valentin A, Alarcon G, et al. Characteristics of scalp electrical fields associated with deep medial temporal epileptiform discharges. *Clin Neurophysiol.* 2004;115(6):1423-1435.
32. Koessler L, Cecchin T, Coulbois SC, et al. Catching the invisible: mesial temporal source contribution to simultaneous EEG and SEEG recordings. *Brain Topogr.* 2015;28(1):5-20.
33. Lam AD, Zepeda R, Cole AJ, Cash SS. Widespread changes in network activity allow non-invasive detection of mesial temporal lobe seizures. *Brain.* 2016;139(10):2679-2693.
34. Lam AD, Maus D, Zafar SF, Cole AJ, Cash SS. SCOPE-mTL: A non-invasive tool for identifying and lateralizing mesial temporal lobe seizures prior to scalp EEG ictal onset. *Clin Neurophysiol.* 2017;128(9):1647-1655.
35. Spyrou L, Lopez DM, Valentin A, Alarcón G, Sanei S. Detection of intracranial signatures of interictal epileptiform discharges from concurrent scalp EEG. *Int J Neural Syst.* 2016;26(04):1650016.
36. Pizzo F, Roehri N, Villalon SM, et al. Deep brain activities can be detected with magnetoencephalography. *Nat Commun.* 2019;10(1):1-13.
37. Born HA. A. Seizures in Alzheimer's disease. *Neuroscience.* 2015;286:251-263.
38. Lopera F, Ardilla A, Martínez A, et al. Clinical features of early-onset alzheimer disease in a large kindred with an E280A presenilin-1 mutation. *JAMA J Am Med Assoc.* 1997;277(10):793-799.
39. Minkeviciene R, Rheims S, Dobszay MB, et al. Amyloid beta-induced neuronal hyperexcitability triggers progressive epilepsy. *J Neurosci.* 2009;29(11):3453-3462.
40. Schauwecker PE, Steward O. Genetic determinants of susceptibility to excitotoxic cell death: implications for gene targeting approaches. *Proc Natl Acad Sci U S A.* 1997;94(8):4103-4108.
41. Roberson ED, Levie KS, Palop JJ, et al. Reducing endogenous tau ameliorates amyloid-induced deficits in an Alzheimer's disease mouse model. *Science.* 2007;316(5825):750-754.
42. Sepulcre J, Grothe MJ, Uquillas FD, et al. Neurogenetic contributions to amyloid beta and tau spreading in the human cortex. *Nat Med.* 2018;24(12):1910-1918. doi:10.1038/s41591-018-0206-4
43. Voskobiynk Y, Roth JR, Cochran JN, et al. Alzheimer's disease risk gene BIN1 induces Tau-dependent network hyperexcitability. *Elife.* 2020;9:e57354.
44. Glasscock E, Qian J, Yoo JW, Noebels JL. Masking epilepsy by combining two epilepsy genes. *Nat Neurosci.* 2007;10(12):1554-1558.
45. Klassen T, Davis C, Goldman A, et al. Exome sequencing of ion channel genes reveals complex profiles confounding personal risk assessment in epilepsy. *Cell.* 2011;145(7):1036-1048.
46. Johnson EL, Krauss GL, Lee AK, et al. Association between white matter hyperintensities, cortical volumes, and late-onset epilepsy. *Neurology.* 2019;92(9):E988-E995.
47. Dickerson BC, Sperling RA. Large-scale functional brain network abnormalities in Alzheimer's disease: insights from functional neuroimaging. *Behav Neurol.* 2009;21(1,2):63-75.
48. Bakker A, Krauss GL, Albert MS, et al. Reduction of hippocampal hyperactivity improves cognition in amnesic mild cognitive impairment. *Neuron.* 2012;74(3):467-474.
49. Tracy JI, Doucet GE. Resting-state functional connectivity in epilepsy: growing relevance for clinical decision making. *Curr Opin Neurol.* 2015;28(2):158-165.
50. Villemagne VL, Doré V, Burnham SC, Masters CL, Rowe CC. Imaging tau and amyloid-B proteinopathies in Alzheimer disease and other conditions. *Nat Rev Neurol.* 2018;14(4):225-236.
51. Theodore WH. Presurgical focus localization in epilepsy: PET and SPECT. *Semin Nucl Med.* 2017;47(1):44-53.
52. Von Oertzen TJ. PET and ictal SPECT can be helpful for localizing epileptic foci. *Curr Opin Neurol.* 2018;31(2):184-191.
53. Finnema SJ, Nabulsi NB, Eid T, et al. Imaging synaptic density in the living human brain. *Sci Transl Med.* 2016;8(348):348ra96.
54. Mecca AP, Chen MK, O'Dell RS, et al. In vivo measurement of widespread synaptic loss in Alzheimer's disease with SV2A PET. *Alzheimers Dement.* 2020;16(7):974-982.
55. Palmqvist S, Janelidze S, Quiroz YT, et al. Discriminative accuracy of plasma phospho-tau217 for Alzheimer disease vs other



- neurodegenerative disorders. *JAMA J Am Med Assoc.* 2020; 324(8):772-781. doi:10.1001/jama.2020.12134
56. Bridel C, Van Wieringen WN, Zetterberg H, et al. Diagnostic value of cerebrospinal fluid neurofilament light protein in neurology: a systematic review and meta-analysis. *JAMA Neurol.* 2019; 76(9):1035-1048.
57. Portelius E, Zetterberg H, Skillbäck T, et al. Cerebrospinal fluid neurogranin: relation to cognition and neurodegeneration in Alzheimer's disease. *Brain.* 2015;138(11):3373-3385.
58. Cadena MC, Jones TS, Zetterberg H, et al. The clinical promise of biomarkers of synapse damage or loss in Alzheimer's disease. *Alzheimers Res Ther.* 2020;12(1):1-2.