

Double Hit Lymphoma – a Case of Unusual Response After Sequential Aggressive Chemotherapy and Review of the Literature

Faisal N. Cheema¹, Maliha Agloria¹, Nebu Koshy¹ and Gerhard C. Hildebrandt^{1,2}

¹Division of Hematology and Oncology, Louisiana State University Health Sciences Center, Shreveport, LA, USA. ²Division of Hematology and Hematologic Malignancies, University of Utah School of Medicine, Salt Lake City, UT, USA.

ABSTRACT: Lymphomas with recurrent chromosomal breakpoints activating multiple oncogenes, including *MYC*, *BCL2*, and *BCL6* are often referred to as “Dual Hit” or “Double Hit” lymphomas (DHL). In the updated classification for malignant lymphomas by the World Health Organization (WHO), the novel category of “B-cell lymphoma unclassifiable with features intermediate between diffuse large B-cell lymphoma (DLBCL) and Burkitt’s lymphoma (BL)” was proposed in an attempt to create a (temporary) container for aggressive mature B-cell lymphomas that should not be diagnosed as either BL or DLBCL. DHL make up an important part of this novel WHO category, the other part representing heterogeneous cases of aggressive B-cell lymphoma that have features of BL. DHL are highly aggressive lymphomas with generally poor response to first line and salvage treatment. Limited data is available to guide therapeutic decisions, and despite aggressive measures including high dose (HD) chemotherapy followed by autologous hematopoietic cell transplantation (AHCT), outcome is unsatisfyingly poor. Herein, we report a case of a patient with DHL and review the relevant literature.

KEYWORDS: double hit lymphoma, diffuse large B cell lymphoma, autologous hematopoietic cell transplantation, myc, bcl2

CITATION: Cheema et al. Double Hit Lymphoma – a Case of Unusual Response After Sequential Aggressive Chemotherapy and Review of the Literature. *Clinical Medicine Insights: Case Reports* 2014;7:117–121 doi: 10.4137/CCRep.S11393.

RECEIVED: December 16, 2012. **RESUBMITTED:** February 24, 2013. **ACCEPTED FOR PUBLICATION:** February 28, 2013.

ACADEMIC EDITOR: Athavale Nandkishor, Associate Editor

TYPE: Case Report

FUNDING: Authors disclose no funding sources.

COMPETING INTERESTS: Authors disclose no potential conflicts of interest.

COPYRIGHT: © the authors, publisher and licensee Libertas Academica Limited. This is an open-access article distributed under the terms of the Creative Commons CC-BY-NC 3.0 License.

CORRESPONDENCE: gerhard.hildebrandt@hsc.utah.edu

This paper was subject to independent, expert peer review by a minimum of two blind peer reviewers. All editorial decisions were made by the independent academic editor. All authors have provided signed confirmation of their compliance with ethical and legal obligations including (but not limited to) use of any copyrighted material, compliance with ICMJE authorship and competing interests disclosure guidelines and, where applicable, compliance with legal and ethical guidelines on human and animal research participants.

Introduction

Lymphomas with recurrent chromosomal breakpoints activating multiple oncogenes, including *MYC*, *BCL2*, and *BCL6* are often referred to as “Dual Hit” or “Double Hit” lymphomas (DHL). In the updated classification for malignant lymphomas by the World Health Organization (WHO), the novel category of “B-cell lymphoma unclassifiable with features intermediate between diffuse large B-cell lymphoma (DLBCL) and Burkitt’s lymphoma (BL) was proposed in an attempt to create a (temporary) container for aggressive mature B-cell lymphomas that should not be diagnosed as either BL or DLBCL. DHL make up an important part of this novel WHO category, the other part representing heterogeneous cases of aggressive B-cell lymphoma that have features of BL.”¹ In a population-based cohort of 303 patients with previously untreated, de novo DLBCL, 245 were evaluable at

the *MYC* locus, and of these, 14% were found to have *MYC* translocation. Of those with *MYC* rearrangements, 83% had concurrent abnormalities of *BCL2* and/or less commonly *BCL6*. The majority of double-hit cases in this series were “classic” *MYC/BCL2* double-hit.² DHL are highly aggressive lymphomas with generally poor response to first line and salvage treatment, with a median overall survival (OS) of 0.2–1.5 years.^{3–5} With a reported incidence of approximately 10–15%, limited data is available to guide therapeutic decisions, and despite aggressive measures including high dose (HD) chemotherapy followed by autologous hematopoietic cell transplantation (AHCT), outcome is unsatisfyingly poor.

Herein, we report a case of a patient with DHL treated aggressively, still living and enjoying good quality of life almost 2 years post-diagnosis. A review of the relevant literature is also discussed.



Case Report

A man in his 50s presented to an outside facility with fatigue, cervical lymphadenopathy, and increased lactate dehydrogenase (LDH = 369 U/L). Positron emission tomography scan (PET/CT) revealed right cervical, supraclavicular, and axillary lymphadenopathy. Complete blood count and renal function were normal. Cervical lymph node biopsy revealed a B-cell lymphoma with t(14,18)(q32;q21) *BCL2* and t(8;22)(q24;q11.2) *MYC* translocation (Fig. 1); bone marrow biopsy was without disease involvement; and diagnosis of Stage IIA DHL with an International Prognostic Index (IPI) score 1, was made. DHL seeming evolved from stage 1A DLBCL, diagnosed four years earlier, after achieving complete remission following four cycles of rituximab, doxorubicin, cyclophosphamide, vincristine, and prednisone (R-CHOP) and an abbreviated course of radiation treatment to right cervical lymphadenopathy (total 1800 cGy of planned 4500 cGy) in March 2007.

Upon transfer to our clinic, seven months after his presentation to the outside facility, eastern cooperative oncology group score (ECOG score 0), and the overall grim prognosis of his disease, decision for aggressive treatment with rituximab plus hyperfractionated cyclophosphamide, vincristine, doxorubicin, dexamethasone alternating with methotrexate and cytarabine (R-Hyper-CVAD) was made, and cycle 1a and 1b were administered over a period of two months. Secondary to development of renal failure after cycle 1b, therapy was switched to rituximab, ifosfamide, carboplatin, and etoposide (R-ICE). He was admitted on day 12 of cycle 1 for collection. A total of 5.71×10^6 /kg granulocyte-colony stimulating factor/plerixafor mobilized CD 34+ cells were collected for future consolidation with HD chemotherapy followed by AHCT. PET/CT staging demonstrated completeremission after one cycle of R-ICE.

The patient developed, though, prolonged severe thrombocytopenia (grade3) requiring a total of four units of platelet transfusion. Bone marrow biopsy revealed normal cellularity, normal myeloid and erythroid maturation, and decreased megakaryocytes without evidence of cytogenetic abnormalities or other signs of treatment-related myelodysplastic syndrome. Two cycles of weekly rituximab 375 mg/m² without additional chemotherapy but with platelet transfusion support were initiated in the following month to allow time for marrow stromal and hematopoietic recovery prior to AHCT, assuming that in contrast to intensive systemic chemotherapy, rituximab may only cause minor marrow stroma injury but provide some protection from relapse. Systemic chemo- and immunotherapy was complemented by intra-theal CNS prophylaxis consisting of a total of three courses of methotrexate alternating with three courses of cytarabine.

Following this treatment, PET/CT prior to AHCT revealed no evidence of active disease, and R-BEAM (rituximab, carmustine, etoposide, cytarabine, and melphalan) HD chemotherapy followed by infusion of 5.71×10^6 /kg

CD34+ cells was given. AHCT was tolerated well, and the patient remains in complete remission by PET/CT one year later. His most recent performance status is an ECOG 0 with normal complete blood count and no impairment of renal function.

Discussion

Improvements in OS of patients with DLBCL have been achieved since the combination of standard dose anthracycline-containing regimens, such as CHOP, with the anti-CD20 antibody rituximab.^{6,7} However, one-third of the patients present with disease that is either refractory to initial therapy or relapses.^{8,9} Cytogenetic and molecular diagnostics have shed light on this dire situation. Translocation of the *MYC* gene, which is involved in many cellular functions including proliferation, is prognostically unfavorable with two year OS less than 30%.^{10–12} Similarly, translocation of *BCL2*, a central anti-apoptotic gene, has been found to be a marker of poor prognosis.^{13,14} In DHL, there is a synergistic adverse clinical effect of combined activation of these genes; *MYC* promotes cellular proliferation and *BCL2* blocks cellular death. Combined *MYC* and *BCL-2* translocations or overexpression is thus characterized by poor response to standard therapy and by an aggressive clinical course resulting in extremely poor prognosis with OS in the range of 4.5–6 months, with one year survival <30%¹⁵ (Table 1).

The British Columbia Cancer Agency identified 54 patients who had concurrent *BCL2* and *MYC* translocations.⁴ Treatment consisted of CHOP (n = 23), R-CHOP (n = 11), high-dose chemotherapy with or without stem cell transplantation (n = 6), and palliation (n = 14). Only six patients remained in remission, with a follow-up of 5 years, whereas the majority of patients died within 6 months. Le Gouill et al conducted a study including 16 patients with DHL treated with CHOP like regimens (n = 9) or, in the case of central nervous system involvement, a methotrexate containing regimen. Autologous and allogeneic transplant was performed in three and two patients, respectively. The median OS was 5 months.³ Despite improved outcomes of DLBCL after incorporation of rituximab in immunochemotherapy, the prognosis for DHL remains dismal. Kobayashi et al reported on 93 consecutive DLBCL patients with revised IPI good and poor risk categories and with double and non-double hit immunohistochemical phenotype. None of the DHL patients were found to have a good IPI score. Complete response rates were 93.2% for the non-DHL patients and 40% for the DHL patients, and PFS and OS in DHL patients were significantly shorter when compared with poor risk non-DHL.¹⁶

Data evaluating alternative therapies is limited and largely based on small patient numbers either reported as case series or as small subgroup analyses within larger lymphoma trials and stated responses have been overall poor. For example, all four patients with DHL

Table 1. Double hit lymphoma studies and outcomes.

STUDY AUTHOR	DHL/SAMPLE SIZE	TREATMENT RECEIVED	TRANSPLANT AFTER CR1 ALLOTRANSPLANT (ALLO) OR AUTO TRANSPLANT (A)	ADVANCED STAGE (STAGES III/IV)%	MEDIAN OVERALL SURVIVAL (MONTHS)
Le Gouill et al. ²	16/16	CHOP+/-R; CHOP with HD MTX	3(A), 2(allo)	100	5
Nitsu et al. ¹⁸	19/394	CycIOBEAP+/-R; CHOP+/- R and HD MTX	3 (A – unclear if after CR1 or relapse)	100	18
Johnson et al. ³	23/54	CHOP or CHOP like, high dose chemotherapy	6 (information unavailable)	Unavailable	4
Snuderl et al. ²⁵	20/20	CHOP, R-ICE, R-EPOCH, CODOX-M/R-IVAC	1(A)	85	4.5
Macpherson et al. ²⁶	13/39	CHOP or CHOP like, high dose chemotherapy* without transplant	1 (information unavailable)	92	2.5
Tomita et al. ²⁷	23/27	CHOP, CODOX-M/IVAC, R-Hyper-CVAD	None	65	6
Li et al. ¹⁶	52/52	CHOP-R, R-HyperCVAD, CODOX, FM	11 (A or allo; unclear if after CR1 or relapse)	70	18.6

Note: *High dose chemotherapy = cyclophosphamide and etoposide after 4 cycles of CHOP like regimen.

Abbreviations: CHOP, doxorubicin, cyclophosphamide, vincristine, prednisone; R-ICE, rituximab, ifosfamide, carboplatin, etoposide; CODOX-M/R-IVAC, cyclophosphamide, vincristine, adriamycin, methotrexate, intrathecal cytarabine, intrathecal methotrexate/rituximab, ifosfamide, etoposide, cytarabine, intrathecal methotrexate; R-EPOCH, rituximab, etoposide, prednisone, cyclophosphamide, adriamycin; CycIOBEAP, cyclophosphamide, vincristine, bleomycin, etoposide, doxorubicin, prednisone; HD MTX, high dose methotrexate; R-Hyper-CVAD, rituximab plus hyperfractionated cyclophosphamide, vincristine, doxorubicin, dexamethasone alternating with methotrexate and cytarabine; FM, Fludarabine, mitoxantrone and dexamethasone.

treated on a study protocol with modified CODOX-M/IVAC (cyclophosphamide, vincristine, doxorubicin, methotrexate, ifosfamide, etoposide, and cytarabine)¹⁷ died from disease within 5 months of treatment initiation. The MD Anderson Cancer Center recently reported outcomes of patients with both *MYC* rearrangement and *BCL2*. Nine of the 19 patients with DHL were treated with R-Hyper-CVAD and the rest with R-CHOP; prognosis remained poor.¹⁸ Niitsu et al published their experience with 19 DHL patients treated with either CHOP with or without rituximab or CycIOBEAP (doxorubicin with alternating courses of cyclophosphamide, etoposide, vincristine, bleomycin, and prednisone) administered over 12 weeks. Compared with CHOP, this regimen was observed to have a better median OS, 16 months vs. 8 months, suggesting increased activity against this phenotype.¹⁹ So far, AHCT as part of front-line therapy has been reported not to add substantial benefit in these patients,^{20,21} although the feasibility and efficacy of front-line AHCT has not been extensively investigated in DHL. Recently, ABT 263, a *BCL2* inhibitor has been shown to sensitize DHL cells to conventional therapeutic agents,²² and further clinical testing is warranted and novel treatments need to be explored.

Given the nowadays recognized frequency of double-hit biology, it is possible that more patients with relapsed or refractory DLBCL after R-CHOP may fall in this category than previously considered. “Primary” DHL may be missed among DLBCL cases as the result of insufficient cytogenetic and molecular characterization during initial diagnostic work-up. “Secondary” DHL – as in our patient – may present an evolutionary path from primary DLBCL, on which chromosomal injury, selection pressure, and cancer cell-inherent abilities to accommodate to prior chemotherapy insult lead to the acquisition of genetic alterations, which modify tumor biology. Our patient’s clinical course and his response to intensive multi-agent chemotherapy followed by HD chemotherapy plus AHCT are somewhat surprising when compared to other cases of DHL, and imply that there are unexplored markers in DHL which may portend a rather benign DHL phenotype or a favorable outcome after chemotherapy and whose identification may help delineate the responders from the non-responders.

Currently, the US Intergroup is evaluating dose-adjusted rituximab, etoposide, prednisone, vincristine, cyclophosphamide, and doxorubicin (R-EPOCH) therapy for *MYC*-driven DLBCL, including patients with double-hit biology.²³ While enrollment in clinical trials should be the primary goal for DHL patients, our case supports the concept of choosing an aggressive treatment approach incorporating AHCT as a reasonable option, which in our opinion should not be precluded from physically fit patients not having access to clinical trials. Although, a front-line approach to highly aggressive NHLs with HD chemotherapy followed by AHCT is seen

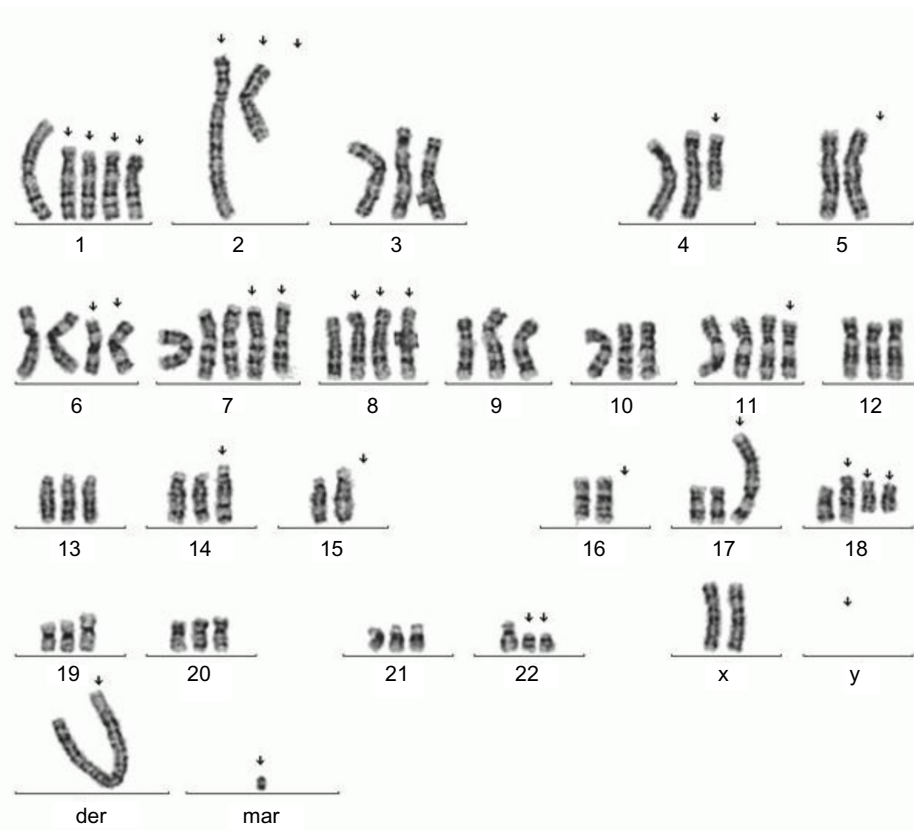


Figure 1. Chromosomal analysis.

Note: (72–77,XX,-Y,+add(1)(p13),+add(1)(p13),+add(1)(p13)×2,-2,der(2)t(1;2)(p13;q33),i(2)(p10),+add(4)(q21),-5,+6,i(6)(p10)×2,+7,+7,+8,t(8;22)(q24;q11.2)×2,der(8)t(8;22),+11,t(14;18)(q32;q21),-15,-16,+add(17)(p13),+18,+add(18)(q23),+der(18)t(14;18),+der(?)t(1;?)(p13;?),+1-5 mar[cp9]).

controversial,²⁴ incorporation of AHCT in a high-risk situation or in a potential “evolutionary relapse” setting as in our patient seems justified.²⁵

Author Contributions

Wrote the first draft of the manuscript: FC. Contributed to the writing of the manuscript: FC, MA, NK, GH. Agree with manuscript results and conclusions: All authors. Jointly developed the structure and arguments for the paper: FC, GH. Made critical revisions and approved final version: GH. All authors reviewed and approved of the final manuscript.

REFERENCES

- Aukema SM, Siebert R, Schuurings E, et al. Double hit B-cell lymphomas. *Blood*. 2011;117:2319–31.
- Lindsley RC, LaCasce AS. Biology of double-hit B-cell lymphomas. *Curr Opin Hematol*. 2012;19:299–304.
- Le Gouill S, Talmant P, Touzeau C, et al. The clinical presentation and prognosis of diffuse large B-cell lymphoma with t(14;18) and 8q24/c-MYC rearrangement. *Haematologica*. 2007;92:1335–42.
- Johnson NA, Savage KJ, Ludkovski O, et al. Lymphomas with concurrent BCL2 and MYC translocations: the critical factors associated with survival. *Blood*. 2009;114:2273–9.
- Green TM, Young KH, Visco C, et al. Immunohistochemical double-hit score is a strong predictor of outcome in patients with diffuse large B-cell lymphoma treated with rituximab plus cyclophosphamide, doxorubicin, vincristine, and prednisone. *J Clin Oncol*. 2012;30:3460–7.
- Pfreundschuh M, Kuhnt E, Trümper L, et al. CHOP-like chemotherapy with or without rituximab in young patients with good-prognosis diffuse large-B-cell lymphoma: 6-year results of an open-label randomised study of the MabThera International Trial (MInT) Group. *Lancet Oncol*. 2011;12:1013.
- Coiffier B, Lepage E, Briere J, et al. CHOP chemotherapy plus rituximab compared with CHOP alone in elderly patients with diffuse large-B-cell lymphoma. *N Engl J Med*. 2002;346:235.
- Sehn LH, Donaldson J, Chhanabhai M, et al. Introduction of combined CHOP plus rituximab therapy dramatically improved outcome of diffuse large B-cell lymphoma in British Columbia. *J Clin Oncol*. 2005;23:5027–33.
- Friedberg JW. Rituximab for early-stage diffuse large-B-cell lymphoma. *Lancet Oncol*. 2006;7:357–9.
- Savage KJ, Johnson NA, Ben-Neriah S, et al. MYC gene rearrangements are associated with a poor prognosis in diffuse large B-cell lymphoma patients treated with R-CHOP chemotherapy. *Blood*. 2009;114:353–7.
- Barrans S, Crouch S, Smith A, et al. Rearrangement of MYC is associated with poor prognosis in patients with diffuse large B-cell lymphoma treated in the era of rituximab. *J Clin Oncol*. 2010;28:3360–5.
- Klapper W, Stoecklein H, Zeynalova S, et al. Structural aberrations affecting the MYC locus indicate a poor prognosis independent of clinical risk factors in diffuse large B-cell lymphomas treated within randomized trials of the German High-Grade Non-Hodgkin's Lymphoma Study Group (DSHNHL). *Leukemia*. 2008;22:2226–9.
- Barrans SL, Evans PA, O'Connor SJ, et al. The t(14;18) is associated with germinal center-derived diffuse large B-cell lymphoma and is a strong predictor of outcome. *Clin Cancer Res*. 2003;9:2133–9.
- Copie-Bergman C, Gaulard P, Leroy K, et al. Immunofluorescence in situ hybridization index predicts survival in patients with diffuse large B-cell lymphoma treated with R-CHOP: a GELA study. *J Clin Oncol*. 2009;27:5573–9.
- Snuderl M, Kolman OK, Chen YB, et al. B-cell lymphomas with concurrent IGH-BCL2 and MYC rearrangements are aggressive neoplasms with clinical and pathologic features distinct from Burkitt lymphoma and diffuse large B-cell lymphoma. *Am J Surg Pathol*. 2010;34:327–40.



16. Kobayashi T, Tsutsumi Y, Sakamoto N, et al. Double-hit lymphomas constitute a highly aggressive subgroup in diffuse large B-cell lymphomas in the era of rituximab. *Jpn J Clin Oncol*. 2012;42:1035–42.
17. Mead GM, Barrans SL, Qian W, et al. A prospective clinicopathologic study of dose-modified CODOX-M/IVAC in patients with sporadic Burkitt lymphoma defined using cytogenetic and immunophenotypic criteria (MRC/NCRI LY10 trial). *Blood*. 2008;112:2248–60.
18. Li S, Lin P, Fayad LE, et al. B-cell lymphomas with MYC/8q24 rearrangements and IGH@BCL2/t(14;18)(q32;q21): an aggressive disease with heterogeneous histology, germinal center B-cell immunophenotype and poor outcome. *Mod Pathol*. 2012;25:145–56.
19. Niitsu N, Okamoto M, Miura I, Hirano M. Clinical features and prognosis of de novo diffuse large B-cell lymphoma with t(14;18) and 8q24/c-MYC translocations. *Leukemia*. 2009;23:777–83.
20. Philip T, Guglielmi C, Hagenbeek A, et al. Autologous bone marrow transplantation as compared with salvage chemotherapy in relapses of chemotherapy-sensitive non-Hodgkin's lymphoma. *N Engl J Med*. 1995;333:1540–5.
21. Cuccini W, Briere J, Mounier N, et al. MYC+ diffuse large B-cell lymphoma is not salvaged by classical R-ICE or R-DHAP followed by BEAM plus autologous stem cell transplantation. *Blood*. 2012;119:4619–24.
22. Sasaki N, Kuroda J, Nagoshi H, et al. Bcl-2 is a better therapeutic target than c-Myc, but attacking both could be a more effective treatment strategy for B-cell lymphoma with concurrent Bcl-2 and c-Myc overexpression. *Exp Hematol*. 2011;39:817–28.
23. Dunleavy K, Little RF, Pittaluga S, et al. A prospective study of dose-adjusted EPOCH with rituximab in adults with newly diagnosed Burkitt lymphoma: a regimen with high efficacy and low toxicity. *Ann Oncol*. 2008;19:483.
24. Greb A, Bohlius J, Trelle S, et al. High-dose chemotherapy with autologous stem cell support in first-line treatment of aggressive non-Hodgkin lymphoma—results of a comprehensive meta-analysis. *J Cancer Treat Rev*. 2007;33:338–46.
25. Espigado I, Ríos E, Marin-Niebla A, et al. High rate of long-term survival for high-risk lymphoma patients treated with hematopoietic stem cell transplantation as consolidation or salvage therapy. *Transplant Proc*. 2008;40:3104–5.