

Received: 2016.08.09
Accepted: 2016.10.12
Published: 2017.01.05

ISSN 1941-5923
© Am J Case Rep, 2017; 18: 17-21
DOI: 10.12659/AJCR.900970

Polymyositis without Beneficial Response to Steroid Therapy: Should Miyoshi Myopathy be a Differential Diagnosis?

Authors' Contribution:
Study Design A
Data Collection B
Statistical Analysis C
Data Interpretation D
Manuscript Preparation E
Literature Search F
Funds Collection G

ABDEF 1,2,3 **Renata Siciliani Scalco***
EF 4 **Paulo José Lorenzoni***
ACD 1 **David S. Lynch**
BE 2 **William Alves Martins**
DE 5,6,7 **Heinz Jungbluth**
DE 1 **Ros Quinlivan**
ABD 2 **Jefferson Becker**
ACD 1 **Henry Houlden**

1 MRC Centre for Neuromuscular Diseases and Division of Molecular Neuroscience, University College London (UCL) Institute of Neurology, London, U.K.
2 Department of Neurology, Pontifical Catholic University of Rio Grande do Sul (PUCRS), Porto Alegre, Brazil
3 Capes Foundation, Ministry of Education, Brasil, Brazil
4 Service of Neuromuscular Disorders, Division of Neurology, Department of Internal Medicine, Universidade Federal do Paraná (UFPR), Curitiba, Brazil
5 Department of Basic and Clinical Neuroscience, Institute of Psychiatry, Psychology and Neuroscience, King's College London (KCL), London, U.K.
6 Department of Paediatric Neurology, Evelina Children's Hospital, Guy's and St Thomas NHS Foundation Trust, London, U.K.
7 Randall Division for Cell and Molecular Biophysics, Muscle Signalling Section, King's College London, London, U.K.

* Both authors contributed equally to this publication

Corresponding Author: Henry Houlden, e-mail: h.houlden@ucl.ac.uk
Conflict of interest: None declared

Patient: Male, 16
Final Diagnosis: Miyoshi myopathy
Symptoms: HyperCKemia • myalgia • weakness
Medication: —
Clinical Procedure: —
Specialty: Neurology

Objective: Rare disease


Background: Miyoshi myopathy (MM) is an autosomal-recessive muscle disorder caused by mutations in the *DYSF* gene. Clinical features and histopathological changes in dysferlinopathies may mimic inflammatory myopathies and a high degree of clinical suspicion is required to guide the genetic investigation.

Case Report: We report the case of a 16-year-old male who presented with severe bilateral calf pain and elevated CK levels (15 000 IU/l) who was on prolonged steroid therapy prompted by the clinical suspicion of inflammatory myopathy. Three years into his illness, he was referred for neuromuscular evaluation presenting with untreatable muscle pain and progressive weakness. The diagnosis of "refractory polymyositis" was revisited. Targeted exome sequencing revealed homozygous pathogenic mutations in the *DYSF* gene, confirming a diagnosis of Miyoshi myopathy.

Conclusions: Our case illustrates that severe muscle pain may be the initial feature of Miyoshi myopathy and should be considered in the differential diagnosis of inflammatory myopathies. Although the described patient reported partial clinical improvement in muscle pain, steroid treatment is not an effective therapy for dysferlinopathy patients and it did not prevent disease progression. In addition, we confirm the utility of next-generation sequencing approaches to myopathies, particularly in complex or unusual cases when muscle biopsy is not available.

MeSH Keywords: Diagnostic Errors • Genetic Testing • Myalgia

Full-text PDF: <http://www.amjcaserep.com/abstract/index/idArt/900970>

 1236

 1

 1

 18



Background

Miyoshi myopathy (MM) is an autosomal-recessive muscle disorder caused by mutations in the *DYSF* gene (OMIM #603009) characterized by an early adult onset muscular dystrophy predominantly characterized by distal and posterior leg muscle involvement in association with markedly elevated serum creatine kinase (CK) levels [1–3]. The diagnosis is confirmed by reduced dysferlin protein expression in muscle biopsy and/or confirmed pathogenic mutations in the *DYSF* gene [1,4]. We report a patient who presented with severe muscle pain in association with elevated CK levels who was initially misdiagnosed as having polymyositis.

Case Report

A Brazilian teenage boy reported severe myalgia affecting calf muscles at the age of 16. He was initially diagnosed with an inflammatory myopathy (polymyositis). Steroid treatment (prednisone 80mg/day) was prescribed, with a partial clinical improvement of the myalgia. Unfortunately, muscle biopsy, muscle MRI, and genetic tests were not available when he was first treated. Past medical history had been uneventful. Attempts to reduce the steroid dose resulted in worsening of muscle pain, which became increasingly severe and limited his physical activities. He was also hampered by adverse effects, including cushingoid-appearance and weight gain. As the disease progressed, he reported difficulty climbing stairs and frequent falls while walking long distances. Fatigue was prompted by moderate exertion. As muscle weakness and pain progressed, he was referred to neuromuscular evaluation. A physical exam performed 3 years following the clinical onset revealed symmetrical weakness in the arms (MRC 4+ proximally and MRC 4 distally) and in the legs (MRC 4 proximally and MRC 3 distally). Distal weakness was evident in lower limbs with weakness of both feet, particularly in foot flexion (MRC 3) with associated inability to walk on the toes. Muscle atrophy was prominent in the calves (Figure 1A). There was no facial weakness or scapular winging. There were no cardiorespiratory symptoms. Further investigation revealed elevated serum CK levels (>15 000 IU/L; normal range: 60–174 IU/L). Needle electromyography showed myopathic features (lower limbs > upper limbs). Lower limbs muscle MRI performed at a later stage showed bilateral involvement of the posterior compartment (Figure 1B).

His parents were first-degree cousins. His father died at age 50 years due to an unexplained cardiac arrhythmia. His mother did not report neuromuscular symptoms apart from generalized fatigue. His 3 sisters were asymptomatic.

Even though this patient was initially diagnosed as having inflammatory myopathy, the clinical phenotype was very atypical

for polymyositis and was more consistent with an underlying neuromuscular disorder such as MM. His parents were first-degree cousins, which increased the suspicion of an inherited disease. To confirm the existence of an underlying neuromuscular disorder, targeted exome sequencing (Illumina TruSight) was performed and revealed a homozygous frameshift deletion of 'TC' at position c.3149_3150del (p. Leu1050Glnfs*63) in exon 29 of the *DYSF* gene (Figure 1C) and a heterozygous V62I variant in the *MYF6* gene (herculin). Sanger sequencing confirmed that both variants were also present in the patient's mother in the heterozygous state. Following the genetic diagnosis, the patient's mother underwent a physical exam and had normal results, with normal electromyography results and a slightly increased CK measurement (268 IU/L; VR: 30–135 IU/L). Steroid therapy was discontinued and amitriptyline was prescribed for muscle pain, with mild improvement of the muscle pain.

Discussion

Clinical features and histopathological changes in dysferlinopathies may mimic inflammatory myopathies, and a high degree of clinical suspicion is required to guide the genetic investigation [5]. Physical examination is likely to reveal predominance of distal weakness and muscle atrophy mainly affecting posterior segments of the legs, with inability to stand on the toes, which is an important diagnostic clue for MM [2,6–8].

Approximately 25% of patients with *DYSF* gene mutations are initially misdiagnosed as having polymyositis [2] and approximately 10% to 15% of patients with MM may have received the clinical diagnosis of an inflammatory myopathy before immunohistochemical analysis for dysferlin became available [2,5]. Misdiagnosis of MM as inflammatory myopathy has been previously reported in 8 cases (Table 1) [2,5,7,9,10] although this could be an underestimate. Misdiagnosis often concerned sporadic forms of the disease not responsive to steroid treatment, based on clinical assessment and/or histopathological evaluation [5,7,9]. The correct diagnosis of MM diagnosis was eventually established by dysferlin immunostaining on muscle biopsy and/or genetic analysis in the described cases.

Muscle biopsy in dysferlinopathies may show inflammatory infiltration [5–7,9], further leading to a misdiagnosis of inflammatory myopathy [4,7,9] highlighting the importance of performing dysferlin immunostaining when assessing muscle biopsies of young adults presenting with muscle pain and other non-specific features, in whom inflammatory myopathy was initially suspected [5,7,9]. The widespread upregulated MHC-I expression in muscle fibers can also help in the histological differentiation of these disorders because it is more evident in polymyositis [11], although different patterns of

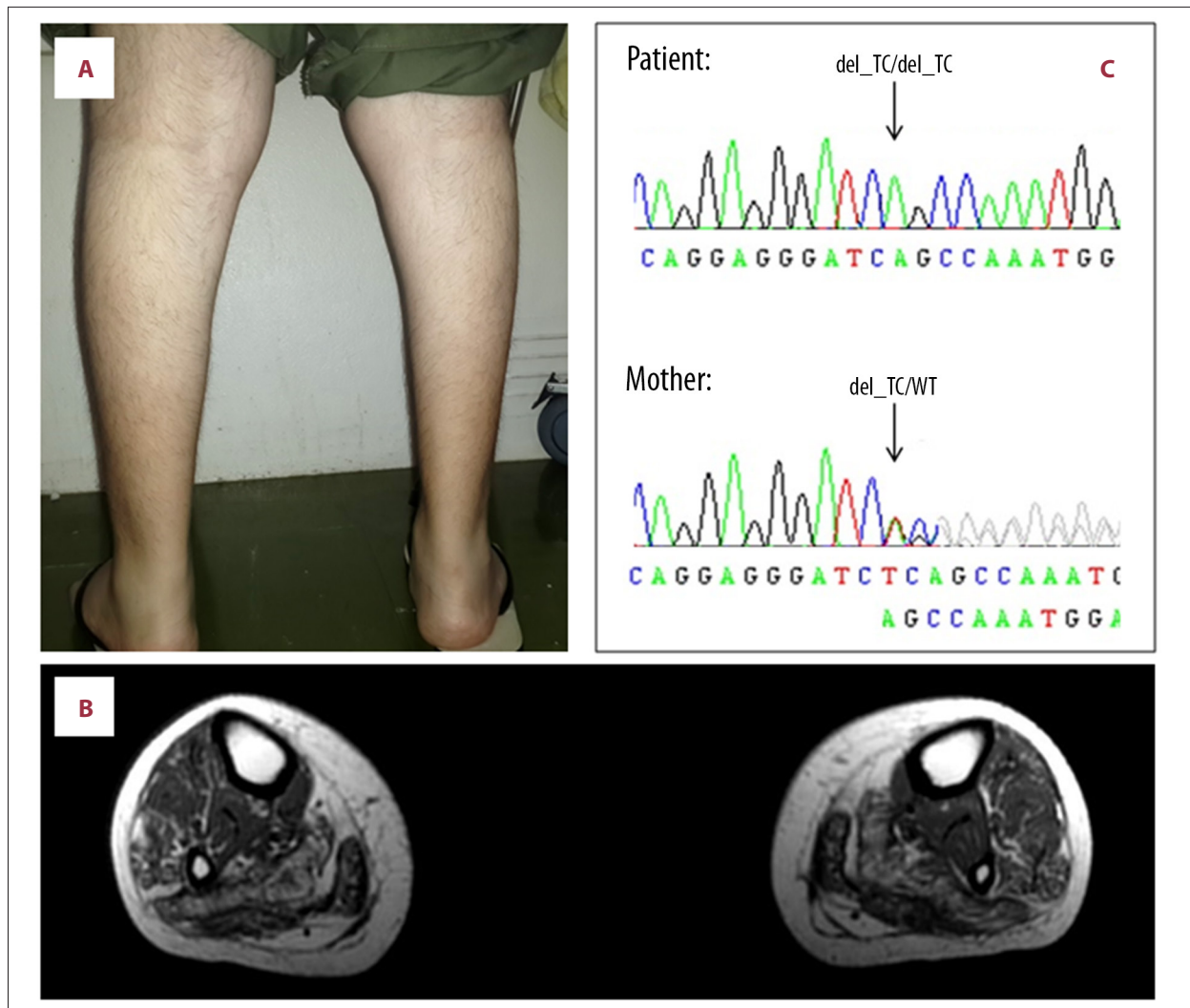


Figure 1. Clinical, radiological, and genetic features in the reported case. Illustration of the leg muscle atrophy (A). Lower-limb muscle MRI showed bilateral muscle atrophy mainly affecting the posterior compartment, increased signal in T1-weighted image representing fat infiltration, and fibrosis in the calf regions (B). Chromatogram demonstrated the result of *DYSF* gene sequencing in the patient and his unaffected mother (C).

upregulation have been reported in association with dysferlinopathies [2,4,12,13]. Partial invasion has been described in association with myositis [11]. The presence of inflammatory infiltrates in muscle biopsy of dysferlinopathies has been associated with a higher rate of disease progression [2].

The reported patient was initially misdiagnosed with an inflammatory myopathy prompted by severe muscle pain and high CK levels. Unfortunately, muscle biopsy, muscle MRI, and genetic investigation were not performed at an early stage due to public health system limitations [14,15], which, in association with the partial improvement of the myalgia in response to steroid treatment, contributed to the delay in considering a genetic cause. Although the described patient reported partial clinical improvement in muscle pain [7], steroid treatment

is not an effective therapy for dysferlinopathy patients and it did not prevent muscle weakness and disease progression [6,9,16]. We suggest that patients presenting with muscle pain initially diagnosed with polymyositis “refractory” to treatment should undergo muscle biopsy at an early stage or genetic investigation for an underlying neuromuscular disorder such as dysferlinopathy, especially if muscle pathology immunostainings are restricted and miss important staining such as dysferlin immunostaining, even if more typical features of these conditions have not evolved yet.

The frameshift deletion in the *DYSF* gene found in our patient was previously reported as pathogenic, causing limb-girdle muscular dystrophy type 2B in another Brazilian patient (see Leiden *DYSF* mutation database, unpublished case) [17].

Table 1. Previously published patients in the English literature with Miyoshi myopathy misdiagnosed as polymyositis.

Case	1 Gallardo et al. (2001) [9]	2 Gallardo et al. (2001) [9]	3 Cho et al. (2006) [7]	4 Cho et al. (2006) [7]	5 Nguyen et al. (2007) [2]	6 Park et al. (2012) [10]	7 Park et al. (2012) [5]	8 Park et al. (2012) [5]	9 Present case
Sex	M	M	M	F	NI	NI	M	M	M
Age at onset (years)	17	17	17	26	NI	NI	21	20	16
Age (years)**	NI	NI	45	30	NI	NI	22	50	19
Family history	–	–	+	–	NI	–	–	–	–
CK*	>10(?)	>10(?)	38	36	NI	>10(?)	41	8	86
Neurophysiology	NI	NI	Myop	Myop	NI	NI	Myop	Myop	Myop
PM diagnosis by	C	MBwd	MBwd	MBwd	MBwd	NI	MBwd	MBwd	C
Muscle biopsy:									
Inflammatory infiltrate	–	+	+	+	+	+	+	+	NK
Dysferlin deficiency	+WB	+WB	NK	NK	+IH	+IH/WB	+IH	+IH	NK
Genetic analysis***	NK	NK	+	+	+(?)	+(?)	–	–	+
PM therapy	CC	CC	CC	CC	CC	CC	CC, IVIg	CC, IVIg	CC
Beneficial PM therapy	–	–	–#	–#	–	NI	–	–	–#

MM – Miyoshi myopathy; PM – polymyositis; CK – serum creatine kinase level; * times above normal value; ** age at MM diagnosis; *** pathogenic mutations in the DYSF gene; ‘+’ – present or positive; ‘–’ – absent or negative; ‘±’ – reduced; C – clinical data; MBwd – muscle biopsy without dysferlin analysis; Myop – myopathic changes; IH – immunohistochemistry; WB – western blot; CC – corticosteroid; IVIg – intravenous immunoglobulin; NK – not performed; NI – no information; # showed transient responses at the initial treatment; (?) – no full information in the article.

Variants in the *MYF6* gene have been reported as a genetic modifier in X-linked muscular dystrophy [18]; however, without additional functional data it is very difficult to prove that the *MYF6* V62I variant identified acted as a genetic modifier in our patient. The patient’s mother carried the same *MYF6* V62I variant and was asymptomatic apart from a very mildly raised CK level (268 IU/L; VR: 30–135 IU/L).

Conclusions

We reported a patient with MM who initially presented with severe muscle pain misdiagnosed as polymyositis resistant to steroid therapy. Myalgia partially improved with steroid treatment even though distal muscle weakness slowly progressed. This case illustrates that diagnosis and treatment based solely on clinical presentation may not be an appropriate method

because different conditions may overlap in the early manifestation. Polymyositis usually responds dramatically to steroid therapy, either histologically or clinically. In the absence of such a dramatic response, more diagnostic attempts, including either dysferlin immunostaining or Western blot analysis, should be undertaken. Our observation confirms that next-generation sequencing approaches, through disease-specific panels or targeted exome sequencing, are very helpful in the evaluation of the differential diagnosis of inherited neuromuscular disorders, especially when muscle biopsy is not available, as occurred in our case.

Acknowledgment

The authors would like to thank The MRC, Wellcome Trust and NIHR BRC.

References:

1. Kawabe K, Goto K, Nishino I et al: Dysferlin mutation analysis in a group of Italian patients with limb-girdle muscular dystrophy and Miyoshi myopathy. *Eur J Neurol*, 2004; 11: 657–61
2. Nguyen K, Bassez G, Krahn M et al: Phenotypic study in 40 patients with dysferlin gene mutations: High frequency of atypical phenotypes. *Arch Neurol*, 2007; 64: 1176–82
3. Udd B: Distal myopathies – New genetic entities expand diagnostic challenge. *Neuromuscul Disord*, 2012; 22: 5–12

4. Angelini C, Grisold W, Nigro V: Diagnosis by protein analysis of dysferlinopathy in two patients mistaken as polymyositis. *Acta Myol*, 2011; 30: 185–87
5. Park HJ, Hong JM, Suh GI et al: Heterogeneous characteristics of Korean patients with dysferlinopathy. *J Korean Med Sci*, 2012; 27: 423–29
6. Austin SG, Pappolla MA, Dimachkie M, Vriesendorp FJ: A confusing case of Miyoshi distal myopathy. *Muscle Nerve*, 1995; 18: 922–23
7. Cho HJ, Sung DH, Kim EJ et al: Clinical and genetic analysis of Korean patients with Miyoshi myopathy: identification of three novel mutations in the DYSF gene. *J Korean Med Sci*, 2006; 21: 724–27
8. Soares CN, de Freitas MR, Nascimento OJ et al: Myopathy of distal lower limbs: the clinical variant of Miyoshi. *Arq Neuropsiquiatr*, 2003; 61: 946–49
9. Gallardo E, Rojas-Garcia R, de Luna N et al: Inflammation in dysferlin myopathy: Immunohistochemical characterization of 13 patients. *Neurology*, 2001; 57: 2136–18
10. Park YE, Kim HS, Lee CH et al: Two common mutations (p.Gln832X and c.663+1G>C) account for about a third of the DYSF mutations in Korean patients with dysferlinopathy. *Neuromuscul Disord*, 2012; 22: 505–10
11. Hilton-Jones D: Myositis mimics: how to recognize them. *Curr Opin Rheumatol*, 2014; 26: 663–70
12. Jethwa H, Jacques TS, Gunny R, Wedderburn LR et al: Limb girdle muscular dystrophy type 2B masquerading as inflammatory myopathy: Case report. *Pediatr Rheumatol Online J*, 2013; 11: 19
13. Cenacchi G, Fanin M, De Giorgi LB, Angelini C: Ultrastructural changes in dysferlinopathy support defective membrane repair mechanism. *J Clin Pathol*, 2005; 58: 190–95
14. Zavascki AP: Brazil's Family Health Strategy. *N Engl J Med*, 2015; 373: 1277–78
15. Trevisol DJ, Traebert J, Schuelter-Trevisol FL: Brazil's Family Health Strategy. *N Engl J Med*, 2015; 373: 1277
16. Walter MC, Reilich P, Thiele S et al: Treatment of dysferlinopathy with deflazacort: A double-blind, placebo-controlled clinical trial. *Orphanet J Rare Dis*, 2013; 8: 26
17. Dysferlin. Available from: http://www.dmd.nl/nmdb/variants.php?select_db=DYSF&action=view&view=0002535%2C0000541%2C0 [cited 2015 15 May 2015]
18. Kerst B, Mennerich D, Schuelke M et al: Heterozygous myogenic factor 6 mutation associated with myopathy and severe course of Becker muscular dystrophy. *Neuromuscul Disord*, 2000; 10: 572–77