

Traumatic Basilar Artery Entrapment without Longitudinal Clivus Fracture: A Case Report and Review of the Literature

Ayumu YAMAOKA,¹ Kei MIYATA,^{1,2} Naofumi BUNYA,¹ Hirotoishi MIZUNO,¹ Hideto IRIFUNE,¹ Naoya YAMA,³ Yukinori AKIYAMA,² Takeshi MIKAMI,² Masahiko WANIBUCHI,² and Nobuhiro MIKUNI²

¹Department of Emergency Medicine, Sapporo Medical University, Sapporo, Hokkaido, Japan;

²Department of Neurosurgery, Sapporo Medical University, Sapporo, Hokkaido, Japan;

³Department of Diagnostic Radiology, Sapporo Medical University, Sapporo, Hokkaido, Japan

Abstract

In blunt cerebrovascular injury, reported traumatic basilar artery occlusions have involved dissection of the basilar artery, distal embolization due to traumatic vertebral artery dissection, or entrapment of the basilar artery into the clivus fracture. To date, however, there are no reports of traumatic basilar artery entrapment without a clivus fracture. Here, we report the first case of traumatic basilar artery occlusion caused by entrapment into an originally existing bone defect. A 67-year-old man with a history of treatment for intracranial aneurysm suffered multiple traumatic injuries in a fall. On arrival at our hospital, he presented with neurogenic shock with quadriplegia. Computed tomography (CT) showed small epidural hematoma, C4-6 cervical spinous process fracture, and Th2-3 vertebral body fracture. CT angiography revealed occlusion of the basilar artery trunk. As vertebrobasilar artery dissections and clivus fracture were not observed; however, we could not elucidate the pathology of the basilar artery occlusion. On day 4, after surgery for the cervical and thoracic lesions, he exhibited consciousness disturbance. Diffusion-weighted imaging on day 5 showed hyperintensities in the brainstem and cerebellum. Basi-parallel anatomic scanning magnetic resonance imaging showed that the basilar artery, while lacking vascular wall injuries, was tethered into the clivus. Antithrombotic therapy was performed, but the patient progressed to a locked-in state. Previous head CT before the trauma revealed a bone defect already present in the clivus. We speculated basilar artery entrapment into this preexisting bone defect. We must look for basilar artery injury in trauma patients even in the absence of clivus fracture.

Key words: traumatic basilar artery entrapment, brainstem infarction, sphenoid-occipital synchondrosis, basi-parallel anatomical scanning

Introduction

Blunt cerebrovascular injuries (BCVIs) affecting the carotid or vertebral artery can lead to abnormal arterial narrowing, pseudoaneurysm, and occlusion, and typically occur in the setting of either generalized multiple trauma or direct craniocervical trauma. Although rare, there are some reports of traumatic basilar artery occlusion causing lethal infarction

of the brainstem and severe disability or death.^{1–10)} Reported mechanisms of traumatic basilar artery occlusion have involved dissection of the basilar artery originating from the trauma itself,¹¹⁾ distal embolization due to traumatic vertebral artery dissection,¹²⁾ or entrapment of the basilar artery into a longitudinal clivus fracture.^{1–10,13–16)} In the absence of clivus fracture, however, to the best of our knowledge, there are no reports of traumatic basilar artery entrapment. Here, we report the first case of traumatic basilar artery occlusion caused by entrapment into an originally existing bone cortex defect at the sphenoid-occipital synchondrosis, and review the relevant published literature.

Received February 9, 2018; Accepted April 3, 2018

Copyright© 2018 by The Japan Neurosurgical Society
This work is licensed under a Creative Commons Attribution-NonCommercial-NoDerivatives International License.

Case Report

A 67-year-old man fell to the ground from the cargo bed of a truck (height of approximately 1 m), and was initially transferred to another emergency hospital. He suffered from neurogenic shock with quadriplegia, and was treated with an adrenergic vasopressor. He was transferred to our hospital for multidisciplinary treatment. On arrival at our hospital, the patient was alert with a Glasgow Coma Scale score of 14 (E3V5M6). His vital signs were respiratory rate 23 breaths/min, blood pressure 106/69 mmHg (dopamine, 5.5 µg/kg/min), and heart rate 70 bpm (sinus rhythm). His oxygenation on pulse oximetry (SpO₂) was 99% (O₂ 1L). Computed tomography (CT) of the head revealed a small epidural hematoma at the frontal bone of the skull. He had a past history of bifrontal craniotomy for surgical clipping of an intracranial aneurysm 3 years earlier at another hospital. He also exhibited a C4-6 cervical spinous process fracture, Th2-3 vertebral-body fracture, bilateral first rib fracture, and sternal fracture. T₂-weighted magnetic resonance imaging (MRI) showed high-intensity areas at the C3-4 and Th2 spinal cord. Three-dimensional CT angiography (3D-CTA) as part of a whole-body CT

scan revealed occlusion of the basilar artery trunk and poor description of the left vertebral artery distal to the posterior inferior cerebellar artery (Fig. 1A, C–E). In contrast, no abnormal findings, such as arterial dissection were observed in the vertebral artery near the cervical vertebral fracture. We could not recognize any obvious clivus fracture on multi-planar CT images. The patient presented no neurological abnormality except for quadriplegia. Because of ongoing management, including surgery for multiple traumas, antithrombotic therapy was not indicated. On day 3, the patient underwent posterior fusion surgery for the cervical and thoracic lesions, and went into hypovolemic shock due to intraoperative bleeding. His systolic blood pressure decreased to <80 mmHg several times. After the surgery, he exhibited delayed awakening from anesthesia with severe consciousness disturbance. On day 4, head CT showed no evidence of intracranial hemorrhage but did show a small low-density area on the pons and cerebellum. On day 5, diffusion-weighted imaging showed hyperintensities in the area of the pontine arteries and the left anterior inferior cerebellar artery (Fig. 2A, B). We retrospectively recognized that the lower half of the basilar artery trunk was entrapped in a minor bone defect in the

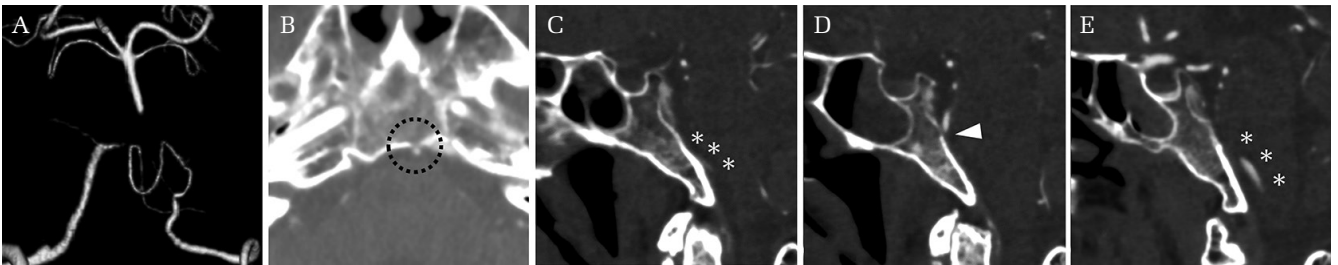


Fig. 1 Computed tomography (CT) images of the head at admission showed occlusion of the basilar artery trunk. (A) Poor description of the left vertebral artery distal to the posterior inferior cerebellar artery (C), and the right vertebral artery proximal to the bifurcation (E). The lower half of the basilar artery trunk was entrapped in a minor hole in the middle part of the clivus (B, D).

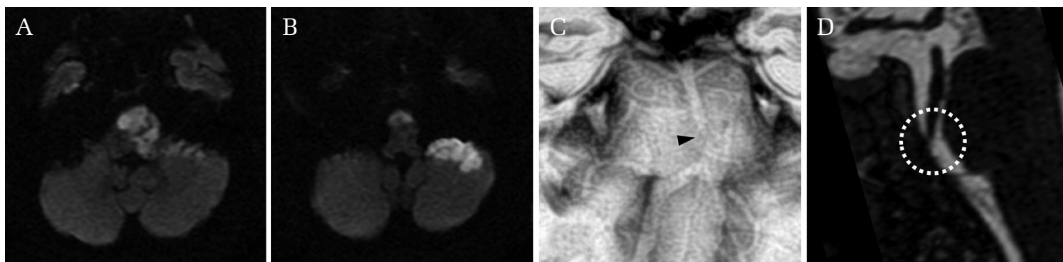


Fig. 2 Magnetic resonance imaging (MRI) of the head on day 5 (A, B) showed hyperintensities in the area of the pontine arteries and the left anterior inferior cerebellar artery. Basi-parallel anatomic scanning MRI (BPAS-MRI) on day 6 (C) revealed that the outer contour of the basilar artery was narrowed at the middle portion of the clivus (*black arrow*). BPAS-MRI on day 18 (D) showed that the basilar artery trunk was tethered to the clivus (*white dotted circle*).

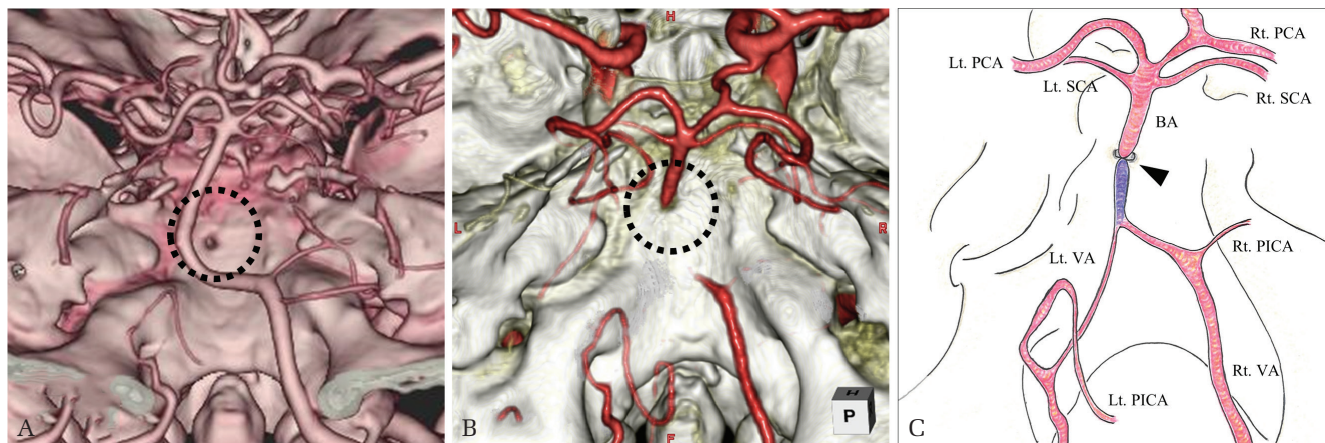


Fig. 3 Previous head computed tomography (CT) performed 3 years before this injury (A) revealed the same bone defect in the middle region of the clivus (*black dotted circle*). Three-dimensional computed tomography angiography (3D-CTA) at admission (B) showed the basilar artery entrapped in the middle portion of the clivus (*black dotted circle*). A speculated schematic drawing of the vertebrobasilar artery in this case (C) demonstrated a retrograde thrombosis or dissecting occlusion of the basilar artery (*painted purple*).

middle part of the clivus, which was visible on the 3D-CTA performed at admission (Figs. 1B and 3B). We confirmed stabilization of the hemorrhagic lesions at other trauma sites and started antithrombotic therapy with heparin and aspirin immediately after the diagnosis. Basi-parallel anatomic scanning MRI (BPAS-MRI) findings on day 6 revealed that the outer contour of the basilar artery narrowed at the middle portion of the clivus (Fig. 2C). On day 10, 3D digital subtraction angiography (DSA) confirmed retrograde blood flow from the right posterior communicating artery to points distal to the basilar artery occlusion. Sagittal BPAS-MRI images on day 18 revealed that the basilar artery trunk with a normal outer contour was tethered to the middle portion of the clivus (Fig. 2D). The patient progressed to a locked-in state, and was transferred to another hospital for rehabilitation on day 19. Previous head CT performed at another hospital at the time of aneurysmal clipping 3 years prior to this injury revealed that the bone defect in the middle clivus was present at that time (Fig. 3A). The location of the bone defect was highly suggestive of a remnant of sphenoid-occipital synchondrosis.

Discussion

The course of our case suggested two important clinical issues. First, it should be noted that the traumatic basilar artery occlusion occurred without a clivus fracture. Second, the combination of radiological modalities was useful in the differential diagnosis of basilar artery occlusion.

About 15 previous cases of traumatic basilar artery entrapment can be retrieved by searching the PubMed electronic database^{1-10,13-17} (Table 1). In our review, 14 involved a longitudinal clivus fracture,^{1-10,13-16} and the remaining case involved a nondisplaced clivus fracture.¹⁷ The typical mechanism of traumatic basilar artery entrapment is understood as follows: the basilar artery is pressed against the fissure of a longitudinal clivus fracture, the fracture is closed, and the basilar artery is incarcerated.^{7,9} This injury mechanism is thought to explain why traumatic basilar artery entrapment cannot usually occur without a longitudinal clivus fracture. Our case, in contrast, exhibited no clivus fracture, but a minor bone defect in the clivus was observed. We suspected that this bone defect had occurred as a remnant of sphenoid-occipital synchondrosis in the process of endochondral ossification. After birth, the clivus develops from a sphenoid bone at the top and an occipital bone at the bottom. Between these bones is the sphenoid-occipital synchondrosis. It has been reported that complete closure of this synchondrosis in males occurs between 13 and 25 years of age.¹⁸ However, complete holes in this location have also been reported in several cases associated with spontaneous cerebrospinal fluid rhinorrhea.¹⁹ The sphenoid-occipital synchondrosis develops through endochondral ossification without fusion points, which could explain the occasional development of bone defects and eventual dehiscence at this site.²⁰ In our case, moreover, CT findings of the cervical vertebral fracture indicated a cervical extension injury pattern.²¹ It was suggested that the spinal cord had been towed downward. From these

Table 1 Summary of patients with traumatic basilar artery entrapment

Author, Year	Age/sex	GCS score	Diagnostic method	Clivus fracture	Basilar artery	Treatment	Outcome
Fang (2012) ¹⁴	39 M	3 (Drunk)	CT, CTA	Longitudinal	Severe stenosis	Not described	Completely recovered
Garcia-Garcia (2012) ³	37 M	15	CT, CTA	Longitudinal	Occlusion	AT	Mild left hemiparesis
Bala (2004) ¹⁶	46 M	15	CT, CTA, MRA	Longitudinal	Severe stenosis	AT	Mild left hemiparesis
Khanna (2010) ¹⁵	55 M	8 (Sedated)	CT, CTA	Longitudinal	Severe stenosis	Not described	Left hemiparesis
Taguchi (2000) ⁵	52 M	3 (Drunk)	CT, MRA	Longitudinal	Occlusion	AT	Quadriparesis
Present case (2017)	67 M	14	CT, CTA, BPAS-MRI	None	Occlusion	AT	Locked-in state
Wang (2017) ¹	59 M	15	CT, CTA	Longitudinal	Focal stenosis → Occlusion	AT	Locked-in state
Sen-Gupta (2012) ²	67 M	11	CT, CTA	Longitudinal	Occlusion	Not described	Locked-in state
Kaakaji (2004) ¹⁷	50 M	6	CT, MRA	Nondisplaced	Severe stenosis	EVD	Locked-in state
Guha (1989) ⁶	27 M	3	CT, DSA	Longitudinal	Occlusion	Not described	Vesitative state
Kliesch (2017) ¹³	Adult	11	CT, CTA, 3D-FPA	Longitudinal	Severe stenosis	DC	Death
Sato (2001) ⁴	56 M	5	CT, DSA	Longitudinal	Occlusion	Not described	Death
Anthony (1987) ⁷	70 M	3	Autopsy	Longitudinal	Occlusion	Not described	Death
Shaw (1972) ⁸	59 M	3	Autopsy	Longitudinal	Occlusion	Supportive care	Death
Sights (1968) ⁹	23 M	3	Autopsy	Longitudinal	Occlusion	Supportive care	Death
Loop (1964) ¹⁰	59 M	3	Autopsy	Longitudinal	Occlusion	Supportive care	Death

AT: Antithrombotic therapy, BPAS-MRI: basi-parallel anatomic scanning-magnetic resonance imaging, CT: computed tomography, CTA: computed tomography angiography, DSA: digital subtraction angiography, 3D-FPA: three-dimensional flat panel angiography, DC: decompressive craniectomy, EVD: external ventricular drainage, GCS: glasgow coma scale, MRI: magnetic resonance imaging, MRA: magnetic resonance angiography.

findings, the following mechanisms were presumed to have caused this case. A laceration occurred in the dura due to external force from the fall. The brainstem was towed downward by the traction of the spinal cord. The basilar artery was compressed between the brainstem and the clivus bone, and was coincidentally entrapped in the bone defect of the clivus. Additionally, we speculated that the entrapment of the basilar trunk has progressively led to a retrograde thrombosis or dissecting occlusion and delayed pontine perforators infarction (Fig. 3C).

The combination of radiological modalities was useful in the differential diagnosis of basilar artery occlusion. Because CTA is affected by blood flow and the contrast agent is visualized in the vascular inner luminal regions, it is difficult to visualize the vessels themselves. Evaluating the outer contour of the basilar artery by BPAS-MRI enables us to

distinguish whether pathology is due to arterial dissection.²² Traumatic basilar artery occlusion due to entrapment is often diagnosed based on radiological findings showing a longitudinal clivus fracture and obvious invagination of the basilar artery. In our case, although CTA and MRA revealed the occlusion of the basilar artery, bone scan imaging of the cranial base did not show the clivus fracture. There were no findings suggesting the dissection of vertebrobasilar arteries such as intimal flaps, double lumen, or the pearl and string sign. BPAS-MRI images of this case revealed that the basilar artery was tethered into the clivus in the absence of any vascular wall injury or narrowing. These findings supported our speculation of basilar artery entrapment in an originally existing bone defect. In similar cases in the future, further evaluation for the pathology of basilar artery occlusion may be

important to determine whether reperfusion therapy is warranted during the acute phase. A previous case report suggested that endovascular treatment might be effective for distal embolization of the basilar artery due to traumatic vertebral artery dissection.¹²⁾

For early diagnosis and treatment of BCVI, appropriate evaluation of the head and neck vessels based on signs or symptoms and risk factors must be performed as soon as possible.^{23,24)} Antithrombotic therapy has been reported as the standard treatment for traumatic basilar artery entrapment.¹⁵⁾ In our review, treatment has been described in nine cases and five cases including our case received antithrombotic therapy. Three cases with good neurological outcome (completely recovered or mild left hemiparesis) were diagnosed as basilar artery entrapment on the first day and started treatment.^{3,5,16)} In previous case reports, bifrontal decompressive craniectomy¹³⁾ or external ventricular drainage¹⁷⁾ has been performed to control elevated intracranial pressure caused by the infarction. There are no reports, however, of direct surgical or endovascular treatment for basilar artery entrapment. In our case, we were able to detect traumatic basilar artery occlusion on cranial CTA at admission. Antithrombotic therapy was not started; however, we did not observe apparent clinical signs of basilar artery occlusion and peri-operative management. Also, we did not perform an assessment of cerebral blood flow besides CTA at admission. It was reported that most patients with BCVIs exhibit “a latent period (10–72 h)” between their injury and the onset of stroke.²⁵⁾ In our review, four cases including our case were alert at admission (GCS 14 or 15).^{1,3,16)} Two cases, however, developed consciousness disturbance and proceeded to a locked-in state.¹⁾ Even in the absence of clinical signs, if there are equivocal findings, early evaluation of cerebral blood flow such as DSA is needed.²³⁾ Furthermore, immediate antithrombotic therapy for basilar artery occlusion is crucial and should be stopped only during the peri-operative period. We also speculated that the patient's hypovolemic shock during surgery might have caused delayed cerebral infarction. In the case of multiple traumas, it is often difficult to introduce antithrombotic therapy in the acute phase. Strict blood pressure management should be considered to prevent hypovolemic, obstructive, or neurogenic shock.

Conclusions

We experienced a rare case of traumatic basilar artery entrapment that caused severe disability due to basilar artery occlusion in the absence of

a clivus longitudinal fracture. The combination of radiological modalities was useful to detect the cause of traumatic basilar artery occlusion. Early indication of antithrombotic therapy and systemic management are essential for preventing severe cerebral infarction.

Conflicts of Interest Disclosure

No authors have conflicts of interest.

References

- 1) Wang A, Wainwright J, Cooper J, Tenner MS, Tandon A: Basilar artery herniation into the sphenoid sinus secondary to traumatic skull base fractures: case report and review of the literature. *World Neurosurg* 98: 878.e7–878.e10, 2017
- 2) Sen-Gupta I, Daiga DA, Alberts MJ: Teaching neuroimages: locked-in syndrome resulting from traumatic basilar artery occlusion following clivus fracture. *Neurology* 78: e148–e149, 2012
- 3) García-García J, Villar-García M, Abad L, Segura T: Brainstem infarct due to traumatic basilar artery entrapment caused by longitudinal clival fracture. *Arch Neurol* 69: 662–663, 2012
- 4) Sato S, Iida H, Hirayama H, Endo M, Ohwada T, Fujii K: Traumatic basilar artery occlusion caused by a fracture of the clivus—case report. *Neurol Med Chir (Tokyo)* 41: 541–544, 2001
- 5) Taguchi Y, Matsuzawa M, Morishima H, Ono H, Oshima K, Hayakawa M: Incarceration of the basilar artery in a longitudinal fracture of the clivus: case report and literature review. *J Trauma* 48: 1148–1152, 2000
- 6) Guha A, Fazl M, Cooper PW: Isolated basilar artery occlusion associated with a clivus fracture. *Can J Neurol Sci* 16: 81–83, 1989
- 7) Anthony DC, Atwater SK, Rozear MP, Burger PC: Occlusion of the basilar artery within a fracture of the clivus. Case report. *J Neurosurg* 66: 929–931, 1987
- 8) Shaw CM, Alvord EC Jr: Injury of the basilar artery associated with closed head trauma. *J Neurol Neurosurg Psychiatry* 35: 247–257, 1972
- 9) Sights WP Jr: Incarceration of the basilar artery in a fracture of the clivus. Case report. *J Neurosurg* 28: 588–591, 1968
- 10) Loop JW, White LE Jr, Shaw CM: Traumatic occlusion of the basilar artery within a clivus fracture. *Radiology* 83: 36–40, 1964
- 11) Gallerani M, Veronesi V, Ceruti S, Mantovani G, Ghadirpour R: Isolated basilar artery occlusion by parietal dissection after severe chest and minor head trauma. *Am J Emerg Med* 16: 614–616, 1998
- 12) Hauck EF, Natarajan SK, Horvathy DB, Hopkins LN, Siddiqui AH, Levy EI: Stent-assisted basilar reconstruction for a traumatic vertebral dissection

- with a large basilar artery thrombosis. *J Neurointerv Surg* 3: 47–49, 2011
- 13) Kliesch S, Bauknecht C, Bohner G, Liebig T, Siebert E: Traumatic basilar artery entrapment with patency of pontine perforators and absence of significant brainstem infarction: report of an unusual case. *J Neurointerv Surg* 9: e17, 2017
 - 14) Fang J, Kuang L, Chen J, et al.: Posttraumatic basilar artery herniation associated with dissecting aneurysm formation: follow-up over 20 months. *Cardiovasc Intervent Radiol* 35: 1237–1241, 2012
 - 15) Khanna P, Bobinski M: Computed tomography and magnetic resonance imaging of a basilar artery herniation into the sphenoid sinus. *Skull Base* 20: 269–273, 2010
 - 16) Bala A, Knuckey N, Wong G, Lee GY: Longitudinal clivus fracture associated with trapped basilar artery: unusual survival with good neurological recovery. *J Clin Neurosci* 11: 660–663, 2004
 - 17) Kaakaji R, Russell EJ: Basilar artery herniation into the sphenoid sinus resulting in pontine and cerebellar infarction: demonstration by three-dimensional time-of-flight MR angiography. *AJNR Am J Neuroradiol* 25: 1348–1350, 2004
 - 18) Sinanoglu A, Kocasarac HD, Noujeim M: Age estimation by an analysis of spheno-occipital synchondrosis using cone-beam computed tomography. *Leg Med (Tokyo, Japan)* 18: 13–19, 2016
 - 19) Codina Aroca A, Gras Cabrerizo JR, De Juan Delago M, Masegur Solench H: Spontaneous cerebrospinal fluid fistula in the clivus. *Eur Ann Otorhinolaryngol Head Neck Dis* 134: 431–434, 2017
 - 20) Al-Shurbaji AA, Abu-Salma ZA: Spontaneous cerebrospinal fluid rhinorrhea through clival defect. *Neurosciences (Riyadh, Saudi Arabia)* 10: 232–234, 2005
 - 21) Allen BL, Jr, Ferguson RL, Lehmann TR, O'Brien RP: A mechanistic classification of closed, indirect fractures and dislocations of the lower cervical spine. *Spine* 7: 1–27, 1982
 - 22) Nagahata M, Abe Y, Ono S, Hosoya T, Uno S: Surface appearance of the vertebrobasilar artery revealed on basiparallel anatomic scanning (BPAS)-MR imaging: its role for brain MR examination. *AJNR Am J Neuroradiol* 26: 2508–2513, 2005
 - 23) Biffi WL, Cothren CC, Moore EE, et al.: Western Trauma Association critical decisions in trauma: screening for and treatment of blunt cerebrovascular injuries. *J Trauma* 67: 1150–1153, 2009
 - 24) Bromberg WJ, Collier BC, Diebel LN, et al.: Blunt cerebrovascular injury practice management guidelines: the Eastern Association for the Surgery of Trauma. *J Trauma* 68: 471–477, 2010
 - 25) Burlew CC, Biffi WL: Imaging for blunt carotid and vertebral artery injuries. *Surg Clin North Am* 91: 217–231, 2011
-
- Address reprint requests to:* Ayumu Yamaoka, MD, Department of Emergency Medicine, Sapporo Medical University, Sapporo, Hokkaido, Japan, South 1 West 16, Chuo-ku, Sapporo, Hokkaido 060-8543, Japan. *e-mail:* yamaoka@sapmed.ac.jp