



It Is Not Only the Meniscus That Flips—A Case of TFCC Tear with a Flipped Fragment in the Distal Radioulnar Joint

Aakanksha Agarwal¹ Abhishek Chandra² Timothy Murray¹ Mark Cresswell¹

¹Department of Radiology, University of British Columbia, St. Paul's Hospital, Vancouver, Canada

²Department of Orthopedics, All India Institute of Medical Sciences, Rishikesh, Uttarakhand, India

Address for correspondence Aakanksha Agarwal, MD, Department of Radiology, University of British Columbia, St. Paul's Hospital, Vancouver V6Z2P9, Canada (e-mail: a.agarwal.1992@gmail.com).

Indian J Radiol Imaging 2023;33:129–131.

Abstract

Acute wrist injuries with ongoing ulnar-sided wrist pain warrant a magnetic resonance imaging (MRI) to diagnose ligamentous injuries. Triangular fibrocartilage complex (TFCC) tears have been classified and described in the literature but complex tear patterns have limited representation. Bucket-handle tears of the TFCC represent only 0.5% of TFCC tears and have recently been identified, posing a diagnostic and management challenge. Preoperative diagnosis is possible with MRI and necessary for optimal and early surgical management. The authors describe a unique case of a flipped tear of the central disc of the TFCC, where the fragment was flipped into the distal radioulnar joint, a site hidden during routine arthroscopy.

Keywords

- ▶ triangular fibrocartilage tear
- ▶ flipped TFCC
- ▶ MRI in TFCC tear

Introduction

Posttraumatic and unresolving ulnar-sided wrist pain is one of the major indications for a wrist magnetic resonance imaging (MRI). The underlying clinical suspicion in these cases is of a triangular fibrocartilage complex (TFCC) tear. Palmer¹ classified traumatic TFCC tears into four categories that were further expanded by Atzei and Luchetti² who subclassified peripheral tears. Atzei and Luchetti rejuvenated the concept of TFCC tears comparing it to an “iceberg” instead of the usual “hammock” and accentuated the stabilizing action of the deeper portion of the TFCC. More recently, additional tear variations have been noted, which appear to have a frequency of one in 200 MRI scans.³ We describe one such case with a complex TFCC tear in which the torn fragment is displaced and flipped into distal radioulnar joint (DRUJ).

Case Report

A 34-year-old male patient presented with ongoing wrist pain after a motor-bike accident. On clinical examination, focal tenderness was elicited at the ulnar styloid and the patient mentioned discomfort with supination and pronation. The piano key sign was positive suggesting DRUJ instability.

Wrist radiographs were unremarkable and the patient was referred for an MRI of the wrist that revealed an interesting tear pattern of the TFCC. The central disc was torn and flipped into the DRUJ with attenuation of the dorsal radioulnar ligament. The volar radioulnar ligament, the foveal and styloid attachments of the TFCC, and the ulno-meniscal homolog were intact. The ulnotriquetral and ulno-lunate ligaments were also intact. The patient was noted to have mild positive ulnar variance (▶ **Fig. 1**).

article published online
December 7, 2022

DOI <https://doi.org/10.1055/s-0042-1759484>.
ISSN 0971-3026.

© 2022. Indian Radiological Association. All rights reserved.
This is an open access article published by Thieme under the terms of the Creative Commons Attribution-NonDerivative-NonCommercial-License, permitting copying and reproduction so long as the original work is given appropriate credit. Contents may not be used for commercial purposes, or adapted, remixed, transformed or built upon. (<https://creativecommons.org/licenses/by-nc-nd/4.0/>)
Thieme Medical and Scientific Publishers Pvt. Ltd., A-12, 2nd Floor, Sector 2, Noida-201301 UP, India

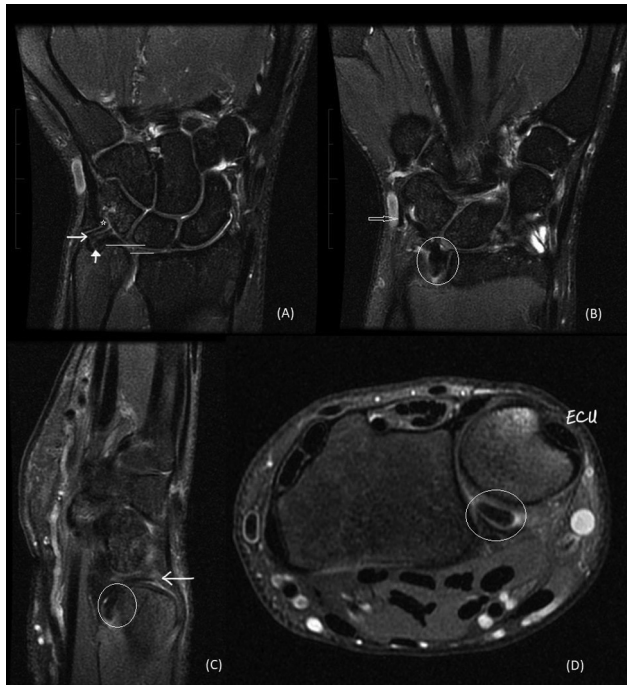


Fig. 1 Index case with a flipped fragment (encircled) in the distal radioulnar joint (DRUJ). (A) Coronal proton density fat saturated (PDFS) image demonstrating intact styloid (arrow) and foveal (solid arrow) attachments of triangular fibrocartilage complex with the meniscal homolog (asterisk). The solid horizontal lines depict the mild positive ulnar variance. (B) Flipped fragment in the DRUJ (encircled) with intact ulnar collateral ligament (arrow). (C) Sagittal PDFS image demonstrating the flipped component into the volar aspect of DRUJ (encircled) with attenuated dorsal radioulnar ligament (arrow). (D) Axial PDFS image demonstrating the flipped fragment (encircled) on the volar aspect of the DRUJ.

The patient underwent reconstructive arthroscopy with removal of the fragment from the DRUJ.

Discussion

The TFCC is a complex structure with multiple parts—articular disc, meniscus homolog, distal radioulnar ligaments, ulnocarpal and ulnar collateral ligament, ulnomeniscal homolog, and extensor carpi ulnaris tendon sheath.^{4,5}

Clinical presentation differs with the location of a TFCC tear—if the peripheral TFCC is torn, the patient will experience a constant pain limiting range of motion; while a central tear will result in pain with pronation and supination.^{4–8} However, the clinical examination can remain challenging, necessitating imaging for planning further management. MRI is the preferred modality for assessing the TFCC that itself has a complex anatomy. Palmer and Atzei^{1,2} classified TFCC tears to better characterize them and assist in making management decisions. There remains limited discussion of injuries to the dorsal components and complex tear anatomies.

Literature search revealed that the first case of a displaced TFCC tear was described in 2011 by Theumann et al⁹ who described the pattern as a “bucket-handle” tear, reminiscing the more widely known and described bucket-handle tears of the menisci of the knee. The torn fragment was flipped under itself. Since then, two cases have been described by Jose et al⁴ and another by Toye¹⁰ with the fragment being flipped either in the pre-styloid recess or in the DRUJ, the latter being similar to the index case (► **Fig. 2**).

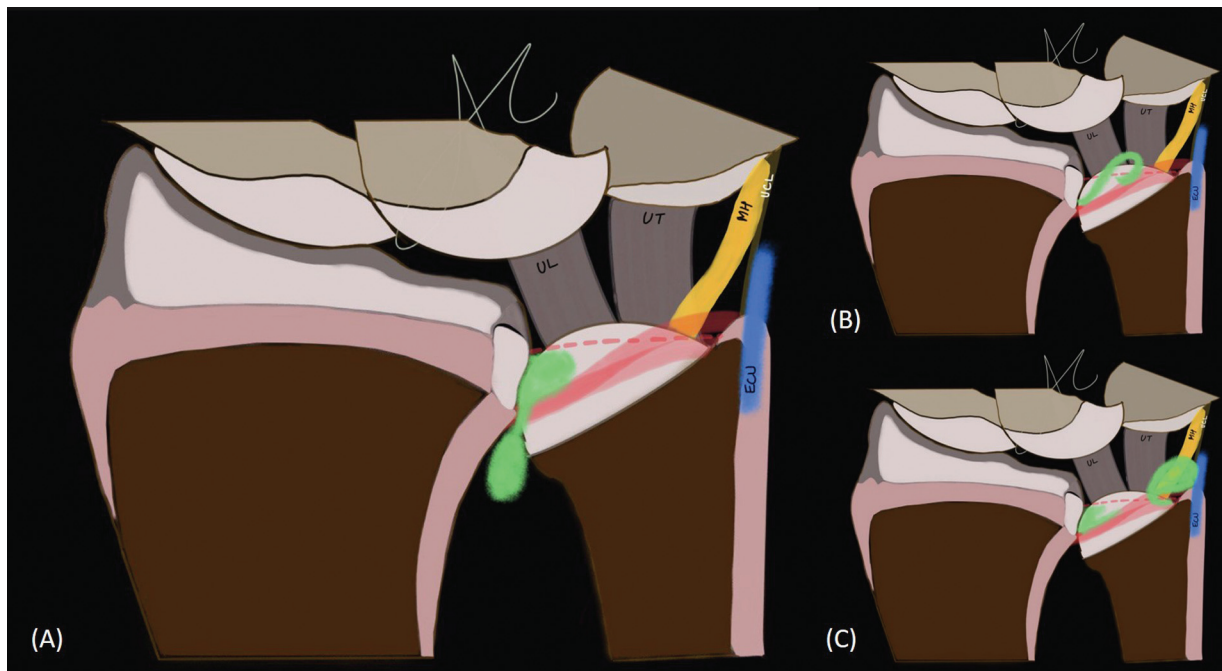


Fig. 2 Diagrammatic representation of the “bucket handle” tear of the central disc of the triangular fibrocartilage complex (TFCC): (A) Index case with the central disc flipped in the distal radioulnar joint (green), radioulnar ligaments with foveal and styloid attachments of the TFC (red), ulnolunate (UL) and ulnотriquetral (UT) ligaments, ulnomeniscal homolog (MH), ulnar collateral ligament (UCL), and the extensor carpi ulnaris subsheath (ECU). (B) Another type of flipped TFCC tear described in the literature with the disc (green) flipped upon itself. (C) The third type of flipped TFCC tear with the torn fragment (green) flipped in the prestyloid recess.

A study by Boutin and Fritz published in 2021³ found the frequency of such “complex” tear anatomies with flipped fragment to be 0.5%. They also described a “comma sign” in which the flipped fragment is connected to the TFCC via a pedicle.

The TFCC and radioulnar ligaments play an important role in stabilization of the DRUJ. Identifying peripheral tears is necessary as they are more amenable to surgical repair. During routine wrist arthroscopy, the DRUJ is a “blind spot.” Displaced TFCC fragments can thus be missed, necessitating identification on MRI for optimal management as flipped fragments can be associated with pain, joint obstruction, mechanical symptoms, reduced supination, and early DRUJ arthrosis.^{3,4}

Conclusion

Complex tears of the TFCC have not been traditionally classified and pose a diagnostic and management challenge. The authors describe a bucket-handle tear of the central disc with the flipped fragment lying in the DRUJ, a rare tear pattern. Preoperative diagnosis is necessary for the surgeon to prepare for DRUJ arthroscopy, and remove and repair the flipped fragment to prevent development of early arthrosis.

Conflict of Interest
None declared.

References

- 1 Palmer AK. Triangular fibrocartilage complex lesions: a classification. *J Hand Surg Am* 1989;14(04):594–606
- 2 Atzei A, Luchetti R. Foveal TFCC tear classification and treatment. *Hand Clin* 2011;27(03):263–272
- 3 Boutin RD, Fritz RC. Displaced flap tears of the triangular fibrocartilage complex: frequency, flap location, and the “Comma” sign on wrist MRI. *AJR Am J Roentgenol* 2021;217(03):707–708
- 4 Jose J, Arizpe A, Barrera CM, Ezuddin NS, Chen D. MRI findings in bucket-handle tears of the triangular fibrocartilage complex. *Skeletal Radiol* 2018;47(03):419–424
- 5 Vezeridis PS, Yoshioka H, Han R, Blazar P. Ulnar-sided wrist pain. Part I: anatomy and physical examination. *Skeletal Radiol* 2010;39(08):733–745
- 6 Sachar K. Ulnar-sided wrist pain: evaluation and treatment of triangular fibrocartilage complex tears, ulnocarpal impaction syndrome, and lunotriquetral ligament tears. *J Hand Surg Am* 2008;33(09):1669–1679
- 7 Tay SC, Tomita K, Berger RA. The “ulnar fovea sign” for defining ulnar wrist pain: an analysis of sensitivity and specificity. *J Hand Surg Am* 2007;32(04):438–444
- 8 Watanabe A, Souza F, Vezeridis PS, Blazar P, Yoshioka H. Ulnar-sided wrist pain. II. Clinical imaging and treatment. *Skeletal Radiol* 2010;39(09):837–857
- 9 Theumann N, Kamel EM, Bollmann C, Sturzenegger M, Becce F. Bucket-handle tear of the triangular fibrocartilage complex: case report of a complex peripheral injury with separation of the distal radioulnar ligaments from the articular disc. *Skeletal Radiol* 2011;40(12):1617–1621
- 10 Meadows M. Displaced Triangular Fibrocartilage Cartilage Complex Tears [Internet]. *Radsourc*. 2022 [cited 2022 Jul 9]. Accessed October 13, 2022 at: <https://radsourc.us/displaced-triangular-fibrocartilage-cartilage-complex-tears/>