

Extraforaminal ligament attachments of the thoracic spinal nerves in humans

G. A. Kraan · P. V. J. M. Hoogland ·
P. I. J. M. Wuisman

Received: 17 July 2008 / Revised: 25 December 2008 / Accepted: 4 January 2009 / Published online: 23 January 2009
© The Author(s) 2009. This article is published with open access at Springerlink.com

Abstract An anatomical study of the extraforaminal attachments of the thoracic spinal nerves was performed using human spinal columns. The objectives of the study are to identify and describe the existence of ligamentous structures at each thoracic level that attach spinal nerves to structures at the extraforaminal region. During the last 120 years, several mechanisms have been described to protect the spinal nerve against traction. All the described structures were located inside the spinal canal proximal to the intervertebral foramen. Ligaments with a comparable function just outside the intervertebral foramen are mentioned ephemerally. No studies are available about ligamentous attachments of thoracic spinal nerves to the spine. Five embalmed human thoracic spines (Th2–Th11) were dissected. Bilaterally, the extraforaminal region was dissected to describe and measure anatomical structures and their relationships with the thoracic spinal nerves. Histology was done at the sites of attachment of the ligaments to the nerves and along the ligaments. The thoracic spinal nerves are attached to the transverse process of the vertebrae cranial and caudal to the intervertebral foramen. The ligaments consist mainly of collagenous fibers. In conclusion, at the thoracic level, direct ligamentous connections exist between extraforaminal thoracic spinal nerves and nearby structures. They may serve as a protective mechanism against traction and compression of the

nerves by positioning the nerve in the intervertebral foramen.

Keywords Spinal nerve · Transforaminal ligaments · Intervertebral foramen · Intercostal neuralgia · Superior costotransverse ligament · Intercostal nerve

Introduction

A considerable amount of research has been undertaken to describe the local anatomy of the intraforaminal and extraforaminal parts of the thoracic spine [2, 4, 5, 10–13, 17, 19, 20]. However, detailed anatomical and histological studies of extraforaminal attachments of thoracic spinal nerves to the spine have not been performed.

Beside injuries of the thoracic spinal nerves because of stab wounds, no lesions of the thoracic spinal nerves by traction are described. Jiang et al. [7] and Ibrahim and Darwish [6] describe extraforaminal ligaments, specifically the superior costotransverse ligaments, but do not mention attachments of the spinal nerve at the location of the superior costotransverse ligaments. On the lumbar level ligamentous, connections between lumbar extraforaminal spinal nerves and the spine are described [9].

Pre-, inter- and extraforaminal structures, such as the ligaments of Trolard [20], Hofmann [5], Spencer [18], suspensor radial ligaments [1, 3] and the denticular ligaments have been regarded as a possible source for neuralgia [10, 11, 17]. However, determining more precisely the underlying cause of the irradiating pain should await detailed anatomical studies of particularly the extraforaminal region.

In order to better understand the role of the ligaments in the biomechanical behaviour in relation to the physiological

G. A. Kraan (✉) · P. I. J. M. Wuisman
Department of Orthopedic Surgery,
VU University Medical Center,
1081 BT Amsterdam, The Netherlands
e-mail: geraldkraan@hotmail.com

G. A. Kraan · P. V. J. M. Hoogland
Department of Anatomy, VU University Medical Center,
Amsterdam, The Netherlands

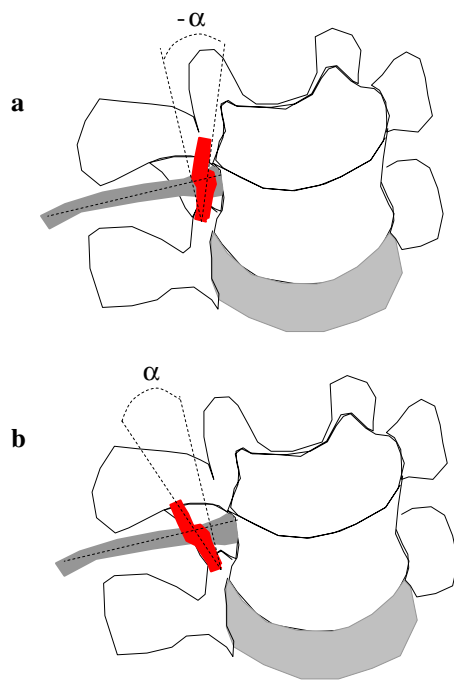


Fig. 1 Antero-lateral view of thoracic vertebra. Measurement of the angle (α) between the nerve and the extraforaminal ligament. **a** A ventrocranial–dorsocaudal direction in relation to the spinal nerve is designated as a negative angle, **b** a ventrocaudal–dorsocranial direction as positive

and pathological loads on the thoracic spinal nerves, detailed knowledge of the extraforaminal anatomy is necessary. The aim of this study is to describe the gross anatomy of the extraforaminal attachments of the thoracic spinal nerves to the tissues surrounding the intervertebral foramina from the 2nd till the 11th thoracic level. The 12th thoracic level is described in a lumbar study [9] and the 1st thoracic level is regarded to be related to the brachial plexus and will therefore be described in a separate study on the cervical part of the spine. In addition, histological studies of the extraforaminal ligaments will be performed.

Materials and methods

Five human bodies, embalmed by vascular perfusion with a medium containing 2.2% formaldehyde, were carefully dissected from the 2nd till the 11th thoracic vertebra. The specimens were carefully selected to exclude bodies with pathological changes of the spine. The age of the specimens ranged from 74 to 92 years; none of the specimens showed any pathology during dissection involving or disrupting the extraforaminal structures. On both sides, the dissection was performed by approaching the intervertebral foramen from the lateral side. All the thoracic spinal nerves were dissected as far back as the intervertebral foramen, carefully preserving all soft tissue attachments.

At all levels, ligamentous structures connected to the spinal nerves were identified, and their origin and insertion and the spatial orientation were determined. At each level, the relationship with the spinal nerve and other surrounding structures of the intervertebral foramina was photographically documented. In addition, length and width of the ligamentous structures were measured with a millimetre calliper. Also, the angle (α) between the ligaments and a line perpendicular to the longitudinal direction of the spinal nerves was measured (see Fig. 1).

We defined a ventrocranial–dorsocaudal direction of the ligament in relation to the spinal as negative (Fig. 1a), a ventrocaudal–dorsocranial direction nerve as negative (Fig. 1a).

Histology

After the measurements and photographic documentation, the ligamentous connections between the extraforaminal spinal nerves and the nearby structures were dissected and fixed in neutral formalin. Consequently, the tissue was embedded in gelatine and cut transversely at 40 μm

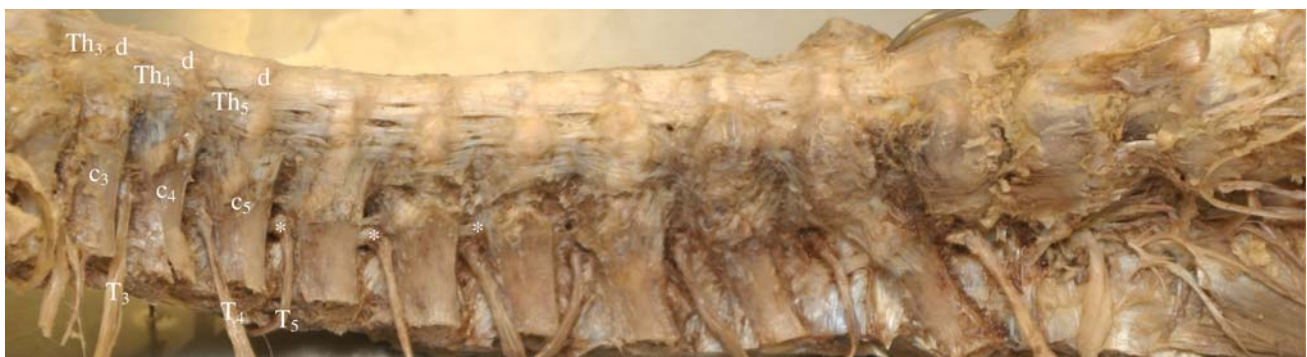

Fig. 2 Right lateral view of the thoracic spine. Dissection of the thoracic spinal nerves as far as the intervertebral foramen preserving soft tissue attachments. Extraforaminal ligament attachments of the

spinal nerves to the transverse process (*). T_3 – T_5 3rd–5th spinal thoracic nerve, d intervertebral disc, c_{3-5} 3rd–5th costa, Th_{3-5} thoracic vertebra 3–5

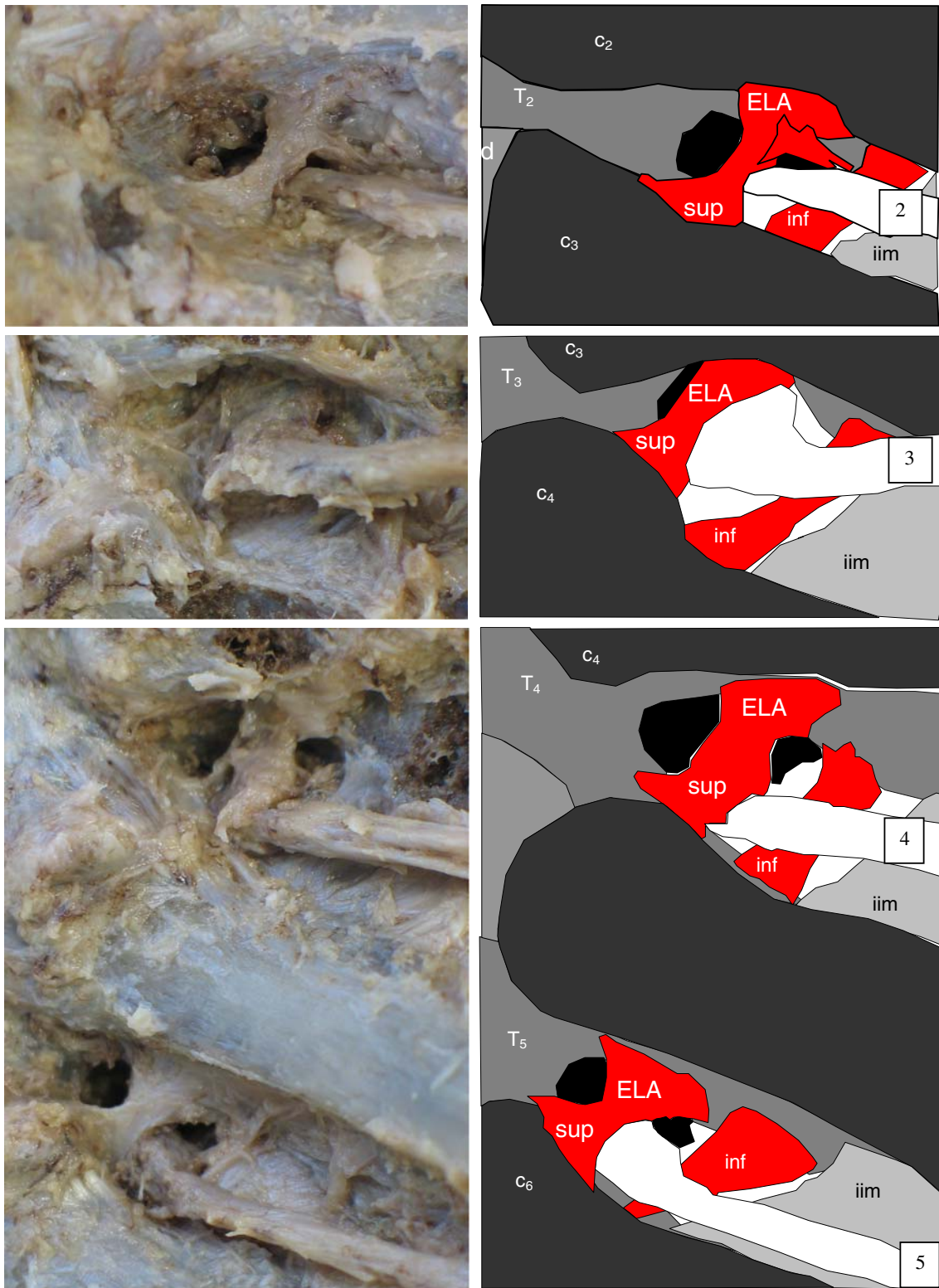


Fig. 3 Left lateral view. Dissection of the 2nd till 11th spinal nerves (2–11) and intervertebral discs (*d*). The extraforaminal ligament attachments (*ELAs*) consist of a superior (*sup*) (the superior costo-transverse ligament) and an inferior part (*inf*). The superior ligaments

pass the spinal nerves laterally; the inferior ligaments are attached dorsally and laterally to the spinal nerves. *T*_{2–11} 2nd till 11th thoracic vertebra, *c*_{2–11} 2nd till 11th costa, *iim* internal intercostal membrane

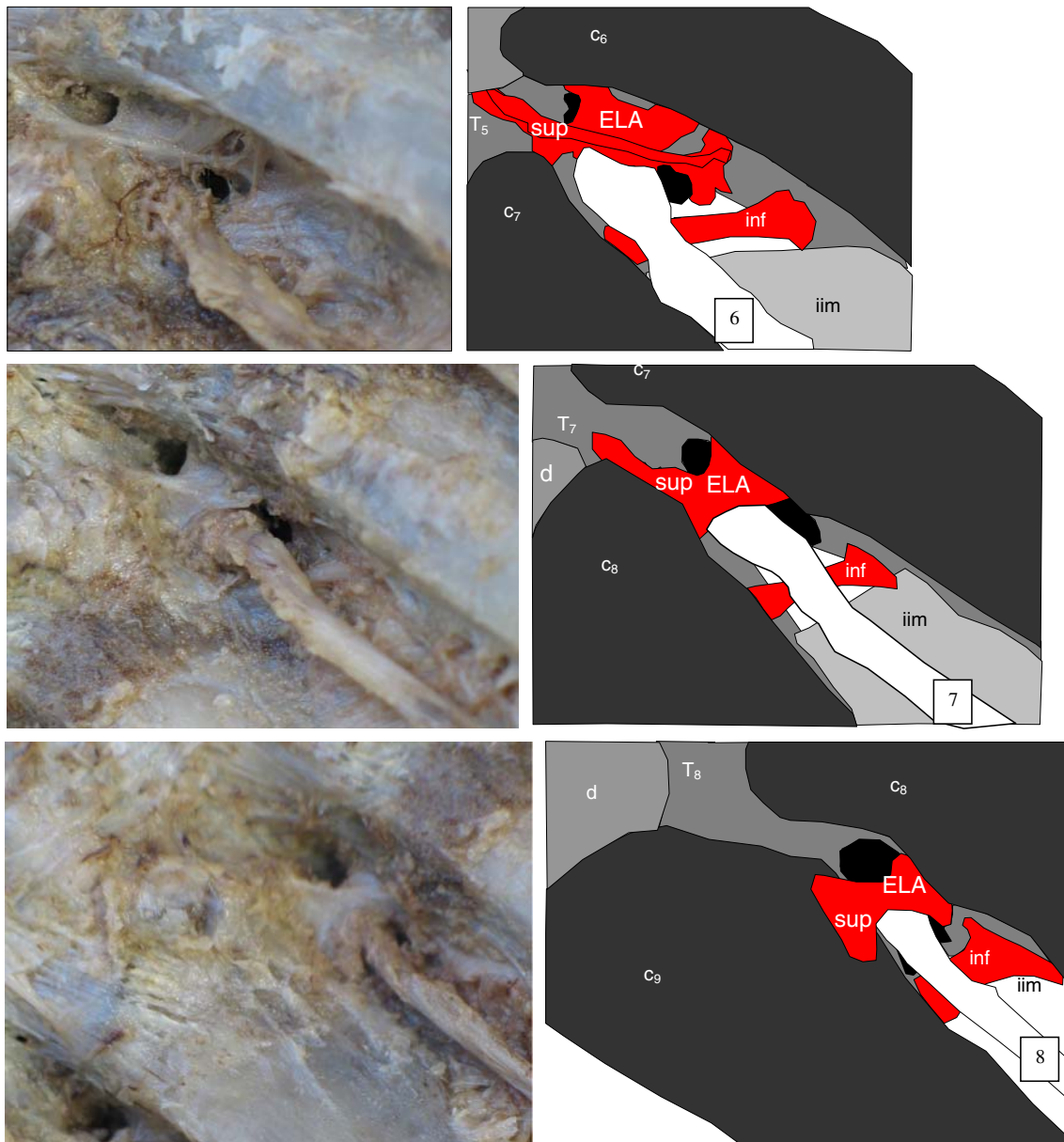


Fig. 3 continued

thickness. After mounting, the sections were stained with hematoxylin–eosin (H&E) and by the Elastica van Gieson method (EVG).

Results

The dissected specimens show extraforaminal attachments of the spinal nerves bilaterally at all thoracic levels. Figures 2, 3, and 4 show characteristic extraforaminal ligamentous networks at the thoracic levels, Th2–Th11. These ligaments consist of a superior and an inferior part. The superior ligaments are identified as the superior

costotransverse ligaments (SC). The inferior ligaments are called the inferior extraforaminal ligament attachments (ELAs). The thoracic spinal nerves are attached to the neighbouring, cranial and caudal, transverse process and to the costovertebral joint capsule by the superior ELAs (Figs. 3, 4). In literature, these ligamentous structures are usually called superior costotransverse ligaments. The inferior ELAs attach the spinal nerves to the superior and inferior transverse process. The orientation of the ligaments is, in general, perpendicular to the thoracic spinal nerves.

These attachments vary at different levels of the thoracic spine. Detailed anatomical description of the individual levels shows the following findings.

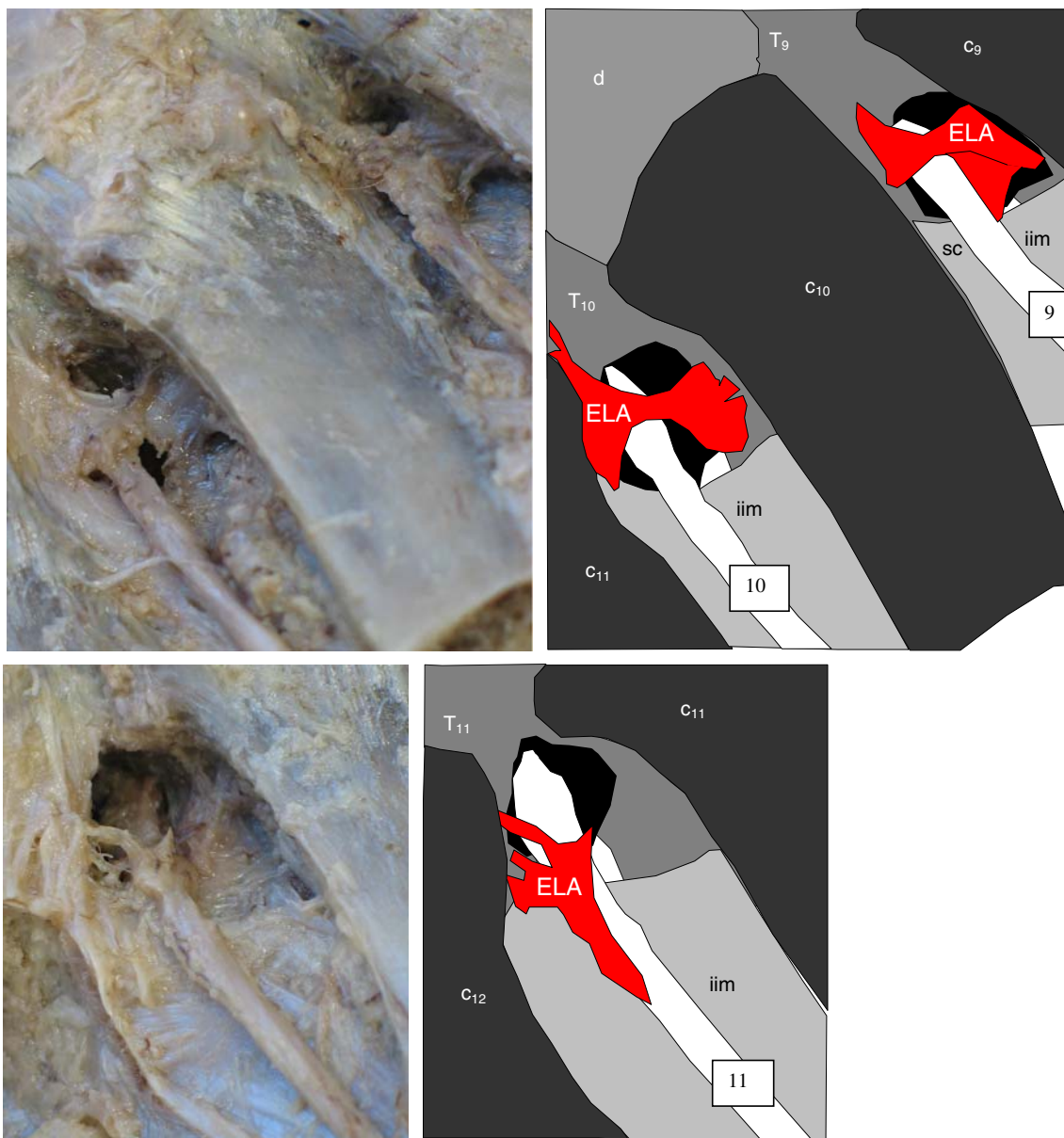


Fig. 3 continued

Thoracic spinal nerves Th2–Th9

Figure 3 shows ELA of the spinal nerve to the articular capsule of the costovertebral joint and the superior and inferior transverse process. From the 2nd till the 9th thoracic level, two ligaments can be identified: a superior and an inferior ligament. The superior ligament originates from the capsule of the costovertebral joint and the cranial transverse process and passes the nerve on its ventral side. It inserts on the capsule of the caudal costovertebral joints and the caudal transverse process. In all specimens, the

inferior ligament originates from the cranial transverse process and inserts on the caudal transverse process always attaching the nerve dorsally.

The spatial orientation of the superior and inferior ligament is from laterocranialdorsal to mediocaudalventral.

From the 2nd till the 9th thoracic spinal nerves, the superior ELAs show variations. These ligaments consist of one, two or three parts (Table 1). However, in one specimen, the most ventral part of the superior ligament on the 6th, 7th and 8th level on the left side is not attached to the spinal nerve (Fig. 4).

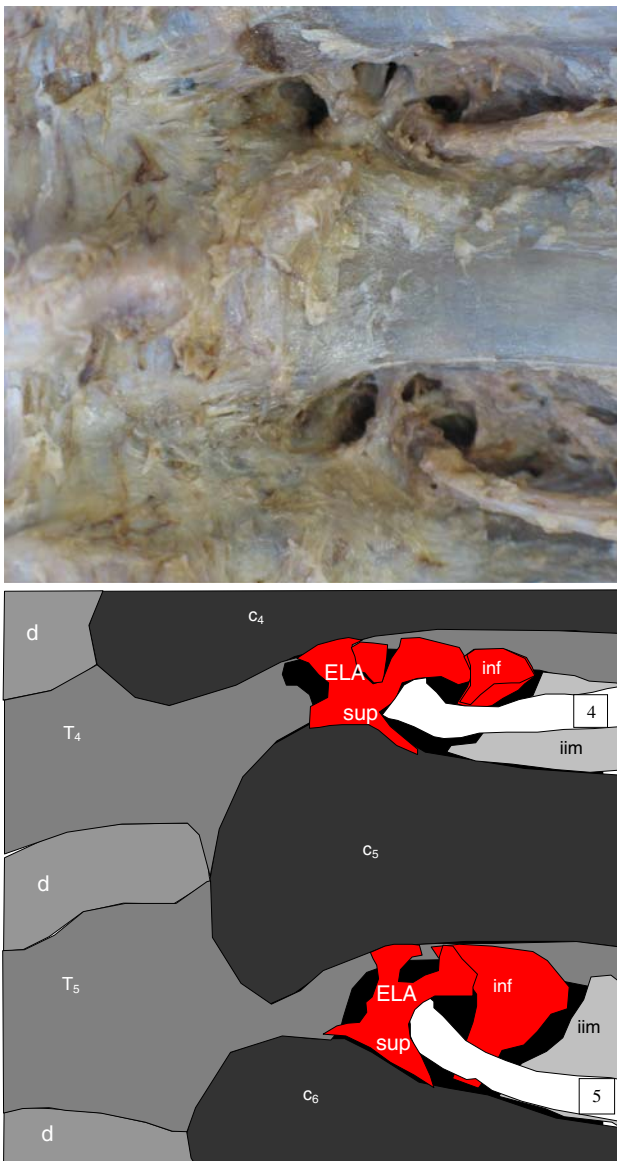


Fig. 4 Left lateral view of dissection of the 4th and 5th thoracic spinal nerves (5, 6) and intervertebral discs (*d*). The superior extraforaminal ligament attachments (*ELAs*) sometimes consist of two or three parts, passing the spinal nerves laterally. *T_{5,6}* 4th and 5th thoracic vertebra, *c_{5,6}* 5th and 6th costa, *iim* internal intercostals membrane

Tenth thoracic spinal nerve (Th10)

Figure 3 shows the ELA of the 10th thoracic spinal nerve to the capsule of the costovertebral joint and cranial and caudal transverse process. In six of the ten sides, a superior and an inferior ligament is seen. The other four of the ten sides have no inferior ligament. The nerve is dorsally attached to the internal intercostal membrane (*iim*).

Table 1 Amount of ligaments on the thoracic levels T2–T11

Level	Superior				Inferior
	1 part	2 parts		3 parts	
		Right	Left		
Th2	9	1			10
Th3	9	1			10
Th4	8	1		1	10
Th5	6	2	2*		10
Th6	7	3			10
Th7	8	2			10
Th8	9				10
Th9	9	1			10
Th10	10				6
Th11	3				9

* Th5 is the only level where two parts on the left side were seen. All the other two and three parts were right sided

Eleventh thoracic spinal nerve (Th11)

The 11th thoracic spinal nerve is caudally attached to the capsule of the costovertebral joint and the intervertebral foramen and dorsally to the *iim* (Fig. 3). These ligaments are attached to the nerve caudally and laterally along the entire width of the spinal nerve.

Table 1 shows the variations in amount of ligaments on the thoracic level from the 2nd till the 11th thoracic level.

Table 2 shows length and width of the ELAs and the angle between the extraforaminal ligament and the spinal nerve. In all specimens, from the 2nd till 9th thoracic level, the superior and inferior ligaments run from craniolateral to caudomedial forming a positive angle (Fig. 1).

Histology

At all thoracic levels in all specimens, the connections between the extraforaminal part of the spinal nerves and nearby structures consist of collagen fibers (Fig. 5). These collagen fibers are parallel orientated and attached to the epineurium of the nerve.

In addition, these ligaments seem to contain some elastine as can be seen in Elastica van Gieson staining. No major histological differences were seen at the various thoracic levels.

Discussion

The present study describes and specifies the anatomy of not yet described extraforaminal ligamentous attachments of the thoracic spinal nerves in the extraforaminal region.

Table 2 Levels Th2–Th11: length, width and depth in mm and angle (°) of the extraforaminal ligament attachment of the spinal thoracic nerves to the thoracic transverse processes ($n = 10$)

Level	Ligament	Length (mm)	Width (mm)	Depth (mm)	Angle (°)
Th2	Superior 1	11.9 (6.1)	7.4 (4.8)	1.4 (1.0)	15.04 (22.3)
	Superior 2	11.8 (–)	5.3 (–)	0.3 (–)	80 (–)
	Inferior	13.3 (7.0)	7.5 (6.7)	1.0 (0.7)	34.6 (15.1)
Th3	Superior 1	12.3 (7.0)	7.7 (5.5)	1.1 (1.0)	11.0 (19.8)
	Superior 2	7.1 (–)	2.6 (–)	1.2 (–)	0 (–)
	Inferior	12.9 (7.0)	8.7 (8.5)	1.6 (1.0)	13.3 (19.3)
Th4	Superior 1	11.6 (3.8)	7.8 (5.5)	1.4 (0.7)	10.8 (14.9)
	Superior 2	12.0 (–)	7.0 (–)	2.0 (–)	10 (–)
	Superior 3	15.0 (–)	15.1 (–)	4.2 (–)	60 (–)
	Inferior	13.9 (7.5)	10.5 (7.3)	1.5 (0.9)	27.8 (15.7)
Th5	Superior 1	11.0 (4.1)	7.5 (5.9)	1.5 (1.1)	15.5 (31.7)
	Superior 2	12.8 (4.9)	7.4 (3.5)	1.2 (1.0)	35.2 (25.4)
	Inferior	15.8 (11.7)	9.2 (6.5)	1.3 (0.9)	29.7 (19.6)
Th6	Superior 1	10.6 (3.0)	8.5 (6.0)	1.5 (0.8)	23.6 (24.6)
	Superior 2	9.1 (3.8)	6.0 (4.3)	0.8 (0.6)	21.7 (6.5)
	Inferior	13.4 (6.4)	9.9 (5.7)	1.3 (0.9)	32.8 (18.2)
Th7	Superior 1	11.1 (4.9)	8.1 (5.5)	1.6 (0.6)	18.7 (8.6)
	Superior 2	12.6 (6.3)	4.3 (3.9)	0.4 (0.6)	19.9 (0.15)
	Inferior	12.0 (7.0)	7.0 (4.6)	1.8 (1.4)	33.3 (21.0)
Th8	Superior 1	12.5 (4.8)	8.3 (4.7)	2.1 (1.6)	22.3 (16.6)
	Inferior	14.1 (7.1)	10.8 (6.6)	1.6 (0.6)	34.7 (19.3)
Th9	Superior 1	13.8 (7.0)	8.7 (5.2)	1.1 (0.6)	22.5 (27.0)
	Superior 2	10.0 (–)	1.7 (–)	0.6 (–)	21.9 (–)
	Inferior	16.8 (9.3)	10.1 (7.5)	1.9 (1.0)	32.3 (24.6)
Th10	Superior	11.0 (2.9)	5.6 (2.5)	1.9 (1.7)	–8.6 (41.6)
	Inferior	15.4 (10.1)	8.6 (7.2)	5.2 (5.0)	31.6 (68)
Th11	Superior	21.6 (20.6)	7.0 (4.2)	1.75 (0.3)	52.5 (10.6)
	Inferior	6.7 (1.2)	2.8 (0.4)	0.8 (0.5)	70.6 (3.0)

Values are means and standard deviation (SD)

From the 2nd till the 9th thoracic level, the ELAs consist of a superior and an inferior part. The superior ELA originates from the costovertebral joint and the superior transverse process. It inserts on the inferior transverse process. The superior part is identified as the superior costotransverse ligament. This ligament is ventrally attached to the spinal nerves. The inferior ligament attaches the nerve dorsally and originates and inserts on, respectively, the superior and inferior transverse process. In literature, no such ligament has been described.

All the superior and inferior ligaments have a laterocranialdorsal mediocaudalventral orientation in relation to the spinal nerves. On the 10th and 11th levels, we see the same attachments to the thoracic spinal nerves.

A review of different anatomic textbooks [1, 8, 14–16] provided several descriptions of transforaminal

ligaments. Rickenbacher et al. [15] and Reulen [14] describe a topographic relation of the spinal nerve and the superior costotransverse ligament. In contradiction with our findings, they draw the spinal nerve ventrally to the superior costotransverse ligaments. We found a dorsal position of the spinal nerve in all the ten measurements. Beside that, they do not mention connections between these two structures, which we found in all the specimens.

Jiang et al. [7] described the superior costotransverse ligaments as a tendon, woven or membranous-like ligaments. The superior costotransverse ligaments in our study are more like the described ligaments by Ibrahim and Darwish [6], existing of two parts. Although previous studies, by Jiang et al. and Ibrahim and Darwish, describe the anatomy of the extraforaminal region on the thoracic level to the best of our knowledge, these studies do not mention the attachments of ligaments to the spinal nerves.

A comparable situation of ELAs to spinal nerves was seen at lumbar levels [9]. In this study, it was shown that at lumbar levels the spinal nerves were attached by extraforaminal ligaments to the intervertebral foramen and its surroundings.

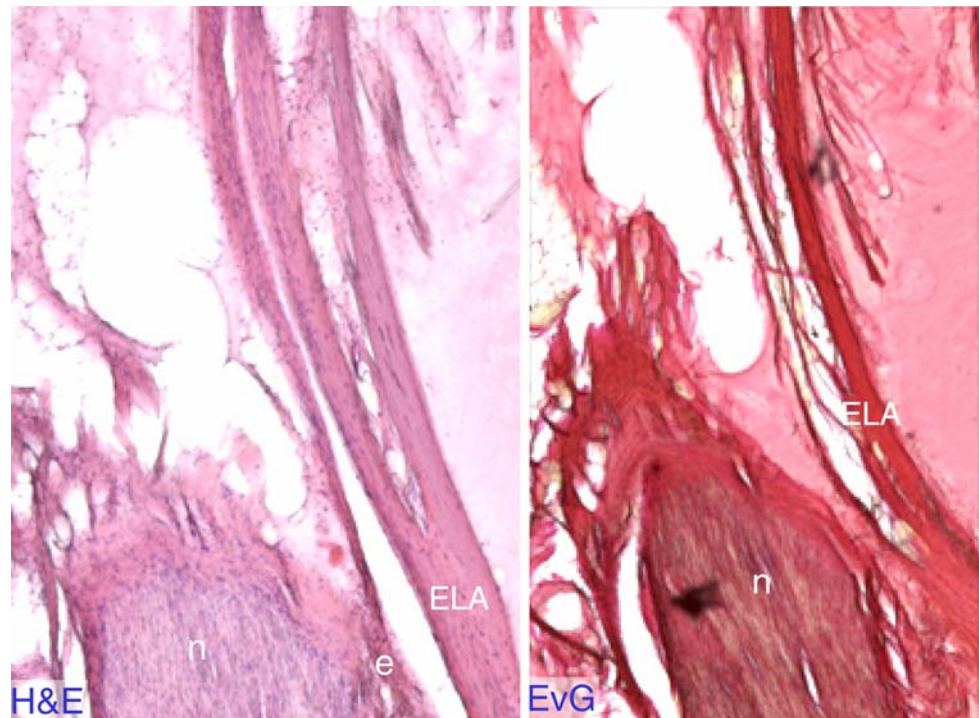
The features of the ELAs at the thoracic levels correspond to the 12th thoracic and the 1st lumbar levels. At these levels, the extraforaminal ligaments connect the spinal nerves to the intervertebral foramen and disc [9]. These ligaments cross the spinal nerves ventrally and are perpendicularly orientated to the spinal nerves. We hypothesize that the mechanical function of these ligaments appears to be the same. The present findings on the ELAs of the thoracic spinal nerves are relevant for answering the question whether thoracic spinal nerves are subjected to compression and traction.

Jiang et al. [7] described the superior costotransverse ligament as perhaps the most important ligament for active lateral balancing of the spine. But they did not describe a relation to the spinal nerves. We assume that the most important function of these superior and inferior extraforaminal ligaments is prevention of spinal nerve compression against the superior and inferior transverse process and not balancing the spine.

In literature, protection of the peripheral nerves against nerve traction damage by pre-, inter- and extraforaminal structures such as the ligaments of Trolard [20], Hofmann [5], Spencer [18], suspensor radial ligaments [1, 3] and the denticular ligaments has been described.

When moving the thoracic spinal nerve in craniocaudal direction, the ELAs protect the thoracic nerves of being pushed against the bony superior and inferior transverse process and the superior and inferior costae. Based on the results of the present study, the following assumption can

Fig. 5 Forty-micrometre thick coupes of transverse section of the thoracic spinal nerve (*n*). Staining with hematoxylin–eosin (*H&E*) and elastica van Gieson (*EvG*). The extraforaminal ligament attachments (*ELAs*) consist of parallel-orientated collagen fibers and are attached to the outer parts (epineurium, *e*) of the nerve tissues



be formulated: the superior and inferior ELAs of the levels Th2–Th10 are important for craniocaudal positioning of the thoracic spinal nerve rather than protecting the nerve against traction damage.

In this study, we used a limited number of fixated bodies of old aged people. Since fixation can cause shrinkage of anatomical structures, the measurements may be influenced by the fixation process. We thus must be aware of the fact that fixation and age-related degeneration might have influenced the size of the ligaments.

At present, interpretation of these findings with respect to back pain and neuralgia is speculative. The described ligaments seem to protect against noxious stimuli rather than being the cause of any form of neuralgia.

Currently, we are focusing on the anatomy of extraforaminal ligaments at cervical levels, biomechanical analysis of the extraforaminal ligament, and further histological studies with respect to innervation of these ligaments. For these histological studies, we will use specific neuro-immunohistochemical staining.

In conclusion, the extraforaminal ligamentous attachments described in this study connect the thoracic spinal nerve to the surroundings of the intervertebral foramen. The direction of these ligaments suggests that in the thoracic region the ligamentous fixation of the spinal nerves serves an optimal positioning of the nerve rather than a protection against pulling forces.

Acknowledgments We thank F. Sommers, E. Norbart and D. de Jong (VU university medical center Amsterdam) and P. Pilot (Reinier de Graaf Groep, Delft) for their valuable advice and technical support.

Open Access This article is distributed under the terms of the Creative Commons Attribution Noncommercial License which permits any noncommercial use, distribution, and reproduction in any medium, provided the original author(s) and source are credited.

References

1. Akdemir G et al (1999) Microanatomy of thoracic spine foramina and ligaments. In: Dickman CA, Rosenthal NIP (eds) Thoracoscopic spine surgery. Thieme, New York, pp 69–78
2. Baldwin WM (1908) The topography of spinal nerve roots. *Anat Rec* 2:155–156
3. Berry JL (1987) A morphometric study of human lumbar and selected thoracic vertebrae. *Spine* 12(4):362–367. doi:10.1097/00007632-198705000-00010
4. Frykholm R (1951) Lower cervical nerve roots and their investments. *Acta Chir Scand* 101(6):457–471
5. Hofmann M (1898) Die befestigung der dura mater im wirbelcanal. *Arch Anat Physiol (Anat Abt)*:403–410
6. Ibrahim AF, Darwish HH (2005) The costotransverse ligaments in human: a detailed anatomical study. *Clin Anat* 18(5):340–345. doi:10.1002/ca.20102
7. Jiang H et al (1994) Quantitative morphology of the lateral ligaments of the spine. Assessment of their importance in maintaining lateral stability. *Spine* 19(23):2676–2682
8. Johnson D et al (2005) Chest wall. In: Standring S et al (eds) Gray's anatomy, 39th edn. Elsevier, Edinburgh, pp 959–960
9. Kraan GA et al (2005) Extraforaminal ligament attachments of human lumbar nerves. *Spine* 30(6):601–605. doi:10.1097/01.brs.0000155403.85582.39
10. Louis R (1981) Vertebro-radicular and vertebromedullar dynamics. *Anat Clin* 3:1–11. doi:10.1007/BF01557969
11. Melvill RL, Baxter BL (1994) The intertransverse approach to extraforaminal disc protrusion in the lumbar spine. *Spine* 19(23):2707–2714

12. Nathan H, Feuerstein M (1970) Angulated course of spinal nerve roots. *J Neurosurg* 32(3):349–352
13. Reid JD (1958) Ascending nerve roots and tightness of dura mater. *N Z Med J* 57(317):16–26
14. Reulen HJ (1991) Neurochirurgische Operationen. In: Bauer R, Kerschbaumer F, Poisel S (eds) *Orthopädische Operationslehre*. Georg Thieme Verlag Stuttgart, New York, p 318
15. Rickenbacher J, Landolt AM, Theiler K (2004). In: Rickenbacher J, Landolt AM, and Theiler K (eds) *Lanz/Wachsmuth Praktische Anatomie: Rücken*. Ein Lehr- und Hilfsbuch der anatomischen Grundlagen ärztlichen Handelns. Springer, New York, pp 40–41
16. Rohen JW, Yokochi C (1983) *Human anatomy: photographic atlas of systematic and regional anatomy/head, neck, trunk*. Schattauer, Stuttgart, p 159
17. Rydevik B, Brown MD, Lundborg G (1984) Pathoanatomy and pathophysiology of nerve root compression. *Spine* 9(1):7–15. doi: [10.1097/00007632-198401000-00004](https://doi.org/10.1097/00007632-198401000-00004)
18. Spencer DJ, Irwin GS, Miller JAA (1983) Anatomy and significance of function of the lumbosacral nerve roots in sciatica. *Spine* 8(6):672–679. doi: [10.1097/00007632-198309000-00014](https://doi.org/10.1097/00007632-198309000-00014)
19. Sunderland S (1974) Meningeal–neural relations in the intervertebral foramen. *J Neurosurg* 40(6):756–763
20. Trolard P (1888) Recherches sur l’anatomie des méninges spinales et du filum terminale dans le canal sacré. *Arch Physiol* 2:191–199