

Case Report

Thrombotic microangiopathy associated with sunitinib, a VEGF inhibitor, in a patient with factor V Leiden mutation

Seth A. Levey¹, Randeep S. Bajwa¹, Maria M. Picken², Joseph I. Clark¹, Kevin Barton¹ and David J. Leehey¹

¹Department of Medicine and ²Department of Pathology, Loyola University Medical Center, Maywood, IL 60153, USA and Veterans Affairs Hospital, Hines, IL 60141, USA

Keywords: Factor V Leiden; sunitinib; thrombotic microangiopathy; VEGF inhibitors

Haemolytic uraemic syndrome (HUS) and thrombotic thrombocytopenic purpura (TTP) are closely related disorders characterised by non-immune microangiopathic haemolytic anaemia and thrombocytopenia. Thrombotic microangiopathy is the underlying pathologic lesion in both syndromes. Under physiological conditions, platelets bind to endothelium via von Willebrand Factor (vWF) and are released back into the circulation by ADAMTS13, a metalloprotease that cleaves ultra-large, newly synthesized vWF multimers. A deficiency of ADAMTS13 (due to either a decrease in its production or the presence of a circulating inhibitor) may thus result in microvascular thrombi. However, patients with thrombotic microangiopathy may have normal ADAMTS13 levels and no evidence of a circulating inhibitor [1].

Sunitinib malate, an oral multi-targeted tyrosine kinase inhibitor that blocks the receptors for VEGF, has utility in a variety of metastatic tumours [2]. We report a patient who developed proteinuria, hypertension and biopsy-proven thrombotic microangiopathy after treatment with sunitinib malate. This patient had normal ADAMTS13 levels but had factor V Leiden mutation that may have predisposed her to this complication.

Case report

A 57-year-old female with metastatic renal-cell carcinoma began treatment with sunitinib (Sutent [SU11248]; Pfizer) 50 mg/day from January 2006 after failing cytokine therapy with interleukin-2. She had undergone left nephrectomy 2 years previously. Her past medical history included stage III chronic kidney disease, stage I hypertension, Factor V Leiden mutation, history of deep venous thrombosis

32 years earlier and hypothyroidism. Two weeks after starting sunitinib therapy, her haemoglobin decreased from 123 g/L to 117 g/L and the platelet count decreased from $246 \times 10^9/L$ to $63 \times 10^9/L$. She was admitted with complaints of fatigue, anorexia, mild nausea/vomiting and decreased urine output. On exam, she was afebrile and hypertensive (206/114 mmHg). She had 1+ bilateral lower extremity oedema, but otherwise the examination was unremarkable. Laboratory findings on presentation were remarkable for elevated serum urea nitrogen and creatinine, 18.9 mmol/L and 366 $\mu\text{mol/L}$, respectively, marked thrombocytopenia, $36 \times 10^9/L$, and worsening anaemia, 111 g/L. Coagulation tests were normal. Haemolytic anaemia was confirmed by low serum haptoglobin, <0.1 g/L, elevated serum lactate dehydrogenase, 736 IU/L, and schistocytes on blood smear. The Coombs test was negative. Fibrin split products were elevated, 80 $\mu\text{g/ml}$. Urinalysis showed 3+ proteinuria with 86 red blood cells, 8 white blood cells, 3 granular casts and no red blood cell casts per high power field. The protein to creatinine ratio in a random urine sample was 15 mg/mg. Prior urinalyses had showed trace of 1+ proteinuria, without quantification. Serologic testing for glomerular disease was unrevealing. ADAMTS13 levels were normal and no inhibitor was present.

Sunitinib was discontinued immediately and she was treated with prednisone and daily plasma exchange over the next 7 days. Her anaemia and thrombocytopenia resolved and serum creatinine slowly decreased to near baseline. Transjugular kidney biopsy performed after normalisation of the platelet count showed several glomeruli with fragmented red blood cells within the mesangial areas. There was also thickening of the glomerular capillary wall with a double contour appearance (Figure 1). Pathology from the original nephrectomy showed normal renal parenchyma in non-neoplastic tissue.

Discussion

There is increasing evidence that VEGF inhibitors could cause or at least predispose to thrombotic microangiopathy. For example, administration of anti-VEGF antibodies to

Correspondence and offprint requests to: David J. Leehey, Loyola University Medical Center, Bldg 102, Rm. 3661, 2160 S., 1st Avenue, Maywood, IL 60153, USA. Tel: +1-708-2163-306; Fax: +1-708-2164-060; E-mail: dleehey@lumc.edu

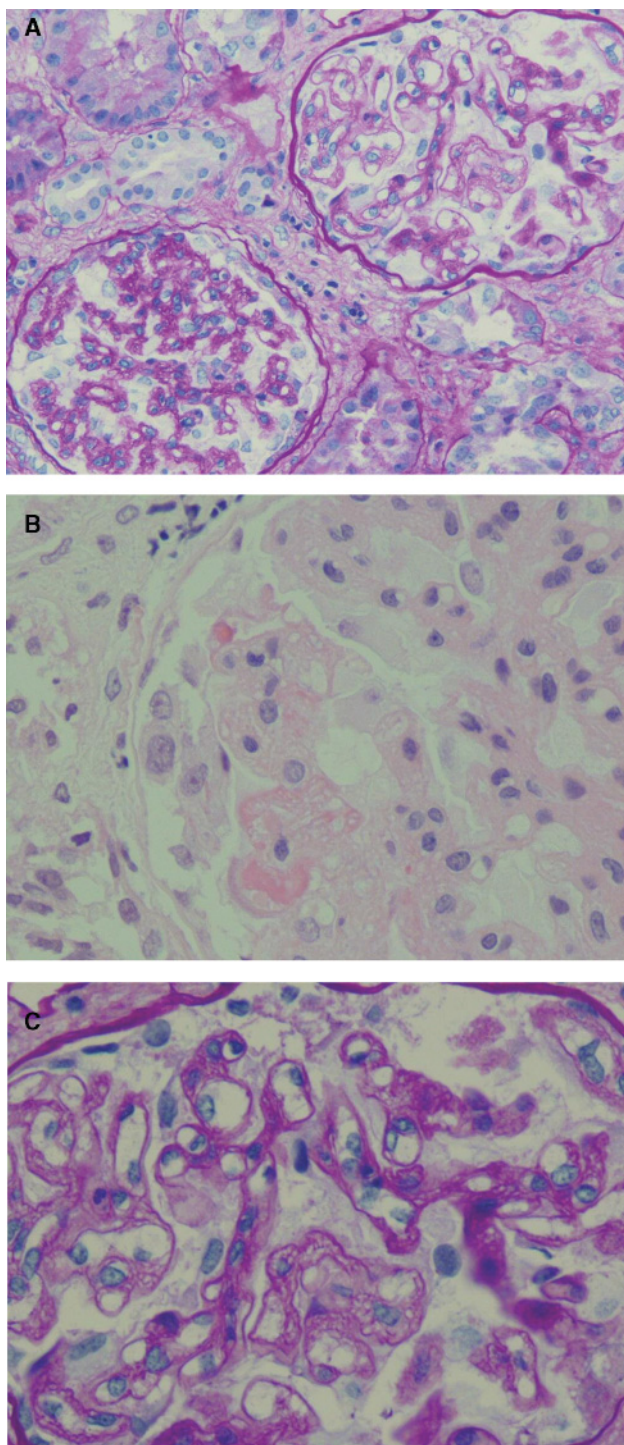


Fig. 1. (A) Kidney biopsy with two glomeruli: one showing advanced tuft collapse (left lower corner) and the other with capillaries showing a double contour appearance. PAS stain, magnification 200 \times . (B and C) Segment of a glomerulus with thickened, double-contoured capillaries and increased mesangial matrix with entrapped fragmented red blood cells. H & E (B) and PAS stain (C), magnification 400 \times .

animals has been shown to cause proteinuria associated with detachment of glomerular endothelial cells and downregulation of nephrin [3]. VEGF promotes repair of glomerular endothelium in experimental thrombotic microangiopathy [4], and elevated serum levels of VEGF were noted in patients 2 to 3 weeks after the onset of thrombotic microangiopathy, suggesting a reactive increase in VEGF in an attempt to repair glomerular endothelial damage [5]. A naturally circulating soluble form of the VEGF receptor, sFlt-1, binds VEGF in the circulation and acts as an antagonist. Upregulation of sFlt-1 is a characteristic of pre-eclampsia and administration of sFlt-1 to pregnant rats can induce hypertension, proteinuria and endotheliosis [6]. Thus VEGF inhibition may be the common mechanism in both patients receiving VEGF antagonists and patients with severe pre-eclampsia that results in endothelial cell injury and predisposes to thrombotic microangiopathy.

Adverse effects of VEGF inhibitors reported in clinical trials have included hypertension, proteinuria, anaemia, neutropenia and thrombocytopenia [2]. An increased incidence of thrombosis also occurs after VEGF inhibition, which is probably due to impairment of vascular integrity due to diminished regenerative capacity of endothelial cells and exposure of pro-coagulant phospholipids on the luminal plasma membrane or underlying matrix [7]. VEGF increases production of nitric oxide and prostaglandin I₂; reduction in these substances after inhibition of VEGF signaling may predispose to thrombosis [7]. VEGF inhibition may also increase erythropoietin production, resulting in an increase in haematocrit and blood viscosity [7].

Thrombotic microangiopathy occurring in single patient treated with bevacizumab [8], sunitinib [9], VEGF trap treatment [10] and sequential bevacizumab and sunitinib [11] has been very recently reported. However, an unanswered question is what predisposes only certain patients to this severe complication of VEGF inhibition.

Our patient had a history of factor V Leiden with prior deep venous thrombosis. This hypercoagulable state, in light of endothelial injury due to sunitinib-induced VEGF inhibition, may have predisposed her to thrombotic microangiopathy. This theory is supported by a recent study involving 30 patients with thrombotic microangiopathy and normal ADAMTS13 activity, in whom 4 (13%) were found to have factor V Leiden mutation, whereas only 3% of control subjects (6/186) possessed the mutation [12].

Although such data provide a plausible hypothesis as to why our patient developed this complication, it should be noted that factor V Leiden is generally associated with venous rather than microvascular thrombosis, whereas anti-VEGF agents (as well as other antiangiogenic agents) have been more commonly associated with arterial and microvascular thrombosis [13]. Moreover, the association between factor V Leiden and thrombotic microangiopathy has been recently questioned [14]. Thus it remains unclear as to whether or not factor V Leiden will prove to be a predisposing factor for thrombotic complications of anti-VEGF agents. At our present state of knowledge, the presence of Factor V Leiden should not be considered a contraindication to the use of an anti-VEGF agent.

Conflict of interest statement. The results presented in this paper have not been published previously in whole or in part, except in abstract form. Dr. Clark is a member of the Speakers' Bureau for Pfizer, makers of Sutent (sunitinib).

References

1. George JN. Thrombotic thrombocytopenic purpura. *N Engl J Med* 2006; 354: 1927–1935
2. Faivre S, Delbado C, Vera K *et al.* Safety, pharmacokinetic, and antitumor activity of SU11248, a novel oral multitarget tyrosine kinase inhibitor, in patients with cancer. *J Clin Oncol* 2005; 24: 25–35
3. Sugimoto H, Hamano Y, Charytan D *et al.* Neutralization of circulating vascular endothelial growth factor (VEGF) by anti-VEGF antibodies and soluble VEGF receptor 1 (sFlt-1) induces proteinuria. *J Biol Chem* 2003; 278: 12605–12608
4. Kim YG, Suga SI, Kang DH *et al.* Vascular endothelial growth factor accelerates renal recovery in experimental thrombotic microangiopathy. *Kidney Int* 2000; 58: 2390–2399
5. Maroeska TLD, Bosma N, Van Hinsbergh V *et al.* Elevated levels of vascular endothelial growth factor in serum of patients with D+ HUS. *Pediatr Nephrol* 2004; 19: 754–760
6. Maynard SE, Min JY, Merchan J *et al.* Excess placental soluble fms-like tyrosine kinase (sFlt1) may contribute to endothelial dysfunction, hypertension, and proteinuria in preeclampsia. *J Clin Invest* 2003; 111: 600–602
7. Kamba T, McDonald DM. Mechanisms of adverse effects of anti-VEGF therapy for cancer. *Br J Cancer* 2007; 96: 1788–1795
8. Roncone D, Satoskar A, Nadasdy T *et al.* Proteinuria in a patient receiving anti-VEGF therapy for metastatic renal cell carcinoma. *Nat Clin Pract Nephrol* 2007; 3: 287–293
9. Kapiteijn E, Brand A, Kroep J *et al.* Sunitinib induced hypertension, thrombotic microangiopathy and reversible posterior leukoencephalopathy syndrome. *Ann Oncol* 2007; 18: 1745–1747
10. Izzedine H, Brocheriou I, Deray G *et al.* Thrombotic microangiopathy and anti-VEGF agents. *Nephrol Dial Transplant* 2007; 22: 1481–1482
11. Frangie C, Lefaucheur C, Medioni J *et al.* Renal thrombotic microangiopathy caused by anti-VEGF-antibody treatment for metastatic renal-cell carcinoma. *Lancet Oncol* 2007; 8: 177–178
12. Raife TJ, Lentz SR, Atkinson BS *et al.* Factor V Leiden: a genetic risk factor for thrombotic microangiopathy in patients with normal von Willebrand factor-cleaving protease activity. *Blood* 2002; 99: 437–442
13. Scappaticci FA, Skillings JR, Holden SN *et al.* Arterial thromboembolic events in patients with metastatic carcinoma treated with chemotherapy and bevacizumab. *JNCI* 2007; 99: 1232–1239
14. Krieg S, Studt JD, Sulzer I *et al.* Is factor V Leiden a risk factor for thrombotic microangiopathies without severe ADAMTS 13 deficiency? *Thromb Haemost* 2005; 94: 1186–1189

Received for publication: 28.10.07

Accepted in revised form: 23.1.08