

## Pathogenesis of Focal Segmental Glomerulosclerosis

Beom Jin Lim · Jae Won Yang<sup>1</sup>  
Woo Sung Do · Agnes B. Fogo<sup>2</sup>

Department of Pathology, Yonsei University College of Medicine, Seoul; <sup>1</sup>Department of Nephrology, Yonsei University Wonju College of Medicine, Wonju, Korea; <sup>2</sup>Department of Pathology, Microbiology and Immunology, Vanderbilt University Medical Center, Nashville, TN, USA

Received: August 23, 2016  
Accepted: September 21, 2016

### Corresponding Author

Agnes B. Fogo, MD  
MCN C3310, Department of Pathology,  
Microbiology and Immunology, Vanderbilt University  
Medical Center, Nashville, TN 37232, USA  
Tel: +1-615-322-3114  
Fax: +1-615-343-7023  
E-mail: agnes.fogo@vanderbilt.edu

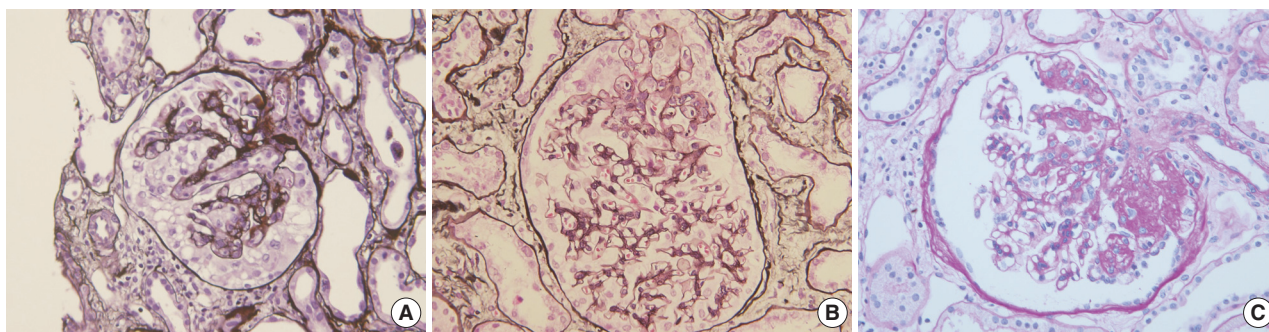
Focal segmental glomerulosclerosis (FSGS) is characterized by focal and segmental obliteration of glomerular capillary tufts with increased matrix. FSGS is classified as collapsing, tip, cellular, perihilar and not otherwise specified variants according to the location and character of the sclerotic lesion. Primary or idiopathic FSGS is considered to be related to podocyte injury, and the pathogenesis of podocyte injury has been actively investigated. Several circulating factors affecting podocyte permeability barrier have been proposed, but not proven to cause FSGS. FSGS may also be caused by genetic alterations. These genes are mainly those regulating slit diaphragm structure, actin cytoskeleton of podocytes, and foot process structure. The mode of inheritance and age of onset are different according to the gene involved. Recently, the role of parietal epithelial cells (PECs) has been highlighted. Podocytes and PECs have common mesenchymal progenitors, therefore, PECs could be a source of podocyte repopulation after podocyte injury. Activated PECs migrate along adhesion to the glomerular tuft and may also contribute to the progression of sclerosis. Markers of activated PECs, including CD44, could be used to distinguish FSGS from minimal change disease. The pathogenesis of FSGS is very complex; however, understanding basic mechanisms of podocyte injury is important not only for basic research, but also for daily diagnostic pathology practice.

**Key Words:** Focal segmental glomerulosclerosis; Podocytopathy; Permeability factors; Parietal epithelial cells

Focal segmental glomerulosclerosis (FSGS) typically presents with nephrotic range proteinuria and, as its name implies, shows obliteration or collapse of glomerular capillary loops by increased extracellular matrix in some glomeruli only, and the capillary injury does not occupy the entire glomerulus involved. In primary FSGS, direct podocyte injury is postulated to result in sclerosis. Though morphologically similar, secondary FSGS develops due to varying injuries, conditions such as obesity, renal mass reduction, drug toxicity, viral infection, familial genetic background, hypertension-related injury, chronic pyelonephritis, or healing of pauciimmune necrotizing crescentic injury.

FSGS has heterogeneous morphology (Fig. 1). Several attempts have been made to classify FSGS according to the pattern and intraglomerular distribution of sclerotic lesions. The Columbia Classification proposed in 2004 divides FSGS into collapsing, tip, cellular, perihilar, and not otherwise specified (NOS) variants.<sup>1</sup> In collapsing variant of FSGS, glomerular capillary collapse accompanied by podocyte hypertrophy and hyperplasia is observed in at least one glomerulus. The presence of other variants in the remaining glomeruli does not alter the diagnosis. This variant has been characterized by its aggressive behavior.<sup>2</sup> While collapsing

FSGS is a histologic feature of human immunodeficiency virus-associated nephropathy (HIVAN), it has also been related to various conditions such as other viral infection (parvovirus B19<sup>3</sup>) and drugs (pamidronate,<sup>4</sup> interferons,<sup>5</sup> and anthracyclin<sup>6</sup>), or it can be idiopathic.<sup>7</sup> The tip variant means that the segmental lesion involves the outer 25% of the glomerular tuft next to the tubular pole, i.e., tip portion, in the absence of collapsing or perihilar lesions.<sup>1</sup> Tip variant has a favorable prognosis and good response to therapy in most series.<sup>8</sup> However, contrary reports have also been published.<sup>9</sup> In the cellular variant, at least one glomerulus shows segmental endocapillary hypercellularity, but not in a tip location.<sup>1</sup> The perihilar variant is diagnosed when more than half of the sclerotic glomeruli have sclerosis or hyalinosis in the perihilar area.<sup>1</sup> In a study on Korean adults, the incidence of each subtype was 63.1%, 18.0%, 15.3%, 2.7%, and 0.9% for NOS, tip, perihilar, cellular and collapsing variant, respectively.<sup>10</sup> In Korean children, the incidence was 72.7%, 6.1%, 9.1%, 1.5%, and 10.6% for each subtype.<sup>11</sup> The low incidence of collapsing lesions in adults may partly be associated with the low frequency of HIVAN in Asia.<sup>12,13</sup>



**Fig. 1.** Morphologic variants of focal segmental glomerulosclerosis. (A) Capillary collapse and podocyte hyperplasia are characteristic features of the collapsing variant. (B) In the tip variant, segmental lesion involves the glomerular tuft next to the tubular pole. (C) The perihilar variant is diagnosed when sclerosis or hyalinosis are present in perihilar lesion in more than half of the sclerotic glomeruli.

### PATHOGENESIS OF PODOCYTE INJURY

There are several observations indicating that podocyte injury is at the center of the development of FSGS. First, podocyte injury is the earliest morphologic feature of FSGS. In recurrent FSGS in the allograft kidney, podocyte injury is detected by electron microscopy prior to the development of overt sclerosis.<sup>14-16</sup> Second, there are animal models of podocyte-specific injury resulting in FSGS. NEP25 mice express human CD25 specifically on podocytes. Injection of immunotoxin which binds to human CD25 induced podocyte-specific injury and FSGS occurred a few weeks later.<sup>17</sup> Rats expressing diphtheria toxin receptors on podocytes developed FSGS after diphtheria toxin injection.<sup>18</sup> Third, histologic appearance of FSGS and clinical symptoms were in proportion with the number of injured podocytes.<sup>18</sup> Therefore, the pathogenesis of podocyte injury is a key to understand the characteristics of FSGS.

### CIRCULATING PERMEABILITY FACTORS

As for the pathophysiology of podocyte injury, several mechanisms have been proposed with supporting evidences. Circulating permeability factors have been reckoned as the initiating factor of podocyte injury in primary FSGS and its recurrence after transplantation. The presence of serum factors that can cause podocyte injury was suggested from the therapeutic effect of immunoabsorption therapy<sup>19</sup> and observations that plasmapheresis could decrease the glomerular injury induced by patients' serum.<sup>20</sup> Further, serum of recurrent FSGS patients significantly increased albumin permeability of glomeruli in an *in vitro* test.<sup>21</sup> Among the proposed circulating permeability factors, soluble urokinase receptor (suPAR) has been most thoroughly investigated. Wei *et al.*<sup>22</sup> presented data in a mouse model suggesting that the urokinase receptor of podocytes contributed to podocyte loss and pro-

teinuria. The same group also suggested that suPAR could be the cause of FSGS. Serum levels of suPAR were increased in about two-thirds of primary FSGS patients and were also associated with recurrent FSGS after transplantation.<sup>23</sup> They also demonstrated that suPAR was increased in two different cohorts of biopsy-proven FSGS patients. However, suPAR was inversely correlated with estimated glomerular filtration rate (eGFR) and treatment response.<sup>24</sup> Other authors found that plasma suPAR level was significantly increased in FSGS patients versus patients with minimal change disease, membranous nephropathy, or normal control. However, suPAR level was not useful in distinguishing primary and secondary FSGS.<sup>25</sup> Several contradicting reports on suPAR have also been published. Importantly, eGFR affects plasma levels of suPAR in patients with non-FSGS glomerular lesions, and a suPAR cut off value could not be determined even in FSGS patients due to the effect of eGFR.<sup>26</sup> Plasma levels of suPAR were also increased in lupus nephritis patients compared to lupus patients without renal involvement.<sup>27</sup> In IgA nephropathy patients, the plasma level of suPAR was related to the development of secondary segmental sclerosis.<sup>28,29</sup> Therefore, whether suPAR plays a role in the development of focal segmental lesions and its specificity to the primary FSGS are still open to further investigation.

Cardiotrophin-like cytokine-1 (CLC-1 or cardiotrophin-like cytokine factor 1 [CLCF-1]) is another candidate circulating permeability factor for primary FSGS. Savin *et al.*<sup>30</sup> have published on a serum factor purified from FSGS patients, which increased albumin permeability in isolated rat glomeruli. This factor had affinity for galactose and its molecular weight was less than 30 kDa. They identified this factor as CLC-1 by proteomic analysis and also found that the activity of CLC-1 was decreased by several factors such as heterodimer formation with cosecreted cytokine receptor-like factor 1 (CRLF1), Janus kinase 2 (JAK2) inhibitor, and signal transducer and activator of transcription 3 (STAT3)

inhibitor.<sup>31,32</sup> A phase II clinical trial on therapeutic effect of galactose in patients with steroid-resistant FSGS was performed with inconclusive results due to small sample size.<sup>33,34</sup> This study design is interesting, considering that CLC-1 has high affinity for galactose and the CLC-1–galactose complex can be easily removed in the liver.<sup>30</sup>

Though known to be related to minimal change disease rather than FSGS, angiotensin-like-4 (Angptl4) is also of interest.<sup>35</sup> Angptl4 has different functions according to its sialylation. While proteinuria was induced by hyposialylated Angptl4 located within the glomerulus, normosialylated Angptl4 was present in the peripheral circulation and mediated hypertriglyceridemia,<sup>35,36</sup> indicating that these two symptoms of nephrotic syndrome could be linked through a common circulating factor.

## GENETIC BACKGROUND

FSGS, as a podocytopathy, may be caused by mutation in several genes, which are important in maintaining podocyte morphology and function. Most of these genes can be categorized as those which are related with slit diaphragm structure, actin cytoskeleton of podocytes, or podocyte-glomerular basement membrane interaction through foot processes.<sup>37-39</sup> In addition, a specific channel mutation (see below) has also been identified as a cause of FSGS (Table 1). Alteration of these genes results in autosomal dominant or recessive congenital, infantile, or late onset nephrotic syndrome, some of which presents as FSGS histologically.<sup>40</sup> Mutation in the *NPHS1* gene and resulting loss of its product nephrin, are responsible for congenital nephrotic syndrome of Finnish type. The locus of *NPHS1* was identified at 19q13.1 in 1998,<sup>41</sup> which was the first identification of a podocytopathy-related gene. After this discovery, *NPHS2*,<sup>42,43</sup> *PLCE1* (phospholipase C $\epsilon$ 1, *NPHS3*),<sup>43</sup> *WT1* (Wilms tumor 1, *NPHS4*),<sup>44</sup> *LAMB2* (laminin  $\beta$ 2, *NPHS5*),<sup>45</sup> *PTPRO* (protein tyrosine phosphatase receptor type O, *NPHS6*),<sup>46</sup> *ARHGDI*A (Rho GDP dissociation inhibitor  $\alpha$ , *NPHS8*),<sup>47</sup> *ADCK4* (aarF domain containing kinase 4, *NPHS9*),<sup>48</sup> and *EMP2* (epithelial membrane protein 2, *NPHS10*)<sup>49</sup> were identified and related to autosomal recessive nephrotic syndrome. Many other genes related to nephrotic syndrome have been identified including *ACTN4* (actinin  $\alpha$ 4, *FSGS1*),<sup>50</sup> *TRPC6* (transient receptor potential cation channel 6, *FSGS2*),<sup>51</sup> *CD2AP* (CD2-associated protein, *FSGS3*),<sup>52</sup> *APOL1* (apolipoprotein L1, *FSGS4*),<sup>53</sup> *INF2* (inverted formin, *FSGS5*),<sup>54</sup> *MYO1E* (myosin 1E, *FSGS6*),<sup>55</sup> *PAX2* (paired box gene 2, *FSGS7*),<sup>56</sup> *ANLN* (anillin, *FSGS8*),<sup>57</sup> and *CRB2* (Crumbs homolog 2, *FSGS9*).<sup>58</sup> There are interactions of these genes and their

**Table 1.** Genes related to FSGS or nephrotic syndrome

	Related protein or gene description
<i>NPHS1</i>	Nephrin
<i>NPHS2</i>	Podocin
<i>PLCE1</i> ( <i>NPHS3</i> )	Phospholipase C $\epsilon$ 1
<i>WT1</i> ( <i>NPHS4</i> )	Wilms tumor 1
<i>LAMB2</i> ( <i>NPHS5</i> )	Laminin $\beta$ 2
<i>PTPRO</i> ( <i>NPHS6</i> )	Protein tyrosine phosphatase receptor type O
<i>ARHGDI</i> A ( <i>NPHS8</i> )	Rho GDP dissociation inhibitor $\alpha$
<i>ADCK4</i> ( <i>NPHS9</i> )	aarF domain containing kinase 4
<i>EMP2</i> ( <i>NPHS10</i> )	Epithelial membrane protein 2
<i>ACTN4</i> ( <i>FSGS1</i> )	$\alpha$ -Actin-4
<i>TRPC6</i> ( <i>FSGS2</i> )	Transient receptor potential cation channel 6
<i>CD2AP</i> ( <i>FSGS3</i> )	CD2-associated protein
<i>APOL1</i> ( <i>FSGS4</i> )	Apolipoprotein L1
<i>INF2</i> ( <i>FSGS5</i> )	Inverted formin
<i>MYO1E</i> ( <i>FSGS6</i> )	Myosin 1E
<i>PAX2</i> ( <i>FSGS7</i> )	Paired box gene 2
<i>ANLN</i> ( <i>FSGS8</i> )	Anillin
<i>CRB2</i> ( <i>FSGS9</i> )	Crumbs homolog 2

FSGS, focal segmental glomerulosclerosis.

products. For example, *WT1* transcriptionally regulates nephrin encoding of *NPHS1*, therefore, *WT1* mutations influence *NPHS1* function.<sup>59</sup> A study in a European cohort reported that two thirds of nephrotic syndrome within 1 year of life are related to alteration of *NPHS1*, *NPHS2*, *WT1*, or *LAMB2*.<sup>60</sup> Another study in a non-Finnish ethnic group also reported that *NPHS1* and *NPHS2* mutations were the most common genetic alterations in congenital nephrotic syndrome.<sup>61</sup> In contrast to these Western studies, a genetic analysis of 30 Korean congenital and infantile nephrotic syndrome patients revealed that *WT1* and *NPHS1* mutations were the most frequent alterations, while *NPHS2* mutations were the lowest frequency genetic alteration.<sup>62</sup>

## PARIETAL EPITHELIAL CELLS AND PODOCYTE INJURY

Podocytes are terminally differentiated cells having very limited ability of regeneration or proliferation. Therefore, the mechanism of repopulation of podocytes after podocyte injury has been of great interest. Recently, it has been suggested that parietal epithelial cells (PECs) lining Bowman's capsule play an important role in this process by migrating from their original site to replace injured podocytes.<sup>63</sup> During glomerulogenesis, PECs and podocytes originate from common mesenchymal progenitors and finally have different phenotypes. Although little is known about the function of terminally differentiated PECs, they express tight junction molecules such as claudin-1, zonula occludens-1, and



occludin and have barrier function against protein.<sup>64</sup> Some PECs express both CD133 and CD24, which are known to be stem cell markers, and these cells have regenerative ability.<sup>65</sup> More detailed study revealed that PECs show hierarchical differentiation according to their locations. PECs located at the urinary pole express CD133 and CD24 without the expression of podocyte markers (nestin, complement receptor-1, and podocalyxin). PECs of the vascular pole express podocyte markers without the expression of CD133 or CD24. In other areas, PECs express both CD133/CD24 and podocyte markers.<sup>66</sup> CD133 and CD24-expressing PECs have the ability to ameliorate kidney injury by potentiating tubular regeneration<sup>65</sup> and podocyte replacement, however, they can also contribute to glomerular injury such as glomerulosclerosis and crescent formation.<sup>67,68</sup> Animal models and human post-transplant biopsies demonstrated that invasion of activated PECs through the adhesion sites of the capillary tuft contributed to the development of FSGS.<sup>69</sup> The adhesion of the glomerular tuft to the Bowman's capsule as a bridge of PEC migration appears to occur at early stages of FSGS development.<sup>70</sup> Therefore, detecting activated PECs on Bowman's capsule or on the glomerular tuft could be an adjunctive diagnostic tool for early FSGS. In support of this concept, CD44 as a marker of activated PECs successfully distinguished early primary FSGS<sup>70</sup> and early post-transplant recurrence of FSGS<sup>71</sup> from minimal change disease. Interestingly, mutation of *ARHGDI1*, which is responsible for nephrotic syndrome, increased migration activity of cultured podocytes.<sup>47</sup>

## CONCLUSION

The etiology and pathogenesis of FSGS are very complex. Current research is focusing on the role of podocytes and interaction with PECs. Understanding the mechanism of podocyte injury, its progression and possible recovery is important not only for basic research but also for daily diagnostic pathology practice.

## Conflicts of Interest

No potential conflict of interest relevant to this article was reported.

## REFERENCES

1. D'Agati VD, Fogo AB, Brujijn JA, Jennette JC. Pathologic classification of focal segmental glomerulosclerosis: a working proposal. *Am J Kidney Dis* 2004; 43: 368-82.
2. Weiss MA, Daquiao E, Margolin EG, Pollak VE. Nephrotic syn-

- drome, progressive irreversible renal failure, and glomerular "collapse": a new clinicopathologic entity? *Am J Kidney Dis* 1986; 7: 20-8.
3. Moudgil A, Nast CC, Bagga A, *et al.* Association of parvovirus B19 infection with idiopathic collapsing glomerulopathy. *Kidney Int* 2001; 59: 2126-33.
4. Markowitz GS, Appel GB, Fine PL, *et al.* Collapsing focal segmental glomerulosclerosis following treatment with high-dose pamidronate. *J Am Soc Nephrol* 2001; 12: 1164-72.
5. Markowitz GS, Nasr SH, Stokes MB, D'Agati VD. Treatment with IFN- $\alpha$ , - $\beta$ , or - $\gamma$  is associated with collapsing focal segmental glomerulosclerosis. *Clin J Am Soc Nephrol* 2010; 5: 607-15.
6. Mohamed N, Goldstein J, Schiff J, John R. Collapsing glomerulopathy following anthracycline therapy. *Am J Kidney Dis* 2013; 61: 778-81.
7. Gulati A, Sharma A, Hari P, Dinda AK, Bagga A. Idiopathic collapsing glomerulopathy in children. *Clin Exp Nephrol* 2008; 12: 348-53.
8. D'Agati VD, Alster JM, Jennette JC, *et al.* Association of histologic variants in FSGS clinical trial with presenting features and outcomes. *Clin J Am Soc Nephrol* 2013; 8: 399-406.
9. Trivedi M, Pasari A, Chowdhury AR, Abraham A, Pandey R. Tip variant of focal segmental glomerulosclerosis: is it truly a benign variant? *Ren Fail* 2015; 37: 763-8.
10. Kwon YE, Han SH, Kie JH, *et al.* Clinical features and outcomes of focal segmental glomerulosclerosis pathologic variants in Korean adult patients. *BMC Nephrol* 2014; 15: 52.
11. Paik KH, Lee BH, Cho HY, *et al.* Primary focal segmental glomerular sclerosis in children: clinical course and prognosis. *Pediatr Nephrol* 2007; 22: 389-95.
12. Praditpornsilpa K, Napathorn S, Yenrudi S, Wankrairo P, Tungsa-ga K, Sitprija V. Renal pathology and HIV infection in Thailand. *Am J Kidney Dis* 1999; 33: 282-6.
13. Naaz I, Wani R, Najjar MS, Banday K, Baba KM, Jeelani H. Collapsing glomerulopathy in an HIV-positive patient in a low-incidence belt. *Indian J Nephrol* 2010; 20: 211-3.
14. Chang JW, Pardo V, Sageshima J, *et al.* Podocyte foot process effacement in postreperfusion allograft biopsies correlates with early recurrence of proteinuria in focal segmental glomerulosclerosis. *Transplantation* 2012; 93: 1238-44.
15. Alachkar N, Wei C, Arend LJ, *et al.* Podocyte effacement closely links to suPAR levels at time of posttransplantation focal segmental glomerulosclerosis occurrence and improves with therapy. *Transplantation* 2013; 96: 649-56.
16. Canaud G, Dion D, Zuber J, *et al.* Recurrence of nephrotic syndrome after transplantation in a mixed population of children and

- adults: course of glomerular lesions and value of the Columbia classification of histological variants of focal and segmental glomerulosclerosis (FSGS). *Nephrol Dial Transplant* 2010; 25: 1321-8.
17. Matsusaka T, Xin J, Niwa S, *et al.* Genetic engineering of glomerular sclerosis in the mouse via control of onset and severity of podocyte-specific injury. *J Am Soc Nephrol* 2005; 16: 1013-23.
  18. Wharram BL, Goyal M, Wiggins JE, *et al.* Podocyte depletion causes glomerulosclerosis: diphtheria toxin-induced podocyte depletion in rats expressing human diphtheria toxin receptor transgene. *J Am Soc Nephrol* 2005; 16: 2941-52.
  19. Haas M, Godfrin Y, Oberbauer R, *et al.* Plasma immunoadsorption treatment in patients with primary focal and segmental glomerulosclerosis. *Nephrol Dial Transplant* 1998; 13: 2013-6.
  20. Artero ML, Sharma R, Savin VJ, Vincenti F. Plasmapheresis reduces proteinuria and serum capacity to injure glomeruli in patients with recurrent focal glomerulosclerosis. *Am J Kidney Dis* 1994; 23: 574-81.
  21. Savin VJ, Sharma R, Sharma M, *et al.* Circulating factor associated with increased glomerular permeability to albumin in recurrent focal segmental glomerulosclerosis. *N Engl J Med* 1996; 334: 878-83.
  22. Wei C, Moller CC, Altintas MM, *et al.* Modification of kidney barrier function by the urokinase receptor. *Nat Med* 2008; 14: 55-63.
  23. Wei C, El Hindi S, Li J, *et al.* Circulating urokinase receptor as a cause of focal segmental glomerulosclerosis. *Nat Med* 2011; 17: 952-60.
  24. Wei C, Trachtman H, Li J, *et al.* Circulating suPAR in two cohorts of primary FSGS. *J Am Soc Nephrol* 2012; 23: 2051-9.
  25. Huang J, Liu G, Zhang YM, *et al.* Plasma soluble urokinase receptor levels are increased but do not distinguish primary from secondary focal segmental glomerulosclerosis. *Kidney Int* 2013; 84: 366-72.
  26. Meijers B, Maas RJ, Sprangers B, *et al.* The soluble urokinase receptor is not a clinical marker for focal segmental glomerulosclerosis. *Kidney Int* 2014; 85: 636-40.
  27. Qin DD, Song D, Huang J, Yu F, Zhao MH. Plasma-soluble urokinase-type plasminogen activator receptor levels are associated with clinical and pathological activities in lupus nephritis: a large cohort study from China. *Lupus* 2015; 24: 546-57.
  28. Guo SM, Han M, Chen MX, *et al.* Soluble urokinase receptor levels are correlated with focal segmental glomerulosclerosis lesions in IgA nephropathy: a cohort study from China. *PLoS One* 2015; 10: e0138718.
  29. Working Group of the International IgA Nephropathy Network and the Renal Pathology Society, Cattran DC, Coppo R, *et al.* The Oxford classification of IgA nephropathy: rationale, clinicopathological correlations, and classification. *Kidney Int* 2009; 76: 534-45.
  30. Savin VJ, McCarthy ET, Sharma R, Charba D, Sharma M. Galactose binds to focal segmental glomerulosclerosis permeability factor and inhibits its activity. *Transl Res* 2008; 151: 288-92.
  31. McCarthy ET, Sharma M, Savin VJ. Circulating permeability factors in idiopathic nephrotic syndrome and focal segmental glomerulosclerosis. *Clin J Am Soc Nephrol* 2010; 5: 2115-21.
  32. Sharma M, Zhou J, Gauchat JF, *et al.* Janus kinase 2/signal transducer and activator of transcription 3 inhibitors attenuate the effect of cardiotrophin-like cytokine factor 1 and human focal segmental glomerulosclerosis serum on glomerular filtration barrier. *Transl Res* 2015; 166: 384-98.
  33. Trachtman H, Vento S, Gipson D, *et al.* Novel therapies for resistant focal segmental glomerulosclerosis (FONT) phase II clinical trial: study design. *BMC Nephrol* 2011; 12: 8.
  34. Trachtman H, Vento S, Herreshoff E, *et al.* Efficacy of galactose and adalimumab in patients with resistant focal segmental glomerulosclerosis: report of the font clinical trial group. *BMC Nephrol* 2015; 16: 111.
  35. Clement LC, Avila-Casado C, Macé C, *et al.* Podocyte-secreted angiopoietin-like-4 mediates proteinuria in glucocorticoid-sensitive nephrotic syndrome. *Nat Med* 2011; 17: 117-22.
  36. Clement LC, Macé C, Avila-Casado C, Joles JA, Kersten S, Chugh SS. Circulating angiopoietin-like 4 links proteinuria with hypertriglyceridemia in nephrotic syndrome. *Nat Med* 2014; 20: 37-46.
  37. Chen YM, Liapis H. Focal segmental glomerulosclerosis: molecular genetics and targeted therapies. *BMC Nephrol* 2015; 16: 101.
  38. Jefferson JA, Shankland SJ. The pathogenesis of focal segmental glomerulosclerosis. *Adv Chronic Kidney Dis* 2014; 21: 408-16.
  39. D'Agati VD, Kaskel FJ, Falk RJ. Focal segmental glomerulosclerosis. *N Engl J Med* 2011; 365: 2398-411.
  40. Pollak MR. Familial FSGS. *Adv Chronic Kidney Dis* 2014; 21: 422-5.
  41. Kestilä M, Lenkkeri U, Männikkö M, *et al.* Positionally cloned gene for a novel glomerular protein-nephrin-is mutated in congenital nephrotic syndrome. *Mol Cell* 1998; 1: 575-82.
  42. Boute N, Gribouval O, Roselli S, *et al.* *NPHS2*, encoding the glomerular protein podocin, is mutated in autosomal recessive steroid-resistant nephrotic syndrome. *Nat Genet* 2000; 24: 349-54.
  43. Hinkes B, Wiggins RC, Gbadegesin R, *et al.* Positional cloning uncovers mutations in *PLCE1* responsible for a nephrotic syndrome variant that may be reversible. *Nat Genet* 2006; 38: 1397-405.
  44. Mucha B, Ozaltin F, Hinkes BG, *et al.* Mutations in the Wilms' tumor 1 gene cause isolated steroid resistant nephrotic syndrome and occur in exons 8 and 9. *Pediatr Res* 2006; 59: 325-31.
  45. Zenker M, Aigner T, Wendler O, *et al.* Human laminin beta2 deficiency causes congenital nephrosis with mesangial sclerosis and distinct eye abnormalities. *Hum Mol Genet* 2004; 13: 2625-32.
  46. Ozaltin F, Ibsirlioglu T, Taskiran EZ, *et al.* Disruption of PTPRO

- causes childhood-onset nephrotic syndrome. *Am J Hum Genet* 2011; 89: 139-47.
47. Gee HY, Saisawat P, Ashraf S, et al. *ARHGDIA* mutations cause nephrotic syndrome via defective RHO GTPase signaling. *J Clin Invest* 2013; 123: 3243-53.
  48. Ashraf S, Gee HY, Woerner S, et al. *ADCK4* mutations promote steroid-resistant nephrotic syndrome through CoQ10 biosynthesis disruption. *J Clin Invest* 2013; 123: 5179-89.
  49. Gee HY, Ashraf S, Wan X, et al. Mutations in *EMP2* cause childhood-onset nephrotic syndrome. *Am J Hum Genet* 2014; 94: 884-90.
  50. Kaplan JM, Kim SH, North KN, et al. Mutations in *ACTN4*, encoding alpha-actinin-4, cause familial focal segmental glomerulosclerosis. *Nat Genet* 2000; 24: 251-6.
  51. Winn MP, Conlon PJ, Lynn KL, et al. A mutation in the *TRPC6* cation channel causes familial focal segmental glomerulosclerosis. *Science* 2005; 308: 1801-4.
  52. Gigante M, Pontrelli P, Montemurno E, et al. *CD2AP* mutations are associated with sporadic nephrotic syndrome and focal segmental glomerulosclerosis (FSGS). *Nephrol Dial Transplant* 2009; 24: 1858-64.
  53. Genovese G, Friedman DJ, Ross MD, et al. Association of trypanolytic ApoL1 variants with kidney disease in African Americans. *Science* 2010; 329: 841-5.
  54. Brown EJ, Schlöndorff JS, Becker DJ, et al. Mutations in the formin gene *INF2* cause focal segmental glomerulosclerosis. *Nat Genet* 2010; 42: 72-6.
  55. Mele C, Iatropoulos P, Donadelli R, et al. *MYO1E* mutations and childhood familial focal segmental glomerulosclerosis. *N Engl J Med* 2011; 365: 295-306.
  56. Barua M, Stellacci E, Stella L, et al. Mutations in *PAX2* associate with adult-onset FSGS. *J Am Soc Nephrol* 2014; 25: 1942-53.
  57. Gbadegesin RA, Hall G, Adeyemo A, et al. Mutations in the gene that encodes the F-actin binding protein anillin cause FSGS. *J Am Soc Nephrol* 2014; 25: 1991-2002.
  58. Ebarasi L, Ashraf S, Bierzynska A, et al. Defects of *CRB2* cause steroid-resistant nephrotic syndrome. *Am J Hum Genet* 2015; 96: 153-61.
  59. Wagner N, Wagner KD, Xing Y, Scholz H, Schedl A. The major podocyte protein nephrin is transcriptionally activated by the Wilms' tumor suppressor WT1. *J Am Soc Nephrol* 2004; 15: 3044-51.
  60. Hinkes BG, Mucha B, Vlangos CN, et al. Nephrotic syndrome in the first year of life: two thirds of cases are caused by mutations in 4 genes (*NPHS1*, *NPHS2*, *WT1*, and *LAMB2*). *Pediatrics* 2007; 119: e907-19.
  61. Machuca E, Benoit G, Nevo F, et al. Genotype-phenotype correlations in non-Finnish congenital nephrotic syndrome. *J Am Soc Nephrol* 2010; 21: 1209-17.
  62. Lee JH, Han KH, Lee H, et al. Genetic basis of congenital and infantile nephrotic syndromes. *Am J Kidney Dis* 2011; 58: 1042-3.
  63. Appel D, Kershaw DB, Smeets B, et al. Recruitment of podocytes from glomerular parietal epithelial cells. *J Am Soc Nephrol* 2009; 20: 333-43.
  64. Ohse T, Chang AM, Pippin JW, et al. A new function for parietal epithelial cells: a second glomerular barrier. *Am J Physiol Renal Physiol* 2009; 297: F1566-74.
  65. Sagrinati C, Netti GS, Mazzinghi B, et al. Isolation and characterization of multipotent progenitor cells from the Bowman's capsule of adult human kidneys. *J Am Soc Nephrol* 2006; 17: 2443-56.
  66. Ronconi E, Sagrinati C, Angelotti ML, et al. Regeneration of glomerular podocytes by human renal progenitors. *J Am Soc Nephrol* 2009; 20: 322-32.
  67. Lasagni L, Romagnani P. Glomerular epithelial stem cells: the good, the bad, and the ugly. *J Am Soc Nephrol* 2010; 21: 1612-9.
  68. Smeets B, Uhlig S, Fuss A, et al. Tracing the origin of glomerular extracapillary lesions from parietal epithelial cells. *J Am Soc Nephrol* 2009; 20: 2604-15.
  69. Smeets B, Kuppe C, Sicking EM, et al. Parietal epithelial cells participate in the formation of sclerotic lesions in focal segmental glomerulosclerosis. *J Am Soc Nephrol* 2011; 22: 1262-74.
  70. Smeets B, Stucker F, Wetzels J, et al. Detection of activated parietal epithelial cells on the glomerular tuft distinguishes early focal segmental glomerulosclerosis from minimal change disease. *Am J Pathol* 2014; 184: 3239-48.
  71. Fatima H, Moeller MJ, Smeets B, et al. Parietal epithelial cell activation marker in early recurrence of FSGS in the transplant. *Clin J Am Soc Nephrol* 2012; 7: 1852-8.