

# A prospective study to evaluate the efficacy of ultrasound-guided ganglion impar block in patients with chronic perineal pain

## ABSTRACT

**Background:** The blockade of the ganglion impar has been described to relieve the intractable perineal pain of sympathetic origin in patients with coccydynia. Chronic perineal pain (CPP) has been effectively managed by ganglion impar block. The feasibility, safety, and efficacy of ultrasound (US)-guided ganglion impar block by transsacrococcygeal approach was analyzed in the present study.

**Methods:** A total of 15 patients with CPP were administered US-guided ganglion impar block using out of plane approach. Patients were followed for VAS and quality of life using Karnofsky performance status (KS), Linear Analog Scale Assessment (LASA), and constipation score up to 2 months at different time intervals. Time required to perform the procedure, number of attempts, and any complications were also noted.

**Results:** The mean time required to perform the procedure was  $7.67 \pm 1.23$  min. There were no adverse events. All the patients had significant pain relief during 2 month follow-up ( $P < 0.05$  compared to baseline VAS). The KS and LASA score improved post block which was statistically significant. The dose of nonsteroidal anti-inflammatory drugs (NSAIDs) decreased from preblock state with statistically significant difference, while the difference in dose of tramadol and morphine was statistically insignificant.

**Conclusion:** US-guided ganglion impar block is technically feasible and safe technique. USG can be used to locate sacrococcygeal junction (SCJ) and facilitate the performance of ganglion impar block. The efficacy and safety of the US-guided ganglion impar blockades needs a proper evaluation in the randomized controlled trials.

**Key words:** Coccygodynia; ganglion impar block; pain; ultrasound guidance

## Introduction

The ganglion impar or ganglion of Walther is a solitary retroperitoneal structure at the level of sacrococcygeal junction. Ganglion impar block is indicated in coccygodynia, chronic prostatitis, chronic proctitis, pelvic malignancies, and chronic perineal pain (CPP) with either somatic or sympathetic component. Sympathetically mediated perineal pain is a

poorly localized type of pain with burning quality combined with sense of urgency with urination or defecation.<sup>[1]</sup> It is linked with pain originating from blood vessels, nerves, and other tissues. Pelvic malignancies lead to CPP due to compression, distension, and invasion of the visceral structures. Visceral pain is vague, poorly localized, deep

This is an open access journal, and articles are distributed under the terms of the Creative Commons Attribution-NonCommercial-ShareAlike 4.0 License, which allows others to remix, tweak, and build upon the work non-commercially, as long as appropriate credit is given and the new creations are licensed under the identical terms.

**For reprints contact:** reprints@medknow.com

**How to cite this article:** Ghai A, Jangra P, Wadhera S, Kad N, Karwasra RK, Sahu A, *et al.* A prospective study to evaluate the efficacy of ultrasound-guided ganglion impar block in patients with chronic perineal pain. Saudi J Anaesth 2019;13:126-30.

Access this article online	
<b>Website:</b> www.saudija.org	<b>Quick Response Code</b> 
<b>DOI:</b> 10.4103/sja.SJA_667_18	

**ANJU GHAI, PRITI JANGRA, SARTHAK WADHERA<sup>1</sup>, NANDITA KAD, R. K. KARWASRA<sup>2</sup>, ANKUR SAHU<sup>3</sup>, RAJMALA JAISWAL**  
Departments of Anaesthesiology, <sup>2</sup>Surgery and <sup>3</sup>Orthopedics, <sup>1</sup>Postgraduate Student, PGIMS, Rohtak, Haryana, India

**Address for correspondence:** Dr. Anju Ghai, Department of Anaesthesiology, Medicine Surgery, Orthopedics, PGIMS, Rohtak, Haryana, India. E-mail: dr.wadhera@yahoo.com

noxious, and squeezing. The management of CPP needs a multimodal approach with primary goal directed toward maximal functional restoration and significant reduction in severity and intensity of pain.<sup>[2]</sup>

Coccygodynia is mainly associated with abnormal mobility of the coccygeal region triggering chronic inflammation. The pain worsens with abnormal sitting posture, such as leaning back while being seated, prolonged sitting as well as standing, and abrupt rising from sitting position.<sup>[3]</sup>

Coccygeal cushions, nonsteroidal anti-inflammatory drugs, local analgesics, levator ani relaxation exercises, and transcutaneous electrical nerve stimulation have been used in conservative treatment, but in cases that are not responsive to conservative treatment, direct injections around the coccyx, caudal epidural blocks, or ganglion impar blocks can be applied.<sup>[4]</sup>

Ganglion impar block is useful for evaluating and managing visceral or sympathetically mediated pain in the coccygeal and perineal area. Improvements in transducer technology and imaging processing within the last decade have increased interest in ultrasound (US)-guided procedures, including regional anesthesia and interventional pain management.<sup>[5,6]</sup>

Since the literature on US-guided ganglion impar block is limited; hence, we evaluated the feasibility of using US-guided needle placement into the SCJ along with loss of resistance technique to facilitate ganglion impar block and assess its efficacy in patients with CPP.

## Materials and Methods

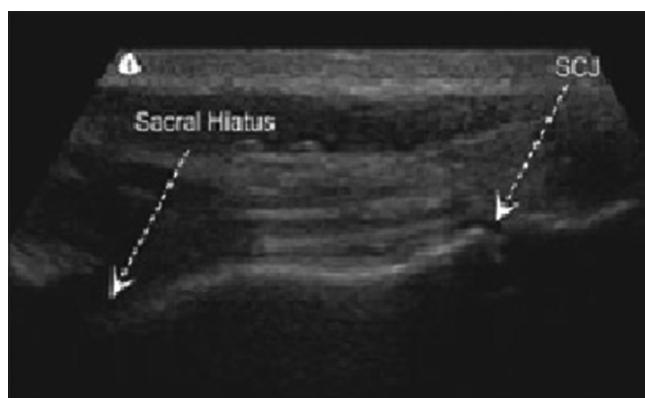
Patients aged between 25 and 65 years, suffering from CPP presenting to pain clinic from September 2016 to January 2018, were included in the study. Patients having sepsis, local infection, and coagulopathy were excluded from the study. Written informed consent was taken after explaining the procedure in detail.

All the patients were assessed for pain by visual analog score (0–10, where 0 means no pain and 10 represents maximum pain perceived). All the patients were assessed for current drug therapy and its dosage. Patients having VAS equal to or more than 4 and inadequate response to oral analgesics was considered for block.

Quality of life was assessed by Karnofsky performance status (KS), Linear Analog Scale Assessment (LASA), and constipation score (CS).<sup>[7,8]</sup> The Karnofsky Performance Scale Index

(0–100) allows patients to be classified as to their functional impairment. This can be used to compare effectiveness of different therapies and to assess the prognosis in individual patients. LASA (0–50) includes five simple parameters, each of which targets a specific domain of quality of life. Specific domains include physical wellbeing (i.e., fatigue, activity level), emotional well-being (i.e., depression, anxiety, and stress), spiritual well-being (i.e., sense of meaning, relationship with God), and intellectual well-being (i.e., ability to think clearly, concentrate). A parameter for overall quality of life (QOL) was also included.

Patients were placed in the prone position with the pelvis supported with a pillow. The lower extremities rotated internally, the toes pointing toward the opposite foot to hold the gluteal masses apart to achieve a flatter skin surface at the sacral hiatus area. The intergluteal area was prepared and draped, and the transducer covered with sterile cover. The transducer was placed transversely at the midline to obtain a transverse view of the sacral hiatus.<sup>[9]</sup> The two sacral cornua, the apex of the sacral hiatus, the base of sacrum, and the sacrococcygeal ligament, which stretches across the sacral hiatus, separating the subcutaneous tissue layer from the epidural space underneath were identified. The transducer was rotated 90° to examine the longitudinal view of the sacral hiatus [Figure 1].<sup>[9]</sup> The proximal cephalic part of the transducer rest between the two cornua and the first cleft caudal to the sacral hiatus was identified as the SCJ and the location confirmed by pressing with a long forceps under sonographic monitoring. After local infiltration of the skin and subcutaneous tissue overlying SCJ, a 23-gauge needle was advanced into the SCJ under real time US guidance. The needle was then advanced slowly through the cleft of the SCJ using out of plane approach. The needle was advanced up to the point of loss of resistance indicating placement of the needle tip anterior to the ventral sacrococcygeal ligament. Diagnostic block



**Figure 1:** Ultrasound appearance of sacrococcygeal junction on longitudinal view

was given with 3–5 ml of 1% lignocaine. If VAS decreased to less than 3, therapeutic block was performed with 10 ml of 0.25% bupivacaine and 40 mg of methylprednisolone acetate. Vitals were monitored during the procedure. Time taken to perform the block (time from introduction of needle to final placement), sonographic depth of the SCJ junction, depth of the needle, and number of attempts or any other complication were also noted.

Pain scores were noted at 10 min, 30 min, 1<sup>st</sup> hour, 1<sup>st</sup> week, 2<sup>nd</sup> week, 1<sup>st</sup> month, and 2<sup>nd</sup> month after the block. Time required for VAS to reduce by 50% was noted. KS, LAS, and constipation score were noted at 2<sup>nd</sup> month. The oral drug treatment (NSAIDs, tramadol, morphine, gabapentin, and combination therapy) at 2<sup>nd</sup> month required to achieve satisfactory pain control was noted along with the KS, LASA, and CS.

## Results

Demographic data are shown in Table 1.

Technical parameters are shown in Table 2. The mean time to perform the block was  $7.67 \pm 1.23$  min ranging from 6 to 10 min. The mean depth of sacrococcygeal junction measured by ultrasound was  $13.73 \pm 0.52$  mm ranging from 12.8 to 14.5 mm. Similarly, depth of needle inserted to the point of injection was  $15.38 \pm 1.30$  mm ranging from 14.2 to 16.0 mm. A total of patients had successful block in single attempt. Three patients required 2<sup>nd</sup> attempt and one patient needed 3<sup>rd</sup> attempt.

Table 3 and Figure 2 shows baseline VAS and its value at different time intervals. The VAS was significantly reduced from baseline at all intervals. The pain intensity was significantly lower postblock when compared to baseline value throughout the 2 month follow-up period.

The mean KS and LASA decreased postblock with a difference which is statistically significant as shown in Table 4. However, constipation score did not reduced significantly. Mean

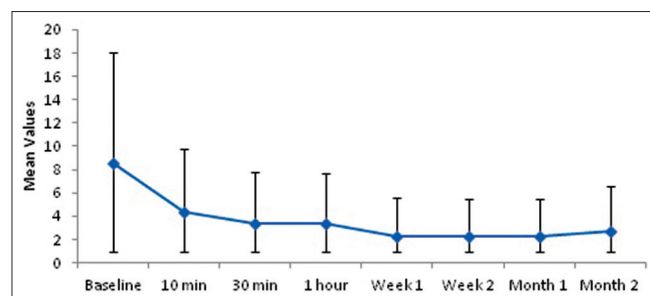


Figure 2: VAS at different time intervals

consumption of NSAIDs decreased significantly while that of tramadol and Morphine was insignificant [Table 5].

## Discussion

There are three commonly used techniques to achieve blockade of the ganglion impar. The original Plancarte technique utilizes a bent or “c” shaped needle introduced through the anococcygeal ligament with position confirmed by lateral and anterior–posterior fluoroscopy, this technique also commonly requires the operator to insert a finger into the rectum of the patient during the procedure.<sup>[10]</sup> The transsacrococcygeal junction approach utilizes also fluoroscopy, as well as the paramedian approach with a curved needle (Wemm and Saberski, 1995).<sup>[11]</sup> Computed tomography (CT) guidance in place of fluoroscopy has also been described (Agarwal-Kozlowski *et al.*, 2009).<sup>[12]</sup>

The growing popularity of ultrasound technique has facilitated the performance of regional blocks. The use of

Table 1: Demographic parameters

Age (years)	Mean ± SD	50.12 ± 9.59 (29-65)
Sex	Male	26.7%
	Female	73.3%
Diagnosis	Ca breast with pelvic metastasis	6.7%
	Ca cervix	20.0%
	Ca rectum	6.7%
	Coccygodynia	66.7%

Table 2: Technical parameters

	Mean ± SD	Min-Max
Time taken (min)	7.67 ± 1.23	6-10
Depth of SCJ (mm)	13.73 ± 0.52	12.8-14.5
Depth of needle (mm)	15.38 ± 0.56	14.2-16.0

Table 3: Mean VAS at various time intervals

VAS	n	Mean ± SD	P
Baseline	15	8.53 ± 0.52	<0.001
10 min	15	4.40 ± 0.74	
30 min	15	3.40 ± 0.74	
1 h	15	3.33 ± 1.50	
Week 1	15	2.30 ± 1.87	
Week 2	15	2.23 ± 1.89	
Month 1	15	2.23 ± 1.90	
Month 2	15	2.77 ± 1.77	

Table 4: Outcome parameters

	Baseline	Month 2	P
KS	54.67 ± 14.57	74.67 ± 15.06	<0.001
LASA	20.20 ± 9.52	24.47 ± 8.94	<0.001
CS	0.93 ± 1.03	0.73 ± 0.88	0.082

**Table 5: Oral drug therapy**

	Preblock (Mean±SD)	Postblock (Mean±SD)	Mean difference	SD	P
<b>NSAIDs</b>					
<i>n</i>	7	7			
Mean±SD	642.86±350.51	457.14±362.7	185.71	154.69	0.027
Median (IQR)	600 (300-1000)	500 (15-1000)			
<b>Tramadol</b>					
<i>n</i>	5	5			
Mean±SD	240.00±54.77	220.00±44.72	20	44.72	0.317
Median (IQR)	200 (200-300)	200 (200-250)			
<b>Morphine</b>					
<i>n</i>	3	3			
Mean±SD	20.00±0.00	16.67±5.77	3.33	5.77	0.423

ultrasound is postulated to improve efficacy and reduce complications. It could replace the use of conventional fluoroscopic techniques for ganglion impar blockade with an advantage of reduced radiation exposure. Additional advantages using ultrasound are that there is no need to palpate the rectum during needle placement. So, patient's acceptance and comfort during the procedure is likely to be improved. As there is no need to access the rectum, so the risk of infections is decreased.

We could easily locate patient's SCJ under US guidance in all 15 patients. Our results are comparable to study by Lin *et al.* who used ultrasound as primary imaging tool with fluoroscopic confirmation of depth of needle in 15 patients.<sup>[13]</sup> But we could feel loss of resistance of sacrococcygeal ligament and drug was injected at this point.

In our study, there was statistically significant decrease in pain score which is comparable to study by Bhatnagar *et al.* ( $P < 0.05$ ). The VAS score was lowest at 2<sup>nd</sup> week which persisted till 2<sup>nd</sup> month. Quality of life of patients improved significantly as shown by KS, LASA ( $P < 0.05$ ) while in study by Bhatnagar *et al.*, the QOL did not improve. Their study included only six patients of malignant etiology. They recommended early US-guided neurolysis to control pain in cancer patients. In our study, there was statistically significant decrease in dose of NSAIDs ( $P 0.027$ ) as well as number of patients taking oral drug therapy decreased significantly and the results are comparable to study by Bhatnagar *et al.*<sup>[14]</sup>

The limitations of our study include low power, small sample size, and relatively short follow-up. With a lower power, the study may not have produced a statistically significant result even when one existed. It is difficult to determine the importance with a small sample size. A larger study with longer follow-up is indicated.

In conclusion, we recommend the use of ultrasound to locate SCJ and facilitate the performance of ganglion impar block. It is technically feasible and safe technique. The efficacy and safety of the US-guided ganglion impar blockades needs a proper evaluation in the randomized controlled trials.

#### Financial support and sponsorship

Nil.

#### Conflicts of interest

There are no conflicts of interest.

#### References

- Wallace MS, Leung AY, McBeth MD. Malignant pain. In Raj P, editor. Textbook of Regional Anesthesia. Pennsylvania: Churchill Livingstone Publishers; 2002. p. 585.
- Bridges D, Thompson SWN, Rice ASC. Mechanism of neuropathic pain. *Br J Anaesth* 2001;87:12-26.
- Maigne JY, Doursounian L, Chatellier G. Causes and mechanisms of common coccydynia: Role of body mass index and coccygeal trauma. *Spine* 2000;25:3072-9.
- Lirette LS, Chaiban G, Tolba R, Eissa H. Coccydynia. An overview of the anatomy, etiology, and treatment of coccyx pain. *Ochsner J* 2014;14:84-7.
- Narouze S. Ultrasonography in pain medicine: A sneak peak at the future. *Pain Pract* 2008;8:223-5.
- Peng P, Narouze S. Ultrasound-guided Interventional procedures in pain medicine: A review of anatomy, sonoanatomy and procedures. Part I: Non-axial structures. *Reg Anesth Pain Med* 2009;34:458-74.
- Yates JW, Chalmer B, McKegney FP. Evaluation of patients with advanced cancer using the Karnofsky performance status. *Cancer* 1980;45:2220-4.
- Locke DEC, Decker PA, Sloan JA, Brown DP, Malec FJ, Clark MM, *et al.* Validation of single-item linear analog scale assessment of quality of life in neuro-oncology patients. *Pain Symptom Manage* 2007;34:628-38.
- Chen CP, Tang SF, Hsu TC. Ultrasound guidance in caudal epidural needle placement. *Anesthesiology* 2004;101:181-4.
- Plancarte R, Amescua C, Patt RB. Presacral blockade of the ganglion of Walther (ganglion impar). *Anesthesiology* 1990; 73:A751.
- Wemm K Jr, Saberski L. Modified approach to block the ganglion

- impar (ganglion of Walther). *Reg Anesth* 1995;20:544-5.
12. Agarwal-Kozlowski K, Lorke DE, Habermann CR, Amm Esch JS, Beck H. CT-guided blocks and neuroablation of the ganglion impar (Walther) in perineal pain: Anatomy, technique, safety and efficacy. *Clin J Pain* 2009;25:570-6.
  13. Lin CS, Cheng JK, Hsu YW, Chen CC, Lao HC, Huang CJ, *et al.* Ultrasound-guided ganglion impar block: A technical report. *Pain Med* 2010;11:390-4.
  14. Bhatnagar S, Khanna S, Roshni S, Goyal GN, Mishra S, Rana SP, *et al.* Early ultrasound guided neurolysis for pain management in gastrointestinal and pelvic malignancies: An observational study in a tertiary care center of urban India. *Pain Pract* 2012;12:23-32.

### Staying in touch with the journal

**1) Table of Contents (TOC) email alert**

Receive an email alert containing the TOC when a new complete issue of the journal is made available online. To register for TOC alerts go to [www.saudija.org/signup.asp](http://www.saudija.org/signup.asp).

**2) RSS feeds**

Really Simple Syndication (RSS) helps you to get alerts on new publication right on your desktop without going to the journal's website. You need a software (e.g. RSSReader, Feed Demon, FeedReader, My Yahoo!, NewsGator and NewzCrawler) to get advantage of this tool. RSS feeds can also be read through FireFox or Microsoft Outlook 2007. Once any of these small (and mostly free) software is installed, add [www.saudija.org/rssfeed.asp](http://www.saudija.org/rssfeed.asp) as one of the feeds.