

CASE REPORT

BEGINNER

CLINICAL CASE

A Rare Case of Mad Honey Disease

A Reversible Cause of Complete Heart Block



Saman Setareh-Shenas, MD, MS,^a Scott Kaplin, MD,^b Theodore C. Bania, MD,^c Robert Kornberg, MD^a

ABSTRACT

This case describes a patient with hypotension, bradycardia, and third-degree atrioventricular block following ingestion of a grayanotoxin-containing *Pieris* species, or lily of the valley bush. Although unlikely in metropolitan environments, physicians should be aware of the possibility of grayanotoxin ingestion when confronted with new-onset heart block even in nonendemic areas. (**Level of Difficulty: Beginner.**) (J Am Coll Cardiol Case Rep 2019;1:579-82) © 2019 The Authors. Published by Elsevier on behalf of the American College of Cardiology Foundation. This is an open access article under the CC BY-NC-ND license (<http://creativecommons.org/licenses/by-nc-nd/4.0/>).

HISTORY OF PRESENTATION

A 46-year-old homeless man was brought to a tertiary emergency department (ED) by local police officers after he was discovered demonstrating bizarre behavior in a subway station. When confronted by police, the patient reportedly told the police that he had eaten trees and could no longer see. When assessed for further symptoms, the patient had frontal headaches, nausea with 1 episode of vomiting, and vision abnormalities. He stated that before being brought to the ED he had seen vivid colors; however, this quickly resolved within 20 min after his arrival. Initial vital signs were notable for hypotension (76/58 mm Hg), bradycardia (36 beats/min), and hypothermia (95.9 °F). At physical examination, the patient

was laughing but appeared calm and not to be in acute distress. His lungs were clear to auscultation bilaterally. He was bradycardic but had a regular heart rhythm without any discernable murmurs or adventitious heart sounds. His lower extremities were notable for 1+ pitting edema bilaterally. The patient was awake, alert, and oriented to self and place and had no identifiable focal neurological deficits.

MEDICAL HISTORY

The patient did not provide any medical or psychiatric history that could be contributed to his condition.

DIFFERENTIAL DIAGNOSIS

The differential diagnosis for this patient's altered mental status, hypotension, bradycardia, and hypothermia was rather broad and included infectious (sepsis, meningitis), endocrine (hypothyroidism, adrenal insufficiency), and toxin-mediated etiologies (beta-blocker, non-dihydropyridine calcium channel blocker, digoxin, acetylcholinesterase inhibitors, and so on).

LEARNING OBJECTIVES

- To better understand the manifestations and management of grayanotoxin toxicity.
- To accentuate the importance of a thorough history and physical examination following a suspected toxic ingestion.

From ^aMount Sinai Heart, Icahn School of Medicine at Mount Sinai, St. Luke's Hospital and Mount Sinai West Hospital, New York, New York; ^bDepartment of Medicine, Icahn School of Medicine at Mount Sinai, St. Luke's Hospital and Mount Sinai West Hospital, New York; and the ^cEmergency Department, Division of Toxicology, Icahn School of Medicine at Mount Sinai, St. Luke's Hospital and Mount Sinai West Hospital, New York, New York. The authors have reported that they have no relationships relevant to the contents of this paper to disclose.

Informed consent was obtained for this case.

Manuscript received July 17, 2019; revised manuscript received September 11, 2019, accepted September 15, 2019.

ABBREVIATIONS AND ACRONYMS

AV = atrioventricular
ED = emergency department
ECG = electrocardiogram
ICU = intensive care unit

INVESTIGATIONS

The initial electrocardiogram (ECG) demonstrated third-degree atrioventricular (AV) block (Figure 1), which prompted a consultation with the cardiology service. Laboratory work-up, including complete blood count and cardiac enzymes, did not provide any additional clues into the patient's possible etiology. Imaging studies, including computed tomography of his head and bedside transthoracic echocardiography, were unremarkable.

MANAGEMENT

Because of the patient's hypotension, hypothermia, and confusion, treatment was initiated with a norepinephrine intravenous drip, as well as acyclovir, vancomycin, and ceftriaxone for possible meningitis. The patient was then transferred to the medical intensive care unit (ICU) for further management.

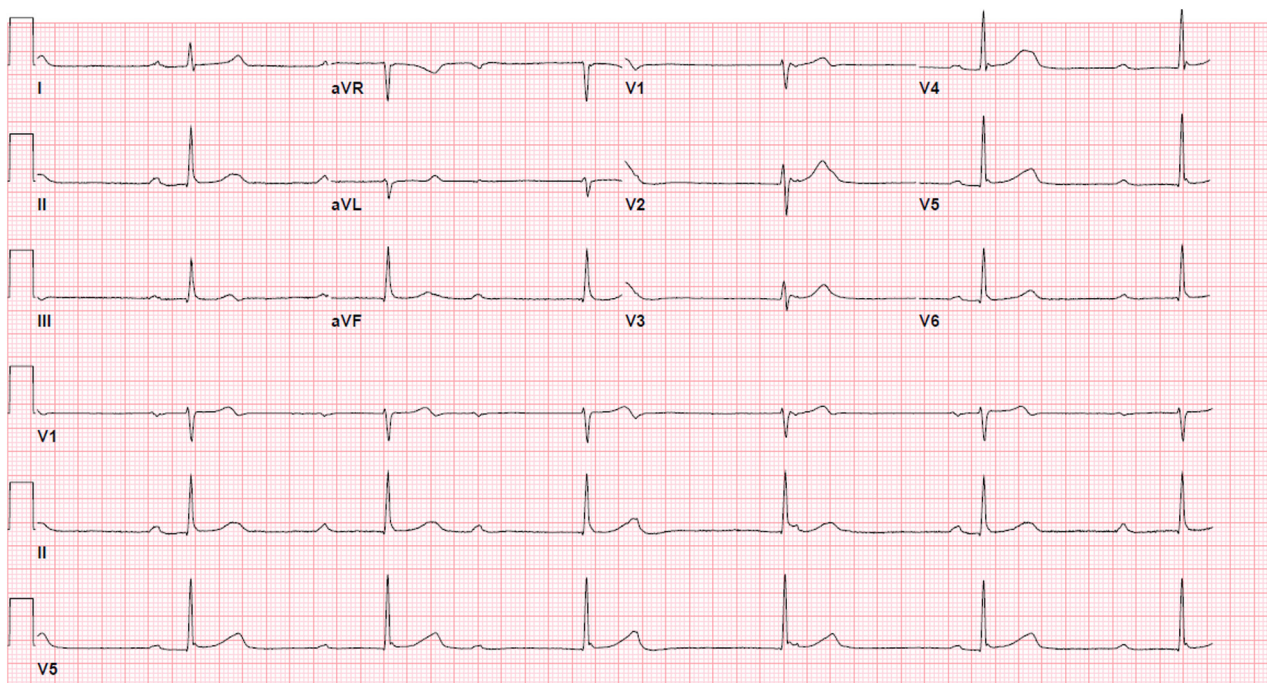
On arrival to the medical ICU, the patient's condition began to improve, and he was immediately

weaned off of norepinephrine. Over the following 2 h, his mental status recovered as well, and he was awake, alert, and oriented to person, place, and time. His ECG progressed from third-degree AV block to second-degree type I AV block in approximately 0.5 h and finally to sinus bradycardia within 2.5 h after the initial ECG. After further investigation of the patient's belongings, a bag was discovered containing plant material (Figure 2). The material was later identified as originating from a *Pieris* species, or lily of the valley bush, known to contain grayanotoxins. Because of the reversibility of the patient's condition following likely toxin exposure, the patient did not require a permanent pacemaker. Following a short hospitalization for monitoring, the patient was safely discharged with psychiatric follow-up.

DISCUSSION

This *Pieris* species, which is better known as lily of the valley bush, is an evergreen shrub that flowers in the summer and is grown in temperate climates

FIGURE 1 Initial ECG



The patient's initial electrocardiography (ECG) findings upon arrival to the emergency department consistent with third-degree atrioventricular block. This finding prompted consultation of the cardiology service for treatment guidance and is a common manifestation of grayanotoxin ingestion.

FIGURE 2 Discovered Plant Material



Upon further assessment of the patient's belongings with the patient's consent, a plastic bag was discovered that contained the plant. After consultation with the hospital's on-site toxicologist, it was determined that these plant materials likely were a *Pieris* species, better known as lily of the valley bush, which has previously been known to contain grayanotoxins.

in planting beds (1). The flower and leaves are known to contain grayanotoxins, which are also in a variety of other plants, including other *Kalmia* species (common name mountain laurel species), *Leudothoe* species (common name sweet bells), *Lyonia* species (common name fetter bush), *Pieris* species (common name lily of the valley bush), *Rhododendron* species (common name azalea or rhododendron). Honey produced from these species form grayanotoxins that can lead to sickness or even death. Grayanotoxins exert their toxic effects by binding to sodium channels, preventing their inactivation and leaving the cell in a depolarized, activated state (2). Most of the symptoms associated with grayanotoxin ingestion can be attributed to binding to sodium channels and to producing neurological and cardiac symptoms; the constellation of symptoms are commonly classified as mad honey disease. Symptoms include burning in the mouth, salivation, vomiting, diarrhea, and paresthesias. Patients may also complain of headache, muscle weakness, and dimness of vision (1). A previous case study on the cardiac effects of mad

honey disease attempted to identify the most common symptoms experienced following toxin ingestion (3). Of the patients included in the study, most (95%) presented with chief complaints of nausea, vomiting, dizziness, fainting, and sweating. Syncope (12%) and seizures (2%) were less frequent. Initial systolic blood pressure was 73.1 ± 12.7 mm Hg (range: 50 to 100 mm Hg), and diastolic blood pressure was 52.1 ± 11.3 mm Hg (range: 40 to 70 mm Hg). Mean heart rate was 38 ± 7 beats/min (range: 25 to 59 beats/min). On ECG, 43% of patients had sinus bradycardia, 36% had complete heart block, and 21% had a nodal rhythm. It should be noted that various types of grayanotoxins exist, with varying affinity for sodium channels within different areas of the conduction system. For example, grayanotoxin II has a predominant effect on the sinus node, whereas grayanotoxin I has affinity for both the sinus node and the AV node. Grayanotoxins can also bind to muscarinic receptors, which may present as supra-Hisian conduction abnormalities (4). This might explain why this patient's ECG demonstrated complete heart block with a narrow QRS complex. All patients were admitted to the cardiac ICU, and 95% of patients were treated with atropine with a good response. Generally, symptoms resolved within approximately 24 h, and mean hospital stay was 34 ± 20 h (range: 24 to 70 h).

CONCLUSIONS

This case described a patient with hypotension, bradycardia, and third-degree AV block following ingestion of a grayanotoxin-containing *Pieris* species, or lily of the valley bush. Although unlikely in the urban environment of New York City, a thorough history taking and physical examination was paramount for identifying the etiology of this patient's condition. Throughout the United States and around the world, increased use of natural substances may lead to more frequent patient presentations of this nature. Thus, physicians should be aware of the possibility of grayanotoxin ingestion when confronted with new-onset heart block even in non-endemic areas.

ADDRESS FOR CORRESPONDENCE: Dr. Robert Kornberg, Mount Sinai Heart, Mount Sinai West, 425 West 59th Street, Suite 9C, New York, New York 10019. E-mail: Robert.kornberg@mountsinai.org.

REFERENCES

1. Nelson LS. Handbook of Poisonous and Injurious Plants. 2nd edition. New York, NY: Springer, 2007.
2. Jansen SA, Kleerekooper I, Hofman ZL, Kappen IF, Stary-Weinzinger A, Van der heyden MA. Grayanotoxin poisoning: "mad honey disease" and beyond. *Cardiovasc Toxicol* 2012;12: 208-15.
3. Okuyan E, Uslu A, Ozan Levent M. Cardiac effects of "mad honey": a case series. *Clin Toxicol (Phila)* 2010;48:528-32.
4. Aliyev F, Türkoglu C, Celiker C, Firatli I, Alici G, Uzunhasan I. Chronic mad honey intoxication syndrome: a new form of an old disease? *Europace* 2009;11:954-6.

KEY WORDS complete heart block, grayanotoxins, sinus node dysfunction, third-degree AV block