

Nucleus management with Fishhook

A Hennig

The fishhook technique developed at the Lahan eye hospital is widely used in Nepal and other countries. Its specialty is the extraction of the nucleus with a bent 30-G needle (Fishhook) out of the capsular bag and the self-sealing tunnel. All sizes of nuclei can be extracted. The fishhook technique has a short learning curve, a low complication rate and provides excellent immediate visual outcome. It is cost-effective and has proved to be useful also for high-volume cataract surgery and thus can play an important role in the reduction of cataract blindness.

Key words: Fishhook, high volume cataract surgery, small incision cataract surgery

Indian J Ophthalmol: 2009;57:35-7

As an alternative to phacoemulsification, different sutureless non-phaco cataract surgical techniques were developed, where either the whole nucleus or the nucleus divided in parts, is removed through a self-sealing tunnel.^[1-5] One of these techniques is the fishhook technique.^[6-11]

The Fishhook Technique

The Lahan eye hospital is a busy hospital where only few ophthalmologists sometimes need to perform 300-400 cataract operations per day. Therefore there was need for a straightforward, fast, easy-to-learn and safe technique to achieve excellent results. The author first practiced the Blumenthal technique.^[1] The required anterior chamber (AC) maintainer and extra opening in the cornea were not very practical in the hospital's high-volume setting, where surgeons move between two to four tables.

Other manual small incision cataract surgery (MSICS) techniques, where the nucleus needs to be lifted into the AC before removal, were not favored because of the risk of corneal endothelial damage.

The MSICS techniques requiring two instruments in the AC, like the sandwich technique or the dissection of the nucleus inside the AC, were found difficult and dangerous, especially with big brown nuclei.

As an alternative, finally, the fishhook technique was developed in Lahan in 1997. Since 1998 the fishhook technique became the routine cataract surgical procedure. Till the end of 2006 more than 340,000 cataract surgeries have been performed in Lahan with this technique and in addition many in other eye centers around the world.

Tunnel construction and capsulotomy

The same principles of preparing the sclerocorneal tunnel apply

Sagarmatha Choudhary Eye Hospital, Lahan, G.P.O. Box 15108, Kathmandu, Nepal

Correspondence to Dr. A. Hennig, Sagarmatha Choudhary Eye Hospital, Lahan, G.P.O. Box 15108, Kathmandu, Nepal. E-mail: akhennig@gmx.net

Manuscript received: 26.01.07; Revision accepted: 24.04.07

to all MSICS techniques. Ideally, the tunnel should be placed at the steepest corneal meridian. The smaller the frown-shaped size of the tunnel and the farther it is placed from the limbus, the lower will be the surgically induced astigmatism. Very big brown nuclei in older patients may require an opening of 8 mm, whereas cataracts in younger patients need incisions only as large as the intraocular lens (IOL).

A linear capsulotomy can be performed or preferably a continuous curvilinear capsulorhexis (CCC), which guarantees the best IOL centration. The CCC needs to be large enough for the nucleus to get through.

Nucleus extraction

The uniqueness of the fishhook technique is the way of extracting the nucleus, done with a hook made from a 30-G needle [Fig. 1].

In case of a linear capsulotomy, a forceful hydrodissection is done to mobilize the nucleus. Then the nucleus is slightly lifted at the side of the tunnel.

In case of CCC, a gentle hydrodissection is performed beneath the remaining anterior capsule. The fluid pressure pushes a part of the nucleus out of the capsular bag. Then the elevated nucleus is rotated towards the tunnel [Fig. 2]. After injection of viscoelastics in front and behind the nucleus, the fishhook is carefully inserted between the nucleus and posterior capsule and the tip turned so that it inserts into the central lower nucleus. Without lifting the nucleus into the AC, it is just extracted out of the capsular bag and the tunnel [Figs. 3-5].

Finally, the remaining cortex is removed by hydroexpression and with the help of a Simcoe cannula and a posterior chamber IOL is inserted into the capsular bag.

Learning Curve and Outcome

As with all surgeries the fishhook technique also needs experience to be mastered, especially the insertion of the hook, the correct placement of the hook's tip into the nucleus and the nucleus extraction. At Lahan eye hospital, fellows and ophthalmologists undergoing surgical training learn these steps first with normal ab-externo cataract surgery before changing to tunnel surgery. Once they change from ab-externo

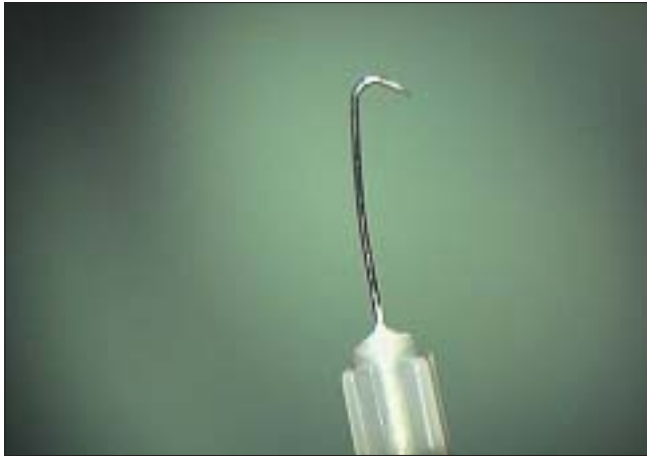

Figure 1: "Fishhook" made from a 30-G needle

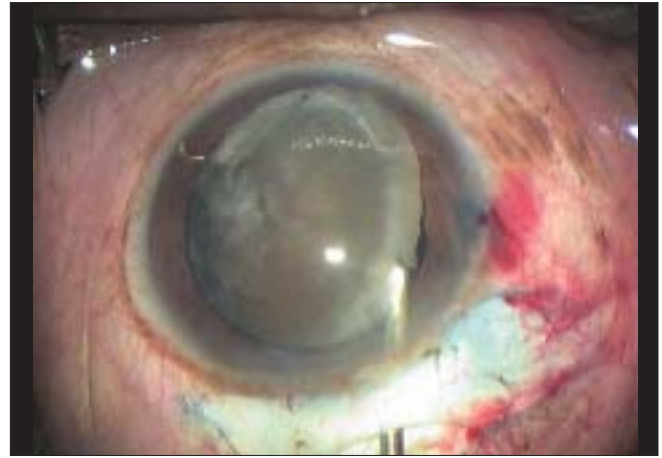


Figure 2: Mobilization of the nucleus

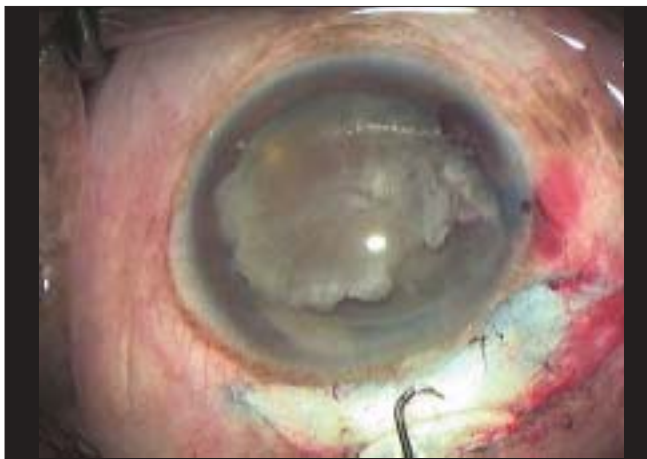

Figure 3: Fishhook before insertion

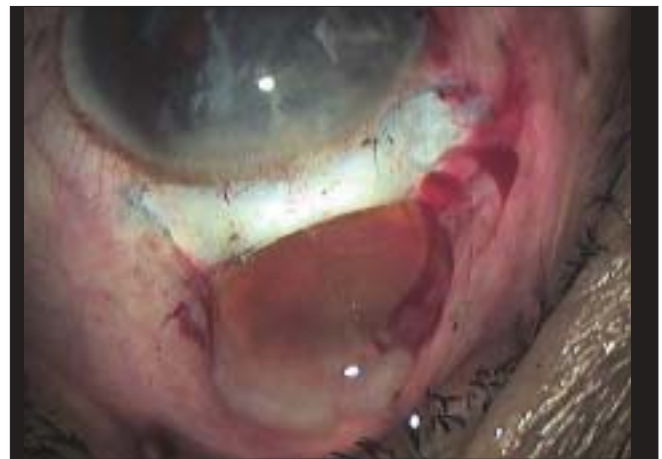

Figure 4: The Fishhook extracting the nucleus

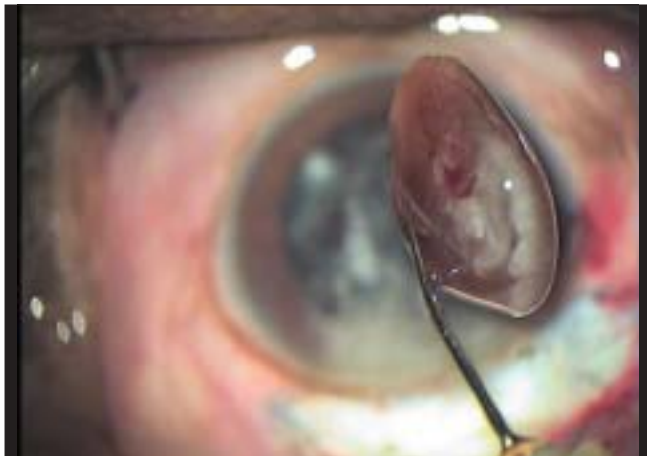

Figure 5: Extracted nucleus, side view

extracapsular to tunnel surgery, it requires about 20-30 assisted surgeries till they master the nucleus hook extraction through the tunnel. An evaluation of 26 fellows and ophthalmologists on surgical training shows that with a supervised stepwise approach the surgical complication rate is very low with

less than 3% posterior capsule rupture during their first 300 fishhook extractions. Also, the surgically related reasons (e.g. corneal edema and hyphema) for poor uncorrected visual acuity (<20/200) on the first postoperative day is 3.1% during the first 100 surgeries and decreases with more experience.

In the hands of experienced eye surgeons the fishhook technique provides excellent immediate uncorrected postoperative visual acuity.^[12] This is underlined by another outcome study on high-volume surgery, where six surgeons performed 2,111 sutureless cataract surgeries within six days.^[13]

Advantages of the fishhook technique

- Only one additional instrument is needed (Fishhook).
- The nucleus does not need to be brought into the anterior chamber. It is extracted with the hook out of the capsular bag straight through the self-sealing tunnel. Thus there is reduced risk for endothelial damage.
- Extracting the nucleus with the hook through the self-sealing tunnel requires a smaller tunnel size.
- All nuclei, even very big and hard ones can be extracted with the hook.

The fishhook technique has also proved to be suitable for

high-volume surgery. In our Lahan eye hospital experienced surgeons perform 15-20 cataract operations per hour.

Conclusion

The fishhook technique has proved to be easy to learn, fast and safe and provides excellent outcome. Therefore it can play a significant role in the reduction of cataract blindness.

References

1. Blumenthal M. Manual ECCE, the present state of the art. *Klin Monatsbl Augenheilkd* 1994;205:266-70.
2. Thomas R, Kuriakose T, George R. Towards achieving small-incision cataract surgery 99.8% of the time. *Indian J Ophthalmol* 2000;48:145-51.
3. Ruit S, Paudyal G, Gurung R, Tabin G, Moran D, Brian G. An innovation in developing world cataract surgery: Sutureless extracapsular cataract extraction with intraocular lens implantation. *Clin Exp Ophthalmol* 2000;28:274-9.
4. Natchiar G. Manual small incision cataract surgery. An alternative to instrumental phacoemulsification: Aravind Eye Hospital and Postgraduate Institute of Ophthalmology. 2nd ed. Madurai, India: 2004.
5. Sandford-Smith J. Sutureless cataract surgery: Principles and Steps. *Community Eye Health* 2003;16:49-53.
6. Hennig A, Singh V. Small Incision Cataract Surgery. In: Saxena S, editor. *Ophthalmic Surgery - The Cutting Edge*. New Delhi: Jaypee Medical Publishers; 2006. p. 259-71.
7. Hennig A. Sutureless non-phaco cataract surgery: A solution to reduce worldwide cataract blindness? *Community Eye Health* 2003;16:49-51.
8. Hennig A, Singh AK. SICS - Fishhook Technique. In: Sachdev MS, editor. *Techniques of Cataract Surgery*. New Delhi: Jaypee Medical Publishers; 2007. p. 3-7.
9. Hennig A, Sutureless Cataract Surgery with Nucleus Extraction: Fishhook Technique. In: Garg A, editor. *Step by Step, Manual Phaco (Manual Small Incision Cataract Surgery)*. New Delhi: Jaypee Medical Publishers; 2006. p. 61-74.
10. Hennig A. Sutureless cataract surgery with nucleus extraction - fishhook technique. In: Garg A, editor. *Clinical practice in small incision cataract surgery (Phaco Manual)*". New Delhi: Jaypee Medical Publishers; 2004. p. 417-21.
11. Hennig A. High volume cataract surgery at lahan eye hospital, Nepal - Management, Outcome and Cost. *Asia Pac J Ophthalmol* 2003;15:9-11.
12. Hennig A, Kumar J, Yorston D, Foster A. Sutureless cataract surgery with nucleus extraction: Outcome of a prospective study in Nepal. *Br J Ophthalmol* 2003;87:266-70.
13. Hennig A, Kumar J, Singh AK, Singh S, Gurung R, Foster A. World Sight Day and cataract blindness. *Br J Ophthalmol* 2002;86:830-1.

Source of Support: Nil, **Conflict of Interest:** None declared.