



Effect of intravenous infusion of iodinated contrast media on the coronary blood flow in dogs



Thura T. Abd^{a,*}, Asim I. Shafique^b, Hayder S. Yasir^c, Jung-Hee Seo^d, Richard T. George^a, Rajat Mittal^d, Albert C. Lardo^a

^a Division of Cardiology, Department of Internal Medicine, Johns Hopkins University School of Medicine, Baltimore, MD, United States

^b University of Maryland, College Park Campus, College Park, MD, United States

^c Baltimore Medical System, Baltimore, MD, United States

^d Department of Mechanical Engineering, Johns Hopkins University, Baltimore, MD, United States

ARTICLE INFO

Article history:

Received 19 March 2016

Accepted 2 May 2016

Available online 18 May 2016

Keywords:

Coronary flow

Isovue

Visipaque

Iodixanol

Iopamidol

Canine

Dogs

Intravenous

ABSTRACT

Background: Coronary computed tomography angiography (CCTA) is obtained using peripheral intravenous iodinated contrast agents (ICA) injection. There is continuing attempts to derive coronary physiological information like coronary blood flow (CBF) and/or fractional flow reserve from CCTA images. However, no data is available regarding the effect of peripheral intravenous injection of ICA on CBF.

Methods: A series of 4 experiments was performed using healthy mongrel dogs. All dogs underwent anesthesia and open thoracotomy with placement of ultrasound flowmeter to one of the coronary artery to provide real time absolute CBF measurements. Different infusion protocols of Isovue-370 and Visipaque-320 were injected into a peripheral vein. Similar doses of normal saline injection were performed to be used as controls. The effect of iodinated contrast media injection on absolute coronary blood flow was monitored and recorded.

Results: Injection of normal saline in the peripheral vein did not produce any significant increase in CBF. Peripheral intravenous injection of ICA resulted in a consistent increase of 40–73% in absolute CBF as recorded 5 minutes post-contrast administration. The contrast effect starts about 30 seconds and peaks at about 2 minutes post-contrast injection then slowly fades away in the following 10–15 min. The increase in the CBF was dose related. There was greater increase in the CBF to 50 ml infusion compared to 25 ml infusion of both Visipaque and Isovue.

Conclusions: Peripheral venous administration of iodinated contrast-media in dogs results in a dose related, significant and prolonged increase in CBF.

© 2016 Published by Elsevier Ireland Ltd. This is an open access article under the CC BY-NC-ND license (<http://creativecommons.org/licenses/by-nc-nd/4.0/>).

1. Introduction

Iodinated contrast media are the cornerstone agents used for radiographic vascular imaging. Coronary computed tomography (CT) angiography (CTA) is a radiographic imaging study in which CT images of the coronary artery are obtained after an intravenous injection of a contrast agent to opacify the coronary arteries. Over the past decade, Coronary CTA has been used increasingly for the diagnosis of coronary artery disease. This increased use has been the result of the significant advances in the technology of the coronary CTA including improving the spatial and temporal resolution and reducing radiation dose.

While coronary CTA is primarily an imaging modality to define coronary anatomy, there are continued efforts to derive physiological information of the coronary circulation from coronary CTA images. Examples

include myocardial CT perfusion (CTP) studies [1–4], fractional flow reserve (FFR) derived from coronary CT angiography (CTA) also known as CT-FFR [5,6] and Translumenal Attenuation Gradient (TAG) [7]. Our group recently described a new way to derive absolute coronary flow from coronary CTA images [8]. All those relatively new techniques are attempts to extract information about the coronary blood flow from static CTA images that are acquired following peripheral intravenous injection of iodinated-contrast.

Injection of iodinated contrast agents directly inside the coronary arteries in dogs [9] and humans [10,11] causes vasodilation and increase in coronary blood flow. However, no data is available regarding the effect of iodinated contrast agents on coronary blood flow when those agents are injected in the peripheral veins. This data is critical in order to guide further efforts to improve attempts to derive physiological information about the coronary artery from coronary CTA images.

In this study, we describe the effect on peripheral injection of two types of iodinated contrast media on absolute coronary blood flow in dogs.

* Corresponding author.
E-mail address: tabd1@jhmi.edu (T.T. Abd).

Table 1
Effect of peripheral intravenous contrast injection on absolute coronary blood flow in the first 3 dog experiments.

Dog number	Coronary artery	Contrast type	Contrast dose	Coronary flow (ml/min) at baseline (pre-contrast infusion)	Coronary flow (ml/min) at 5-minute post-contrast infusion	Percentage increase in absolute coronary blood flow
1st	LAD	Isovue	25 mL @ 2.5 ml/s	26	45	73%
2nd	LAD	Isovue	25 mL @ 2.5 ml/s	28	40	42%
3rd	LCx	Visipaque	25 mL @ 2.5 ml/s	54	76	40%

LAD: left anterior descending; LCx: left circumflex.

2. Materials and methods

A series of 4 experiments was performed using healthy mongrel dogs. All procedures were approved by the Johns Hopkins Animal Care and Use Committee. Each dog weighed between 25 and 30 Kg. Each dog fasted for 8 h prior to the study. These dog experiments were designed primarily to investigate the effect of peripheral intravenous injection of iodinated contrast agents on coronary blood flow. A secondary goal of the experiments was to correlate direct coronary flow measurement with a novel CT derived coronary blood flow measurement. Therefore, the first 3 dog experiments contrast injections were part of cardiac CT scanning protocol. However, the 4th dog experiment contrast injections were not associated with cardiac CT scanning to allow closer monitoring of contrast effect on coronary flow.

Pre-anesthesia sedation was provided by 3 mg of Acepromazine intramuscular injection. A peripheral IV was placed. The dogs were then anesthetized and intubated in the usual aseptic manner. Propofol was used for induction of anesthesia and Isoflurane at 0.5–2% was used for maintenance of anesthesia. Additionally, an 8 French sheath was placed in the right femoral artery. A pressure sensor was placed through the sheath for continuous pressure monitoring of the descending aorta.

2.1. Open thoracotomy and epicardial coronary artery instrumentation

A left lateral thoracotomy was performed with the dog positioned on the right side and ventilated mechanically. Following a blunt and sharp dissection, the pericardium was exposed and incised. Further dissection was performed to isolate a 5 cm segment of the proximal left anterior descending artery (LAD) (first and second dogs) or 5 cm segment of the proximal left circumflex (LCX) artery (3rd and 4th dogs). The LCX artery is usually double the size of the LAD and has twice the flow of the LAD. Once the LAD or the LCX was isolated, we placed an ultrasonic flow meter at the proximal part of the vessel for continuous coronary blood flow measurements.

2.2. Contrast agents

Visipaque 320 (Iodixanol) is a dimeric, isosmolar, nonionic, water-soluble, radiographic contrast medium with a molecular weight of 1550.20 g/mo. It has an osmolality of 290 mOsm/Kg water and iodine content of 320 mg/ml. It is made by GE Healthcare.

Isovue 370 is a monomer, hyperosmolar, nonionic, water-soluble contrast medium with a molecular weight of 777.08 g/mo. It has an osmolality of 796 mOsm/Kg water and iodine content 370 mg/ml. It is developed by Bracco Imaging, S.p.A.

2.3. Contrast injection protocol

The first 3 dog experiments were performed with the infusion of 25 ml of contrast at a rate of 2.5 ml/s. Isovue was used in the first and second experiment while Visipaque was used in the third. For the first and second dog experiments, the coronary flow values were recorded before and 5-min after contrast administration.

In the 3rd dog experiment, coronary flow values were also recorded before and 5-min after contrast administration. However, two additional Visipaque 25 ml injections at a rate of 2.5 ml/s at about 10-minute

intervals were given in order to examine the additive effect of multiple contrast injections on coronary blood flow. Coronary blood flow measurements were recorded continuously as well as before and after each injection.

For the 4th dog experiment, we sequentially infused different doses of Isovue, Visipaque and normal saline. At each injection we recorded baseline coronary flow and post-contrast injection coronary flow every 30 s until the coronary flow returned to the pre-injection baseline value. We used two contrast doses: 25 ml at 2.5 ml/s and 50 ml at 2.5 ml/s. We repeated the experiment sequentially using Isovue, Visipaque and normal saline. Normal saline was used as a control. The effect of each contrast injection protocol on coronary flow was graphed across time. The magnitude of coronary flow change was indexed per baseline flow and compared to different contrast injection protocols.

3. Results

Injection of normal saline in the peripheral vein did not produce any significant increase in the coronary blood flow. In the first 3 dog experiments, peripheral intravenous injection of contrast (Visipaque or Isovue) resulted in a consistent increase of 40–73% in absolute coronary blood flow as recorded 5 minute post-contrast administration (Table 1). The 4th dog experiments revealed that the contrast effect starts about 30 s and peak at about 2 minute post-contrast injection then slowly fades away in the following 10–15 min. (Fig. 1). The increase in the coronary blood flow in response to peripheral contrast injection was dose related. There was greater increase in the coronary blood flow to 50 ml infusion compared to 25 ml infusion of both Visipaque and Isovue (Fig. 1). Furthermore, multiple consecutive injections of contrast resulted in additive effects resulting in 133% increase in the absolute coronary flow for Visipaque and 100% for Isovue. (Figs. 2 and 3).

4. Discussion

In this study, we examined the effect of intravenous administration of iodinated contrast media (Isovue and Visipaque) into a peripheral vein on the coronary blood flow in dogs. The study shows that there is a significant increase of moderate intensity (40–73%) in coronary

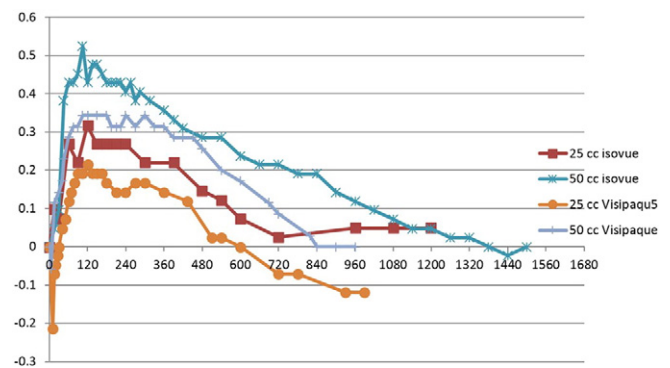


Fig. 1. Shows graphical representation of the effect of different doses of intravenous injection of Isovue and Visipaque on coronary flow over time in the left circumflex artery from dog experiment #4. X axis is time in seconds; Y axis is percentage change of blood flow compared to baseline.

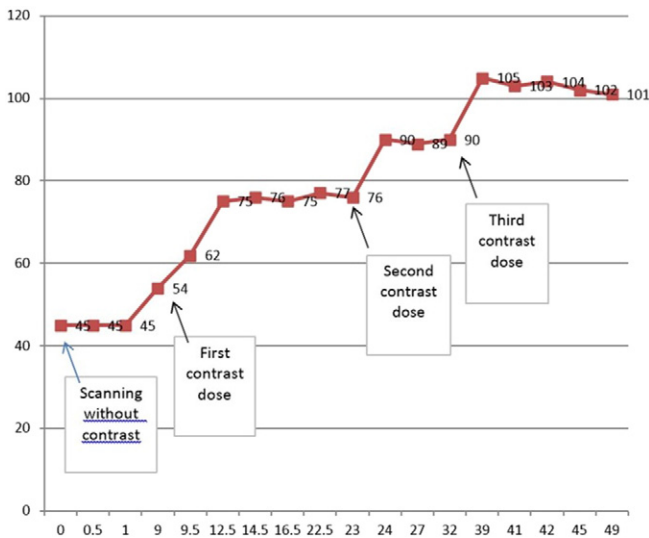


Fig. 2. Left circumflex blood flow in dog #3 in response to every 10 min of intravenous injection of 25 cm³ of Visipaque for a total of 3 injections. X axis in minutes. Y axis is flow in ml/min. There is a cumulative increase in coronary flow with multiple sequential injection of contrast. X axis is time in minutes with zero time is the time of the first scan. Y axis is the flow as detected by the ultrasound flow meter measured in ml/min.

blood flow 5 minutepost-intravenous contrast infusion. Additionally, the response appears to be dose related and cumulative with repeated contrast injections increasing coronary blood flow up to 133% of baseline.

Iodinated contrast media is known to cause vasodilation and increase in coronary blood flow after a direct intra-arterial injection in both human [10,11] and dogs [9]. Narishige et al. study found a dose response increase in coronary flow to 50% with 1 ml and 80% with 3 ml intracoronary injection of Iopamidol (Isovue) and Iomeprol, respectively. The positive effect of contrast media on coronary flow in Harishige study was short and lasted for about 1.5 min. Steiner RM et al. found a 60% increase in femoral artery blood flow following an intra-arterial injection of Iopamidol (Isovue) compared to about 100% increase with Conray (Iothalamate) 280 contrast agent in dogs. The effect of Iopamidol peaked at 30 secondpost-injection and faded slowly over 2 minutepost-injection [12].

Our study findings are consistent with prior literature. The magnitude of increase of coronary flow was dependent on the dose and type of contrast media used and overall ranged between 40 and 73% after single injection. However, multiple cumulative injections of Isovue and Visipaque caused much more robust increase in coronary flow up to 100% for Visipaque and 133% for Isovue. Even more striking is that the duration of the contrast-induced hyperemic response is much larger than what has been reported in the literature. As seen in Fig. 1, a hyperemic response lasted for about 12 min after 25 ml of Isovue and Visipaque injection, while a 50 ml of injection of Isovue had an effect

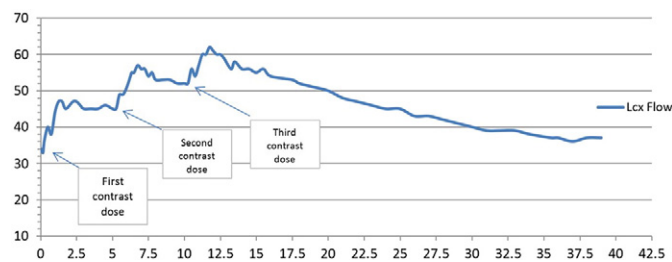


Fig. 3. Left circumflex blood flow in dog #4 in response to every 5 minute injection of 25 cm³ of Isovue for a total of 3 injections. There is a cumulative positive response of increased blood flow with each injection. X axis is time in minutes. Y axis is absolute coronary flow in the LCx artery.

that last to 22 min before coronary flow returned to baseline. Such a prolonged effect of contrast induced hyperemic response in our study is likely because of the relatively large bolus of contrast (about 1 cm³/kg per dog weight) and possible recirculation of the contrast media in the blood system exposing the coronary vasculature to a longer period of contrast compared to a small intra coronary injection.

To our knowledge this is the first study to report on the effect of intravenous iodinated contrast injections on coronary blood flow in dogs. Prior studies looked only at the effect of direct intra-arterial (not intravenous) contrast injection on coronary diameter and flow which is relevant to invasive coronary angiography. They showed a mild increase in coronary diameter and flow in response to direct intracoronary injection [10,13,14].

The mechanism by which iodinated contrast media increases vascular blood flow has been described and is thought to be related to vasodilation. The exact mechanism that underlies contrast agent-induced vasodilation remains to be fully elucidated, but it is thought to be the result of direct action on the vascular smooth muscle that involves modulation of Na⁺/K⁺ ATPase, intracellular Ca²⁺ sequestration and/or Na⁺/H⁺ exchange [15,16].

The rapidly expanding use of coronary CTA in which contrast enhanced images of the coronary arteries are obtained after an iodinated contrast media is injected through a peripheral vein calls for further understanding of the interaction of the intravenous contrast agent with the coronary flow. The arrival of the contrast agent to the coronary circulation is likely to cause changes to the coronary vascular tree, yet the nature of these changes and their impacts on cardiac CT images have not been described before, whether in dogs or humans. The effect of intravenous injection of iodinated contrast agents on coronary flow is even more critical in myocardial CT perfusion (CTP) studies. In myocardial CTP studies, achieving maximal hyperemia is essential in producing a diagnostic quality studies. Usually, this is achieved by using adenosine or dipyridamole infusion which is usually time consuming and requires special nursing skills. Further understanding of the contrast agent's hyperemic effects might help simplify the myocardial CTP protocols by getting rid of the need for adenosine or dipyridamole infusion as a result of optimizing the hyperemic response of the contrast agent.

5. Conclusion

Peripheral venous administration of iodinated contrast-media in dogs results in a dose related, significant and prolonged increase in coronary blood flow. Larger studies are needed to confirm these findings and evaluate if a similar effect is present in humans.

Conflict of interest

The study was funded by a grant from Toshiba Medical System Corporation.

R.M. and A.C.L. are named inventors on patents in the area of contrast agent gradient-based assessment of bloodflow. R.M. and A.C.L. have other significant financial interests in technologies associated with contrast agent gradient-based flow assessment.

The authors report no relationships that could be construed as a conflict of interest.

References

- [1] R.T. George, C. Silva, M.A. Cordeiro, et al., Multidetector computed tomography myocardial perfusion imaging during adenosine stress, *J. Am. Coll. Cardiol.* 48 (1) (2006) 153–160.
- [2] C.E. Rochitte, R.T. George, M.Y. Chen, et al., Computed tomography angiography and perfusion to assess coronary artery stenosis causing perfusion defects by single photon emission computed tomography: the CORE320 study, *Eur. Heart J.* 35 (17) (2014) 1120–1130.
- [3] M. Rief, E. Zimmermann, F. Stenzel, et al., Computed tomography angiography and myocardial computed tomography perfusion in patients with coronary stents:

- prospective intraindividual comparison with conventional coronary angiography, *J. Am. Coll. Cardiol.* 62 (16) (2013) 1476–1485.
- [4] N. Bettencourt, A. Chiribiri, A. Schuster, et al., Direct comparison of cardiac magnetic resonance and multidetector computed tomography stress–rest perfusion imaging for detection of coronary artery disease, *J. Am. Coll. Cardiol.* 61 (10) (2013) 1099–1107.
- [5] J.K. Min, J. Leipsic, M.J. Pencina, et al., Diagnostic accuracy of fractional flow reserve from anatomic CT angiography, *JAMA* 308 (12) (2012) 1237–1245.
- [6] B.L. Nørgaard, J. Leipsic, S. Gaur, et al., Diagnostic performance of noninvasive fractional flow reserve derived from coronary computed tomography angiography in suspected coronary artery disease: the NXT trial (analysis of coronary blood flow using CT angiography: next steps), *J. Am. Coll. Cardiol.* 63 (12) (2014) 1145–1155.
- [7] D.T. Wong, B.S. Ko, J.D. Cameron, et al., Transluminal attenuation gradient in coronary computed tomography angiography is a novel noninvasive approach to the identification of functionally significant coronary artery stenosis: a comparison with fractional flow reserve, *J. Am. Coll. Cardiol.* 61 (12) (2013) 1271–1279.
- [8] A.C. Lardo, A.A. Rahsepar, J.H. Seo, et al., Estimating coronary blood flow using CT transluminal attenuation flow encoding: formulation, preclinical validation, and clinical feasibility, *J. Cardiovasc. Comput. Tomogr.* 9 (6) (2015) 559–566 (e1).
- [9] T. Narishige, K. Egashira, Y. Akatsuka, T. Takahashi, A. Takeshita, Effects of iomeprol, a new nonionic contrast medium, vis a vis iopamidol and nitroglycerin, on coronary diameter and blood flow in chronically instrumented dogs, *Cardiovasc. Intervent. Radiol.* 16 (6) (1993) 343–347.
- [10] H. Emanuelsson, S. Holmberg, K. Selin, F. Waagstein, Effects of iohexol and metrizoate on myocardial blood flow and metabolism, *Acta Radiol. Suppl.* 366 (1983) 121–125.
- [11] S. Tatineni, M.J. Kern, U. Deligonul, F. Aguirre, The effects of ionic and nonionic radiographic contrast media on coronary hyperemia in patients during coronary angiography, *Am. Heart J.* 123 (3) (1992) 621–627.
- [12] R.M. Steiner, R.G. Grainger, N. Memon, D. Weiss, P.B. Kanofsky, H. Menduke, The effect of contrast media of low osmolality on the peripheral arterial blood flow in the dog, *Clin. Radiol.* 31 (6) (1980) 621–627.
- [13] P. Dawson, Cardiovascular effects of contrast agents, *Am. J. Cardiol.* 64 (9) (1989) E2–E9.
- [14] S. Egashira, H. Tomoiike, H. Nishijima, H. Adachi, M. Nakamura, Effects of ionic and nonionic contrast media on coronary diameter and blood flow in chronically instrumented dogs, *Am. Heart J.* 118 (1) (1989) 39–46.
- [15] N. Pugh, J. Karlsson, Vasodilator and hemorheological effects of iodinated contrast media, *Medicamentos de actualidad.* 33 (3) (1997) 191–203.
- [16] M. Pitman, J. Karlsson, T. Griffith, Ionic mechanisms contributing to the vasorelaxant properties of iodinated contrast media: a comparison of iohexol and iodixanol in the rabbit isolated aorta, *Br. J. Pharmacol.* 119 (4) (1996) 685–690.