


Anatomical Study of the Innervation of the Masseter Muscle and Its Correlation with Myofascial Trigger Points

This article was published in the following Dove Press journal:
Journal of Pain Research

Roberto Procópio Pinheiro
Matheus Aquesta Gaubeur 
Ana Maria Itezerote
Samir Omar Saleh 
Flávio Hojaj 
Mauro Andrade 
Alfredo Luiz Jacomo 
Flávia Emi Akamatsu 

Department of Surgery, Laboratory of Medical Research—Division of Human Structural Topography, Faculty of Medicine of the University of São Paulo (FMUSP), São Paulo, SP, 01246903, Brazil

Background and Purpose: Myofascial pain syndrome (MPS) is widely prevalent in the general population; some reports estimate its prevalence ranges from 9 to 85%. Among the different locations where MPS may arise, pain related to the masseter muscle is referred as masticatory myofascial pain. MPS is characterized by myofascial trigger points (MTPs), which represent tender anatomical areas of a muscle where painful symptoms are elicited whenever stimulated. Previous publications have found MTPs to coincide with neuromuscular junctions at the motor end plate, at the innervation zone (IZ). Our study aimed to describe the innervation of the masseter muscle and relate it to clinically described myofascial trigger points (MTPs).

Materials and Methods: We mapped the nerve fiber distribution into the masseter muscles from 16 cadavers by anatomical dissection. We divided the muscle into six regions, three superior (I–III) and three inferior (IV–VI), and classified the nerve's branches distribution according to these predetermined areas. Statistical analyses was made by Poisson distribution and logarithm link function followed by Bonferroni multiple comparisons ($P < 0.05$).

Results: All six areas received branches from the masseteric nerve. Areas I and II (upper posterior and upper intermediate, respectively) had a significant higher number of nerve entries as compared to the remaining areas.

Conclusion: The penetration areas of the masseteric nerve have been established and MTPs are found in the innervation zones, clinicians should focus initially on the regions of the penetration points, for diagnostics and therapeutic measures, such as injections, dry needling and soft tissue interventions. Anatomical study of nerve supply to the masseter muscle can provide useful additional knowledge to further understanding masticatory myofascial pain and to direct therapeutic interventions and diagnostic studies of temporomandibular junction dysfunction.

Keywords: pain, masseteric nerve, innervation zone, anatomy

Introduction

Musculoskeletal problems are responsible for most cases of chronic pain and myofascial pain syndrome (MPS) and affect 13.5–47% of the general population.¹ The prevalence of MPS in clinical populations varies widely, ranging from 9–85%.^{2–4} Myofascial trigger points (MTPs) are associated with MPS.^{5,6} Clinically, MTPs are identified by palpation of a taut band of muscle or fascia characterized as hyperirritable nodules^{2,7,8} and limited range of motion in the joints, referred pain and local twitch response during mechanical stimulation of MTPs.^{7,8}

Correspondence: Flávia Emi Akamatsu
Tel +55 11 971515516
Fax +55 11 30618277
Email flaea@usp.br

According to the International Association for the Study of Pain,⁹ few studies have investigated the prevalence or incidence of MTPs in the general population. Different studies have shown that MTPs are associated with many pain conditions, such as tension-type headache, temporomandibular disorder, mechanical neck pain,^{10,11} shoulder pain, epicondylalgia, carpal tunnel syndrome, low back pain, pelvic pain, knee pain, ankle pain, post mastectomy pain, cervical and lumbar radiculopathy and fibromyalgia. The pathophysiology is not yet fully understood.⁹

The orofacial region is one of the most frequent locations for chronic pain, with a prevalence of 10–26% worldwide.^{12,13} The most common diagnosis of temporomandibular disorders (TMDs) is masticatory muscle pain and myalgia.¹⁴ The masseter muscle has been implicated in masticatory myofascial pain¹⁵ and has clinical significance for TMD, bruxism, and hypertrophy.¹⁶ Symptoms of TMD are highly prevalent and affect approximately 5–10% of the population.¹⁷

The masseter muscle plays an important role in jaw elevation and is the major contributor to jaw closure strength¹⁸ and its size is closely associated with bite force.^{19,20} Masseter is a rectangular multipennate muscle, that attaches proximally to the inferior margin on the medial surface of the maxillary process of the zygomatic bone and to the zygomatic arch. Its distal insertion occurs at the angle and lateral face of the mandible ramus. Its innervation is performed by the masseteric nerve, a branch from the trigeminal nerve (V cranial nerve).^{20,21}

Travell and Simons⁷ first described MTPs based on clinical observations, subsequently supported by additional studies implying MTPs as the source of musculoskeletal pain.⁸ Physiopathology of the MPS is associated to dysfunction of the motor endplate zone,^{7,8,22,23} innervation zone (IZ),^{22–26} the region where the α -motor neuron divides into a number of branches and supplies the muscle.^{22–26}

Recently, a study reported a coincident distribution of intramuscular nerves on trapezius muscle with MTPs, demonstrating the close anatomical relationship between MTPs and motor end plates,²⁷ supporting the hypothesis that IZ dysfunction can be a cause for trigger point development and, in addition, MTPs have been correlated to anatomical areas previously described in clinical reports.^{28,29}

Our study aimed to describe the distribution of the masseteric nerve branches into the masseter muscle and relate it to myofascial trigger points (MTPs).

Materials and Methods

Ethical Aspects

This study was approved by the Ethics Committee of the Medical School for the Analysis of Research Projects Protocol No. 106/14.

Anatomical Technique

Thirty-two masseter muscles from 16 human adult cadavers (six males and 10 females) were dissected to expose the branches of the masseteric nerve and their point of entry into the masseter muscle. The cadavers were previously fixed using a 4% phenolic acid and 0.5% formaldehyde solution and were obtained from a body donation program undertaken by the Discipline of Human Structural Topography of the Department of Surgery of the University of São Paulo Medical School. Specimens with no sign of previous surgical manipulation or any other visible abnormality in the regions of interest were included. The masseter muscles were carefully dissected from their origins to observe the exact point where nerve fibers penetrated the muscle belly to be further compared to the corresponding MTPs areas over the muscle surface. As muscle size varies among individuals, we calculated the relative entry point of the nerve into the muscle by defining six different areas in the muscle belly: three superior (I–III) and three inferior ones (IV–VI) taken from the posterior margin of the muscle. The cadavers were placed in supine position and topographic dissection of the masseteric region. The skin was reflected after incisions over the anterior margin of the masseter muscle, the lower margin of the zygomatic arch and the lower margin of the mandible angle and body. The dissection was performed in successive layers. The skin, subcutaneous cellular tissue, superficial aponeurotic muscle system (SMAS), and the parotid gland with its fascia were reflected. The masseter muscle insertions were identified and divided, carefully preserving its neurovascular pedicle. The masseteric nerve was identified and dissected from the mandible notch to its branching and penetration into the masseter muscle.

Masseter Muscle Measurements

The following dimensions were measured: superior transverse (A), greater muscular dimension near the inferior margin of the zygomatic bone maxillary process, and zygomatic arch; lower transverse (B), and greater muscular dimension close to the mandible angle. A longitudinal

line (C) was defined and measured between the midpoints of the upper and lower transverse lines of the masseter muscle. The middle transverse line (D) was defined from the midpoint of the longitudinal line and parallel to the upper transverse line (Figure 1).

Sextant Delimitations

The penetration points of the masseteric nerve into the muscle were measured in relation to the median and longitudinal transverse measurements, delimiting an abscissa and ordinate cartesian plane, respectively. As these values vary according to muscle size, the relative values of the penetration point in relation to the median and longitudinal transverse dimensions were calculated. Thus, these dimensions make up 100% of the muscle size, while muscle insertion values make up the relative value. By convention, the following were adopted: the intersection of the axes as the origin and zero point; upper anterior quadrant with positive ordinate and abscissa; lower posterior quadrant with ordinate and negative abscissa; upper posterior quadrant with negative and positive ordered abscissa; and lower anterior quadrant with positive abscissa and negative ordered (Figure 2A).

The data were grouped into categories, forming six areas of distribution to facilitate clinical correlation. The middle transverse line separated the upper and lower areas and was divided into three equally sized segments. On

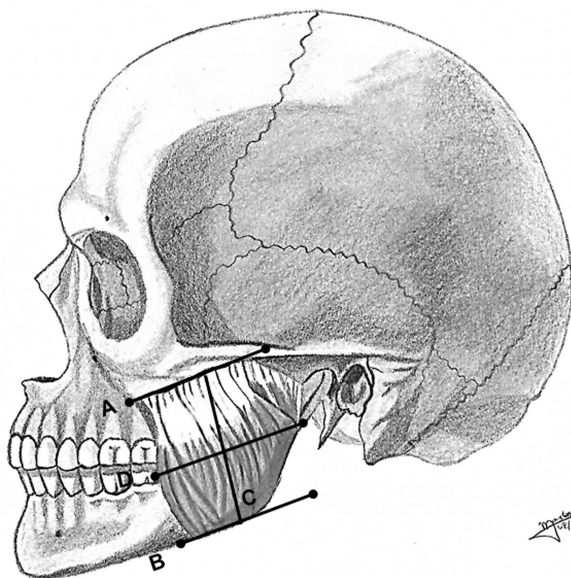


Figure 1 Dimensions of the masseter muscle in relation to segments: (A) superior transverse; (B) lower transverse; (C) longitudinal line of the masseter muscle; and (D) middle transverse line.

Note: Figure courtesy of Marcos Vinicius de Oliveira.

these three segments, perpendicular lines were drawn according to Figure 2B. The areas were numbered from I–VI, with I–III being superior and in the posterior to anterior direction, respectively. Additionally, IV–VI are inferior from posterior to anterior.

The points of entry of the branches of the masseteric nerve into the muscle were indicated with pins and documented photographically by means of a Nikon D52 camera (Nikon Corporation; Tokyo Japan). Penetration points were measured in relation to the median longitudinal and transverse axes by simple division of values and classified according to the numbered area from I–VI (Figure 2C).

Statistical Analysis

Sample Size

During the first four procedures, the maximal variability of the entry points of the masseteric nerve in each area of interest selected was 1.25. Estimating that at least one additional entry point could be found into the most innervated area as compared to the least one, a calculated sample of 16 cadavers was established to have a power and confidence of 75 and 95%, respectively. As our findings demonstrated a variation wider than one entry point, our sample reflects the expected results from a larger population.

Muscle dimensions were compared between gender using Student's *t*-test.³⁰ Muscle entry points were described according to gender and compared using the Mann–Whitney test, and the comparison of points between the sides was made by paired Wilcoxon test.³⁰

The number of points related to each one of the areas analyzed was described and compared between the areas. For the sextant analysis, generalized estimation equations with Poisson distribution and logarithm function³¹ followed by Bonferroni³² multiple comparisons test were used to evaluate the number of entry points of the masseteric nerve into each sextant. IBM-SPSS for Windows version 20.0 software was used to perform the analysis, and Microsoft Excel 2003 software was used to tabulate the data. Data are presented as the mean±standard deviation, and the level of significance was adjusted to 5% ($P<0.05$) for all tests.

Results

The cadaver age ranged from 43–95 years (mean=78.9 years). Their approximate heights measured 1.54–1.90 cm with an average of 1.71 cm. The weight ranged from 45–90 kg (average of 65.2 kg); BMI (body mass index) ranged from 17.3 kg/m² to 31.2 kg/m², with a mean of

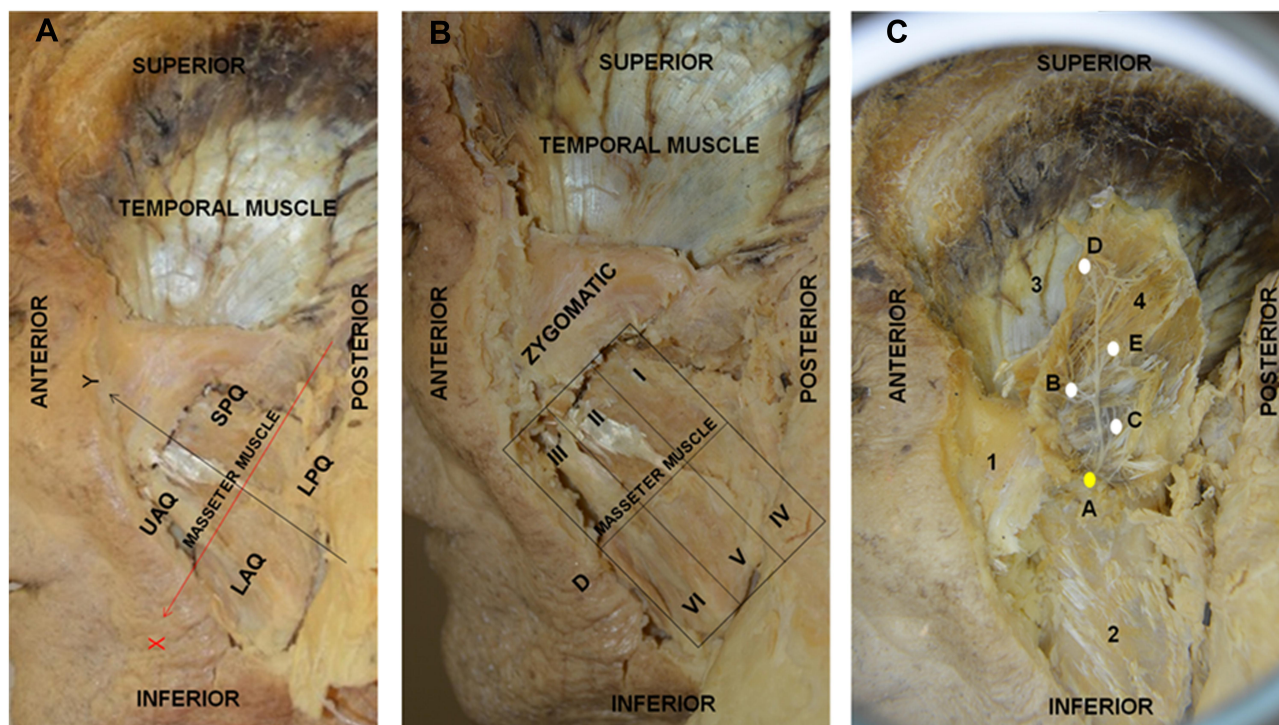


Figure 2 (A) Left side view of the face. Orientation of the abscissa (x) and ordinate (y) of the left masseter. By convention: upper anterior quadrant (UAQ) with positive ordinate and abscissa; lower posterior quadrant (LPQ) with negative ordinate and abscissa; superior posterior quadrant (SPQ) with negative and positive ordinate abscissa; and lower anterior quadrant (LAQ) with positive and negative ordinate abscissa; (B) Left side view of the face. Sextant of the left masseter muscle for localization of the penetration points of the masseteric nerve. D: The middle transverse line separates the upper and lower areas divided into three equally sized segments. The areas are numbered from I–VI, where I–III are superior and IV–VI are inferior in the posterior to anterior direction, respectively; (C) Left side view of the face. 1) zygomatic bone; 2) jaw; 3) temporal muscle; 4) folded masseter muscle. A) Masseteric nerve indicated in yellow; B, C, D and E indicate the branches of the masseteric nerve entering the masseter muscle in white.

22.1 kg/m². Fifteen specimens were Caucasian and one Asian (Table 1).

In our dissections, the masseteric nerve consistently crossed the extension of the masseter muscle from its posterior superior angle towards the anterior inferior angle and branches from the nerve emerged throughout its extension to supply the masseter muscle.

Comparing right and left masseter dimensions according to gender regarding superior transverse (A), inferior transverse (B), longitudinal (C), and median transverse (D) lines, as shown in Table 2, no differences were found between female and male cadavers ($P>0.05$) (Table 2).

All entry points located in the muscle belly in all cadavers were identified as innervations points of the masseteric nerve in the masseter muscle. The number of entry points of the masseteric nerve branches in the masseter muscle was statistically equal between genders and did not differ statistically between right and left sides (Table 3).

We found that sextants presented a significant difference according to the number of entry points of the masseteric nerve among them ($P<0.001$; Figure 3; Table 4).

Areas I and II were observed as targets for a higher number of nerve branches. Whereas area I did not significantly differ from area II ($P=0.433$), statistical analysis showed area I to have a significant higher number of entry points than areas IV and VI ($P=0.002$ and $P=0.030$, respectively), and area II presented statistically more points than all other areas (III, IV, V, VI) ($P<0.05$).

As the observed difference was higher than the expected difference estimated in sample size calculation, it is possible to infer that the results are to be expected from wider populations.

Discussion

Previous studies have reported the nerve supply of the masseter muscle and described the branching of the masseteric nerve.^{33–35} Our report was based on the premise that masseteric nerve entry points into the muscle may have a close anatomical relationship with known myofascial trigger points (MTPs) related to painful disorders of the facial region. This hypothesis was supported by

Table 1 Description of the Characteristics of Cadavers

Variables	Description
	(N=16)
Age	
Mean±SD	78.9±14
Median (min; max)	83 (43; 95)
Gender, n (%)	
Female	10 (62.5)
Male	6 (37.5)
Race, n (%)	
White	15 (93.8)
Yellow	1 (6.3)
Height (m)*	
Mean±SD	1.71±0.11
Median (min; max)	1.7 (1.54; 1.9)
Weight (kg)*	
Mean±SD	65.2±13.9
Median (min; max)	68 (45; 90)
BMI (kg/m ²)*	
Mean±SD	22.1±4
Median (min; max)	21.6 (17.3; 31.2)

Note: *Only 10 cadavers have information available.

Abbreviations: SD, standard deviation; BMI, body mass index.

previous investigations on the innervations of the trapezius, gluteus maximus and abductor hallucis muscles.^{36–38}

Even there was any indication that MTPs were always in the same location we considered the frequently observed indication of MTPs by Travell and Simons⁷ and Simons et al,⁸ because there is not any other data about this location in Masseter muscle. Travell and Simons⁷ and Simons et al⁸ described trigger areas and MTPs in the superficial layer of the masseter muscle: two insertion points near the superior tendon junction, two points in the middle, and two in the lower portion near the insertion. There is also an MTP in the posterosuperior portion of the deep layer below the temporomandibular joint.

Nerves induce muscle contraction by electrical impulses which release acetylcholine in the motor end plates, usually located near the middle of the muscle fiber.³⁹ Some authors suggest excessive release of acetylcholine in the end plates to be the primary factor involved in MTPs development.^{7,–8,–22–26}

Excessive release of neurotransmitter causes neurogenic inflammation and interacts with dysfunctional endplates, shortening the sarcomere and triggering muscle band formation. These bands, latent in asymptomatic

individuals, are activated as a response to predisposing factors and develop active MTPs.⁴⁰ Increased acetylcholine concentration in the synaptic cleft, acetylcholine receptor changes, and changes in acetylcholinesterase activity are consistent known mechanisms of endplate dysfunction and may explain the increase in endplate electrical activity that is seen in active MTPs.⁴¹

Once activated, MTP is associated with multisystem disorder, especially vascular and neurological dysfunction.^{40,41}

A statement from the International Association for the Study of Pain in 2017⁹ listed neurotransmitters, neurosensory and electrophysiological characteristics, and motor dysfunctions among the causes of MTPs. Even though their physiopathology is not clear, these changes occur through signals transmitted by the nerves.⁹

In fact, some authors established a clear distribution map of intramuscular nerves and suggested that IZ dysfunction is responsible for trigger point development.^{27–29}

As for the upper portion of the trapezius muscle, MTPs distribution follows the MTP chart proposed by Simons and Travell^{27,28} suggesting that MTPs, at least in some cases, have a close relationship with nerve branches distribution.²⁷

Thus, considering the correlation between innervations and MTPs, there is a possible anatomical link between nerve entry points and MTPs which could be observed by comparing the clinically described location of MTPs to the nerve branch distribution to the correspondent muscle. In painful facial disorders in which the masseter muscle is involved, identification of the pattern of the masseteric nerve branching may provide support for clinical identification of MTPs and targets for therapeutic approaches.

In our dissections, we studied the nerve supply of the masseter muscle in six topographic areas according to previous reports^{36–38} and entry points of the masseteric nerve were found in all sextants of the muscle, although more prevalent in its upper half.

Considering the surface anatomy of the masseter muscle, our anatomical findings were similar to the location of the MTPs as described by Travell and Simons⁷ and by Simons et al.⁸ It is noteworthy that, unlike descriptions for the trapezius muscle,^{27–29} there is no available reference to the anatomical distribution of MTPs regarding the masseter muscle to compare to its nerve supply.

Haddad et al⁴² divided the surface facial area over the masseter muscle into nine areas and observed the presence

Table 2 Description of Masseter Measurements by Sex

Variables	Gender		Total (N=16)	P
	Female (N=10)	Male (N=6)		
Right masseter muscle				
A Mean±SD Median (min.; max.)	4.39±0.89 4.55 (2.72; 5.5)	3.87±0.68 3.73 (3.13; 5)	4.19±0.84 4.5 (2.72; 5.5)	0.237
B Mean±SD Median (min.; max.)	3.69±0.43 3.5 (3.22; 4.5)	3.33±0.8 3.36 (1.98; 4.5)	3.55±0.6 3.5 (1.98; 4.5)	0.262
C Mean±SD Median (min.; max.)	5.38±0.99 5.21 (4.2; 7)	6.2±0.71 6.31 (4.95; 7)	5.68±0.96 5.63 (4.2; 7)	0.100
D Mean±SD Median (min.; max.)	3.95±0.65 4.2 (2.84; 4.5)	3.62±0.28 3.49 (3.39; 4.1)	3.83±0.55 3.8 (2.84; 4.5)	0.174
Left masseter muscle				
A Mean±SD Median (min.; max.)	3.73±0.84 4 (2.16; 4.5)	3.53±0.87 3.37 (2.6; 5)	3.65±0.83 3.9 (2.16; 5)	0.656
B Mean±SD Median (min.; max.)	3.63±0.75 3.75 (2.58; 4.6)	3.15±0.63 3.35 (1.98; 3.6)	3.45±0.72 3.54 (1.98; 4.6)	0.208
C Mean±SD Median (min.; max.)	5.28±0.92 5.25 (3.7; 7)	5.81±0.69 5.9 (4.9; 6.81)	5.48±0.86 5.59 (3.7; 7)	0.242
D Mean±SD Median (min.; max.)	3.64±0.68 3.76 (2.13; 4.5)	3.52±0.43 3.52 (3.05; 4)	3.6±0.58 3.56 (2.13; 4.5)	0.71

Notes: Dimensions of the masseter muscle in relation to segments: A, superior transverse; B, lower transverse; C, longitudinal line of the masseter muscle; D, middle transverse line.
Abbreviation: SD, standard deviation.

Table 3 Description of the Entry Points of the Masseteric Nerve Branches in the Masseter Muscle According to Sex and Side

Variables	Gender		Total (N=16)	P
	Female (N=10)	Male (N=6)		
Total masseter muscle mean±SD median (min; max)	11±4.42 12 (6; 16)	8.83±2.71 8 (6; 14)	10.19±3.92 8.5 (6; 16)	0.492
Right masseter muscle mean±SD median (min; max)	5.5±2.27 5.5 (3; 8)	4±1.26 3.5 (3; 6)	4.94±2.05 4 (3; 8)	0.22
Left masseter muscle mean±SD median (min; max) <i>P</i> *	5.5±2.22 6.5 (3; 8)	4.83±1.72 4.5 (3; 8)	5.25±2.02 5 (3; 8) 0.165	0.792

Note: Mann–Whitney Test; *Paired Wilcoxon Test.
Abbreviation: SD, standard deviation.

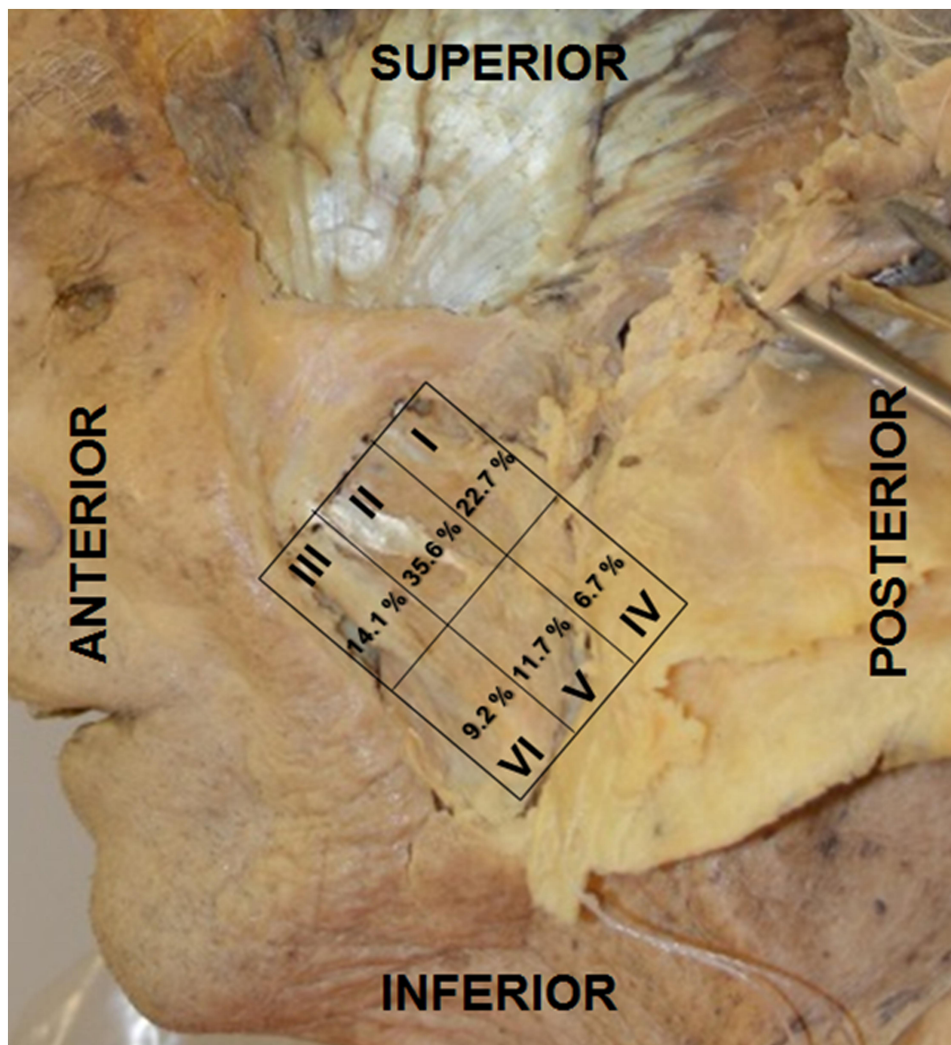


Figure 3 Sextant left masseter muscle. Percentage of nerve entry points by area. Areas numbered from I–VI, where I–III are superior and IV–VI are inferior in the posterior to anterior direction, respectively.

of MTPs in all areas of the muscle through thermography and pressure algometry, but did not mention any correlation with the muscle nerve supply. We divided the masseter muscle into six areas and considered the whole

muscle, and suggest a relationship between innervation and MTPs. The authors have previously studied the nerve supply to the trapezius, gluteus maximus, and abductor hallucis muscles^{36–38} through similar anatomical approaches and found a close relationship with the MTP regions described clinically by Travell and Simons⁷ and Simons et al.⁸ Notwithstanding the fact that the suggested MTPs locations seem to be pretty accurate, without assigning any absolute significance to those markers, anatomical correlation is still lacking.

Kim et al³⁴ published a very interesting anatomical study of the masseteric nerve branching to the masseter muscle using 12 masseter to establish safe places to botulinum toxin injection and also divided the muscle in six areas. Unlike our results, they found a higher number of nerve branches in the lower areas of the masseter, whereas

Table 4 Description of the Number of Points of Entry of the Masseteric Nerve Branches According to Sextants

Sextant	Mean±SD	Median (Min; Max)	P
1	1.16±1.14	1 (0; 4)	<0.001
2	1.81±1.26	2 (0; 4)	
3	0.72±0.96	0 (0; 3)	
4	0.34±0.65	0 (0; 2)	
5	0.59±0.8	0 (0; 3)	
6	0.47±0.84	0 (0; 3)	

Note: GEE with Poisson distribution and identity binding function.

Abbreviation: SD, standard deviation.

our dissections showed that this area had few nerve branches. In our study the most important areas were located superiorly (I and II). Their conclusion that a safer area to inject botulinum toxin based is in opposition to our findings. We do not know the reason for this discrepancy, even after estimating some possible differences in sextant determination and depth of the muscle layer which were considered. Maybe if the authors had performed statistical analysis of their findings, the results would be somewhat distinct from what they reported.

According to Simons et al⁸ the MTPs in the upper region of the masseter muscle represent pain in the lower jaw, molar teeth, and gums. In our study, the upper region corresponded to areas I and II. More specifically, the MTP described by Simons et al⁸ in the posterior and superior part of the deep muscle layer, below the temporomandibular joint (TMJ), coinciding to area I in our classification. We found a greater number of nerve penetrations in these areas, probably because this region is the “gateway” of the masseteric nerve into the masseter muscle and TMJ. The masseteric nerve crosses the anteromedial region of the joint³³ and emits more branches to these upper and proximal areas of muscle to supply most of the muscle fibers and corresponding end plates. The distal area of the muscle harbors few branches of the nerve for the thicker muscle tendon does not present motor end plates. Supposedly, the higher incidence of myofascial pain in the maxillary region could be related to the greater number of nerve penetration points in areas I and II.⁴³

Also in a cadaveric study, Kaya et al³⁵ reported a higher number of nerve branches of the masseteric nerve in the upper half of the muscle. Pain in the anterior and superior margin of the masseter muscle reflects pain to the premolars and lower molars near the lower jaw region^{7,8} which corresponds to area III of our study. Nerve penetration points in lower areas (IV, V, and VI) in our study showed a lower percentage of masseteric nerve penetration points. We did not know if the number of points was related to their dimension because there was no difference in dimensions. We cannot say if there are more points on the larger masseter.

The masseter muscle plays a significant role in masticatory myofascial pain, also known as myofascial temporomandibular disorder¹⁵ and represents the major location of pain.⁴⁴ These anatomical and physiopathological aspects justify approaches such as acupuncture, dry needling treatment, or other types of target therapy to alleviate symptoms caused by MTP-related disorders.⁴⁴

The anatomical knowledge of MTPs provides an accurate benchmark for intervention in MPS. Our results, either the ones previously reported regarding the trapezius muscle,³⁶ gluteus maximus,³⁷ and abductor hallucis,³⁸ or in the present study, concerning the masseter muscle, demonstrate a strong correlation between distribution of nerve supply and clinical characterized MTPs. The penetration areas of the masseteric nerve may correlate to MTPs and serve as a reference to diagnostic and therapeutic procedures.

Conclusion

The penetration areas of the masseteric nerve have been established and MTPs are found in the innervation zones, clinicians should focus initially on the regions of the penetration points, for diagnostics and therapeutic measures, such as injections, dry needling, and soft tissue interventions. Anatomical study of nerve supply to the masseter muscle can provide useful additional knowledge to further understanding masticatory myofascial pain and to direct therapeutic interventions and diagnostic studies of temporomandibular junction dysfunction.

Acknowledgments

The authors also would like to thank Marcos Vinicius de Oliveira for his collaboration in preparing Figure 1 during the project and the donors by the use of cadaveric tissue.

Disclosure

The authors declare no conflicts of interest in this work. The abstract of this paper was presented at the Experimental Biology 2016 Meeting Abstracts as a poster presentation. The poster's abstract was published in 'Poster Abstracts' in the FASEB Journal: https://doi.org/10.1096/fasebj.30.1_supplement.1b1.

References

1. Cimmino MA, Ferrone C, Cutolo M. Epidemiology of chronic musculoskeletal pain. *Best Pract Res Clin Rheumatol*. 2011;25(2):173–183. doi:10.1016/j.berh.2010.01.012
2. Gerwin RD. Classification, epidemiology, and natural history of myofascial pain syndrome. *Curr Pain Headache Rep*. 2001;5(5):412–420. doi:10.1007/s11916-001-0052-8
3. Fleckenstein J, Zaps D, Ruger LJ, et al. Discrepancy between prevalence and perceived effectiveness of treatment methods in myofascial pain syndrome: results of a cross-sectional, nationwide survey. *BMC Musculoskelet Disord*. 2010;11:32. doi:10.1186/1471-2474-11-32
4. Borg-Stein J, Iaccarino MA. Myofascial pain syndrome treatments. *Phys Med Rehabil Clin N Am*. 2014;25(2):357–374. doi:10.1016/j.pmr.2014.01.012
5. Srbely JZ. New trends in the treatment and management of myofascial pain syndrome. *Curr Pain Headache Rep*. 2010;14(5):346–352. doi:10.1007/s11916-010-0128-4

6. Money S. Pathophysiology of trigger points in myofascial pain syndrome. *J Pain Palliat Care Pharmacother.* 2017;31(2):158–159. doi:10.1080/15360288.2017.1298688
7. Travell JG, Simons DG. *Myofascial Pain and Dysfunction: The Trigger Point Manual.* Baltimore; London: Williams & Wilkins; 1983.
8. Simons DG, Travell JG, Simons LS. *Myofascial Pain and Dysfunction: The Trigger Point Manual, Upper Half of Body.* Baltimore: Williams & Wilkins; 1999.
9. International Association for the Study of Pain. Global year against musculoskeletal pain; musculoskeletal pain, fact sheets; 2017. Available from: <https://www.iasp-pain.org/Advocacy/Content.aspx?ItemNumber=1101>. Accessed July 08, 2019.
10. Ciancaglini R, Testa M, Radaelli G. Association of neck pain with symptoms of temporomandibular dysfunction in the general adult population. *Scand J Rehabil Med.* 1999;31(1):17–22. doi:10.1080/003655099444687
11. Lobbezoo F, Visscher C, Naeije M. Impaired health status, sleep disorders, and pain in the craniomandibular and cervical spinal regions. *Eur J Pain.* 2004;8(1):23–30. doi:10.1016/S1090-3801(03)00061-2
12. Madland G, Newton-John T, Feinmann C. Chronic idiopathic orofacial pain: I: what is the evidence base? *Br Dent J.* 2001;191(1):22–24. doi:10.1038/sj.bdj.4801081
13. Macfarlane TV, Blinkhorn AS, Davies RM, Worthington HV. Association between local mechanical factors and orofacial pain: survey in the community. *J Dent.* 2003;31(8):535–542. doi:10.1016/S0300-5712(03)00108-8
14. LeResche L. Epidemiology of temporomandibular disorders: implications for the investigation of etiologic factors. *Crit Rev Oral Biol Med.* 1997;8(3):291–305. doi:10.1177/10454411970080030401
15. Özden MC, Atalay B, Özden AV, Çankaya AB, Kolay E, Yildirim S. Efficacy of dry needling in patients with myofascial temporomandibular disorders related to the masseter muscle. *Cranio.* 2018;9:1–7. doi:10.1080/08869634.2018.1526848
16. Hu KS, Kim ST, Hur MS, et al. Topography of the masseter muscle in relation to treatment with botulinum toxin type A. *Oral Surg Oral Med Oral Pathol Oral Radiol Endod.* 2010;110(2):167–171. doi:10.1016/j.tripleo.2009.12.036
17. National Institute of Dental and Craniofacial Research [homepage internet]. Facial pain. Available from: <https://www.nidcr.nih.gov/research/data-statistics/facial-pain>. Accessed November 15, 2017.
18. McComas AJ. Oro-facial muscles: internal structure, function and ageing. *Gerodontology.* 1998;15(1):3–14. doi:10.1111/j.1741-2358.1998.00003.x
19. Sasaki K, Hannam AG, Wood WW. Relationships between the size, position, and angulation of human jaw muscles and unilateral first molar bite force. *J Dent Res.* 1989;68(3):499–503. doi:10.1177/00220345890680031401
20. Raadsheer MC, van Eijden TM, van Ginkel FC, Prahl-Andersen B. Contribution of jaw muscle size and craniofacial morphology to human bite force magnitude. *J Dent Res.* 1999;78(1):31–42. doi:10.1177/00220345990780010301
21. Stranding S. *Gray's Anatomy: The Anatomical Basis of Clinical Practice.* 40th ed. London, UK: Churchill Livingstone; 2008.
22. Hong CZ, Simons DG. Pathophysiologic and electrophysiologic mechanisms of myofascial trigger points. *Arch Phys Med Rehabil.* 1998;79(7):863–872. doi:10.1016/S0003-9993(98)90371-9
23. Simons DG, Hong CZ, Simons LS. Endplate potentials are common to midfiber myofascial trigger points. *Am J Phys Med Rehabil.* 2002;81(3):212–222. doi:10.1097/00002060-200203000-00010
24. Kuan TS. Current studies on myofascial pain syndrome. *Curr Pain Headache Rep.* 2009;13(5):365–369. doi:10.1007/s11916-009-0059-0
25. Simons DG. Do endplate noise and spikes arise from normal motor endplates? *Am J Phys Med Rehabil.* 2001;80(2):134–140. doi:10.1097/00002060-200102000-00012
26. Simons DG. New views of myofascial trigger points: etiology and diagnosis. *Arch Phys Med Rehabil.* 2008;89(1):157–159. doi:10.1016/j.apmr.2007.11.016
27. Xie P, Qin B, Yang F, et al. Lidocaine injection in the intramuscular innervation zone can effectively treat chronic neck pain caused by MTrPs in the trapezius muscle. *Pain Physician.* 2015;18(5):815–826.
28. Fernández-de-las-Peñas C, Alonso-Blanco C, Miangolarra JC. Myofascial trigger points in subjects presenting with mechanical neck pain: a blinded, controlled study. *Man Ther.* 2007;12(1):29–33. doi:10.1016/j.math.2006.02.002
29. Barbero M, Cescon C, Tettamanti A, et al. Myofascial trigger points and innervation zone locations in upper trapezius muscles. *BMC Musculoskelet Disord.* 2013;14:179. doi:10.1186/1471-2474-14-179
30. Kirkwood BR, Sterne JAC. *Essential Medical Statistics.* 2nd ed. Massachusetts, USA: Blackwell Science; 2006.
31. McCullagh P, Nelder JA. *Generalized Linear Models.* 2nd ed. New York, USA: Chapman and Hall; 1989.
32. Neter J, Kutner M, Nachtsheim CJ, Wasserman W. *Applied Linear Statistical Models.* 4th ed. Illinois: McGraw-Hill/Irwin; 1996.
33. Johansson AS, Isberg A, Isacson G. A radiographic and histologic study of the topographic relations in the temporomandibular joint region: implications for a nerve entrapment mechanism. *J Oral Maxillofac Surg.* 1990;48(9):953–961. doi:10.1016/0278-2391(90)90008-p
34. Kim DH, Hong HS, Won SY, et al. Intramuscular nerve distribution of the masseter muscle as a basis for botulinum toxin injection. *J Craniofac Surg.* 2010;21(2):588–591. doi:10.1097/SCS.0b013e3181d08bb3
35. Kaya B, Apaydin N, Loukas M, Tubbs RS. The topographic anatomy of the masseteric nerve: a cadaveric study with an emphasis on the effective zone of botulinum toxin A injections in masseter. *J Plast Reconstr Aesthet Surg.* 2014;67(12):1663–1668. doi:10.1016/j.bjps.2014.07.043
36. Akamatsu FE, Ayres BR, Saleh SO, et al. Trigger points: an anatomical substratum. *Biomed Res Int.* 2015;2015:623287. doi:10.1155/2015/623287
37. Akamatsu FE, Yendo TM, Rhode C, et al. Anatomical basis of the myofascial trigger points of the gluteus maximus muscle. *Biomed Res Int.* 2017;2017:4821968. doi:10.1155/2017/4821968
38. Wada JT, Akamatsu FE, Hojaji F, et al. An anatomical basis for the myofascial trigger points of the abductor hallucis muscle. *Biomed Res Int.* 2020;2020:9240581. doi:10.1155/2020/9240581
39. Basmajian JV, De Luca CJ. *Muscles.* 5th ed. Baltimore, USA: Williams & Wilkins; 1985.
40. Simons DG. Clinical and etiological update of myofascial pain from trigger points. *J Musculoskelet Pain.* 1996;4(1–2):93–121. doi:10.1300/J094v04n01_07
41. Gerwin RD, Dommerholt J, Shah JP. An expansion of Simons' integrated hypothesis of trigger point formation. *Curr Pain Headache Rep.* 2004;8(6):468–475. doi:10.1007/s11916-004-0069-x
42. Haddad DS, Brioschi ML, Arita ES. Thermographic and clinical correlation of myofascial trigger points in the masticatory muscles. *Dentomaxillofac Radiol.* 2012;41(8):621–629. doi:10.1259/dmfr/98504520
43. Ritter L, Lutz J, Neugebauer J, et al. Prevalence of pathologic findings in the maxillary sinus in cone-beam computerized tomography. *Oral Surg Oral Med Oral Pathol Oral Radiol Endod.* 2011;111(5):634–640. doi:10.1016/j.tripleo.2010.12.007
44. Santos Silva RS, Conti PC, Lauris JR, da Silva RO, Pegoraro LF. Pressure pain threshold in the detection of masticatory myofascial pain: an algometer-based study. *J Orofac Pain.* 2005;19(4):318–324.

Journal of Pain Research

Dovepress

Publish your work in this journal

The Journal of Pain Research is an international, peer reviewed, open access, online journal that welcomes laboratory and clinical findings in the fields of pain research and the prevention and management of pain. Original research, reviews, symposium reports, hypothesis formation and commentaries are all considered for publication. The manuscript

management system is completely online and includes a very quick and fair peer-review system, which is all easy to use. Visit <http://www.dovepress.com/testimonials.php> to read real quotes from published authors.

Submit your manuscript here: <https://www.dovepress.com/journal-of-pain-research-journal>