

# W-plasty in Scar Revision: Geometrical Considerations and Suggestions for Site-specific Design Modifications

Ioannis Goutos, MBBS, BSc,  
FRCSEd, MSc\*

Ali H. Yousif, FEBOBRAS, FRCS,  
MSc†

Rei Ogawa, MD, PhD, FACS‡

**Background:** A large proportion of scars in clinical practice represent good candidates for surgical revision by virtue of their unfavorable characteristics and relative orientation with respect to skin relaxed tension lines. W-plasty is a very popular excisional revision technique, which involves breaking up the scar margins into small triangular components, which are advanced and interdigitated without any rotation or transposition.

**Methods:** We performed an extensive literature search using Pubmed MEDLINE, Web of Science, and Embase using the following keywords [W-plasty] AND [scar] AND [revision]. We retrieved 13 articles pertinent to the indications, geometrical design, and technical evolution of the W-plasty scar revision variants. We formulate indications for the use of isosceles/equilateral as opposed to scalene triangle W-plasty and integrate our experience with regards to the choice of geometrical design for different bodily regions.

**Conclusions:** W-plasty represents a popular technique in reconstructive plastic surgery practice. We believe that the exact W-plasty design should be guided by the relaxed skin tension line definition and to this effect propose 2 main variants of geometrical design pertinent to the index anatomical site. (*Plast Reconstr Surg Glob Open* 2019;7:e2179; doi: 10.1097/GOX.0000000000002179; Published online 2 April 2019.)

## INTRODUCTION

The inevitable consequence of wound healing is scar formation,<sup>1</sup> which can have a significant impact on patients' physical and psychological wellbeing. The ideal scar is thin, flat, oriented along the relaxed skin tension lines (RSTLs) and has good color match with the surrounding skin.<sup>2</sup> In clinical practice, a large proportion of scars are symptomatic, unsightly, and not ideally oriented within the skin.

Scar revision has the potential to improve patients' quality of life by creating a scar with better tissue quality that is cosmetically and functionally more acceptable; central to this is an ideal orientation parallel to RSTLs.<sup>3</sup>

From the \*Department of Plastic Surgery, Royal London Hospital, Barts Health London, London, United Kingdom; †Department of Plastic Surgery, Bedford Hospital, Bedford, United Kingdom; and ‡Department of Plastic, Reconstructive and Aesthetic Surgery, Nippon Medical School, Tokyo, Japan

Received for publication October 24, 2018; accepted January 11, 2019.

Copyright © 2019 The Authors. Published by Wolters Kluwer Health, Inc. on behalf of The American Society of Plastic Surgeons. This is an open-access article distributed under the terms of the Creative Commons Attribution-Non Commercial-No Derivatives License 4.0 (CCBY-NC-ND), where it is permissible to download and share the work provided it is properly cited. The work cannot be changed in any way or used commercially without permission from the journal.  
DOI: 10.1097/GOX.0000000000002179

W-plasty is a popular excisional scar revision technique, using short serial triangular incisions on either side of the scar, which are advanced without any rotational element. The aim of this work is to review the evolution of W-plasty techniques over time with particular reference to the choice of component triangles and propose a site-specific selection of W-plasty techniques in scar management practice.

## Scar Revision Techniques

Surgical scar revision using local flap techniques can be divided into excisional and incisional modalities based on whether the scar tissue is removed or released in situ before neighboring tissue is rearranged in a variety of configurations. A large number of local flaps have been described in the literature including Z-plasty, Y-V/V-Y, and W-plasty techniques each of which have their own merits and shortcomings.<sup>4</sup>

Z-plasty is a widely used technique for revision of scars that require alteration of their direction in relation to

**Disclosure:** The authors have no financial interest to declare in relation to the content of this article.

Supplemental digital content is available for this article. Clickable URL citations appear in the text.

RSTLs.<sup>5</sup> It involves raising equal-in-size triangular flaps in the immediately adjacent skin and transposing them following a degree of undermining. Z-plasty makes scars less noticeable by reorienting the central scar portion in a parallel fashion to RSTLs, and it is most useful in treating linear scar contractures. The limitations of the technique relate to the risk of necrosis of the undermined flaps and the limited applicability in areas where transposition can result in distortion of anatomical boundaries such as adjacent to the hairline. Furthermore, in longer scars, where a serial multiple Z-plasties are used, the resulting flaps in the middle of the revision are rhombic as opposed to triangular in shape, which makes transposition challenging without secondary trimming. In addition, the length of the resulting scar is 3 times longer than the original and at least one-third of it will not be aligned to RSTLs.

Another popular scar contracture release technique includes the Y-V advancement. The design is based on its alphabetic configuration and is ideally indicated to release scar band contractures. Major advantages include the lack of undermining as in Z-plasty techniques resulting in lower risk for flap ischemia and the greater degree of lengthening achieved compared with Z-plasty techniques (100% versus 75% with a 60-degree Z-plasty).<sup>6</sup>

#### W-plasty: Evolution of Surgical Technique

W-plasty is an excisional technique, which involves breaking up the scar margins into small triangular components, which are simply advanced without rotation or transposition.<sup>7</sup>

Penn first described the use of a “zigzag incision” in the seam closure of a tubed pedicle; six years later, in 1954, Covarrubias, reported on an “Original Technique in the Treatment of Facial Scars,” in which scars were excised after identifying the skin lines of tension and in relation to the deep layers with closing the wound in a zigzag pattern.<sup>8</sup> Following this, Borges<sup>9</sup> described W-plasty in details for scar revision, and Penn<sup>10</sup> described a similar diamond-shaped W-plasty for cross hatch scar revision.

The first mathematical analysis of the technique appeared in the literature by Fleming and Williams<sup>11</sup>; this work formally proposed the benefits of the technique in terms of altering/minimizing the forces across the scar and quantified the degree of reduction in “spreading” forces according to the angle of the component triangles in the W-plasty. Borges<sup>12</sup> published his perspective on the various technical aspects of the W-plasty operation in relation to the shape of component triangles as part of planning and technical tips to improve the outcome of the scar revision including the management of dog ears at either end of the reconstruction.

Over the years, a number of modifications of the original technique have been described such as the use of “pinking” scissors to create the triangular flaps on either side of the excised scar; however, this was not popularized in view of its limitations, which include the small dimensions of the resulting triangles, unsuitability for small scars, and the need for considerable undermining to introduce the scissor blades into the wound.<sup>13</sup>

#### W-plasty: Indications, Merits and Shortcomings

W-plasty is a popular revisional technique in plastic surgery practice whose indications include the following<sup>4,14-17</sup>:

1. Scars not aligned to RSTL,
2. Scars on curved surfaces (eg, mandibular border) and concave surfaces where webbing and cicatricial healing are predicted,
3. “Trapdoor” U-shaped defects,
4. Scars on anatomical transitional zones including the hairline, and
5. Others including cleft palate, peristomal stenosis, depressed scars associated with pin-site scars, and correction of hanging neck deformity.

The advantages of the technique include the following<sup>17</sup>:

1. Easy learning curve. W-plasty is a relatively easy technique to plan and perform.
2. Minimal risks. The W-plasty flaps are not transposed; this is advantageous in terms of avoiding distorting areas like the hairline and eliminating the risk of flap necrosis.
3. Versatility. The small size of flaps and transverse mobility make this technique particularly useful for scars over a curved surface such as the jaw.
4. Reduction of tension in a multidirectional manner. W-plasties may contribute to the improvement of previously hypertrophic scars by breaking up the scar borders into smaller triangular segments and hence redirecting the forces of contracture/converting the lines of distraction from perpendicular to oblique and relieving the bowstringing effect of linear scars.
5. Camouflaging effect in relation to RSTLs. It has been argued that the small limbs of W-plasty are more appropriately consistent with the lines of RSTLs as opposed to a Z-plasty, where in theory only the central limb does so. W-plasty achieves a camouflaging effect by dividing the scar into very small segments and intermingling them with normal unscarred skin.

The disadvantages of W-plasty techniques relate to the following:

1. A certain width of tissue which must be given up in the revisional procedure; hence, it may be contraindicated in certain areas of the body, for example, scars parallel to the vermilion/eyelid border.
2. The overall length of the resulting scar is longer (common limitation of most scar revision surgical techniques).

#### Basic Mathematics of W-plasty Design

- Borges<sup>9</sup> described the technique by drawing isosceles triangles (two 65-degree angles and one 50 degrees) to span along the length of the scar. Following scar excision, the flaps are advanced in a way that the tips of the flaps on one side correspond exactly to the angles made at the base of the triangles on the opposite side resulting in a W closure pattern. His view about this technique relates to the fact that breaking the scar in a

geometric shape makes it inconspicuous by “following the lines of skin tension more closely” (Fig. 1).

- Penn<sup>7</sup> described a technique employing a series of diamond-shaped incision patterns for cross hatch scars (ie, multiple Ws on either side of the scar). Following incision and undermining, a slight shift is required to allow interdigitation of the 2 sides; the inevitable dog ears at either side of the revision need to be dealt with by removing a small triangle but inevitably lengthening the resulting final scar (Fig. 2).
- Fleming and Williams<sup>11</sup> employed a 60-degree angle-based (ie, equilateral triangle) design for marking. His work utilized a mathematical analysis to prove that the beneficial effect of W-plasty relates to the decomposition of the original vector (perpendicular to RSTLs) into one, which lies oblique to RSTLs, hence exerting less spreading force across the scar similar to the movement of accordion pleats. A 45-degree angle at the apex of the triangle provides a 29% reduction in spreading forces, whereas a 60-degree angle corresponds to a 50% reduction (an 80-degree angle would theoretically give an 83% reduction but is impractical given the risk of ischemia at the tips of the triangles).
- Kelleher<sup>17</sup> in his publication commented on the possible variable geometry of the component triangles and was the first to eluded to the scalene triangle (“L-shaped”) configuration, but did not provide any indications for the use of this design.
- Borges<sup>12</sup> described his personal account on the execution of the revisional technique and also reiterated that in principle the angle of the component triangles should be approximately 60 degrees (equilateral triangles) but can be increased to 90 degrees (scalene triangles), which he coined stair W-plasty technique; nevertheless, close

scrutiny of the publication drawing reveals that most of the angles are indeed isosceles or equilateral with only a small proportion of the plasty limbs aligning with RSTLs. A fusiform excision at the very ends of the W-plasty was proposed in this work as an effective way to deal with dog ears on either side of the revision.

- Shockley<sup>4</sup> advocated that in order to reduce the chance of dog ear formation on either side of the wound, the W-plasty angles at each end need to be 30 degrees.

#### Practical Considerations in Site-specific Choice of W-plasty Design

We believe that optimum results with W-plasty can be gained by choosing appropriate triangle geometry in relation to the scar anatomical site and the degree of RSTL definition. Taking this in consideration, we propose 2 main designs of either the isosceles/equilateral or the scalene triangle W-plasty.

In most cases, the geometrical characteristics of W-plasty involve 2 or even 3 equal sides of adjacent triangles, and therefore, the resulting shape is series of either isosceles or equilateral triangles. We believe that this configuration suits bodily regions with curved surfaces lacking clear lines of RSTLs as exemplified by the submental region and the cheek **Supplemental Digital Content 1** displays isosceles triangle W-plasty scar revision in the submental region of a 62-year-old female, <http://links.lww.com/PRSGO/B30>.

This configuration allows the breaking down of the scar into smaller triangles with at least one side parallel to poorly defined RSTL; the resulting “broken-line” or accordion effect makes the result less noticeable by reducing the tension during healing and scar maturation.

On the other hand, we propose the W-plasty technique utilizing scalene triangle geometry in regions of well-defined RSTL as exemplified by the nasolabial region and




Fig. 1. Isosceles triangle W-plasty markings.

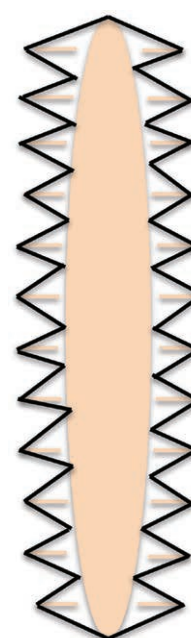
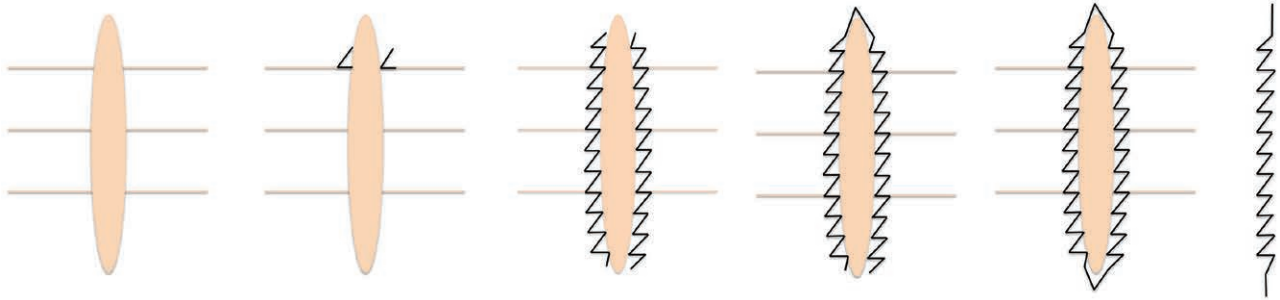


Fig. 2. Penn's<sup>10</sup> diamond-shaped W-plasty excision markings.



**Fig. 3.** Scalene triangle W-plasty markings.

forehead. Following delineation of the RSTL, we draw the smaller side of the triangle coinciding with the wrinkle lines and complete the scalene triangle, which results in one angle being 90 degrees. The rest of the design follows the same principles as the isosceles/equilateral triangle variant. In certain situations, one end of the drawing needs to be modified according to the differential vector of RSTLs, so the resulting scar falls on the exact RSTL configuration (Fig. 3).

**Supplemental Digital Content 2** displays scalene triangle W-plasty scar revision in forehead region of a 43-year-old female with localized scleroderma. Please note the lower part of the revision is a linear pattern to coincide with the configuration of the ipsilateral glabellar RSTL, <http://links.lww.com/PRSGO/B31>, illustrates the preoperative drawings and postoperative outcomes following scalene triangle W-plasty for a forehead scar revision.

### CONCLUSIONS

In summary, W-plasty is a well-established scar revision technique and represents an effective way to realign a scar with minimal tension. We believe that the exact W-plasty design should be guided by the anatomical contours of the index anatomical site and the strength of RSTL definition in order to maximize outcomes and patient satisfaction.

**Ioannis Goutos, MBBS, BSc, FRCSEd, MSc**  
 Consultant Plastic Surgeon  
 Royal London Hospital  
 Barts Health London  
 Whitechapel Road  
 London E1 1BB  
 United Kingdom  
 E-mail: ioannisgoutos@hotmail.com

### REFERENCES

- O’Kane S. Wound remodelling and scarring. *J Wound Care*. 2002;11:296–299.
- Watson D, Reuther MS. Scar revision techniques-pearls and pitfalls. *Facial Plast Surg*. 2012;28:487–491.
- Borges AF. Relaxed skin tension lines. *Dermatol Clin*. 1989;7:169–177.
- Shockley WW. Scar revision techniques: Z-plasty, W-plasty, and geometric broken line closure. *Facial Plast Surg Clin North Am*. 2011;19:455–463.
- Hove CR, Williams EF III, Rodgers BJ. Z-plasty: a concise review. *Facial Plast Surg*. 2001;17:289–294.
- Lin TM, Lee SS, Lai CS, et al. Treatment of axillary burn scar contracture using opposite running Y-V-plasty. *Burns*. 2005;31:894–900.
- Rodgers BJ, Williams EF, Hove CR. W-plasty and geometric broken line closure. *Facial Plast Surg*. 2001;17:239–244.
- Penn J. Zigzag modification of the tubed-pedicle flap. *Br J Plast Surg*. 1948;1:110.
- Borges AF. Improvement of antitension-lines scar by the “W-Plastic” operation. *J Plast Reconstr Aesthet Surg*. 1959;12:29–33.
- Penn J. The removal of “cross-hatch” scars. *Plast Reconstr Surg Transplant Bull*. 1960;25:73–76.
- Fleming JH, Williams HE. Mathematical analysis of the W-plasty and related scar revisions. *Clin Plast Surg*. 1977;4:275–281.
- Borges AF. W-plasty. *Ann Plast Surg*. 1979;3:153–159.
- Sokolowich D, Zimman O. W-plasty: make it easy. *Plast Reconstr Surg*. 1989;83:928–929.
- Beraldo S, Titley G, Allan A. Use of W-plasty in stenotic stoma: a new solution for an old problem. *Colorectal Dis*. 2006;8:715–716.
- Saleh M, Howard AC. Improving the appearance of pin-site scars. *J Bone Joint Surg Br*. 1994;76:906–908.
- Ehlert TK, Thomas JR, Becker FF Jr. Submental W-plasty for correction of “turkey gobbler” deformities. *Arch Otolaryngol Head Neck Surg*. 1990;116:714–717.
- Kelleher JC. W-plasty scar revision and its extended use. *Clin Plast Surg*. 1977;4:247–254.